



LETTERS TO THE EDITOR AND BRIEF COMMUNICATIONS

A simple device to facilitate reduction of lymphoedema of lower extremity

Sir,

Lymphoedema of the extremities is not uncommon in India. Decision about the treatment of lymphoedema depends on the aetiology. In general, the treatment of lymphoedema includes drugs, physical therapy (lymph massage, elastic pressure garments, intermittent pneumatic compression, limb elevation during rest), surgery and psychosocial rehabilitation. The main aim, specially in filarial lymphoedema, is to reduce the swelling and its maintenance for life long.

has been fabricated. It contains a wooden platform $3\frac{1}{2}$ feet long and 3 feet wide with two legs of 8 inches height attached to one end (Fig 1). This keeps the lower extremities effectively elevated in lying down position. The efficacy of this device was evaluated over other methods of limb elevation in 54 patients for the last one year. The device appears to be simple, effective, economical and comfortable. It may be used in other conditions like venous oedema whenever elevation of the lower limb is advised.

This wooden platform used in a camp conducted for treatment of patients with filarial lymphoedema at lymphoedema

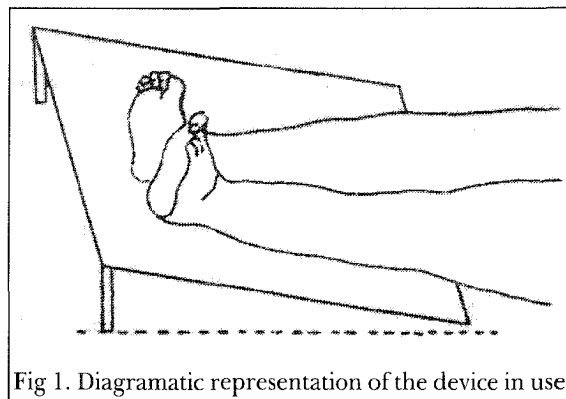


Fig 1. Diagrammatic representation of the device in use

Limb elevation is a well established method to encourage dependent drainage. Use of pillows and raising leg end of the bed is often used in clinical practice for lower limb oedema. Use of pillows, usually advised for this purpose, is often ineffective due to difficulty in maintaining the position and unnecessary strain on the knee joint due to hyperextension. Keeping these various problems in mind, a simple device for elevation of oedematous limb

treatment centre, Chidambaram in collaboration with the Filaria Department, Govt. of Tamil Nadu was found to be an inexpensive and effective addition in the management protocol.

S Mishra MS, DNB, MCh
 Lymphoedema Treatment Centre
 338, II Main Road
 Annamalai Nagar-608002
 Chidambaram, Tamil Nadu, India

Collagen sheets for skin graft donor site dressings

sir,


Collagen sheets are being used widely over several kinds of wounds as a biological dressing. Experience has shown that it may be beneficial especially in superficial scald burns in children. It is also now being aggressively marketed as a skin graft donor site dressing.

Under certain circumstances it may probably do more harm than good. Pus collection under collagen sheets occurs when it has been applied on wounds with dead tissue and was not adequately meshed. In the Burns Unit at Manipal it is used in extensive burns to provide temporary cover to excised burn wounds and skin graft donor sites. We always mesh the collagen sheets with the intention of avoiding fluid and pus collection under them. We have occasionally seen skin graft donor sites being converted to deeper wounds when collagen sheets were used over donor sites with infected foci in the vicinity.

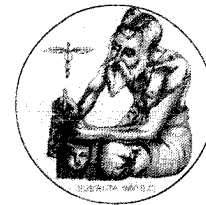
This is true specially in those cases when the donor site dressing was not opened till 10th to 14th day as is the convention in donor site management. External signs of donor site infection may not be evident in extensively burned patients. Inspection revealed pus collection under the collagen sheets and on one occasion a skin graft donor site had to be skin grafted as all epithelial elements were destroyed due to infection.

Probably it may be prudent to inspect donor sites covered with collagen sheets on the third day or so to monitor the progress of wound healing, unlike conventional donor area dressings which are removed after complete healing. Collagen sheets provide biological wound cover but one should be aware of its potential harmful effects to use it effectively.

Paul C Thomas MS, FRCS, MCh
Assistant Professor
Department of Plastic Surgery
Kasturba Medical College, Manipal 576 119
Karnataka, India



College of Pharmaceutical Sciences, Manipal



INTERNATIONAL ABSTRACTS

Long-term result of free forearm skin flap for repair of soft tissue defects of the oral and maxillofacial regions

Chang H, Wu S, Liu M. Chinese J Reparation and Reconstruction Surg 1998;12:65-67.

To evaluate the long-term result of free forearm skin flap in the repair of soft tissue defects of the oral and maxillofacial regions, 26 cases which had received radical resection of maxillofacial tumors were followed-up for 4.5 years. Twenty cases with complete data were analyzed. In this series, there were 8 males and 12 females with age range from 40 to 69 years. The size of the flaps ranged from 4cm x 5cm ~ 6cm x 13cm. The radial artery and the cephalic vein were used as the donor vessels, and maxillary artery, superior thyroid artery, external and the anterior jugular vein were prepared as the recipient vessels. The result was satisfactory in all 20 cases as evaluated according to the shape, colour, temperature and sensation of the flap. The blood supply and function of the donor hand had no problem. The donor site complications were noticed in 4 cases. The conclusion were: (1) Free forearm skin flap is worth trying in the repair of soft tissue defects of oral region; (2) The radial artery need not to be reconstructed because of the abundant vascular network in the upper limb and (3) The residual scar on the forearm was the main shortcoming, but most of the patients could tolerate it because of the obvious advantages received from the operation.

Khoo Boo Chai

Corresponding Author: Dr. Cheng Hong-bin, Department of Microsurgery and Oral Surgery,

Affiliated Hospital Nantong Medical College, Nantong 226001, P R China

Reconstruction of the floor of the mouth with facial artery musculocutaneous flap

Yang M, Kuang M, Cao C. Chinese J Reparation and Reconstruction Surg 1998;12:68-70.

In order to study the clinical efficacy of facial artery musculocutaneous flap in repairing defects of the floor of the mouth, 21 patients had received this form of treatment from 1991 to 1997. The size of the flaps ranged from 8.0 x 3.4cm to 12.1 x 5.4cm and the average age of these patients was 59.5 year. The donor site was closed directly. Nineteen flaps survived completely, while necrosis occurred at the apex of the other 2 flaps, which healed by ordinary management. The applied anatomy of the flap and the design and the main points of the operation were described in details. The advantage of the flap and the prevention of facial malformation following operation were discussed. The conclusion was that this type of flap is ideal for reconstruction of the defects of floor of the mouth.

Khoo Boo Chai

Corresponding Author: Dr Yang Mao-lin, Department of Maxillofacial Surgery, Daping Hospital, Chongqing 40042, P R China

Histological evaluation of collagen-hydroxyapatite composite as osseous implants in the repair of mandibular defect

Cheng Y, Zhao G, Liu H. Chinese J Reparation and Reconstruction Surg 1998;12:74-76.

To observe the collagen-hydroxyapatite composite in the repair of bone defects, ten pigs were chosen and a mandibular defect measuring 2cm in diameter was made. The composite was implanted, while the use of autogenous bone graft served as control. At 4,8,12,24 and 48 weeks after the operation, animals were sacrificed and the examination of samples under light microscope showed no infection or necrosis. The composite coalesced with the host bone and the outcome was similar to that of the autogenous bone graft. No foreign body giant cells or vacuum left from osteonecrosis was observed. It was suggested that the composite had the advantage of abundant supply, easy handling and causes no harm. The biocompatibility was good and it deserves more study as a bone substitute.

Khoo Boo Chai

Corresponding author: Dr Cheng Yu-hua, Department of Stomat, 254 Hospital, PLA, Tianjin 300142 P R China

Primary microsurgical repair of multi-structural defects of hand

Sui H, Cong H, Wang S. Chinese J Reparation and Reconstr Surg 1998;12:81-82.

Forty-eight cases of multi-structural defects of hands were primarily repaired or reconstructed from 1989 to 1997. The structural defects were the defects of radial or ulnar aspect of hands involving multiple fingers and skin. In this series, there were 32 males and 16 females with age ranging from 17 to 46 years. The composite tissue grafts were obtained from wrap-around flap or 2nd toe skin flap of the foot. The result showed that of the 108 composite tissue transplantations in 48 cases, all survived. After a follow-up of 38.5 months (ranged from 5 months to 6 years), the grasp, pinch and opposing functions of the reconstructed finger were restored the two-point discrimination sensation was 4mm-12mm. Most of the patients were completely rehabilitated and resumed their original work. The primary repair of multi-structural defects of hands by composite tissues transplantation

was feasible and valuable, but thorough debridement and skilled microsurgical technique is required.

Khoo Boo Chai

Corresponding Author: Dr Sui-Hai-ming, Wendeng Orthop Hospital, Shandong 264400, P R China

One stage vagina reconstruction using the pudendal thigh skin flap

He Q, Lin Z, Liu Q. Chinese J Plastic surgery and Burns 1998;14:3-5.

This is to introduce a method for vagina reconstruction using the pudendal thigh skin flap. The pudendal thigh skin flap has been used for vagina reconstruction in 70 cases since 1989. All the operations were successful and the method has become a mature technique. The advantages of the method are : (1) the reconstructed vagina has good sensation and stable in maintaining its dimensions; (2) the linear scars of the donor site are hidden and inconspicuous; (3) the appearance of the perineum looks well ; (4) the procedure is simple and favors its application.

Khoo Boo Chai

Corresponding Author: Dr. He Qing-lian, Department of Plastic Surgery, Changzheng Hospital, Shanghai 200003, PR China

Effects of blocking CD₁₈ mediated leukocyte adhesion on the survival of the island flap

Gu H, Lin z, Liu Q. Chinese J. Plast Surg and Burns 1998;14:13-15.

This study was to investigate the role of leukocyte on leukocyte adhesion in tissue injury from ischemia and reperfusion. The experiment utilized the monoclonal anti-body (mAb) directed to the leukocyte adhesion glycoprotein CD₁₈ to block leukocyte adhesion and aggregation in an island flap model in rats. Tissue content of myeloperoxidase (MPO) and malondialdehyde (MDA) were detected after transient treatment with either saline or mAb

directed to CD₁₈. Flap survival was assessed 7 days afterwards. The content of both MPO and MDA was significantly increased with 8 hour ischemia and 1 hour reperfusion of the flap. The treatment with anti-CD₁₈ mAb significantly decreased the levels of MPO and MDA, and also significantly improved the survival of flaps compared with the saline - treated controls. CD₁₈ mediated leukocyte adhesion plays an important role in tissue injury from ischemia and reperfusion. Blocking leukocyte adhesion can attenuate leukocyte-mediated injury, providing protective effects on island flaps.

Khoo Boo Chai

Corresponding Author: Dr. Gu Hai-feng, Department Plastic Surgery, Changzheng Hospital, Shanghai 200003, P R China

Experimental study on the role of the pedicle subdermal vascular network skin flap

Miao Y, Xi Y, Su M. Chinese J Plast Surg and Burns 1998;14:16-18.

The experiment was to investigate the role of the pedicle of the subdermal vascular network skin flap. Ten healthy white pigs, each weighing from 20 to 25 kg were used. The subdermal vascular network skin flap and the traditional skin flap were designed and created on each side of the animal's flank. The traditional skin flap on the contralateral side of the flank was used as control. Flap survival was studied by gross observation and ECT examination of isotope distribution. There were significant differences between the two groups in the mean survival length and area ($P < 0.05$). In both groups the radioactive isotope gathering is restricted proximally with a ratio of length to width of (1 - 1.5) : 1. The presence of the pedicle of the subdermal vascular network skin flap makes no difference compared to the traditional skin flap.

Khoo Boo Chai

Corresponding Author: Dr Miao Yu-lu, Buji People's Hospital, Shenzhen 518112, P R China

Expression of proliferating cell nuclear antigen in hemangioma and vascular malformations

Lin X, Wand W, Qian W. Chinese J Plast Surg and Burns 1998;14:17-22.

This study was to compare the proliferative activity of endothelial cells of various types of hemangiomas and vascular malformations in different phases. Forty one specimens of hemangiomas or vascular malformations were stained with immunohistochemical method for proliferating cell nuclear antigen (PCNA). The proliferative activity of endothelial cells was expressed by labeling index (LI). PCNA was positive in all the proliferative strawberry, composite hemangiomas and some of cavernous hemangiomas in children. PCNA was negative in all of adult involved hemangiomas and some of cavernous hemangiomas in children. There were no statically significant differences in labeling indices of PCNA between various types of proliferating hemangiomas in children while there were statistically significant differences between child proliferating hemangiomas and involved hemangiomas in children or all of adult hemangiomas. The results may be helpful to answer some bewildering questions about hemangiomas and provide a basis for new classification.

Khoo Boo Chai

Corresponding Author: Dr Wang Wei, Department Plast Reconstr Surg., 9th People's Hospital, Shanghai 2nd Medical University, Shanghai 200011, P R China

The responses of fibroblasts from three parts of keloids and normal skin to interleukin and interleukin - 6

Xu S, Wang Z, Bao W. Chin J Plast Surg and Burns 1998;14:23-25.

The purpose of this study was to explore the responses of fibroblasts from keloids and normal skin to interleukin-1 β and interleukin-6. Six samples of normal skin were collected as

the experimental and control group respectively. The means of cell culture was used to investigate the responses of fibroblasts from the different parts of keloids and normal skin to interleukin-1p (200U/ml) and interleukin-6 (100U/ml). Interleukin-1p could inhibit the growth of fibroblasts from the proliferative part of keloids but stimulate growth of those from normal skin, while it did not affect the growth of those from other parts of the keloids.

Fibroblasts from different parts of keloids and normal skin were all inhibited by interleukin-6. The responses of fibroblasts from three parts of keloids and normal skin to interleukin-1p and interleukin-6 were not much similar.

Khoo Boo Chai

Corresponding Author : Dr. Bao Wei-han, Res Ctr Plast Surg, 3rd Clin Sch Beijing Med Univ, Beijing 100083, P R China

Effects of abnormal distribution of calcium on the impairment of myocardial mechanics in the early stage of thermal injury

Che L, Yang Z, Huan Y. Chinese J Plast Surg and Burns 1998;14 : 33-36 .

To investigate the effect of abnormal Ca^{2+} distribution on the impairment of myocardial mechanics in the early stage of thermal injury. Calcium (Ca^{2+}) changes were observed within subcellular distribution in situ in rat heart with calcium cytochemical probe and electron probe microanalytic technique. Meanwhile, myocardial mechanics and energy metabolic changes were investigated after thermal injury. The results demonstrated that levels of cytoplasmic Ca^{2+} in myocardial contraction increased at 1 hour, followed by enhanced mitochondrial Ca^{2+} at 3 hour after burn injury. Parallel to the changes in Ca^{2+} , there were decrease in myocardial contraction, and relaxation capacity and increase of ventricular wall stiffness in burned rats. A lower level of heart energy changes was observed from 6 to 12 hours, compared with the control group. The results indicate that subcellular Ca^{2+} abnormal distribution in myocardium caused by burn in-

jury may be associated with increased contraction and decreased relaxation of the myocardium.

Khoo Boo Chai

Corresponding Author: Dr. Chi Lu-xiang, Southwest Hosp, Chongqing 400038, P R China

Bound and soluble adhesion molecule and cytokine levels in patients with severe burns

Nakae H, Endo S, Yamada Y, Inada K. - Burns, 2000,26:139-144.

In this study an attempt was made to correlate the role of endotoxins, inflammatory cytokines and soluble adhesion molecules in the pathophysiology of severe burns. Seventeen patients were included in the study whose blood was measured for the above mentioned factors. All seventeen patients had burns with a total burn surface area of 20% or more and a burn index of 15% or more. Endotoxins were measured by an endotoxin-specific assay and tumor necrosis factor, interleukin 6, and interleukin 8 and soluble adhesion molecules were measured by enzyme-linked immunosorbent assay. CD11a, CD11b, and CD18 measured by flow cytometry, were elevated in the non surviving group, the septic shock group and the multiple organ dysfunction syndrome, suggesting a close connection between these adhesion molecules and burns complicated by infection.

The results of this study suggest that adhesion molecules, inflammatory cytokines and endotoxins are strongly involved in the evolution of the pathology of severe burns and that inflammatory cytokines are involved in the production of adhesion molecules. In terms of burns treatment, these results may indicate the possibility of using anti-adhesion molecule antibodies in the future.

KG Bhaskara

Corresponding author: Endo S, Critical care and emergency centre, Iwate Medical University, 19-1, Uchimaru, Morioka 020-8505, Japan

Does MRI contribute to the investigation of palatal function ?

Vadodaria S, Goodacre TEE, Auslow P. Brit J Plast Sur 2000;53:191-199.

Velopharyngeal incompetence is a complex issue and results in speech problems. Accurate assessment of the anatomical distortion and functional disorder of the velopharyngeal port by currently available methods like nasendoscopy and videofluoroscopy have their own limitations.

In this pilot study the value of MRI scanning in investigation of velopharyngeal function has been explored. MRI is noninvasive and can be easily repeated. Images may be obtained in many axes and with far more clarity than with fluoroscopy.

The study was conducted on 10 normal volunteers and 15 patients who had speech problems related to cleft and non-cleft palate pathologies. Images were obtained in four different axes; mid-sagittal, coronal, horizontal (at the level of hard palate) and in the axis of excursion of the levator palati muscle (line drawn from mid-point of velum and external auditory meatus). The various useful informations obtained were about i) length, movement and extensibility of the velum, ii) the presence or absence of the passavant's ridge and forward movement of the posterior pharyngeal wall, iii) contribution of the lateral pharyngeal wall in the velopharyngeal closure, iv) The type and extent of velopharyngeal closure, v) The levator sling at rest and its movement to achieve lift during phonation. This study clearly indicates that MRI has great potential as an additional method of evaluating the palate before and after surgery. It may also help to guide speech therapy and surgical planning of patients suffering from velopharyngeal incompetence.

Pramod Kumar

Corresponding author: Shailesh Vadodaria, 24 Gisborne Road, Sheffield S11 7HB, UK.

The outcome of long-term follow-up after Palatoplasty

Park S, Saso Y, Ito O et al. Plast Reconstr Surg 2000;105:12-17.

Push-back palatoplasty is one of the most popular treatment for cleft palate. The bones, adenoids and other tissues of the nasopharyngeal region grow and change over time, affecting velopharyngeal function and hence speech outcome. In particular, adenoids often show hypertrophy at an early age and undergo involution before adolescence, having a marked influence on velopharyngeal competence.

In this study the speech outcome was analysed retrospectively in 140 cleft-palate (with or without cleft lip) patients who underwent push-back palatoplasty at around 18 months. Velopharyngeal function and articulation disorders were evaluated serially at 4,7,10, and more than 10 years of age. Twenty eight patients (20.0 percent), who underwent pharyngeal flap surgery during the follow up period due to poor, or derioration of speech inspite of speech therapy were excluded from the study. In remaining 112 patients, velopharyngeal function and articulation disorder was compared at 4 years of age and after more than 10 years of age. The velopharyngeal function during follow up remained unchanged in 90 patients (64.3 percent), whereas it showed deterioration in 14 patients and showed improvement in 8 patients. Changes of velopharyngeal function often occurred between 4 and 7 years of age but in a few cases it was also after 10 years. Articulation disorder was observed in 49 subjects (35.0 percent) at 4 years of age. Many of the patients with glottal stop showed improvement from 4 to 7 years of age. Palatalized articulation showed less improvement than glottal stop ($p < 0.01$). The number of patients with articulation disorders decreased significantly between 4 years of age and follow up after over 10 years of age. These findings suggest that patients with operated cleft palate should be carefully followed for improvement in speech until more than 10 years of age.

Pramod Kumar

Corresponding author: Susan Park MD, Department of Plastic and Reconstructive Surgery, Kagawa Medical University, 17500-1.

Email: spark@kms.ac.jp

Temporoparietal Fascia: An Anatomical and Histologic Reinvestigation with New Potential Clinical Applications.

Tellioglu AT, Tekdemir I, Erdemli EA, Tuccar E, Ulusoy G. Plast Reconstr Surg 2000;105:40-45.

Temporoparietal fascia is synonymous to superficial temporal fascia, epicranial aponeurosis or galeal extension. Vascularised by the superficial temporal vessels, this is used for reconstruction of craniofacial defects, hand defects and as free flap. It is an important structural unit in face lift and brow lift operations.

In this study a histologically supported anatomic study was conducted on 20 sides from 10 cadavers for the reappraisal of the anatomic relationships and clinical application potential of the data obtained. Temporoparietal fascia is located just under the subcutaneous tissue and could easily be separated into inner and outer parts. Superficial temporal vessels enter between inner and outer parts of the superficial temporal fascia and then travel in the outer layer of the temporoparietal fascia. The superficial temporal fascia is continuous with i) The superficial musculoaponeurotic system (SMAS) in the inferior border, ii) with orbicularis oculi and frontalis muscles in the outer border, iii) occipitalis muscle in the posterior border and iv) though definite junction cannot be determined, it is also continuous with the galea aponeurotica in the most cephalic border. Therefore, plication for the temporoparietal fascia can increase tightness of the SMAS, orbicularis oculi and frontalis muscle in rhytidectomy. The inner part of the temporoparietal fascia which has the same borders as the outer part except for the inferior border, where it blends with innominate fascia on the zygomatic arch and continues towards the masseteric fascia. The frontal branch of facial nerve were noted to course parallel to the frontal branch of the superficial temporal artery,

lying deep to the temporoparietal fascia within the innominate fascia. Hence, careful subcutaneous dissection just under the hair follicles is more appropriate as compared with subfascial dissection to avoid nerve injury and also provide excellent exposure of the temporoparietal fascia for plication in rhytidectomy with protection of the auriculotemporal nerve and the superficial temporal vessels. Histological studies revealed thin muscle layer within the outer part of temporoparietal fascia below the temporal line, hence the term 'temporoparietal myofascial flap' would be more appropriate for this flap. The innominate fascia and deeper part of temporal fascia can be elevated with two layers of the temporoparietal myofascial flap as four layered myofascial flap based on the superficial temporal vessels.

Pramod Kumar

Corresponding author: Ali Teoman Telligoglu, MD. Kenedi Cad 61/8, 06660 Kavaklidere Ankara, Turkey. Email: tellioglu 22@hotmail.com

Trigger finger in children

Cardon LJ, Ezaki M, Carter PR. J Hand Surg 1999; 24A:1156-1161.

Trigger finger in children are much less common than trigger thumbs. Treating trigger fingers in children may not be as straight forward as trigger thumb in children or trigger digits in adults. Nodular thickening of the tendons is more common in pediatric trigger digits, where as in adults the A-1 pulley tends to be thickened and constricted.

This study involves evaluation of surgical release of 33 trigger fingers in 18 children. In 8 (44%) of these 18 children, the finger continued to trigger after A-1 pulley release. The most important finding of this study is that in children, trigger finger is rare than trigger thumb and is not often associated with a fixed flexion contracture. Unlike trigger thumb, it may not respond to usual A-1 pulley release. The surgeon should plan the incision in such a way that, if necessary, after extending the incision he should be able to explore entire

tendon sheath and its contents. Excision of tendon nodules, resection of one or both slips of the sublimis tendon, and release of the A-3 pulley may be required to correct triggering when the A-1 pulley alone does not.

Pramod Kumar

Corresponding Author: Marybeth Ezaki MD, Hand Service, The Texas Scottish Rite Hospital for Children, 2222 Welborn St., Dallas, TX 75219

Trigger finger in children

Tordai P, Engkvist O. J Hand Surg 1999;24A:1162-1165.

This 8 years period retrospective study of twelve children with triggering of 17 digits other than thumb was undertaken by the authors to verify their impression that the required treatment of triggering fingers in children is more extensive and not as simple and straight forward as with thumbs. There were eight children with single finger involvement, the remaining patients had more than one trig-

gering finger. Five children (total 7 fingers) were managed conservatively, one of these had three triggering fingers with residual triggering in all 3 involved fingers. 7 children were treated surgically. In contrast to the operative findings in children with triggering thumbs, no nodules of the flexor tendons were found in these cases. This may indicate different mechanism of triggering like anatomic variations of the chaisma of the flexor digitorum superficialis tendon. The authors advise that if an incision of the A-1 pulley alone does not clearly relieve the triggering (judged by passively moving the finger through a full range of flexion and extension), the surgical procedure should be expanded to include separation of the inserting slips of the flexor digitorum superficialis tendon and release of the proximal A-2 pulley.

Pramod Kumar

Corresponding Author: Paul Tordai, MD, Department of Hand Surgery, Stockholm Soder Hospital, S-11883 Stockholm, Sweden



Shirdi Saibaba Cancer Hospital & Research Centre, Manipal



BOOK REVIEW

Facial clefts and craniosynostosis: Principles and management

Turvey TA, Vig KWL and Fonseca RJ. W.B. Saunders Company, Philadelphia. Pages 782, 1996. ISBN 0-7216-3783-3.

A comprehensive, authoritative book on craniofacial anomalies has been a long felt necessity of all those who have been interested in this field. The fact that we in India come across quite a few of these anomalies and the lack of a standard reference text, was what kindled my interest in this book.

The book consists of four sections: Causes and Consequence, Diagnosis and Treatment planning, Surgical management and Outcome assessment, with a total of thirty chapters.

Among the many authors who have contributed to this book, the most illustrious is Dr. Paul Tessier acknowledged by most as the creator of the subspecialty of craniofacial surgery. He has contributed to two chapters - 'Facial Clefting Disorders and Craniofacial Synostes - Skeletal Considerations' which is full of illustrations and the chapter on 'Management of Mandibulofacial Dysostosis'.

The chapter 17 on 'Primary closure of Cleft Lip and Palate' is by a single author (Frank E. Abyholm of the Oslo Cleft Centre), who advocates Millard's technique for lip closure, with some modifications in bilateral complete clefts and cleft palate repair based on von Langenbeck's principles with a few changes incorporated.

The last section is on 'Outcome assessment' - which is divided into two chapters - 'A methodologic approach to outcome assessment' and 'Evaluating treatment alternatives; Measurement and Design'. I feel that both these chapters are of utmost importance in this age of doctors being held responsible for the kind of care they provide, under the consumer protection act, as well as the tendency of a few doctors to prematurely trumpet their own 'superiority', for personal publicity. The fact that the editors have succeeded in bringing together a large number of contributors (49 in all) from a variety of countries, belonging to a multitude of specialties involved in this area, is by itself creditable and lends credibility to their effort at promoting comprehensive team management (as outlined in Chapter 6) of these anomalies. An eminently readable book, the information provided is quite thorough, it is well written and sustains our interest. Overall, I feel that the authors have achieved what they set out to do, that of 'providing an overview of facial clefts and craniosynostosis', that too in a very creditable manner.

Mohan Alexander MDS

Professor, Oral and Maxillofacial Surgery
College of Dental Sciences, Manipal 576 119
Karnataka, India

Forthcoming Events

- 1. 35th National Conference of the Association of Plastic Surgeons of India**
October 14-19, 2000 at Hotel Clark Shiraj, Agra
Contact: Prof S D Pandey, Dept of Plastic Surgery, KG's Medical College, Lucknow, Uttar Pradesh
 - Tel: 0522-265546 (O) 387268 (R)
 - Fax: 0522-255092, 266025
 - E-mail: info@skbhatnagar.com, apsicol@lw1.vsnl.net.in
 - Website: rahulsahai@vsnl.com
- 2. 8th Congress of the Asian Pacific Association for Laser Medicine and Surgery (APALMS),**
October 19-22, 2000 at York Hotel, Singapore
Contact: Ms. Teo Ali Wah, Arcadia Laser Surgicentre Pvt. Ltd., 424, Balestier Road, 01-01, Giffard Mansion, Singapore 329810
 - Tel: (65) 251 2501 • Fax: 251 2934
 - E-mail: arcadua@mbox4.signet.com
- 3. The 8th Asian-Pacific Congress of IPRAS**
April 1-4th, 2001 at International Convention Centre, Taipei, Taiwan
Contact: Dr Sameul H T Chen, Secretary General, The 8th Asian Pacific Congress of IPRAS C/o Department of Plastic and Reconstructive Surgery, Chang Gung Memorial Hospital, 5-Fu-Shing Street, Kuei-Sha, Taoyuan 333 Taiwan
 - Tel: 886-3-3286654
 - Fax: 886-3-3286647
- 4. Aesthetic Surgery Symposium/BAAPS**
December 2, 2000 at The Wellington Hospital, London
Contact: Mr B M Jones MS, FRCS, The Wellington Plastic and Reconstructive Surgery Unit, The Wellington Hospital, Wellington Place, London NW8 9LE
- 5. 69th Annual Scientific Meeting of the Americal Society of Plastic Surgeons**
Plastic Surgery Education Foundation and Americal Society of Maxillofacial Surgeons. October 14-18, 2000 at Los Angeles, California
Contact: • Tel: 1-800-766-4955, Press 9; International: 847-228-990 Ext 404
 - Fax: 847-228-0117
 - E-mail: im@plasticsurgery.org
 - Website: www.plasticsurgery.org
- 6. Anatomy of the Upper Limb and Hand, Cadaveric dissection**
October 7-8, 2000 at Windsor, UK
Contact: Adam Hodgson, The Hand Clinic, Dedworth Road, Oakley Green, Windsor, Berkshire, SL44LH, UK
 - Tel: +44(0)1753 831333
 - Fax: +44(0)1753 832109
 - E-mail: anatomy@handclinic.co.uk
 - Website: www.handclinic.co.uk/hand.clinic
- 7. 7th International Course in modern Rhinoplosy Techniques and Symposium 'Pitfalls in Rhinoplasty'**
October 12-14, 2000 at Amsterdam, The Netherlands
Contact: Gilbert J Nolst Tremite MD, PhD. Academic Medical Centre of the University of Amsterdam, ENT Department, P.O.Box 22700/A2-233 100 DE Amsterdam, The Neatherlands
 - Tel.: +31 20 566 8586
 - Fax: +31 20 691 3850
- 8. 9th European Course in Plastic Surgery**
November 8-10, 2000 at Naples, Italy
Contact: Prof Guide Molea, Chair of Plastic Surgery, University of Naples, 'Federico II', Via Pansini 5, 80131 Naples, Italy
 - Tel: +39 081 7462843
 - Fax: +39 081 7463696
 - Email: molea@eds.unina.it
- 9. Craniofacial Bone Distraction Congress**
European Association for Craniomaxillofacial Surgery
November 17-19, 2000 at Graz, Australia
Contact: Prof. H Karchar, University Hospital Graz, Anenbruggerplatz 7, A-8036 Graz
 - Tel: +43/316/385-2565
 - Fax: +93/316/385 3511
- 10. AAOMS Midwinter Conference**
inconjunction with Americal Academy of Facial Plastic and Roconstructive Surgery
February 9-11, 2001 at Tampa, FL
Contact: AAOMS, 9700 W Bryn Mawr Ave, Aosemont, 12 60018
 - Tel: 1-800-822-6637
 - Fax: 1-847-678-6286

INSTRUCTIONS TO AUTHORS

Indian Journal of Plastic Surgery (IJPS) is the biannual Official Journal of the Association of Plastic Surgeons of India. The editors and publishers of IJPS invite concise articles on original clinical and/or experimental studies, new surgical techniques and comprehensive review articles which offer significant contribution to the advancement of knowledge in the field of plastic surgery. Brief reports and letter to the editor will be published depending on its originality, educational value and its validity. All the articles should contain substantive ideas and commentary supported by appropriate data and references. Only standard abbreviations should be used for units of measurement. Wherever applicable, it should include statement that the research protocol was approved by the local Ethical Committee. If accepted for publication, the contribution will be the property of the Association of Plastic Surgeons of India.

SUBMISSION REQUIREMENTS

Four complete sets of the manuscript should be submitted, each with a full set of tables and illustrations. All manuscripts must be sent to:

Pramod Kumar
Editor, Indian Journal of Plastic Surgery
Kasturba Medical College
Manipal 576 119
Karnataka, INDIA
Tel : (+91) (0)(8252) 71201 Ext 2286(O) 2135(R)
Fax : (+91) (0)(8252) 70062
Email : info @ mahe.ernet.in

The author should retain one complete set of the manuscript to avoid inconvenience due to possible losses in the mail. All manuscripts must be accompanied by duly signed statement by author(s) that the manuscript under consideration has not been published, simultaneously submitted or already accepted for publication elsewhere. This does not preclude publication of complete manuscript that follows publication of preliminary findings elsewhere provided correct reference(s) is revealed. Whenever applicable permission by the publishers to use

previously published material must be sent at the time of submission. Rejected articles will not be returned to the authors except on request.

TRANSFER OF COPYRIGHT

Author(s) must submit following duly signed transfer of copyright statement with the manuscript:

"I (we) hereby affirm that the submitted manuscript entitled _____ is neither under consideration nor has been published in any other Journal. I (we) hereby assign the copyright to the Association of Plastic Surgeons of India if accepted for publication".

If full or part of the manuscript has been published elsewhere, written permission from the corresponding author and/or the publisher must be submitted along with the manuscript. The editor reserves the right to make editorial and literary changes. Recommendations regarding major rearrangements or corrections may be offered to help authors rewrite their communication in a way that is acceptable to the journal and to enhance the presentation.

PREPARATION OF MANUSCRIPTS

All manuscripts should be type written, double spaced on good quality white A4 paper with a margin about 3cm all around. All pages should be numbered. It should be divided in following sections and each section should start on a separate page: title page, summary, text (including acknowledgements), references, tables and captions to illustrations.

TITLE PAGE: The title page should include i) title of the article, ii) full name of each author with qualification and designation, iii) name and address of the institution, iv) source of support in form of grant (if any) and v) address of the corresponding author (with phone, fax number and e-mail address if any).

SUMMARY: Summary of the manuscript should include background, methods, results

and conclusion of the study. It should not exceed more than 200 words. Three to six key words should be listed at the end in a separate line.

TEXT: The text should include: introduction, methods (including operative steps if any), results and discussion.

Introduction: Purpose of the manuscript and scientific context for the study with strictly pertinent references should be mentioned in not more than 400 words.

Methods: Methods should include selection criteria for subjects, study design, apparatus and equipment used wherever applicable. New ideas/operative steps/techniques should be described systematically and vividly.

Results: Results should be intelligible and supported by tables and illustrations, which should be accurately quoted in the text.

Discussion: Discussion should include reasons for using particular method (new or substantially modified), its advantages and limitations. New and/or important findings, important aspects of the study should be emphasized and compared with available relevant studies. **Conclusion** may be added highlighting any future scope/plan. New hypothesis when appropriate and recommendations when called for should be included.

Acknowledgement: Foot notes of acknowledgement to individuals who significantly helped in completing the study may be included at the end of the text.

REFERENCES: All references should be cited in the text numerically as superscript and in the "References" section listed in the same order as quoted in the text. If a particular reference is quoted twice or more, the same number should be repeated at appropriate places in the text. All authors names should be listed if number is less than four, but if number is five or more, first three names with et al should be added. If it is necessary to quote the name(s) of the Authors (when more than 1) in the text, it is advisable to quote first author's name followed by etal and reference number as superscript. Journal titles should

be abbreviated in the index medicus style. Using abstracts (Medline/Internet) as references should be avoided but if necessary to complete the list of references, it may be quoted as such without drawing any conclusion from it. Unpublished observations and personal communications may be cited when absolutely necessary. Manuscript accepted for publication may be added in the reference list (specify journal, year of acceptance and write "in press" in parentheses). The reference should include author(s) name, title of the manuscript, name of the journal, year of publication, volume number, and first and last page of the manuscript. All authors will be responsible for the accuracy of references.

EXAMPLES OF REFERENCES

A) Journals

i) Standard Journal Articles (List all authors when four or less but when five or more list only three and add etal.)

1. Nagarkar NM, Mann SBS, Gupta AK. Aesthetic values of nasofacial angles. Indian Journal of Plastic Surgery 1996;29:12-15.

2. Becker DG, Mc Langhlin RB, Loevner LA, Mang A. The Lateral Osteotomy in Rhinoplasty: Clinical and Radiologic Rationale for Osteotome Selection. Plast Reconstr Surg 2000;105:1806-1816 (Discussion by Rohrich RJ, Krueger JK:1817-1819).

3. Yuksel F, Kislaoğlu E, Durak N et al. Prevention of painful neuromas by epineural ligatures, flaps and grafts. Br J Plat Surg 1997;50:182-185.

ii) Corporate Author (s)

American College of Chest Physicians/Society of Critical Care Medicine Consensus Conference. Definition for Sepsis and Organ Failure and guidelines for the use of innovative therapies in sepsis. Chest 1992;20:864-974.

B) Books

i) Standard Text Books (List all author(s)/ editor(s))

1. Jackson IT, Munro IR, Salyer KE, Whitaker

LA. Atlas of Craniomaxillofacial surgery. Facial asymmetry; p258-317. St.Louis: The CV Mosby Company 1982.

2. Serafin D. Atlas of Microsurgical Composite Tissue Transplantation. Temporal Fascial Flap; p 323-330, (discussion by Upton J; p 330-338). Philadelphia: W.B. Saunders Company 1996.

3. Franklin CA (ed). Modi's text book of Medical Jurisprudence and Toxicology; p 14-15. Bombay: N.M. Tripathi Private Limited 1988.

ii) Chapters in Book

1. Posnick JC. Craniofacial dysostosis Syndrome: A staged Reconstructive Approach. In: Turvey TA, Vig KWL, Fonseca RJ (eds); Facial Clefts and Craniosynostosis: Principles and management; p 630-685. Philadelphia: W.B. Saunders Company 1996.

2. Bhattacharya V. Fasciocutaneous flaps. Plastic and Reconstructive Surgery: Current trends (proceedings of CME program at national conference of Association of Plastic Surgeons of India, Calcutta) 1998; p 36-40.

iii) Corporate Author(s)

A Guide to Leprosy Control. The World Health Organisation, Geneva 1980; p 43-44.

LEGENDS FOR ILLUSTRATIONS: Concise vivid pen picture for illustrations should be typed on a separate paper. Each illustration should be numbered and cited in the text in consecutive order.

TABLES: Each table should be numbered and typed on separate sheets and should have a brief title. Any explanatory matter (eg. nonstandard abbreviations used in the table) should be explained in the foot note using symbols (*, +, **, ++).

ILLUSTRATIONS: Photographs must be of good quality, sharp, black and white on glossy paper. The size should not be less than 5 x 7 inches. Line diagrams should be of good quality with figure number and caption below it. Colour photographs will be considered for publication only if it adds to the value of the manuscript. Authors may be asked to pay for

publication of colour photographs. Each photograph should have a label pasted on the reverse side stating number of the photograph, the title of the manuscript and arrow indicating the top of the photograph.

BRIEF REPORTS: Brief reports should not be more than two to three pages (approximately 1500 to 2500 words) of the Journal. Number of illustrations and tables should preferably be not more than 4.

LETTERS TO THE EDITOR: Letter to the editor should not be more than 500 words and limited number of relevant references should be included.

BOOK REVIEWS: Books shall be reviewed only at the discretion of the editor.

ELECTRONIC SUBMISSION: After the manuscript is accepted, the author(s) may be asked to submit the original manuscript on diskette/by e-mail. Electronic submission expedites publication with least error. Electronic submission of the original manuscript along with four copies of the manuscript and illustrations at the initial stage will avoid unnecessary delay in correspondence.

SUBMISSION CHECK LIST

- ★ Covering letter
- ★ Copyright statement (duly signed) as mentioned under heading "transfer of copy right"
- ★ Four copies of the manuscript (title page, summary, text, legends for illustrations, tables) with four sets of illustrations
- ★ Written permission granted by the corresponding author and/or the publisher to use the previously published illustrations, diagrams or part of the text with complete details about the source (if required)
- ★ Electronic submission on diskette (optional)

About the founder of Manipal

Dr. T M A Pai (1898 - 1979)



A doctor. A banker. An educationist and above all a man with rare foresight, this in essence was Dr. T M A Pai. A man who was largely responsible for the blooming of Manipal's bald hills.

His perseverance saw the birth of the first college, the first hospital and the first bank. Turning the rocky hill-top of Manipal into a beautiful garden in which blossomed an innovative bank, a premier printing press and a reputed group of publications.

Manipal is a living example of how one man's determination can bring about miracles. Dr T M A Pai had the courage to dream the impossible dream. And the resourcefulness to realise it.

Indeed, his is a life worthy of emulation.

The Stamp of Approval:



As a fitting tribute to Dr Pai's achievements and his vision for a better nation, the Government of India brought out a commemorative stamp on 9th October 1999. This honour is the latest in a long and impressive list of awards and accolades - which includes the Padmashri - that came his way during his lifetime.

Editor