



Closure of Large Pressure Ulcers utilizing the Principles of Limberg flap

Kumar P, Bhaskara KG

Department of Plastic Surgery, Kasturba Medical College, Manipal 576 119, Karnataka, India

Summary

A prospective study of 17 patients (21 Limberg flaps in 19 pressure ulcers) was done to establish the efficacy of Limberg flap. Limberg flaps were used in only those cases where primary closure was not possible. This flap was found to be simple to execute and short-term results were satisfactory. Also, it spares underlying muscles for future use. None of the flaps showed necrosis. Partial wound dehiscence was noticed in 7 (33.33%) cases, which was managed by secondary suturing in four cases, by split skin graft in one case and by second Limberg flap in one case.

Key words : Pressure ulcer, Limberg flap

Introduction

Pressure ulcers may acquire any size and shape. Designing of a flap may be a difficult task due to undermining. Skin graft for donor area of the flaps may have its own problems. Smaller pressure ulcers may be closed primarily¹. Larger pressure ulcers may be closed by using one or more Limberg type flap with advantage of primary closure of donor defect².

Material and Methods

This is a prospective study of 17 patients (7 paraplegic, 10 without any neurological deficit) with pressure ulcers at various sites admitted in Department of Plastic Surgery of Kasturba Medical College, Manipal (Table 1) from June 2000 to Aug 2001.

All pressure ulcers were classified into four stages as mentioned below:

Stage I. Partial thickness of skin (superficial) involvement (redness, abrasion, blistering)

Stage II. Soft tissue involvement (full thickness skin or deeper tissue). Stage II sub classified after excision of necrotic tissue on the basis of deeper tissue involvement

- IIA. Full thickness skin and subcutaneous tissue involvement without skin undermining (II A₁) or with skin undermining (II A₂) .
- IIB. Muscle, tendon and /or bursa involvement
- IIC. Exposed bone, joints and ligaments without osteomyelitis

Stage III. Osteomyelitis and septic arthritis

Stage IV. Pressure ulcer with septicemia

The pressure ulcer was excised with its fibrous wall and floor. Involved bone was excised as indicated. The undermined skin, if any, was not discarded and if needed was elevated as a flap. Modified Limberg flap was used to close the defect only when primary closure was not possible. The base

Table 1. Tabular presentation of case summaries

Case No	Age (Year)	Sex	Site, state and number of Pressure of ulcers	Neurological status	Method of closure
1	24	M	Thoracic Spine IIC	NP*	Limberg flap -single
2	68	M	Sacral IIB	NP*	Limberg flap -single
3	48	M	Sacral IIC and bilateral trochanteric IIC	Paraplegic and	Limberg flap - single for each sacral area right trochateric area. Left trochan-teric area primary closure
4	58	M	Sacral IIC and bilateral trochanteric IIC	Paraplegic	Two Limberg flap for sacral ulcer, Primary closure for ischaial pressure ulcer
5	79	F	Sacral IIC	NP*	Single Limberg flap
6	60	M	Sacral IIC and bilateral Trochanteric IIC	NP*	Two Limberg flaps for sacral ulcer, One Limberg flap for right trochanteric ulcer and Primary closure for left trochanteric ulcer
7	27	M	Sacral IIB	Paralegic	Limberg flap-single
8	47	F	Lumar IIC	NP*	Limberg flap-single
9	48	M	Sacral IIC	NP*	Limberg flap-single
10	32	F	Occipital IIC	NP*	Limberg flap-single
11	65	M	Sacral IIC	Paraplegic	Limberg flap-single after primary closure of part of the ulcer
12	37	M	Sacral IIC	Paraplegic	Limberg flap-single
13	40	M	Sacral IIB	Paraplegic	Limberg flap-two, one on either side (both inferiorly based)
14	44	M	Sacral IIB	NP*	Limberg flap-two, one on either side (one inferiorly and one superiorly based)
15	42	M	Sacral III, Bilateral trochanteric III and bilateral ischaial III	Paraplegic	Limberg flap-single for sacral ulcer, Primary closure for all other ulcers along with excision arthroplasty of left hipjoint, removal of part of both trochanters and both ischium
16	50	M	Sacral IIB	NP*	Limberg flap-single
17	45	M	Sacral IIB	NP*	Limberg flap-single

* NP = Non paraplegic

of the flap over undermined edges was avoided. The principles of pressure ulcer closure were strictly adhered¹. Elastoplast dressing was used to support the wound. Drains were not removed till significant amount of drained fluid was observed. Antibiotics were used till suture removal. Stitches

the laxity of the skin around the ulcer³. The other side of the flap was drawn at 60° angle and equal to the extension. All precautions were taken to avoid narrow base of the flap and excessive tension after closure (including appropriate changes in the angle) in case of irregular shape. To avoid

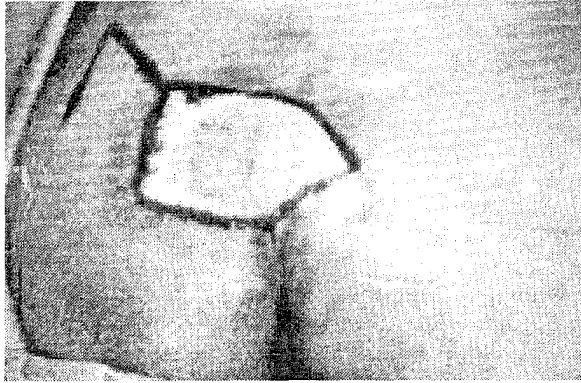


Fig 1a. Pre-operative photograph showing sacral pressure ulcer

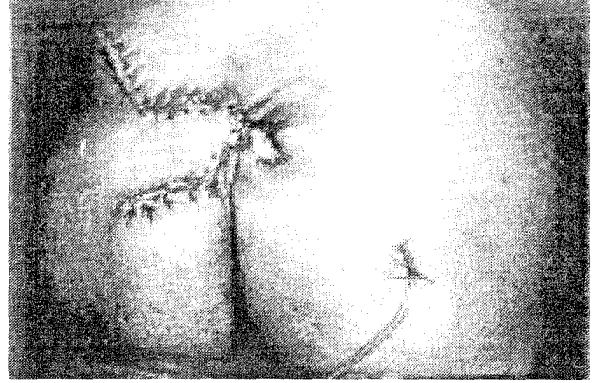


Fig 1b. Post-operative photograph of the same patient showing closure of pressure ulcer by single Limberg flap

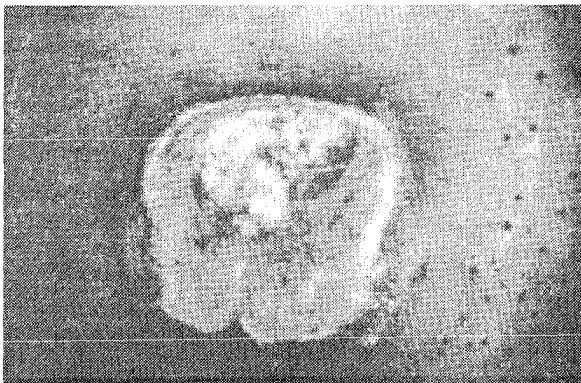


Fig 2a. Pre-operative photograph showing sacral pressure ulcer

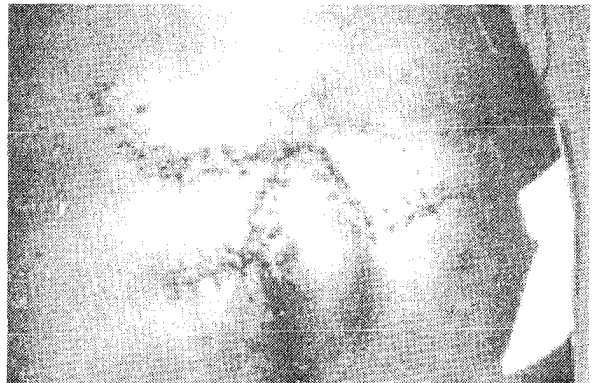


Fig 2b. Post-operative photograph of the same patient showing closure of the pressure ulcer by two Limberg flaps

were removed after 12 to 14 days (Fig 1-3). Patients were gradually, over a period of two weeks, allowed to bear weight over the flap. Post-operative conservative protocol to avoid recurrence was stressed.

Design of the flap

In none of the cases the pressure ulcer was converted to the rhomboid type of defect. The size of the flap was either smaller than the defect or equal to the defect (i.e. extension of the diameter up to 2/3 of its length or equal to the diameter in case of a round defect) depending upon

dehiscence due to excessive tension, when two or more flaps were required, flaps were based on either side and proximally or distally based as required. Proximally based flaps were difficult to close as compared to distally based flaps especially in non-paraplegic patient where muscle tone was normal and skin elasticity was more. Base of the flap lying over undermined area was avoided. A thin layer of shiny and slimy granulation tissue lining the undermined skin was excised before final closure. Closed suction drain(s) was placed in all the cases.

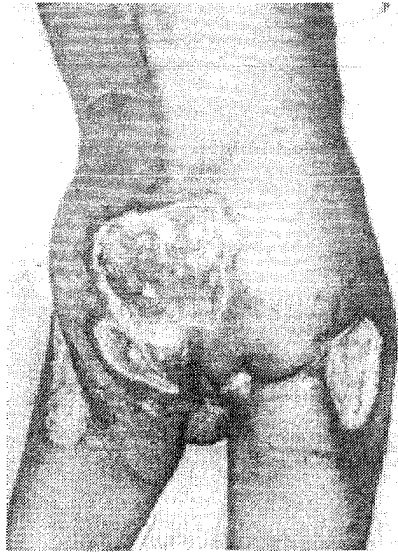


Fig 3a. Pre-operative photograph of the pressure ulcers in case no.15 (Table 1).

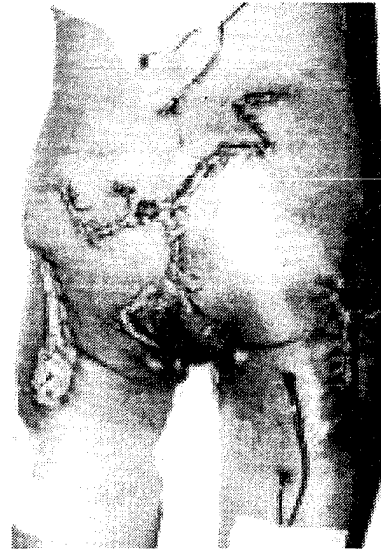


Fig 3b. Post-operative photograph of the same patient showing closure of sacral pressure ulcer by single Limberg flap with rotation flap in combination with Z plasty, and closure of other ulcers by primary closure.

Results

In the present study 21 Limberg flaps were used

Table 2. Complications

Case No	Complications	Management
4	Superficial dehiscence of 2cm suture line of Sacral Wound, Dehiscence of both ischial ulcers after 6 months follow up	Secondary suturing
6	Hematoma followed by dehiscence of Left trochanteric ulcer	Secondary suturing
8	Seroma	Drained through suture line by applying pressure over the flap
11	Partial wound dehiscence	Closed by second Limberg flap
14	Wound dehiscence at the donor area of Limberg flap	Split skin grafting
15	Wound dehiscence at the tip of Limberg flap	Hydrocoll dressing (Elder-Hartmann) followed by split skin graft
17	Blockade of drain leading to collection under the flap	Drained through the suture line by applying pressure over the flap

in 17 patients (19 ulcers). Six ulcers were in stage IIB, 12 in IIC and 1 in stage III. In two (9.52%) stage IIB sacral pressure ulcers double Limberg flaps (one from either side) were used. Remaining seven (33.33%) pressure ulcers in these 17 patients (Three in stage IIC and Four in stage III) were closed primarily. In one stage IIC sacral

ulcer (case 11), wound area was reduced by primary closure of part of the ulcer before final closure by Limberg flap. All the patients, where primary closure was done for pressure ulcers, were paraplegic except one (case 6).

In none of the cases under study flap necrosis

was seen. In one patient discharging sinus was noticed during first follow up after 1 month due to subcutaneous vicryl sutures.

Wound dehiscence and infection was noticed in five cases (Table 2) which was managed by secondary suturing except in two cases which were closed by split skin grafting. In two cases the dehiscence was due to collection.

The largest defect that was covered by this flap was 10x8cms.

Recurrence was not noticed in any of the case.

Discussion

Limberg flap has been used successfully to close small pressure ulcers⁴. In the present study Limberg flap single or double was used to close larger pressure ulcers (up to 10x8cms). In case of multiple ulcers in combination with primary closure, it effectively closes the wounds. Two cases where suction drain did not function properly, collection, infection and partial wound dehiscence was noticed. In two cases wound dehiscence was noticed at the donor area due to excessive tension. In both these cases the flaps were proximally based. In one case dehiscence was noticed both at the donor and recipient area. All these complications were managed either by secondary suturing (four), SSG (one) or by second Limberg flap (one). This flap is simple to execute, short-term results are comparable to any other muscle or musculocutaneous flap and spares underlying muscles for future use. In non-paraplegic patients the results of flap closure appears to be superior to primary closure. Closure is rela-

tively easily achieved by primary closure in paraplegic patients where normal muscle tone is absent and skin yields to tension easily. However study by different surgeons at different centers is desirable to explore more about the efficacy of this flap in pressure ulcers.

References

1. Kumar P, Bhaskara KG, Chittoria R. Primary closure of pressure ulcer revisited. Indian Journal of Plastic Surgery 2000; 33: 22-26
2. Quaba AA, Sommerland BC. "A square peg into a round hole": a modified rhomboid flap and its clinical application. Brit J Plast Surg 1987; 40:163-170.
3. Larrabee WF Jr, Trachy R, Suttan D, Cox K. Rhomboid flap Dynamics. Arch Otolaryngol 1981; 107: 755-757.
4. Hoehn JG, Elliott RA, Stayman JW. The use of Limberg flaps for repairing small decubitus ulcers. Plast Reconstr Surg 1977; 60:548-553.

Authors

Pramod Kumar MS, MCh, DNB, Prof. and Head
KG Bhaskara MS, MCh, DNB, Assist. Professor

Corresponding Author

Pramod Kumar MS, MCh, DNB
Professor & Head
Department of Plastic Surgery
Kasturba Medical College
Manipal 576 119, Karnataka, India

Tel : (+91) (0) (8252) 71201 Ext 22286 (O),
22135 (R)

Fax : (+91) (0) (8252) 70062

Email: pkumar12-vip@zetainfotech.com
pkumar86@hotmail.com