



Review Article

Intersex, Transsexuality and Gender Reassignment Surgery

Ahuja RB, Bhattacharya S

Department of Burns, Plastic, Maxillofacial and Microvascular Surgery, Lok Nayak Hospital and associated Maulana Azad Medical College, New Delhi - 110 002, India

The anatomic and mental ambiguity of sexual image of an individual has tremendous bearing on his status in the society. Both, intersex with structurally ambiguous genitalia and transsexual with mental & sexual disharmony can be addressed effectively by a concerted approach of a pediatrician, gynecologist, plastic surgeon, endocrinologist and a psychologist. Efforts made effectively can go a long way in improving function and appearance, and also enhance the dignity and self-confidence of these patients.

Intersex

'Intersexuality' is classically defined as the expression of male and female, physical and sexual characteristics, within the same individual, but for practical purpose any abnormality of sexual determination or differentiation is considered an intersex state. Intersex can be categorized into abnormalities of gonadal determination or abnormalities of genital differentiation.

Normal Sexual Differentiation^{1, 2}

Characterization of gonads and external genitalia starts after 6th week of gestation. Bi-potential gonads develop on the urogenital ridge, and lying nearby are the Wolffian and Mullerian ducts.

The genes necessary for development of bi-potential gonads are WT-1 & FT2-F1. At this juncture genital tubercle, urethral folds and labioscrotal swellings represent the external genitalia. Sexual chromosomal coding now governs the differentiation of bi-potential gonads into ovary or testes. The pivotal event in sexual differentiation is the presence or absence of testicular determination, which is encoded by SRY gene located on the short arm of y-chromosome. This testicular differentiation and function is important in subsequent development of male phenotype. Further differentiation of testicular cells into Sertoli cells and Leydig cells is responsible for later events in the cascade. The former produce Mullerian Inhibiting Substance (MIS)³ and the latter expresses Testosterone (T), together controlling all phases of male genital differentiation, except testicular descent.

On the other hand the ovaries develop by default in the absence of SRY-gene (Fig 1) and the presence of two x chromosomes. Feminization of the fetus with regards to both internal ducts and external genitalia appears to be an autonomous process. The structural development of the internal ducts and external genitalia is explained in Fig 2 and 3.

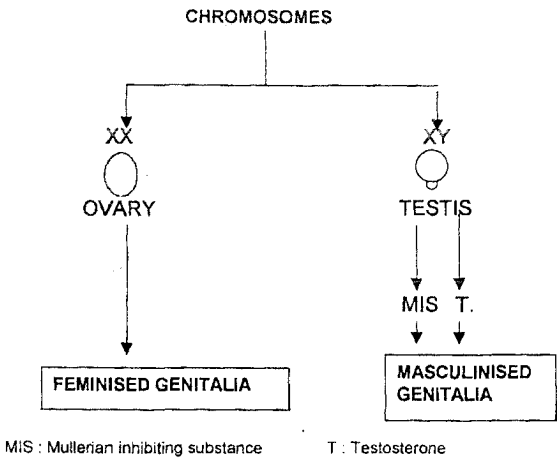


Fig 1. Chromosomal and hormonal inter- play in differentiation of external genitalia.

The mental image of gender and sex is determined mainly by the sex of rearing, but there is evidence of imprinting of brain by testosterone at the age of eighteen months. This aspect will be discussed in more detail in the section of transsexuality.

Causes of Intersexuality

This encompasses a wide array of disorders, which include (gene disorders, mutations and karyotypic errors) chromosomal anomalies, endocrinal disorders and target organ failure.

Chromosomal Anomalies

This can be in the form of inadequate genetic

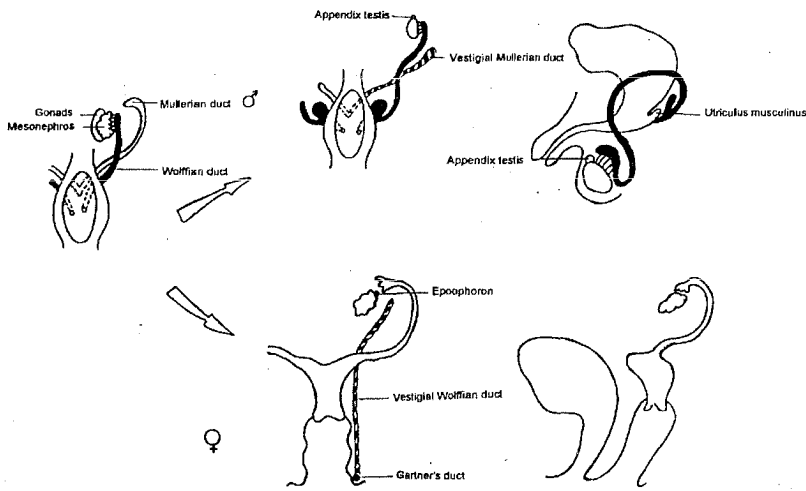


Fig 2. Fate of Wolffian and Mullerian ducts. Male: Wolffian duct forms epididymis, vas and seminal vesicle. Female: Mullerian duct forms the fallopian tubes, uterus and upper third of the vagina.

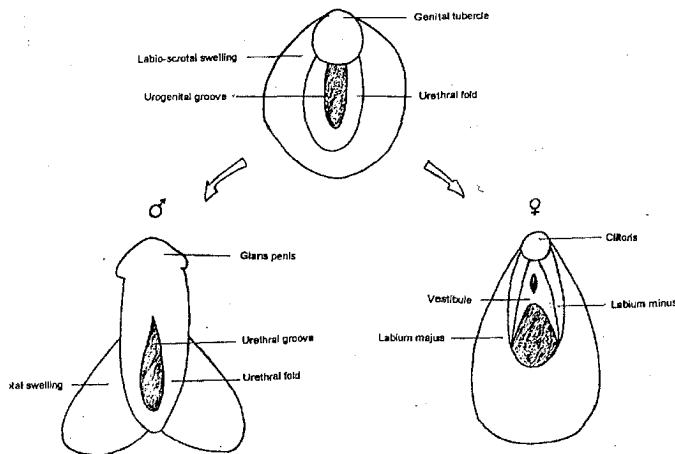


Fig 3. Differentiation of the external genitalia.

material e.g. 46xo (Turner's syndrome) or other categories – having chromosomal mosaics like 46xx or 46xy lines. They are explained by translocation of SRY gene to x-chromosome or to an autosome¹.

Endocrinal Disorders (Testosterone and Mullerian inhibiting substance dependent)

An abnormal endocrinal milieu affects the male profoundly as development of male external genitalia is testosterone dependent. Testicular dysgenesis is due to inadequate expression of both testosterone and Mullerian inhibiting substance, resulting in incomplete virilization of external genitalia, rudimentary Wolffian duct derivatives and persistence of Mullerian structures³. There exists another clinical entity where an isolated deficiency of MIS results in normal male internal and external genitalia but there is persistence of Mullerian structures. Congenital adrenal hyperplasia with block in cortisol synthesis pathway also results in depletion of testosterone and consequent feminization of external genitalia. On the other hand, development of female genitalia being an autonomous process, abnormal function of the ovaries does not give rise to ambiguous genitalia. However, a high concentration of androgens, either exogenous via placenta or endogenous as in congenital adrenal hyperplasia leads to masculinization of external genitalia. This event occurs at a stage after the Mullerian duct has developed and Wolffian structures have regressed¹.

Target Organ Failure (unresponsive external genitalia and wolffian duct)

This is in the form of testicular feminizing syndrome where a histologically and functionally normal testes is present, but the external genitalia and the Wolffian duct are unresponsive to testosterone. At the same time MIS regresses the Mullerian duct structures, leaving only external genitalia as ambiguous.

Classification

A. Classification based on gonadal histology¹ (Fig 4, 5, 6)

i) Female Pseudohermaphrodites

They are karyotypically 46xx with normal

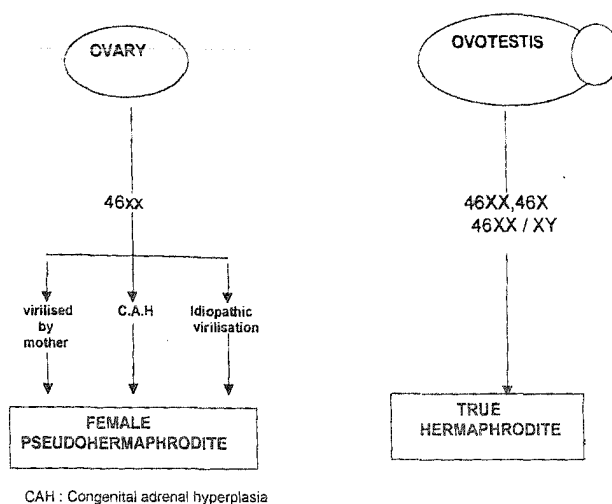


Fig 4. Flow charts indicating the development of female pseudohermaphrodite and true hermaphrodite.

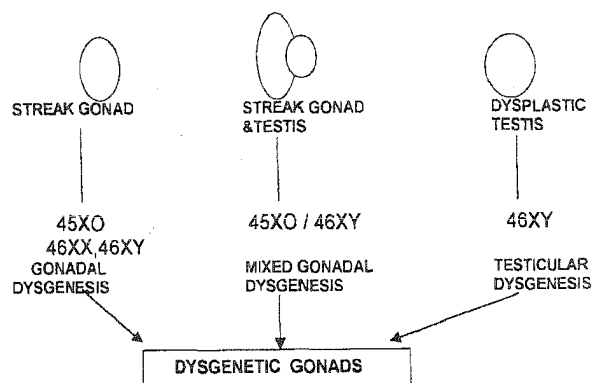


Fig 5. Flow charts indicating the development of dysgenetic gonads.

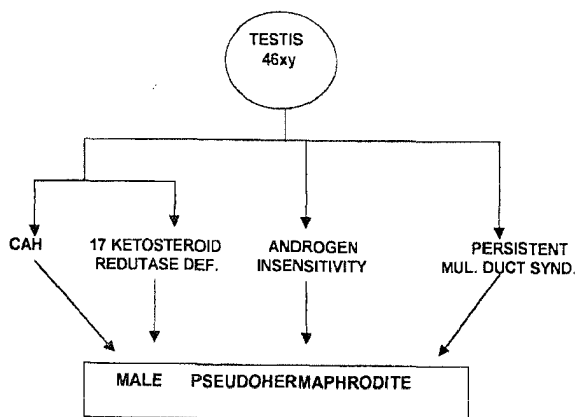


Fig 6. Flow charts indicating the development of male pseudohermaphrodite.

ovaries but their external genitalia are virilized by increased maternal androgen or by congenital adrenal hyperplasia to a varying extent. Therefore, these patients can present as phenotypically male or female depending on the extent of virilization.

ii) *Male Pseudohermaphrodites*

This group has two normal testes with karyotype of 46xy, but the external genitalia are not masculinized as a result of androgen insensitivity and congenital adrenal hyperplasia. These patients can also present as either phenotypically normal males or phenotypically normal females depending on the extent of feminization.

iii) *True Hermaphrodites*

In this condition both ovarian and testicular tissue are found in the same patient. The appearance of the genitalia is variable. The karyotype is generally a mosaic pattern of 46xx/46xy. These patients can present as phenotypically normal males or females, or with ambiguous genitalia.

iv) *Conditions with Dysgenetic Gonads*

This condition presents a spectrum of disorders ranging from partial to completely dysgenetic gonads with fibrous stroma. Both, external genitalia and the karyotype are variable. Most of these patients present with ambiguous genitalia.

B. Classification based on phenotypic characteristics

This is the simplest form of all classifications, and more relevant in overall management.

- i) Phenotypically normal male.
Usually present at onset of puberty.
xx Male – female pseudohermaphrodite
xy Male – male pseudohermaphrodite
xx/xy – true hermaphrodite
- ii) Phenotypically normal female.
Usually present at onset of puberty.
xy Female – male pseudohermaphrodite

xx Female – female pseudohermaphrodite
xx/xy – true hermaphrodite

- iii) Infant with ambiguous genitalia
Male pseudohermaphrodite
Female pseudohermaphrodite
Gonadal dysgenesis
True hermaphrodite

Congenital adrenal hyperplasia and mixed gonadal dysgenesis are the commonest conditions presenting with ambiguous genitalia.

● **Female Pseudohermaphroditism**

Congenital Adrenal Hyperplasia

Any defect in adrenal steroidogenesis that results in impaired production of cortisol leads to ACTH induced adrenal hyperplasia. There are specific enzymes in the pathway, which when absent produce either virilisation in female or under-virilisation in males. The enzymes whose absence produces virilization in females are 21-hydroxylase, 11 β-hydroxylase and 3 β-hydroxysteroid dehydrogenase (Fig 7). *21-hydroxylase enzyme deficiency*: 21-hydroxylase enzyme catalyzes the conversion of progesterone and 17α-hydroxyprogesterone to deoxy-corticosteroid and 11-deoxy-cortisol respectively⁴. Its deficiency results in over production of androgenic steroids and underproduction of cortisol and aldosterone. This is an autosomal recessive disorder resulting from mutation of CYP21 gene on chromosome 6. The patient presents with salt wasting and a simple virilizing condition. The genitalia are typically

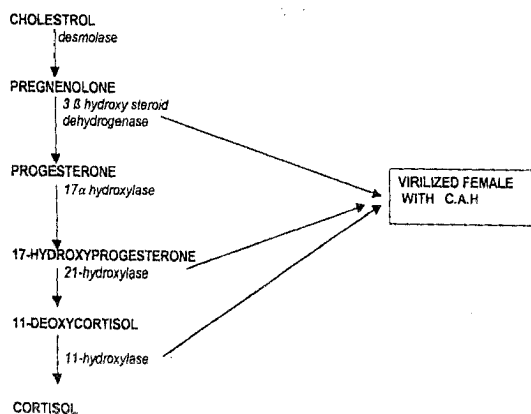


Fig 7. Enzyme deficiency in steroidogenesis pathway responsible for female pseudohermaphroditism.

ambiguous, but the degree of masculinization may range from mild clitoral hypertrophy with minimal labial fusion to complete phallic urethra and fused labia. Electrolyte imbalance is featured by hyponatremia and hypokalemia. Diagnosis is suspected by finding palpable gonads and Mullerian derivatives in a virilized female. The karyotype is 46xx with an increased level of serum 17 α hydroxyprogesterone. There is a possibility of these patients being fertile. Patient is given hydrocortisone to correct its deficiency and to inhibit ACTH overproduction. Gender assignment should always be 'female' because of potential for fertility. Feminizing genitoplasty with clitoroplasty and vaginoplasty are recommended. **11 β hydroxylase deficiency:** This enzyme catalyzes the conversion of 11-deoxycortisol to cortisol and deoxycortisol to corticosterone. The deficiency leads to increased androgen levels, and a decrease in minerelocorticoid and corticosteroid levels. This is a result of mutation of CYP11B gene at chromosome 8. This also results in the same picture of virilization and salt wasting. The increased levels of 11-deoxycortisol and deoxycortisol are characteristic. The treatment is same as the previous group. **3- β hydroxysteroid dehydrogenase deficiency:** This enzyme converts pregnenolone to progesterone steroid. Here also gender of rearing is to female with feminizing genitoplasty⁵.

Exogenous Virilization

Maternal medication in the form of progesterone in 1st trimester for recurrent abortion can cause mild virilization of external genitalia. The other causes are virilizing tumors and idiopathic virilization.

● Male Pseudohermaphroditism

In this group of patients there are normal testes but ambiguity of external genitalia is the result of either an insensitivity of the target tissues to testosterone or an error in the pathway of its biosynthesis.

Androgen Insensitivity Syndrome

This results from either a deficiency of enzyme 5 α reductase, a receptor block or post receptor

block (Fig 8). The normal level of testosterone fails to masculinize the external genitalia. Hence there is feminization of the genitalia and testes are undescended. These cases are reared as girls and present at puberty when male secondary sexual characters develop. These cases should continue with their female sex of rearing and testes are removed. Where the condition is detected at birth by presence of inguinal testes and the phallic size is reasonable, a trial of testosterone can decide if the child can be reared as a boy because there is an anticipation of growth surge at puberty.

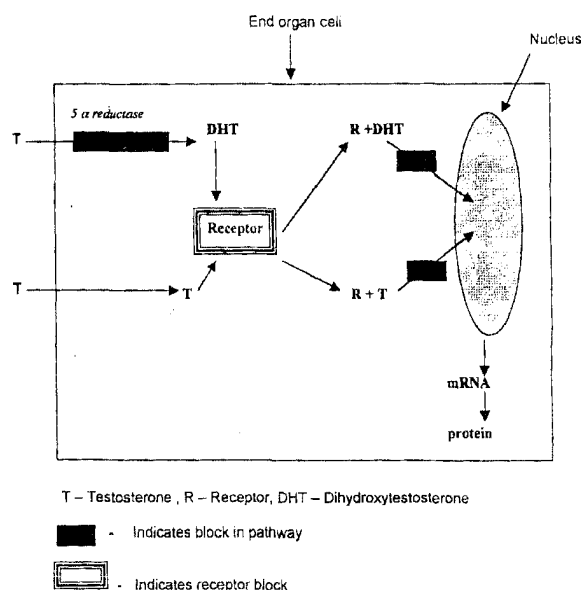


Fig 8. Levels of block in the pathway of testosterone action on the end organ cell leading to testicular feminization syndrome, resulting in a male pseudohermaphrodite.

Congenital Adrenal Hyperplasia

In boys the enzymes whose deficiency leads to feminization of external genitalia are 3 β -hydroxysteroid dehydrogenase, 17 hydroxylase and cholesterol desmolase. These cases present with external genitalia, which are reasonably masculinized but have a penoscrotal or perineal hypospadias, only with cholesterol desmolase deficiency the genitalia is feminized. In all these cases salt wasting is also present.

Testicular Failure

Ambiguity of external genitalia in males can be

present as a result of a selective defect within the testes itself. This can be of the following types: 17 Ketosteroid Reductase Deficiency: This enzyme converts androstenedione into testosterone in the testis. The patient presents with fully feminized genitalia with clitoral hypertrophy and a vagina. One or both gonads can be palpated in the inguinal region. At puberty, however, virilization occurs with normal secondary sexual characters. If not detected at birth, these babies are generally reared as girls and they should continue with the female sex along with hormonal support. But, if the condition is recognized early and there is a fairly well developed phallus, they can be raised as boys after a trial of exogenous testosterone. The growth catches up later with pubertal surge. Leydig Cell Hypoplasia: This results from a defect in the LH receptors on the Leydig cells. These patients have completely feminized external genitalia and are always reared as females. They present at puberty with primary amenorrhoea. The testes can be detected by ultrasound and histologically they have reduced Leydig cell mass. Persistent Mullerian Duct Syndrome: This condition results from, either a defect in the production or peripheral action of MIS. This condition is also called hernia uteri inguinalis because most commonly it presents with inguinal hernia and has fallopian tube or uterus as contents. Otherwise, these patients are normal phenotypic males.

● *True Hermaphroditism*

This is an autosomal recessive condition common in central and South Africa. It is only sporadically seen in rest of the world. The karyotype of the African type is 46XX with no mosaicism. In other cases mosaicism is the rule with karyotype 46XX/46XY and 47XXX/46XY lines. The most common form of gonads is bilateral ovotestes⁶. Functional ovulation may occur at puberty but spermatogenesis is rare. Correspondingly, endocrine function parallels the state of respective components. Although ovarian function continues in early adulthood, testosterone secretion declines with increasing age. Also, the internal duct anatomy parallels the nature of the ipsilateral gonads. The

most characteristic form of true hermaphrodite is that even in well-virilized cases, vagina is usually capacious and opens into the urethra below the pelvic floor. Diagnosis is confirmed by histological presence of both ovarian and testicular tissue. This intersex disorder offers the maximum freedom with regard to sex of rearing. Factors that favor male rearing are presence of a good-sized phallus and ample volume of testicular tissue; either in scrotum or that can be brought into it. Infants with predominantly ovarian gonads are raised as girls because the uterus and vagina are well developed and occasionally fertility has been recorded. Along with gender assigning procedure, the gonadal and ductal element, inappropriate to sex of rearing, is excised. There is 4% risk of malignancy in these deranged gonads⁷.

● *Gonadal Dysgenesis*

In this group of condition, the gonads show disordered development and fail to fully differentiate into either an ovary or testes. This clinical entity ranges from Turner's syndrome where both ovaries are represented by a streak of fibrous tissues to testicular dysgenesis in which the gonads are often recognizable as testis but are dysplastic. Mixed gonadal dysgenesis is in an intermediate position.

Turner's Syndrome

This condition is typically due to 45-xo karyotype. Patients characteristically present with a short stature, web neck, cubitus valgus and sexual infantilism resulting from streak ovaries. As a rule they do not have genital ambiguity and generally get diagnosed by primary amenorrhoea.

46xx Gonadal Dysgenesis

In this clinical state ovaries are represented as streak gonads in spite of the presence of xx chromosomes. These cases also have no genital ambiguity and they present with primary amenorrhoea, but they lack the characteristic habitus of Turner's syndrome.

46xy Gonadal Dysgenesis

This is also known as Sawyer's syndrome. Their

presentation is similar to 46xx dysgenesis but there is a high chance of malignancy in the dysgenetic gonads especially the development of gonadoblastoma.

Mixed Gonadal Dysgenesis

A testicle on one side and a streak gonad on the other side characterize this uncommon form of intersex. These cases have ambiguous genitalia. There is a phallus of variable size with epispadias and they also have labio-scrotal folds. Testis is inguinal in position and has a disordered histology. The contra lateral streak gonad is in place of the ovary. The patient karyotype is a mosaic pattern of 46xx / 45xo line. The internal duct structure parallels the gonad findings. There is a high likelihood of malignancy in both, the testes and the streak gonad. Considering this fact, most of the times these gonads are removed and the patients are reared as girls. Masculinizing genitoplasty is performed in exceptional cases where there is a good size phallus and a scrotal testis, and when this is contemplated the streak gonads are removed and patients can be reared as males.

Testicular Dysgenesis

These cases have bilateral testes but they are histologically dysgenetic, and functionally deficient in testosterone and MIS secretion. As a result, the external genitalia are feminized and the Mullerian duct structures are preserved. They present, either with female genitalia with mild clitoral hypertrophy, or an obvious male form with hypospadias and cryptorchidism. A uterus and fallopian tubes are present as a rule. The gonads have malignant potential and are always removed. The sex of rearing is governed by the appearance of external genitalia.

Patient Evaluation

An intersex disorder is one of the most distressing situations for the parents as it clouds the baby's basic identity. When the ambiguity of the genitalia is too severe, it is best to tell the parents to wait for further confirmatory tests. They should be reassured, and told that there are surgical and hormonal solutions to the problem, and it is best not

to speculate the likely outcome of the tests at this stage.

The evaluation begins with a careful history. As most of these disorders are recessively inherited familial disorders, an inquiry may reveal, siblings or other close relatives with abnormalities of genitalia, pubertal abnormalities and infertility. Also ask about the medications taken by the mother during pregnancy for threatened abortion or any previous casual use of hormonal contraceptives.

The physical appearance of the genitalia varies widely among patients with the same condition, and patients with different etiology may present with similar genitalia. Hence, it is not wise to attempt a definitive diagnosis by the appearance of the ambiguous genitalia. However, if gonads are palpable in a case of ambiguous genitalia it can be convincingly inferred that it is not female pseudo-hermaphroditism. In physical examination note the size of the phallus or clitoris, the position of urethral meatus, and the presence of urogenital sinus or vagina. Per rectal examination is done to detect the uterus. Pigmented patches on the skin indicate increased ACTH levels in congenital adrenal hyperplasia^{7,8}.

Investigations

Buccal Smear

In patients with an extra x-chromosome, the buccal smear will show a Barr body. Fluorescein staining may also identify a y-chromosome.

Karyotype

A venous blood sample is taken and karyotyping is done in leucocytes. To comment on a mosaic pattern a minimum of 40 leucocytes are examined.

Metabolic Studies

To diagnose congenital adrenal hyperplasia, levels of specific products of corticosteroid synthesis pathway are determined in serum and urine. Testosterone levels are important to rule out testicular feminization and other cases of testosterone insensitivity⁹.

Genitography

To determine the level of vagina or urogenital sinus and to confirm the presence of cervix.

Ultrasound

This is done to detect uterus and gonads, and also to assess their nature. Laproscopically a gonadal biopsy is taken for histological examination.

Management

After a definitive diagnosis is made, the sex of rearing is assigned. The chromosomal sex of the child has less importance in gender reassignment. Age, external and internal genitalia, potential for fertility, endocrine function, chances of malignancy and parental bias are more important considerations⁸.

Age of Presentation

The sex of rearing should be decided as early as possible to avoid psychological trauma to family and the child. Hence, the age at which patient presents is the single most important consideration. It is largely accepted that the sexual identity is firmly established by two and a half years, and any reassignment done after this age is bound to be complicated by profound psychological distress. Therefore, males with completely feminized genitalia are assigned female sex or else they get reared as females by parents and later present at puberty with primary amenorrhoea. These cases must continue with the female sex and they are provided female hormonal support. Only in exceptional cases, where the initial choice of sex of rearing by parents was grossly wrong, a reassignment can be contemplated after careful psychiatric evaluation⁸.

Fertility Potential

In all intersex disorders, except in cases of female pseudohermaphroditism, fertility is a rarity. As all female pseudohermaphrodites have fertility potential they should invariably be reared as girls, except where the phallus was well formed and the child was erroneously raised as a boy. In these cases continuation with male gender and excision of the gonads is advised.

Anatomic Considerations

★ Phallus

The size of the phallus and its potential for growth at puberty is the most common consideration for choosing male gender. In evaluating the exact volume of the phallus it is important to palpate the corporal bodies, as presence of chordee and an abundance of pre-pubic fat gives impression of a small size penis. An important test, before assigning male sex of rearing, is to assess the response of the phallus to exogenous testosterone. Recently, some patients and their advocates have challenged the standard use of penile size as the sole criteria for male gender assignment. An explanation forwarded for this is that virilization of brain takes place in early postnatal stage and it may not be supplanted by female sex of rearing^{8,9}.

★ Vagina

The presence of a capacious and low-lying vagina is advantageous in cases of female rearing. A small, high lying vagina presents more of a surgical challenge but can be corrected. This is especially important where fertility is expected^{8,9}.

Endocrine Function

The ease with which exogenous oestrogen or testosterone can be given, the ability of the gonads to produce these hormones is not a consideration in sex assignment. In cases of male pseudohermaphroditism, when there is a good phallic size and a scope for male hormone spurt at puberty, the patient is reared as a male with a hope of increase in phallus growth at adolescence. Endocrinal support is also important in true hermaphroditism. In these patients the estrogen levels never decline but testosterone secretion from ovotestis declines with age, necessitating exogenous administration of testosterone at puberty, if male gender has been assigned.

Malignant Potential

Malignant degeneration in any retained gonad must always be taken into account in sex assignment. These changes are common in streak go-

nads, dysgenetic testes and undescended testes. They should be removed as a rule.

Surgical Correction

1. Timing of Surgery

Infants who are raised as girls generally undergo clitoral reduction or recession and vulvovaginoplasty at the age of 3-6 months. The correction of severe virilization with high lying vagina is best carried out at 1-year age. In cases of boys undescended testes should be brought down at the time of gonadal biopsy. Correction of chordee and urethroplasty is generally carried out between 6-18 months¹⁰.

2. Types of Surgery

Feminizing Genitoplasty

★Clitoroplasty

Clitoral Recession: It is done for a mildly enlarged clitoris. The prepuceal skin is freed and a transverse incision is made proximal to the coronal sulcus. Through this incision the prepuce and shaft skin is elevated above Buck's fascia. Skin flap thus raised is cut in the midline to expose prepubic fascia. The suspensory ligament of clitoris is divided; corpora are gathered by non-absorbable sutures and hitched to the undersurface of symphysis pubis. A superficial wedge of tissue is excised from the dorsum of glans¹⁰. **Clitoral Reduction:** The exposure is done as explained above but a greater part of the corpora is excised after mobilizing and preserving the dorsal neurovascular bundles supporting the glans. Excising a dorsal wedge also reduces glans. Normal erotic sensation remains preserved. **Clitorectomy:** As a procedure for clitoral reduction it has been abandoned in favor of more anatomically conservative techniques described above. Recession of an intact clitoris is frequently complicated by persistent enlargement and painful erection. This complication is not seen with clitoral reduction.

★ Vaginoplasty

Creation of a functional vagina is required in two distinct groups of patients assigned female sex of rearing. 1. In patients with urethro-vaginal

confluence, as in a genetic female with congenital adrenal hyperplasia. 2. In those with vaginal absence or inadequacy i.e. in females with Mullerian dysgenesis or in genetic males with impaired testicular function. **Low Vaginoplasty:** When there is low confluence of the urethra and vagina in the urogenital sinus, as in a low andro-genital syndrome, the vagina can be exteriorized at the time of phallic reduction. When it is very superficial, it may be laid open by a simple cut back, and suturing of the vaginal mucosa to the perineal skin. In most cases, however, a posteriorly based U-flap will be necessary. A circumferential incision is made around the diminutive phallus at the coronal level sparing the urethral groove. A perineal flap is outlined and the two incisions are connected by a midline incision. The posterior flap is elevated. A cavity is dissected in the midline, immediately behind the urethra, to expose the vagina. The wall of the vagina is then widely incised to expose full width of the cavity. The tip of the skin flap sutured to the apex of the cavity while the remaining flap hangs down. Prepuceal and dorsal skin flaps are draped around the sides of the clitoris to create the labia minora. The labio-scrotal skin is extended into the angle formed by the perineal flap and the newly formed labia minora (labio-scrotal Y-V plasty) to reconstruct the labia majora. **Exposure In High Vagina:** While exposing a high vagina great care is taken to safeguard the external urethral sphincter, and the nerves and muscles of the pelvic floor. A perineal U-flap and an anterior flap are elevated as detailed above but a deeper dissection is done in the midline to reach the vagina. The vagina is then detached from the urethra and opened widely. The urethral defect is carefully closed transversely. Vaginal cavity is lined with the elevated perineal flap⁹. The Sometimes, mobilization of a very high vagina is done using the transvesical approach. Other options to line the neovagina are skin graft (Fig 9) and amnion. Amnion, however, only acts as a biological dressing. Vaginoplasty by using sigmoid colon is also possible. Of late, labial skin is being expanded and used along with the posterior U-flap to line the neovagina.

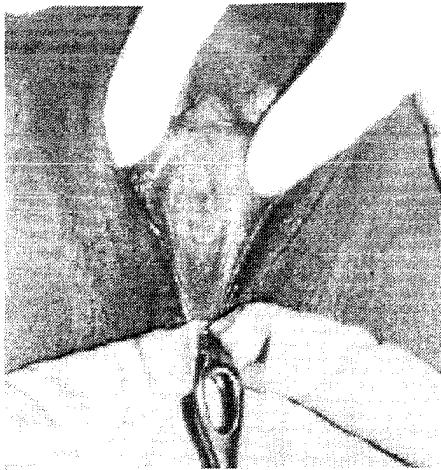

Fig 9 a. A 16 yr. old phenotypically normally female presented with vaginal agenesis. Investigation revealed normal ovaries but absence of Mullerian derivatives. A diagnosis of Mullerian agenesis was made. Feminizing genitoplasty (vaginoplasty) was planned.

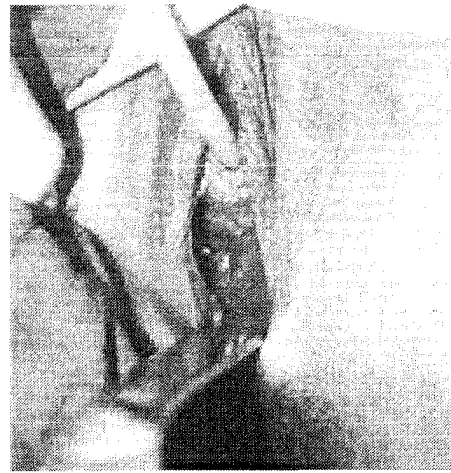

Fig 9 b. A cavity was dissected in front of the perineal body.

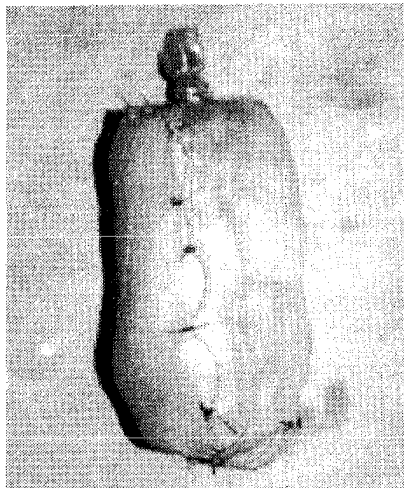


Fig 9 c. Showing a foam mould retained in shape by a condom and then lined by a skin graft. Mould is used to line the neovagina and maintain space. It is removed on 10th day.

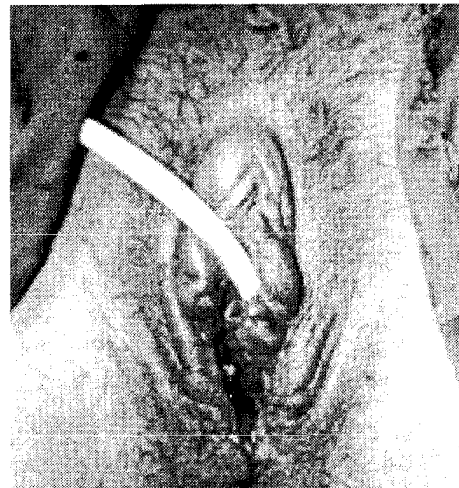


Fig 9 d. On 10th postoperative day at the time of mould removal, showing the introitus of neovagina.

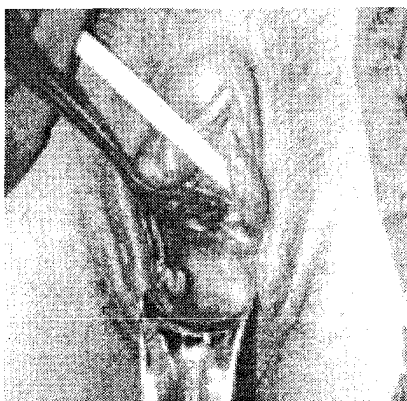


Fig 9 e. At 2 weeks, showing a healed and spacious neovagina.

Masculinizing Genitoplasty

All infants raised as boys will need chordee correction and repair of hypospadias. Additional procedures needed are orchiopexy, and removal of aberrant Mullerian duct structures and dysgenetic gonads.

In Indian context, where there is a delayed presentation of ambiguous genitalia, the infants are often reared as males because of social stigmata. In these patients, who generally present in teens, the sex of rearing assumes considerable impor-

tance and patients must be provided with functional male genitalia.

Transsexualism

Sex is what one sees and gender is what one feels (Harry Benjamin)¹¹. Incoherence between these elements leads to Gender Dysphoria Syndrome or Transsexual State. Caldwell coined the term transsexual, but it was the pioneer sexologist Harry Benjamin who popularized the term and delineated the clinical aspects.

To understand transsexual behavior, it is imperative to study the development of "true sex" of an individual. The criteria for determination of sex, in chronological order, are elaborated in table 1. Any abnormality in the first five factors leads to the development of intersex. The latter three factors correspond to gender identity problem. After the development of normal external and internal genitalia under the chromosomal and hormonal influence, sex dimorphic differentiation of the brain occurs. This sex dimorphic behavior is regulated by brain system and organized during the hormone sensitive prenatal and perinatal period. Later, sex of assignment and rearing imprints the psyche of the child and reinforces the gender behavior. Gender identity i.e. identification of the child with one sex or the other, establishes by the age of 2 ½ years, and it

develops by constant reinforcement from the environment. Further sexual orientation or erotic responsiveness to one sex or other takes place at puberty by hormonal pattern of the sex. Hence, it is obvious that the gender role and identity is laid down indelibly by 2 ½ years and any attempt to change it in later life is quite a futile exercise^{12,13}.

Etiology of gender dysphoria syndrome is presently unknown. Although some authors believe that an as yet unidentified organic cause is present. Others have considered it to be purely a behavior disorder. Another factor is weak reinforcement at the stage when gender identity is developing by ambiguous attitude of parents¹⁵. Hence, the origin of gender dysphoria could lie in:

1. Pre-natal influence of sex hormones of the developing fetal nervous system.
2. Postnatal social and psychological influences.

The diagnosis of transsexualism is made on the following guidelines provided by Harry Benjamin Dysphoria Association and the American Psychiatric Association¹¹.

1. A sense of discomfort and inappropriateness about one's sex.
2. A wish to be rid of one's genitalia and live in the opposite sex.

Table 1. Criteria for determination of sex

S.No.	Parameter	Time	Criteria
1.	Chromosomal sex	Moment of conception	xx or xy
2.	Gonads	45 days	HY antigen
3.	Internal genitalia	First 3 months	Testosterone+ MIS
4.	External genitalia	First 6 months	Tissue receptors & 5 DHT
5.	Sex hormone pattern	Fetal life till menarche	Pulsatile vs Non pulsatile LH & FSH
6.	Pattern of behavior center	Pre or perinatally	Sex dimorphic differentiation
7.	Sex of assignment & rearing	Imprinting by environment	Sex dimorphic differentiation
8.	Psychosexual differentiation	Life long	Gender identity

3. The disturbance has been continuous for two years and not limited to period of stress.
4. An absence of physical intersex or genetic abnormality.
5. No other mental disorder like schizophrenia.

Estimation of prevalence of transsexualism has been difficult. But of late, with openness of society and advent of Internet, along with availability of information on legal rights and so also therapy for these individuals, it is possible to make some estimates. Prevalence of transsexualism in USA is estimated to be 1:100,000 for male and 1:400,000 for female. In Sweden, it is 1: 37,000 among males and 1: 30,000 in females, and in Netherlands, it is 1: 80,000 males and 1: 54,000 in females¹⁴.

Differential Diagnosis

Individuals who demand gender altering surgery because of dissatisfaction with their sex are¹³:

1. Classic trans-sexual
2. Gender Dysphoria syndrome, former effeminate homosexuality
3. Gender dysphoria syndrome, former trans-vestitism
4. Gender dysphoria syndrome, psychosis
5. Gender dysphoria syndrome, psychoneurotic sociopathy
6. Gender dysphoria syndrome, inadequate and schizoid personality

The operation of gender reassignment is done only in classic transsexual patients and it is contraindicated in effeminate homosexuals, in transvestism etc. who can be treated by other medical means.

Management

The patient should be over 21 years of age and under 65 years to qualify for surgery. Besides other complications that can result from surgery, the patient should understand the following^{15, 16}

1. What cannot be achieved by surgery?

2. The operation is irreversible
3. Surgery never changes the biological sex of an individual
4. Surgery only provides a reasonable approximation of external genitalia to the opposite sex
5. Patient will not be able to procreate in the opposite sex
6. Male – female change allows sexual intercourse with some satisfaction but the same is not necessarily true for female to male change, because of problems of erection and difficulty in providing erogenous sensations to the neo-phallus

The consent form should specify the exact details and nature of operation. The patient should provide an affidavit to show the willingness for surgery and the subsequent name change that would be involved.

Rehabilitation of these cases should also consider economic, social and psychological needs of the patient, and surgery is just a part of it^{17, 18}. Candidates for gender reassignment surgery are chosen by the following criteria laid down by Harry Benjamin¹¹:

1. Persistent wish for at least two years to change the gender.
2. Psychiatric assessment for at least two years.
3. A demonstrable ability to live adequately in the chosen gender for at least a year.

Genital Surgery

It would take the form of conversion either towards male or female genitalia. The difference in transsexual and intersex group lies in the uniform availability of local tissues in the former group while the latter group has a variable presentation. Surgery should address besides genitalia other body image parameters like facial bones, breasts, pattern of body fat, hair distribution and prominence of Adam's apple^{13, 19}.

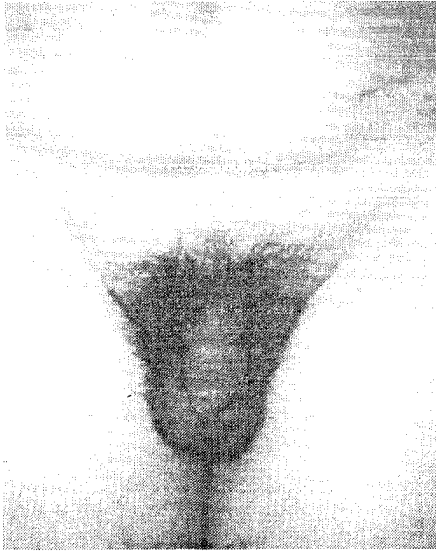

Fig 10 a. A phenotypically normal male presented with an intense desire for conversion of his body form that of a male. A thorough psychological evaluation confirmed the diagnosis of a transsexual. Female genitoplasty was planned for first stage.



Fig 10 b. A scrotal skin flap was raised and penile skin was degloved as a flap. Bilateral orchiectomy completed. A cavity, for neovagina, was dissected behind the urethra but anterior to the perineal body, and upto recto - vesical pouch.

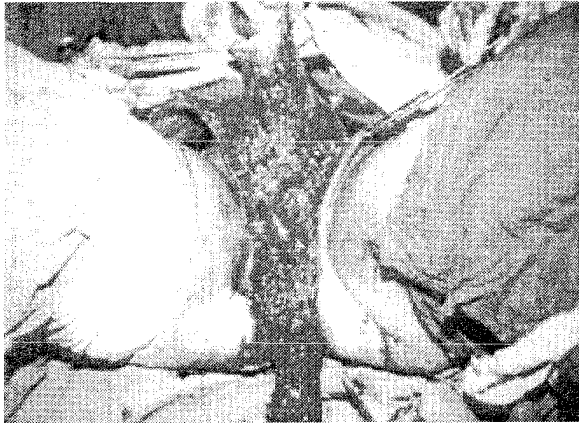


Fig 10 c. Penile crura were resected from pubic bone. Adequate length of corpus spongiosum was preserved. Neovaginal cavity can be seen without retraction. Not seen in the photograph - A skin tube formed by suturing together the penile and scrotal flaps was invaginated into this cavity to line it. The urethra was relocated at the base of the penile flap. Excess skin was refashioned around the urethra to form labia majora.

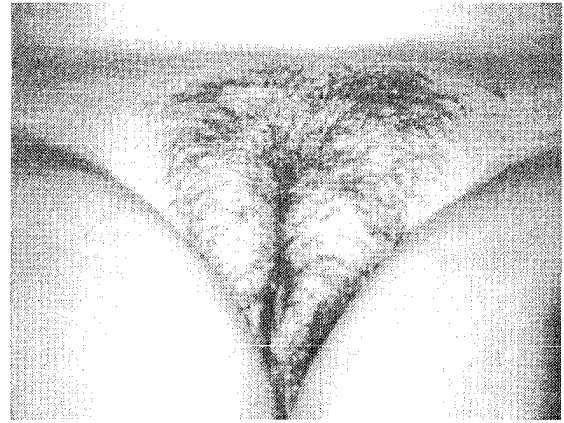


Fig 10 d. Late postoperative result at 1½ years showing the final appearance of external genitalia. The patient was put on flutamide and oestrogens postoperatively.

★ Feminizing Genitoplasty

The essential step is the creation of a vagina, and therefore, involves making of a cavity behind the bladder till the recto-vesical pouch, by a perineal dissection²⁰.

The lining of this cavity is the next step with nu-

merous options. In male transsexuals the lining is formed by inversion of penile and scrotal flaps²¹ (Fig 10). A bilateral orchiectomy and excision of both corpora cavernosa is carried out at pubic symphysis. Corpus spongiosum is transected at an appropriate level to form the neomeatus. The penile and scrotal flaps are stitched together as a tube and invaginated into the neovaginal cavity. The excess of the scrotal skin is aligned around the neovagina to form the labia majora²².

Patients with ambiguous genitalia selected for

feminizing genitoplasty may present with an inadequate vaginal cavity or vaginal agenesis. The existing vaginal cavity is marsupialized and the scrotal flaps are used to form the posterior and lateral vaginal walls and labia majora²³. The penile skin is used to cover the anterior vaginal wall and it can be bundled to simulate the labia minora. In cases of complete vaginal agenesis and in cases where previously used scrotal / penile flaps have undergone necrosis, there are a variety of other options applicable to line the neovaginal cavity. Split skin graft, described by Mc Indoe, works reasonably well with a seasoned operator, but can cause strictures requiring regular dilatation and it may cause donor site scarring²⁴. To overcome the need for regular dilatation and to prevent strictures, full thickness skin grafts have been described²⁵. These can be harvested from groin, infra-gluteal creases and skin following an abdominoplasty. They leave inconspicuous scars at donor sites. Mucosal grafts have also been described but are not preferred due to donor site constraints. Numerous other local flaps e.g. flaps from groin and pudendal thigh flaps, have been described to line the vaginal cavity with varying success rates²⁶.

An alternative forms of reconstruction interpositions a segment of intestine or recto-sigmoid to line the neovaginal cavity. These secrete mucus and are, therefore, self lubricating. As small intestine secretes excess mucus, colon segment interposition is preferred as lining. Recto-sigmoid transposition requires minimal mobilization, and therefore, preserves intact the neural supply to allow tactile stimulation. This procedure requires a laparotomy and intestinal anastomosis, which substantially increases morbidity. Recently, laparoscopic harvesting of the recto-sigmoid has been described to reduce abdominal scarring and morbidity²⁷.

As the results of vaginoplasty become better, attempts to improve cosmetic and functional attributes become necessary²⁸. At present, the glans penis substitution as a pedicled sensate neoclitoris in a position ventral to urethral orifice is being considered in primary gender reassignment

(Male to female) surgery^{29, 30, 31}. In patients with ambiguous genitalia the uncorrected chordee allows glans to simulate clitoris²⁹.

★ Masculinizing Genitoplasty

Creation of a neophallus falls into two broad surgical techniques. The first group is that of metaiodioplasty which utilizes the existing tissues to create a penis. This is achieved by transposing labia majora posteriorly and fusing them to create the scrotum¹⁹. Chordee is released and clitoris moved anteriorly to form glans and body of penis. The inner aspect of labia minora forms a pendulous urethra and cover for the ventral shaft of penis. Although, by this procedure an erotic sensibility is achieved, the size of the neophallus is not adequate because neophallus (clitoris) responds in a limited fashion to testosterone. Its ability of vaginal penetration is doubtful and also the patient cannot micturate from the tip of neophallus³².

The other group of surgical techniques involves importing tissues to form genitalia. Again, numerous techniques have been described, but radial artery forearm flap (Fig 11) has become the gold standard against which all other techniques are compared^{33, 34, 35}. This allows an adequately sized and sensate penis, with an ability to micturate from the tip in erect posture. The drawbacks are, a donor site defect, requirement for microvascular expertise and the need to insert a stiffener at a following stage. Erotic sensations are also not adequately restored by just using a radial forearm flap, and local genital tissue has to be incorporated at the base of the reconstructed penis³⁶. Besides this, a plethora of other flaps, both pedicled and free, have also been described for phallus reconstruction. Amongst the free flaps, a free osteocutaneous peroneal artery flap^{37, 38} and lateral arm free flap, are popular because both can be made sensate^{36, 39}. They, however, require prefabrication of the neourethra by preliminary stage of skin grafting. With a radial forearm flap the neourethra can be reconstructed at the same stage^{34, 35}. Flaps which incorporate bone e.g. free fibular flap have the ability to provide a stiffener

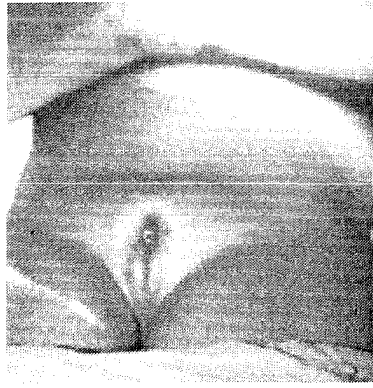

Fig 11 a. A 20 yr. old patient reared as male with absent testis, having partial fusion of labio-scrotal folds and micropenis. Gonads could not be palpated. There was minimal pubic and facial hair. Investigation revealed absent Barr body, no internal gonads or Mullerian derivatives. He was diagnosed as a male pseudohermaphrodite. Since the patient was reared as male, reassignment surgery was undertaken.

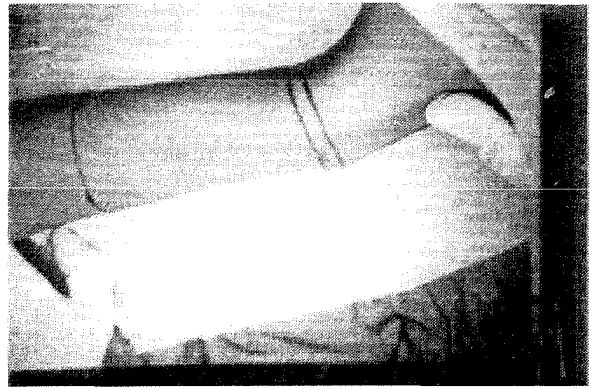


Fig 11 b. Stage 1. Penile reconstruction was planned with free radial artery forearm flap, by the tube in tube technique. The flap outlined one left forearm.

Ancillary Procedures

In such kind of surgery, complete sexual rehabilitation of the patient requires numerous other




Fig 11 c. Flap tubed to form the penis. Catheter in the inner tube forming the urethra. Radial artery and cephalic vein have been prepared for anastomosis.

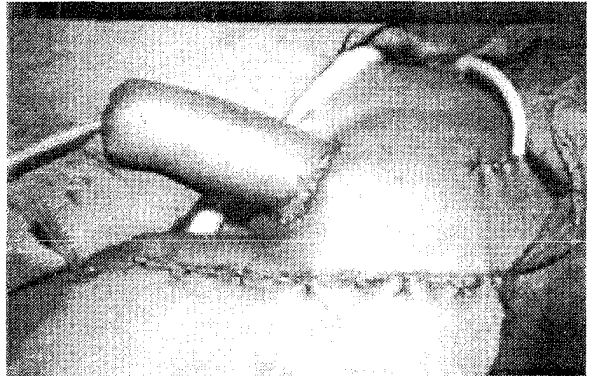


Fig 11 d. Flap inset in place. Radial artery anastomosed to right medial circumflex femoral artery, cephalic vein to external pudendal vein and lateral cutaneous nerve of the forearm to ilioinguinal nerve, to provide non erotic sensation

in the same stage but they have other problems of sensation and urethra formation^{37, 38}.

Before the advent of free flaps several local pedicled flaps have been used for phallus reconstruction^{40, 41}. They have been raised from abdomen or groin as bipediced flaps with a 'tube in tube' principle^{42, 43}. A combination of groin and abdominal flaps has also been used⁴⁴. Further refinements include improvement in aesthetic result by sculpting a glans and creating a coronal fold⁴⁵.

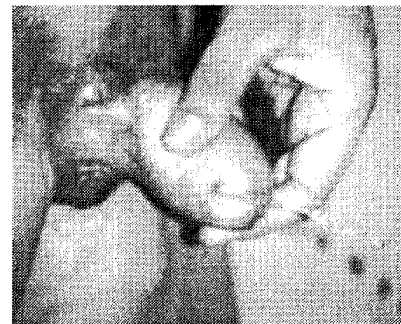


Fig 11 e. A fistula was closed at the base of the penis in the second stage. In third stage, silastic testicular implants were placed after making a pocket in the scrotum. Picture showing late post operative results at 2 years. Patient micturating from the tip of the penis and testicular implants in place.

procedures, especially in transsexual patients. These are designed to alter other physical attributes, allowing the patient to be accepted as a member of the opposite sex in the society.

Male to Female Conversion

The areas that need to be addressed here are the breasts, facial hair, and the facial bones including the nose. Most of the patients develop a breast mound on hormone therapy quite akin to gynaecomastia. Breast augmentation should, therefore, be postponed till two years after hormone therapy has been provided. Only those patients requesting augmentation for an inadequate size following this therapy are candidates for surgery. Broad based implants are required for augmentation as the male chest is wide^{13,16}.

Although female hormones reduce the amount and rate of hair growth, epilation by electrolysis or lasers is usually required to rid the patient of unwanted hair. Even after multiple sittings it is more realistic to promise some control of hair growth rather than a permanent cure.

Aesthetic change in the nose involves reduction of the dorsal hump to allow a more feminine appearance. Infact, this is the most commonly requested ancillary procedure. Other operation on the face are, a zygomatic onlay to enhance the cheeks, a genioplasty to convert a square masculine chin into a more pointed feminine form and a thyroid chondroplasty to reduce prominence of Adam's apple. In addition, patients may also require voice therapy to change their tone and mannerism^{16, 46,47}.

Female to Male Conversion

Similar areas need to be addressed here also, but in a reverse manner. Patients need a mastectomy. Some of them may already have scarred breasts due to recurrent ulceration from tight corsets worn to suppress the prominence. Androgen (testosterone esters) supplementation increases facial hair growth. Facial bones, specially the nose and the chin, may require augmentation to lend

more prominence. Body contours may be modified by suction assisted lipoplasty¹³.

Hormonal Therapy

In intersex, sex hormone supplementation for the sex of rearing is provided near puberty to allow normal development of secondary sexual characters. Thereafter, this is continued indefinitely for psychological and sexual well-being. Patients with congenital adrenal hyperplasia also require steroid supplementation⁴⁸.

Transsexual patients also require hormonal supplementation. This should ideally precede surgical reassignment. Hormonal therapy has a dual role⁴⁸.

1. Induction of feminization or virilization (as the case may be).
2. Suppression of hypothalamic – pituitary – gonadal axis to curtail the production and effect of endogenous hormones.

Choice of hormones and their dosage pattern varies from center to center. The commonest regimen employs testosterone esters in female to male conversion, and ethinylestradiol and cyproterone acetate in male to female conversion. Recently, some authors have preferred flutamide to control hirsutism and to effect other endocrinal changes in male to female conversion⁴⁹.

Administration of androgens can lead to following effects in a female body: increase in the size of clitoris, facial hair growth and weight gain. Side effects of androgen therapy include acne, an increased risk of coronary artery disease and an inability to maintain bone mass. Administration of estrogens in a male body leads to the following effects; breast enlargement, reduction in body hair and its growth, and an alteration in body fat distribution from android to more gynaecoid. There can also be substantial side effects with oestrogen therapy, like hyperprolactaemia; galactorrohea, thromboembolic phenomenon and a probable exposure to a carcinogenic agent. In view of these far reaching effects, a continu-

ous follow up and therapy adjustment is required. The goal is to stabilize the patient on a minimal dose of hormones to obtain an adequate effect with minimal side effects⁴⁸.

References

1. Aaronson IA. Sexual Differentiation and Intersexuality. In PP Kelans, LR King, AB Belman (eds.); Pediatric Urology (3rd ed); p 977-1014. Philadelphia: W.B. Saunders Co. 1992.
2. O'Rahilly R. The timing and sequence of events in the development of human reproductive system during the embryonic period proper. *Anat Embryol.* 1983; 166: 247-261,
3. Gustafson ML, Lee MN; Asmundson L. Mullerian Inhibiting substance in the diagnosis and management of intersex and gonadal abnormalities. *J Pediatr Surg* 1993; 28: 439-442.
4. Qazi QH, Thompson MW. Genital changes in congenital virilizing adrenal hyperplasia. *J Pediatr.* 1972; 80:653-658.
5. Rajendran R, Hariharan S. Profile of intersex children in South India. *Indian Pediatric* 1995; 32: 666-671.
6. Hadjiathanasiou CG, Brauner R. True Hermaphroditism: Genetic variants and clinical management. *J Pediatr.* 1994; 124:738-742.
7. Van Niekerk Wa. True Hermaphroditism: Clinical, Morphologic and Cytogenetic Aspects. Hagerstown: Harper and Row, 1974; 1-5.
8. Money J, Hamson J G, Hamson J L. Hermaphroditism: Recommendations concerning assignment of sex Change of sex and psychological management. *Bull Johns Hopkins Hosp.* 1955; 97: 284-300.
9. Diamond M, Sigmundsson HK. Management of intersexuality. Guidelines for dealing with persons with ambiguous genitalia. *Arch Pediatr Adolesc Med.* 1997; 151: 1046-1050.
10. Oesterling JE, Gearhart JP, Jeffs RD. A Unified approach to early reconstructive surgery of child with ambiguous genitalia. *J Urol* 1987; 138:1079-1080.
11. Benjamin H, Gutheil EA, Deutsch D, Sherwin RV. Transsexualism and transvestism – A symposium. *Am J Psychiatry* 1954; 8: 219-44.
12. Hines, M. Abnormal sexual development and psychosexual issues. *Baillieres Clin. Endocrinol Metab* 1998; 12: 173-89.
13. Laub DR, Laub DR Jr, Massadam JV. Gender Dysphoria Syndrome. In J.W. Smith, and S.J. Aston (eds) *Grabb & Smith's Plastic Surgery* (4th ed); p1393-1412. Boston: Little Brown & Co., 1991.
14. Eklund PLE, Gooren LJC, Bezemer PD. Prevalence of transsexualism in the Netherlands. *Br J Psychiatry.* 1988; 152:638-640.
15. Jones WJ. Assessment and support of sexual functioning in 458 men seeking genitourinary reconstructive surgery. *Clin Plast Surg* 1988; 15:455-462.
16. Laub DR, Fisk N. A rehabilitation programme for gender dysphoria syndrome by surgical sex change. *Plast Reconstr Surg* 1974; 58: 388-392.
17. Meyer J. Psychiatric considerations in the sexual reassignment of non-intersex individuals. *Clin Plast Surg* 1974; 1: 257-264.
18. Schlatterer K, VonWerder K, Stall SK. Multi-step treatment concept of transsexual patient. *Exp Clin Endocrinol Diab* 1996; 104: 413-419.
19. Laub DR. Invited comment to M Edgerton. The role of surgery in the treatment of Transsexualism. *Ann Plast Surg* 1984; 13:476-482.
20. Dalrymple JO. Male to Female gender reassignment. In *Rob & Smith's Operative Surgery* (4th ed). pp401-415, London: Butterworths 1980.
21. Small MP. Penile and scrotal inversion vaginoplasty for male to female transsexuals. *Urology* 1987; 29:593-597.
22. Edgerton MT, Bull J. Surgical construction of vagina and labia in male transsexuals. *Plast Reconstr Surg* 1970; 46:529-539.
23. Thompson IM. Result of vaginal flap urethroplasty in hermaphrodites. *J Urol* 1971; 105:456-460.
24. Stien M, Tiefer L, Melman A. Follow up observation of operated male-to-female transsexuals. *J Urol* 1990; 143:1188-1192.
25. Hage JJ, Karim RB. Abdominoplastic secondary full thickness skin graft vaginoplasty for male to female transsexuals. *Plast Reconstr Surg* 1998; 101:1512-1518.
26. Joseph VT. Pudendal thigh flap vaginoplasty in the reconstruction of genital anomalies. *J Pediatr Surg* 1997; 32: 62-5.
27. Maas SM, Fijsbouts QA, Hage JJ, Cuesta MA. Laparoscopic recto sigmoid colpopoiesis: Does it benefit our transsexual patients? *Plast Reconstr Surg* 1997; 103:518-24.
28. Patil U, Hixson FP. The role tissue expanders in vaginoplasty for congenital malformation of vagina. *Br J Urol* 1992; 70: 554-557.

29. Eldh J. Construction of neovagina with preservation of the glans penis as a clitoris in male transsexuals. *Plast Reconstr Surg* 1993; 91: 895-903.
30. Hage JJ, Karim RB. Sensate pedicled neoclitoroplasty for male transsexuals: Amsterdam experience in the first 60 patients. *Ann Plast Surg* 1996; 36: 621-624.
31. Van Noort DE; Nicolai JPA. Comparison tow methods of vagina construction in transsexuals. *Plast Reconstr Surg* 1993; 91:1308-1315.
32. Granato R. Surgical approach to male transsexuals. *Urology* 1974; 3:792-798.
33. Biemer E. Penile reconstruction by the radial arm flap. *Clin Plast Surg* 1988; 15:425-430.
34. Cheng KX, Hwang WY, Antoine EE et al. Analysis of 136 cases of reconstructed penis using various methods. *Plast Reconstr Surg* 1995; 95:1070-1079.
35. Semple JL, Boyd JB, Farrow GA The 'Cricket Bat' flap: A one-stage free forearm flap phalloplasty. *Plast Reconstr Surg* 1991; 88:514-519.
36. Gilbert DA, Williams MW; Horton CE. Phallic reinnervation via the pudendal nerve. *J Urol* 1988; 140:295-299.
37. Hage JJ, Winters HA, Van Lieshout J. Fibula free flap phalloplasty: Modifications and recommendations. *Microsurgery* 17: 1996; 358-65.
38. Sadove RC, Sengezer M, McRoberts JW. One stage total penile reconstruction with a free sensate osteocutaneous fibula flap. *Plast Reconstr Surg* 1993; 92:1314-1322.
39. Khouri RK, Young VL, Casoli VM. Long-term results of total penile reconstruction with a prefabricated lateral arm free flap. *J Urol* 1998; 160: 383-8.
40. Young VL, Khouri RK, Lee GW. Advances in total phalloplasty and urethroplasty with microvascular free flaps. *Clin Plast Surg* 1992; 19:927-938.
41. Orticochea M. New method of total reconstruction of the penis. *Br J Plast Surg* 1972; 25: 347-366.
42. Persky L, Resnic M, Desprez J. Penile reconstruction with gracilis pedicle grafts. *J Urol* 1983; 129:603-605.
43. Perovic S. Phalloplasty in children and adolescents using extended pedicle island groin flap. *J Urol* 1995; 154, 848-53.
44. Puckett CL, Montie JE. Construction male genitalia in transsexual, using tubed groin flap for the penis and a hydraulic inflation device. *Plast Reconstr Surg* 1978; 61:523-530.
45. Fang RH, Kao YS, Ma S, Lin JT. Glans sculpting in phalloplasty - Experiences in female-to-male transsexuals. *Br J Plast Surg* 1998; 51:376-9.
46. Becking AG, Tuinzing DR, Hage JJ, Gooren IJ. Facial corrections in male to female transsexuals: A preliminary report on 16 patients. *J Oral Maxillofac Surg* 1996; 54:413-8, discussion p419.
47. Hage JJ, Vossen M, Becking AG. Rhinoplasty as part of gender-confirming surgery in male transsexuals: Basic considerations and clinical experience. *Ann Plast Surg* 1997; 39: 266-71
48. Futterweit W. Endocrine therapy of transsexualism and potential complications of long-term treatment. *Arch Sex Behav* 1998; 27:209-26.
49. Moghetti P, Castello R, Negri C et al. Flutamide in the treatment of hirsutism: long term clinical effects, endocrine changes, and androgen receptor behavior. *Fertil Steril* 1995; 64:511-520.

Authors

Rajeev B. Ahuja, MS, MCh, DNB, FICS, FACS.
Sameek Bhattacharya, MS, DNB

Corresponding Author

Rajeev B. Ahuja, MS, MCh, DNB, FICS, FACS.
 Head of the Department
 Department of Burns, Plastic, Maxillofacial and
 Microvascular Surgery,
 Lok Nayak Hospital and associated Maulana Azad
 Medical College,
 New Delhi - 110 002, India
 Email: rbahuja@vsnl.com