

## Original Article

# One stage repair in Hypospadias by prepucial island flap technique

**Bharat Bhushan Dogra**

Department of Reconstructive Surgery, Command Hospital (WC) Chandimandir.

**Address for correspondence:** Col. B. B. Dogra, Senior Advisor, Surgery & Reconstructive Surgery, Command Hospital (SC), Pune-411040. E-mail: bharatdogra@satyam.net.in

### ABSTRACT

Surgical repair of hypospadias has taxed the skills of surgeons the world over. One stage repair is preferable as it decreases operative trauma, allows use of virgin unscarred skin, decreases number of hospitalisations and hence is economical.

During last 4 years the author has managed 60 cases of hypospadias and their complications in a tertiary care service hospital.

The author has randomly used onlay prepucial flap technique and tubularisation of prepucial flap in roughly equal number of cases of hypospadias to assess the advantages and limitations of these techniques in service clientele and their dependents.

### KEY WORDS

Hypospadias, Single stage, Prepucial flap.

### INTRODUCTION

Surgical repair of hypospadias has remained one of the most taxing problems for reconstructive surgeons, urologists and paediatric surgeons alike, because of high complication rate. The very fact that there are about 250 different operations to manage this tricky problem itself is a testimony that no single operation is favoured by all surgeons the world over because no single technique provides uniformly good results. One stage repair is naturally favoured as it decreases operative trauma, decreases number of hospitalisations and thus in turn is economical. This is a retrospective study of consecutive 60 cases managed by a single operating surgeon, aimed at assessing the advantages and limitations of one stage repair in service clientele.

### MATERIAL AND METHODS

During last 4 years, the author has managed 60 cases of hypospadias and related complications. Out of these, 50 cases comprised of different types of hypospadias with varying degrees of chordee (Figure 1). The remaining 10 cases were of urethral fistulae. 3 patients out of these 10 cases of urethral fistulae had undergone earlier repair for hypospadias elsewhere and 7 cases were follow-up cases from the present series.

Chordee correction was required in 48 cases and it was achieved by the standard technique of circumcoronal incision extending proximally to external urethral meatus and then going around it. The Urethral plate could be preserved in 20 cases (Figure 2).

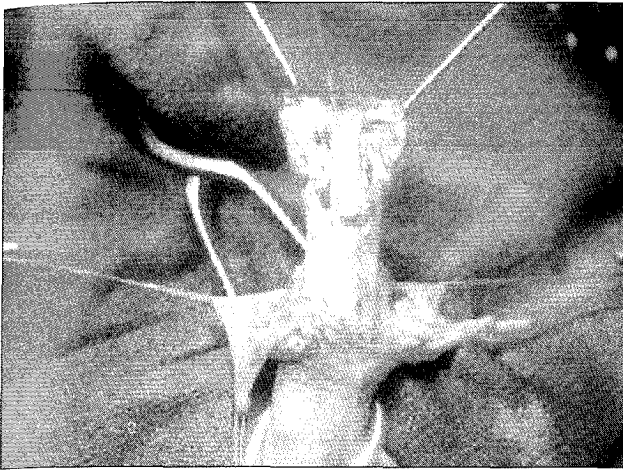


Figure 1: Preserved urethral plate after release of chordee

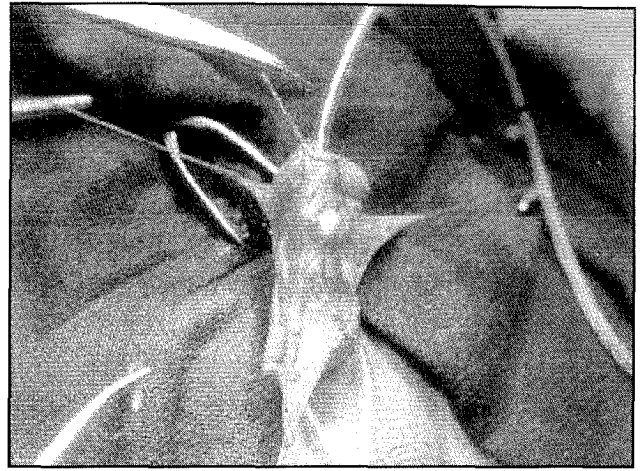


Figure 2: Case of Distal hypospadias with chordee

A prepucial island flap was tubed to reconstruct neo urethra in 26 cases, and was used as onlay flap in another 20 cases (Figure 3). 4 cases could be managed by meatal advancement and glanuloplasty only.

For cases having urethral fistulae, the Cecil-Culp technique of repair was suitable in 5 cases and buccal mucosa was used as an onlay graft to close the fistula in 2 cases.

Urinary diversion was carried out in all the cases, using 8F-feeding tube in distal hypospadias and suprapubic cystostomy in penoscrotal and penile hypospadias.

Dressing was changed on 10<sup>th</sup> postoperative day and second stage correction where required was carried out after a gap of one year.

## TECHNIQUE

All patients requiring urethroplasty were operated by circumcoronal incision extending proximally by two vertical incisions 6-8 mm apart along the urethral plate up to the external urethral meatus and then going around the ectopic urethral meatus.

The urethral plate was preserved in most of the cases. Chordee correction was obtained by excising the fibrous bands on either side of the urethral plate. Chordee correction was checked as a routine in all the cases by artificial erection.

For urethral tube reconstruction inner prepucial layer was used as a flap based on the leash of vessels running dorsally in its mesentery. Width of this flap was kept

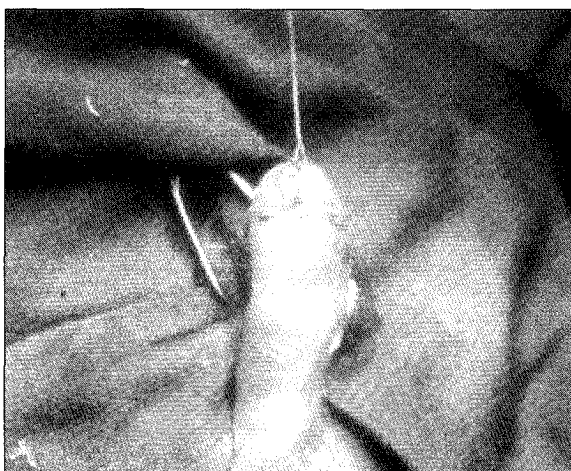


Figure 3: Prepucial onlay flap used to reconstruct distal urethra

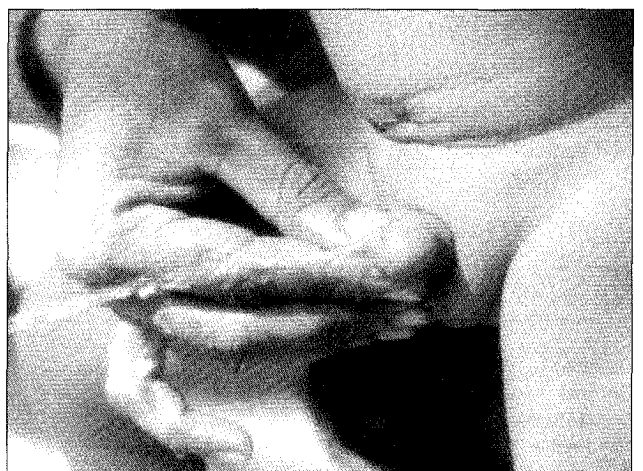


Figure 4: Post-operative results

around 10-15 mm and length was determined as per the length of tube required from ectopic urethral meatus to the tip of glans. The flap along with its mesentery was sufficiently mobilized to bring it to the ectopic meatus and sutured to the edge of the urethral plate using continuous 6-0 Vicryl. Keeping a silicon tube as a urethral stent, the other edge of the flap was then sutured to the opposite edge of the urethral plate to fashion a neourethra. The prepuccial mesentery was then used to cover the suture line by stitching it across the neourethra.

Cases where the urethral plate could not be saved were managed by tubing the 15 mm wide inner prepuccial flap over a silicon tube of 8F size using continuous running 6-0 Vicryl suture. Glanuloplasty was carried out in all the cases and cover was provided using lateral penile flaps.

Dressing was carried out using sofratulle over suture line and then wrapping the penis by polyurethane sponge.

## RESULTS

This study pertains to 60 consecutive cases managed by the author during last 4 years. The results are as depicted in Tables 1-4.

Patient's age ranged from 18 months to 10 yrs. 73% of the cases were below 5 yrs of age at the time of their surgery.

The external urethral meatus was located at the coronal or distal penile region in 44% of cases and in 22% of

**Table 1: Age at repair**

Age Group	Number	Percentage
0-2 yrs	08	13%
2-5 yrs	36	60%
5-10 yrs	14	24%
Above 10 yrs	02	3%

**Table 2: Type of Hypospadias**

Type	Number	Percentage
Glanular	04	7%
Coronal	09	15%
Distal-Penile	13	22%
Mid-Penile	13	22%
Penoscrotal	20	32%
Chordee without Hypospadias	1	2%

cases it was located at mid penile region. 32% of the cases had external urethral meatus at the peno-scrotal region (Table 1).

In the present study, chordee correction was carried out by excising the fibrous bands around urethral plate while preserving the urethral plate in as many as 20 cases, but in another 28 cases urethral plate had to be sacrificed to achieve full release of chordee. Dorsal plication of tunica was required in only 02 cases (Table 2).

Tubularisation of prepuccial layer around 8F feeding tube was carried out in 26 cases and the tube was sutured to the external urethral meatus. However in another 20 cases inner prepuccial layer was used as an onlay flap over preserved urethral plate to reconstruct the neo-urethra. 04 cases required meatal advancement and glanuloplasty for their correction (Table 3).

Out of 10 cases of urethral fistulae, 3 cases had undergone initial surgery elsewhere and 7 cases were follow up cases from present series. 3 cases had 1 fistula and 7 cases had more than one fistula.

Cecil culp technique of repair was the preferred method

**Table 3: Type of operative procedures**

Type of Hypospadias	Operative procedure	No. of cases
Glanular	MAGPI	04
Coronal	Prepuccial flap tubularisation technique	05
Distal Penile	Prepuccial flap tubularisation technique	06
	Prepuccial onlay flap technique	05
Mid penile	Prepuccial flap tubularisation technique	05
	Prepuccial onlay flap technique	05
Penoscrotal	Prepuccial flap tubularisation technique	10
	Prepuccial onlay flap technique	10
Urethral fistulae(2-3)	Cecil culp technique	05
Urethral fistula (single)	Inturned flap+Byers flap	03
Urethral fistulae +scarred skin	Buccal mucosal graft technique	02

**Table 4: Complications**

Flap necrosis	03	Tubularisation Tech (02); Prepuccial onlay flap (01)
Urethrocutaneous fistula	07	Tubularisation Tech (06); Prepuccial onlay flap (01)
Retrusion of meatus	03	MAGPI (02); Prepuccial onlay flap (01)
Oedema	12	Tubularisation Tech (06); Prepuccial onlay flap (06)
Stenosis	04	Tubularisation Tech -03 Prepuccial onlay flap (01)

in cases where fistula was present over proximal penile region. Free buccal mucosal graft was used in two cases where penile skin was scarred and patient had multiple fistulae. Here we used buccal mucosa to reconstruct the urethral tube by freshening the edges and suturing the graft to the edge of fistulous opening with gratifying results.

## DISCUSSION

Surgical repair of hypospadias has taxed the skill of surgeons the world over and no surgical operation provides uniformly good results.

There are reports recently suggesting an increase in incidence of hypospadias possibly related to environmental oestrogen like compounds. A study carried out in Finland has revealed an increase of prevalence by approximately three times.<sup>1</sup>

One stage repair for hypospadias was introduced in 1955, using full thickness skin grafts from prepuce. The advantage of correcting the chordee and reconstruction of neo urethra in a single operative sitting and the associated low morbidity are responsible for the popularity of one stage repair. But certain surgeons remain unhappy with limitations and drawbacks of one stage repair and continue to practice two stage repairs.

In the present study, external urethral meatus was located at coronal or distal penile region in 44% of cases and In22% of cases meatus was located at mid penile location. 32% of the cases had external urethral meatus at peno-scrotal region. This compares favourably with the similar results in studies by Welch in1979.<sup>2</sup>

Snodgrass et al carried out sub epithelial biopsies of urethral plate in 17 patients and found no histological evidence of fibrous bands,<sup>3</sup> concluding thereby that there is no requirement of violating the integrity of urethral plate. In our study we could preserve urethral plate in 20 cases, but in another 26 cases urethral plate had to be violated to obtain complete release of chordee.

We employed different techniques for reconstructing the neo-urethra on a random basis as regards the

severity of hypospadias. Tubularisation of prepuccial layer around 8F feeding tube was carried out in 26 cases and the tube sutured to ext urethral meatus.<sup>4</sup> However in another 20 cases inner prepuccial layer was used as an on-lay flap over the preserved urethral plate to reconstruct the neo-urethra. 4 cases required meatal advancement and glanulo plasty only for their correction.

In our series we have found a very low complication rate in cases where prepuccial flap was used as onlay flap. Urethrocutaneous fistula occurred in 1 case where prepuccial onlay flap was sutured to the preserved urethral plate, whereas, urethral fistula developed in 6 cases managed by tubularisation of prepuccial flap. Penile oedema as a post operative complication was encountered in equal number of cases irrespective of the technique employed (Table 4). Barroso and Jednak et al have reported excellent results with one stage double onlay prepuccial flap for severe hypospadias.<sup>5</sup> He has reported complication rate of 25% in his series of 47 cases and we have encountered a complication rate of 18% in our cases managed by onlay prepuccial flap technique. A urethrocutaneous fistula developed post operatively in 12% of cases. However Baskin and Duckett reported this complication in only 6% of their cases post operatively.<sup>5-7</sup>

## CONCLUSION

We conclude that hypospadias repair should be carried out around the age of 2 years before the child goes to school. Chordee correction where indicated can be effectively and adequately carried out by excising the fibrous bands around urethral plate without sacrificing the urethral plate and this healthy tissue should be used as dorsal layer to reconstruct neourethra by suturing onlay prepuccial flap to the urethral plate. The complication rate was lower in this series where prepuccial flap was used as onlay flap to reconstruct neourethra. This technique gives pleasing cosmetic effect to the repaired area.

## REFERENCES

1. Aho M, Koivisto AM, Tammela TL, Auvinen A. Is the incidence of hypospadias increasing. Analysis of Finnish hospital discharge

- data 1970-1994. *Environ Health Perspect* 2000;108:463-5
2. Welch KJ. Hypospadias. *Paediatric Surgery*, 3rd edn. Chicago: Year Book Medical Publishers; 1979. pp. 1353-76.
  3. Snodgrass W, Patterson K, Plaire JC, Grady R, Mitchell ME. Histology of the urethral plate: implications for hypospadias repair. *J Urol* 2000;164:988-99.
  4. Asopa HS, Elhence EP, Atria SP, et al. One stage correction of penile hypospadias using a foreskin tube a preliminary report, *Int Surg* 1971;55:435.
  5. Barroso UJR, Jednak R, Spencer Barthold J, Gonzalez R. Further experience with the double onlay flap for hypospadias repair. *J Urol* 2000;164:998-1001.
  6. Duckett JW. Transverse prepuceal island flap technique for repair of severe hypospadias. *Urol Clin North Am* 1980;7:723.
  7. Duckett JW, Coplen D, Ewalt D, Baskin LS. Buccal mucosal urethral replacement. *J Urol* 1995;153:1660-3.