

**CME****Ipsilateral fasciocutaneous flaps for leg and foot defects****Visweswar Bhattacharya, Rajesh Kumar Watts**

Department of Plastic Surgery, Institute of Medical Sciences, Banaras Hindu University, Varanasi-221005, India.

**Address for correspondence:** Prof. V. Bhattacharya, B-33/14-16, Gandhi Nagar, Naria, Varanasi-221005, U.P., India.  
Email: visweswar1@rediffmail.com**ABSTRACT**

It was a revolutionary enhancement for lower limb reconstruction when fasciocutaneous flaps were first described and used in clinical practice in 1981. Subsequently persistent studies were made to emphasize and confirm the rich vascular network associated with deep fascia. Thereafter studies were directed to identify the various types of perforators supplying the deep fascia and the overlying subcutaneous tissue and skin. Accordingly the scientists classified these flaps keeping in mind their clinical applications. The authors of this article have also performed extensive research on various aspects. This has led to better understanding about the finer details of vascularity. Based on this various modifications have been made for safe application of reconstruction for defects extending from knee to sole. To avoid complications the clinician should be able to select the proper procedure as regards the donor site and the possible preoperative and postoperative technical faults. A well-designed and meticulously executed flap usually has smooth recovery. Both Colour Doppler and Audio Doppler are useful tools in planning a safe flap. Now these flaps have proved to be standard technique without requiring a special set up extensive training.

**KEY WORDS**

Fasciocutaneous flaps, Antegrade flaps, Retrograde flaps, Defects of leg and foot, Doppler studies, Perforator based flaps.

**INTRODUCTION**

From the initial suspicion about their clinical utility to a standard technique in the armamentarium of a reconstructive surgeon, fasciocutaneous flaps have come a long way. Constituent-wise, fasciocutaneous flaps are those, which include skin, subcutaneous tissue and the deep fascia. The majority of moderate size defects extending from knee to sole can be reconstructed by these procedures. Depending upon the location of the defect, the planning and manoeuvring vary. However the basic

principles of blood supply remain the same.

**Vascular basis<sup>1</sup>**

The word "Flappe" means anything that hung broad and loose, fastened only by the side. In contrast to earlier beliefs, fasciocutaneous flaps have a definite vascular system, a suprafascial plexus and a subfascial plexus anastomosing with the subcutaneous and subdermal plexi. Direct cutaneous, musculocutaneous and septocutaneous perforators contribute to these plexi (Figure 1). Based on this various classifications have been described.

**Cormack and Lamberty Classification<sup>2,3</sup>**

**Type A-** multiple perforators entering at base of flap and extend throughout its longitudinal length, e.g. "super-flap" in the lower leg (Ponten).<sup>4</sup>

**Type B-** single fasciocutaneous perforator, e.g. medial arm flap, parascapular flap etc.

**Modified type B-** where main vessel is taken with the perforator as a "T" junction, e.g. a flap based on inferior cubital artery but taking in addition the radial artery.

**Type C-** it is based on multiple small perforators that run along a fascial septum. The supplying artery is included with the flap, e.g. radial forearm flap.

**Type D-** osteo-myo-fasciocutaneous flap. It is similar to Type C but includes a portion of adjacent muscle and bone, e.g. Chinese forearm flap with half diameter of radius. This is there in the original classification of Cormack and Lamberty and is now considered as a part of Type C.

**Cormack and Lamberty also introduced a new classification**

Type A- has a fascial plexus

Type B- has a single perforator

Type C- has multiple perforators and a segmental source artery

**Mathes and Nahai's Classification<sup>2,3</sup>**

Type A- with a direct cutaneous pedicle to the fascia

Type B- with a septocutaneous perforator

Type C- with perforators from a musculocutaneous source

**VARIANTS OF FASCIOCUTANEOUS FLAPS**

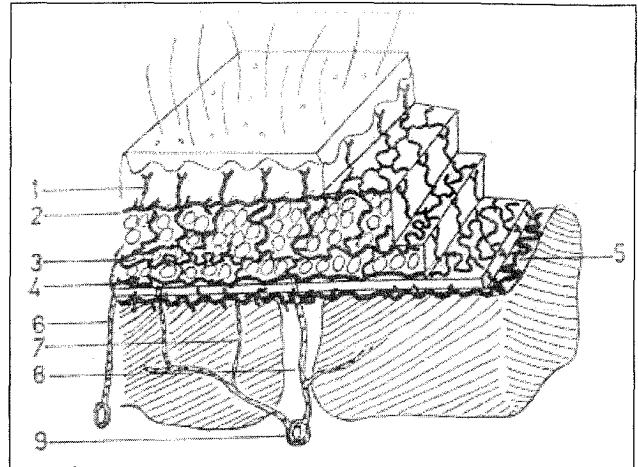
1. Antegrade (superiorly based)
2. Retrograde (inferiorly based)
3. Deepithelized turn over flaps
4. Islanded perforator based flaps
5. Fasciocutaneous with adipofascial extension

**INDICATIONS**

Moderate size defects with local healthy available tissue

**CONTRAINDICATIONS**

1. High velocity trauma



**Figure 1: Vascular Basis of Fascia**

- |                                |                              |
|--------------------------------|------------------------------|
| 1. Subepidermal Plexus         | 2. Subdermal Plexus          |
| 3. Subcutaneous Plexus         | 4. Suprafascial Plexus       |
| 5. Subfascial Plexus           | 6. Direct Cutaneous Artery   |
| 7. Musculocutaneous Perforator | 8. Septocutaneous Perforator |
| 9. Main Vessel                 |                              |

2. Mutilated donor site

**LIMITATIONS**

1. Not applicable for larger defects
2. Maximum reach upto midsole

**ADVANTAGES**

1. Safe vascularity
2. Simple and rapid procedure
3. Applicable in acute as well as chronic wounds
4. Provide stable and pliable soft tissue
5. Allows tendon gliding
6. Can be used as a free flap
7. Easy post op care
8. Does not require any special setup or training
9. External fixator does not preclude their use. Future surgery can be performed through them.

**DISADVANTAGES**

1. Sometimes transfer hair bearing skin
2. Donor site usually requires SSG
3. May require two stages for inferiorly based flap with intervening normal tissue where division of the pedicle is performed under local anaesthesia.

As per location of the defect, the leg and foot can be

divided into six areas-

1. Knee
2. Upper third of leg
3. Middle third of leg
4. Lower third of leg
5. Malleoli, Tendoachilles, Anterior ankle
6. Heel upto Midsole

For defects from knee to upper two third of leg antegrade flaps either based on the perforators arising from posterior tibial artery (on medial side) or flaps from anterolateral aspect based on the perforators of the peroneal artery are used. These flaps are transposition cum rotation in nature, hence the incision requires to be stepped up from the distal margin of the defects. Only those defects require flap cover where underlying vital structures are exposed. Sometimes in a given wound, part of it can be managed by SSG and rest might require a flap cover.

The defects at lower third of leg to midsole will require retrograde flaps based on the lower perforators of the above mentioned vascular trunks. The circumferential area involving tendoachilles, malleoli and anterior ankle can be managed by retrograde flaps supplied by perforators of either posterior tibial artery or peroneal artery depending upon the proximal available tissue. The width of the flap is maximum at the calf which is usually transferred for heel and sole defects. The natural anatomy is such that the weight bearing width of the heel up to midsole is almost same in dimension as that of the calf area. Therefore defects located here should not have paucity of tissue.

It is essential to incorporate 2-3 sizeable perforators in the pedicle, to ensure necessary blood supply, irrespective of the nature of the flap. That is how a non-conventional long flap can be designed with safety. The rationality of these flaps can be assessed by fresh cadaveric dissections, preoperative Colour Doppler study and peroperative fluorescein study.

**Preoperative Colour Doppler Study<sup>5-8</sup>** helps in locating the main vessel and the site and size of the perforators. The size of the peroneal artery decreases as we go from proximal to distal but posterior tibial artery diameter remains almost the same as since it

continues as the main vessel of the foot. However the perforators may vary in size irrespective of their location. The perforators can be classified based on their internal diameter into three groups: Small= 0.8-1.2 mm; Intermediate= 1.3-2.0 mm; Large= more than 2.0mm

The sizeable Perforators to sustain a flap are the intermediate or large ones. Bedside Audio-Doppler definitely helps in corroborating the findings of the Colour Doppler and vice versa. This also increases the accuracy in locating the perforators.

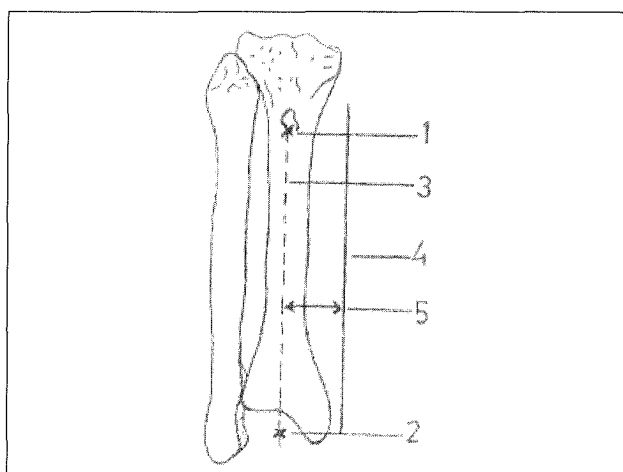
**The surface marking of vascular axis** of all the three main vessels of the leg is useful

#### **For Posterior tibial artery (Figure 2)**

A reference line is drawn by joining the tibial tuberosity and the midmalleolar point. The vascular axis lies approximately 4.5 cm medial and parallel to this line or 1.5 cm from medial border of tibia.

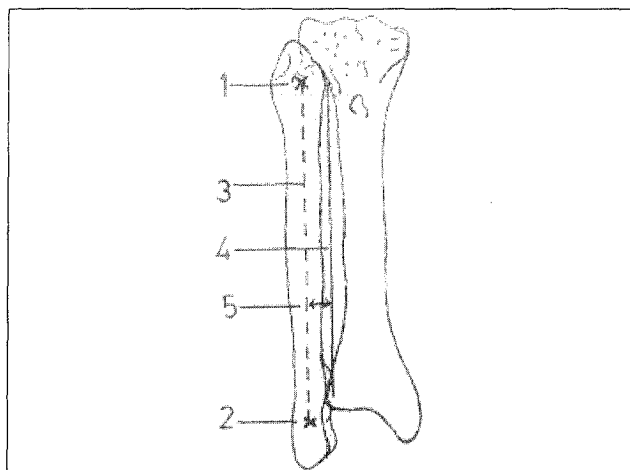
#### **For Anterior tibial and Peroneal arteries (Figures 3 & 4)**

The reference line is drawn by joining the head of fibula and tip of lateral malleolus. The Anterior tibial artery axis lies 2.5cm anterior and parallel to this reference line and Peroneal artery axis lies 2.5 cm posterior and parallel to this reference line. The exact location of the vascular axis can also be identified by pre operative Audio Doppler/ Colour Doppler studies.

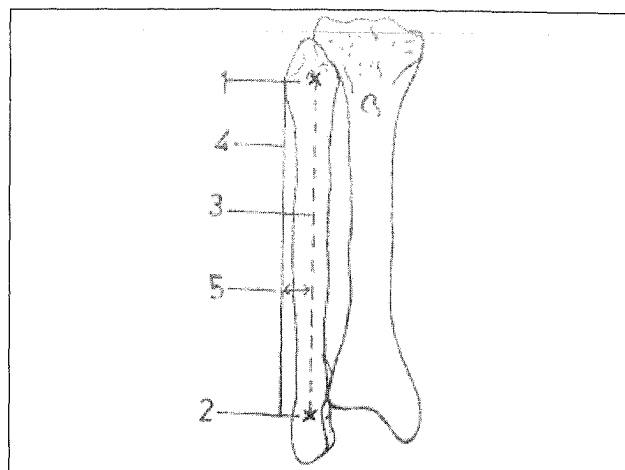


**Figure 2:** Vascular Axis of Posterior Tibial Artery

1. Tibial Tuberosity
2. Mid Malleolar Point
3. Reference Line
4. Vascular Axis
5. 4.5 Cm Medial and Parallel



**Figure 3: Vascular Axis of Anterior Tibial Artery**  
 1. Head of Fibula                      4. Vascular Axis  
 2. Tip of Lateral Malleolus        5. 2.5 Cm Anterior and Parallel  
 3. Reference Line



**Figure 4: Vascular Axis of Peroneal Artery**  
 1. Head of Fibula                      4. Vascular Axis  
 2. Tip of Lateral Malleolus        5. 2.5 Cm Posterior and Parallel  
 3. Reference Line

Peroperatively the vascular axis can be also located by identifying the first perforator (while raising the flap), which is ultimately sacrificed. The perforators of Posterior tibial artery and Peroneal artery are usually located at every 4-5 cm when measured from the tip of malleoli. They can be identified by Doppler about 1 cm on either side of the main vascular trunk depending upon their direction. This knowledge is of immense importance for safe application of a flap.

In retrograde flaps the lower limit of dissection decides the reach of the flap. Since lower two perforators are approximately within 8 cm from malleoli, that is taken as the safe limit of dissection inferiorly. However if the extent of the defect necessitates further dissection, then the vascularity is maintained by the lower perforators as well as by the small vessels arising from the anastomoses around the ankle joint. The safe upper limit of a retrograde flap is about 10 cm from the joint level in an adult. This observation was found justifiable after performing dye studies in fresh cadavers. If it needs enhancement then the distal part of the flap should be delayed 5 to 7 days prior to flap dissection. In anteromedial flaps the medial border of the flap lies along the medial border of tibia and the posterior border is at the mid calf line. In anterolateral flaps the lateral border is over the fibula and posterior border is upto mid calf line. However the flap can be extended by 1-2 cm if need be. Inferiorly based flaps are balloon shaped because of the configuration of the leg as well

as the feasibility of narrowing the pedicle to about 4 cm. If needed more than one flap can be raised for a given defect

### TECHNIQUE OF FLAP RAISING<sup>9,10</sup>

Once the patient is under anaesthesia, before painting, mark the outline/margins of the flap with the reverse side of the scalpel. This helps in knowing the flap design even if the markings are washed away during painting. The surgeon should have a flap planning kit. The dimensions of the defect are estimated. The availability of the surrounding tissue is judged. The final defect is measured after recreation.

**Planning in reverse-** this is a mock transfer of the flap. With a piece of lint a flap passes through all the stages of its transfer in reverse fashion starting from the point as if it has been inset into the recipient defect, to its raising from the donor site so as to avoid a flap falling short.

### Dissection of a Peninsular Fasciocutaneous Flaps

The dissection is initiated by distal beveled incision, which is deepened through skin, subcutaneous tissue and deep fascia so that at the cut margin all the layers remain at the same level. The fascia is sutured to the dermis at regular intervals to prevent shearing forces. The flap is dissected in subfascial plane through epimysium. As the flap is raised from distal to proximal,

perforators are encountered and their presence can be anticipated by carefully noticing the tenting/ tethering in deep fascia. When the desired flap has been raised, the ends are held and transferred to the defect. If need be the pedicle can be narrowed towards the vascular axis up to 4 cm ensuring the incorporation of perforators. This facilitates the transfer of the flap.

### **Dissection of Island/Skeletonized Perforator Based Flaps**

For all practical purpose when the skin is not in continuity at the base it becomes an island flap. Skeletonization of the perforators is a further modification of island flap where all the subcutaneous and fibrous tissues are severed except the perforators and their venae comitantes. Skeletonization of the perforators further increases the mobility of an island flap, though it is not always necessary. The survivability of such flap proves the importance of the perforators as the main source of blood supply.

### **Skeletonization has its advantages**

1. It makes the procedure single stage
2. Facilitates mobility of the flap
3. Can be performed with loupe magnification

Such flaps are indicated when the defect is almost adjacent to it. Technically an incision is given along a proposed line of the flap near the base. The perforators entering the pedicle are identified under loupe magnification. Sometimes another incision has to be given on the opposite proposed line of flap to clearly visualize the perforators from both the sides. There after, the flap can be raised rapidly.

### **USUAL TECHNICAL FAULTS**

#### **Patient Selection**

1. Planning without assessment of local tissue affected by trauma or infection.
2. Poor general condition, systemic diseases, malnutrition, anaemia, history of smoking and drug addiction.

These conditions may adversely affect the microcirculation

### **Intraoperative**

1. Poor flap planning
2. Failure to identify deep fascia and its incorporation in the flap
3. Failure of suturing the deep fascia to the dermis
4. Coarse tissue handling
5. Locating the pedicle away from the vascular axis
6. Towards the end of the dissection unnecessary undermining of the pedicle by blunt dissection.
7. Twist and kink at the pedicle
8. Suturing under tension
9. Pressure dressing
10. Failure to put a drain under the flap

### **POSTOPERATIVE MANAGEMENT**

1. Frequent monitoring is essential
2. Look for haematoma, evacuate if detected
3. Prevent infection
4. Distal part of the flap should be inspected atleast twice a day and whole dressing needs to be changed alternate day

### **IDENTIFICATION OF EARLY SIGNS OF FLAP NECROSIS**

1. Lowering of temperature
2. Fine shrinkage of epidermis at the distal part.
3. Discolouration
4. Appearance of small blisters
5. Dark blood on pinprick

### **FOLLOW UP**

1. Patient should be taught how to take care of the flap
2. after the patient is discharged, the flap should be inspected by the surgeon at least once in fortnight for first three months and thereafter every two months for two years.
3. Gradual weight bearing is allowed after 3 months for heel and sole defects
4. The appearance of sensations and their maturity is variable. Usually it starts around 6 months and takes almost two years.

## DONOR SITE MORBIDITY

It is usually acceptable to the patients. There is no functional loss. The grafted area gradually becomes soft and supple but seldom matches with the adjacent normal skin.

## CONCLUSION

Wherever feasible the ipsilateral fasciocutaneous flaps are most justified for moderate sized defects. Flaps of various other constituents based on same vascular principles are also applicable but it is beyond the scope of this article.

## REFERENCES

1. McCarthy. Plastic Surgery. General Principles; Philadelphia: WB Saunders Company; 1990. Vol 1. pp. 275-377.
2. Cormack GC, Lamberty BGH. "The Arterial Anatomy of Skin Flaps". 2nd edn. Churchill Livingstone; 1994.
3. Cormack GC, Lamberty BGH. A classification of fasciocutaneous flaps according to their patterns of vascularisation. *Br J Plast Surg* 1984;37:80-7.
4. Ponten B. The fasciocutaneous flap: its use in soft tissue defects of the lower leg. *Br J Plast Surg* 1980;34:215.
5. Giunta RE, Geisweid A, Feller AM. The value of preoperative doppler sonography for planning free perforator flaps. *Plast Reconstr Surg* 2000;105:2381-6.
6. Hallock GG. Evaluation of fasciocutaneous perforators using colour duplex imaging. *Plast Reconstr Surg* 1994;94:319.
7. Taylor GI, Doyle M, McCarten G. The doppler probe for planning flaps: anatomical study and clinical applications. *Br J Plast Surg* 1990;43:1-16.
8. Blondeel PN, Beyens G, Verhaege R, et al. Doppler flowmetry in the planning of perforator flaps. *Br J Plast Surg* 1998;51:202.
9. Bhattacharya V, Arora R. Fasciocutaneous flap with adipofascial extension in contour defects of the leg-a new technique. *Indian J Plast Surg* 2002;35:70-6.
10. Bhattacharya V. Fasciocutaneous flaps. *Plastic and Reconstructive Surgery: Current trends* (proceedings of CME program at National Conference of Association of Plastic Surgeons of India, Calcutta) 1998. pp. 36-40.