

## Case Report

# The constricted ear deformity-A case report

**Harish C. Ghildiyal, Tatsat Misra**

Plastic Surgery Unit, P.G. Department of Surgery, M.L.N. Medical College, Allahabad-211001, U.P., India

**Address for correspondence:** Dr. Harish C. Ghildiyal, 226, Niti Khand - III, Indirapuram, Ghaziabad-201010, India.  
E-mail: drghildiyal@yahoo.co.in

### ABSTRACT

A case report of constricted ear deformity and its correction with Musgrave's technique is presented.

### KEY WORDS

Congenital deformity, Constricted ear, Musgrave's correction.

### INTRODUCTION

A curious group of auricular anomalies exists in which one gains the impression that the rim of the ear has been tightened as if by a purse-string. The terms "lop ear" "lidded helix" "cup ear" "canoe ear" and "cockleshell ear" have been applied to various forms of the anomaly. Radford C. Tanzer<sup>1</sup> classified these deformities in to three groups representing a range of increasing severity of constriction. While this deformity seems rather simple to correct a recurrence and irregularities in the outcome is common. A number of techniques are available for the surgical correction of the constricted ear. Musgrave's<sup>2</sup> modification of the Stephenson's<sup>3</sup> method has been utilized by us with gratifying results. The purpose of this paper is to redefine the role of Musgrave's<sup>2</sup> technique in the reconstructive armamentarium for constricted ear deformity with good aesthetic outcome.

### CASE REPORT

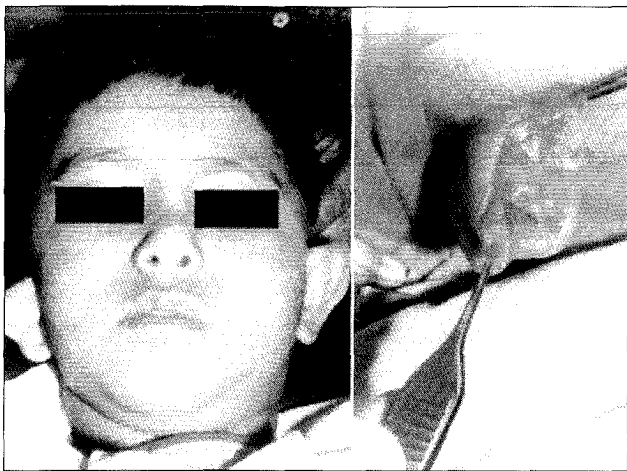A 5-year-old girl was admitted for repair of for her right constricted ear deformity (Figure 1, left). Her deformity

consisted of downward acute folding of the scapha and helix at about the tuberculum auriculae level (Figure 2, left). There was no other congenital anomaly present and family history was negative.

The child was classified as having Group IIA constriction after Tanzer<sup>1</sup> & Musgrave's<sup>2</sup> correction was done. During operation the deformed cartilage was separated from its soft tissue cover through a lateral skin incision along the base of the scaphal curvature. Radiating cartilage incisions were given (Figure 1, right). The cartilage fingers were lifted and a conchal cartilage strut was sutured to their tips. The skin was redraped and the incision was closed. Results were excellent (Figure 2, right).

### DISCUSSION

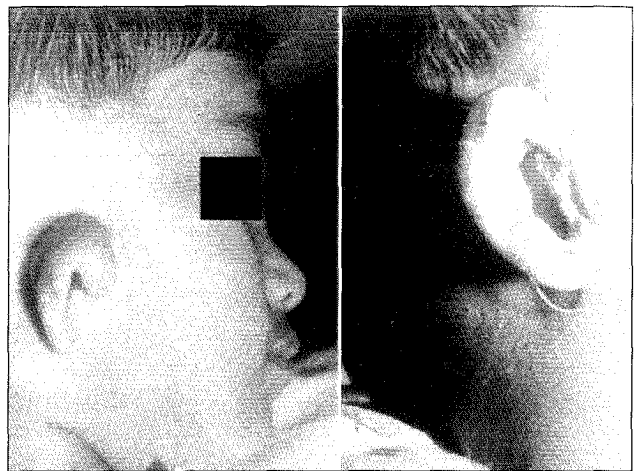
The constricted ears are very obvious, can't be hidden and are a prime target for the cruel humor of the multitude. In correcting such deformed ears, Stephenson<sup>3</sup> described cruciate radiating incisions through the superior edge of the helix rim, with these segments being fanned outward and held in their new position by postoperative packings and dressings.



**Figure 1:** (Left) Child showing right sided constricted ear deformity. (Right) Operative view showing radiating cartilage incisions along the base of the scaphal curvature

However the fanned out cartilage tend to spring back together. Musgrave improved the method. After filleting the deformed cartilage through a lateral incision he developed the radial fingers as described by Stephenson and then anchored the tips with a conchal cartilage strip which had been removed at the time that the prominence of the ear was corrected, through a separate medial incision. This extra strut maintained the re-formed framework in an expanded upright state.

There is no reason today why a human should suffer



**Figure 2:** (Left) Preoperative and (Right) postoperative view of the right ear after Musgrave's correction

because of constricted ear. The operation causes little discomfort and very little after pain. These cases should be among the most satisfactory that plastic surgeons does. The patients should be among the most grateful and they are.

## REFERENCES

1. Tanzer RC. The constricted (cup and lop) ear. *Plast Reconstr Surg* 1975;55:406-15.
2. Musgrave RH. A variation on the correction of the congenital lop ear. *Plast Reconstr Surg* 1966;37:394-8.
3. Stephenson KL. Correction of a lop ear type deformity. *Plast Reconstr Surg* 1960;26:540-5.