Article published online: 2024-03-17

Pictorial Essay

Lessons Learnt from Imaging Review of Interval Breast Cancers in a Single Center in the UK National Breast Screening Program

Jia Mang Lee[1] Palida Jantarang[1] Bhavani Rengabashyam[2]

[1] Hull York Medical School, University of York, York, United Kingdom
[2] York and Scarborough Teaching Hospitals Foundation Trust, York, United Kingdom

Indian J Radiol Imaging

Address for correspondence Bhavani Rengabashyam, MBBS, MRCP, FRCR, PG, York and Scarborough Teaching Hospitals Foundation Trust, Hull York Medical School, Breast Imaging Unit, Magnolia Centre, York Hospital, Wigginton Road, Clifton YO31 8HE, York, United Kingdom (e-mail: bhavani.rengabashyam@nhs.net).

Abstract

False-negative mammograms are a part of any screening program and the National Breast Screening Program in the United Kingdom is no exception. Every year, 2.5 million women have screening mammograms in the United Kingdom. Around 8 per 1,000 women screened are diagnosed with a breast cancer and 3 per 1,000 women will present with an interval breast cancer following a negative screening mammogram and before their next mammogram.

Robust quality standards have to be adhered to at every stage in the screening pathway in order to maintain the fine balance between detecting cancers early and avoiding unnecessary false-positive results. As part of this process, there is a mandatory requirement for screening units to review all breast cancers. We present a pictorial illustration of the lessons learnt from such a review in this essay. The cases described here are from one large breast screening unit in the North of England. In this unit, 30,000 to 40,000 women have a screening mammogram each year and these are all double read by human readers. All cases requiring recall and those where there is a disagreement between the first and second human reader go through a consensus/arbitration process involving a minimum of two human readers. Interval cancers are identified through a consistent process outlined by the screening program and are then subjected to a review by a minimum of two reviewers. In this process, the reviewers have access to the false-negative mammograms along with all priors that were available at the time of initial read. The reviewers make a decision on whether the initial mammogram is normal or abnormal without seeing the diagnostic mammogram with the interval cancer. They also categorize the density of the breast and describe the mammographic abnormality if there is any on a standardized interval cancer data collection form. Finally, they categorize the interval cancer into one of three types —"satisfactory," "satisfactory with learning points," or "unsatisfactory."

Keywords
- interval breast cancer
- National Breast Screening Program
- screening mammogram

DOI https://doi.org/10.1055/s-0043-1778633.
ISSN 0971-3026.

© 2024. Indian Radiological Association. All rights reserved.
This is an open access article published by Thieme under the terms of the Creative Commons Attribution-NonDerivative-NonCommercial-License, permitting copying and reproduction so long as the original work is given appropriate credit. Contents may not be used for commercial purposes, or adapted, remixed, transformed or built upon. (https://creativecommons.org/licenses/by-nc-nd/4.0/)
Thieme Medical and Scientific Publishers Pvt. Ltd., A-12, 2nd Floor, Sector 2, Noida-201301 UP, India

Introduction

The National Health Service Breast Screening Program (NHSBSP) in England defines interval breast cancers as cancers that develop in women in the interim between two screening mammograms. In the United Kingdom, this is usually within 3 years from the most recent screening mammogram. For every 1,000 women screened in the United Kingdom, 8 are diagnosed with a screen detected breast cancer and 992 women are reported to have normal mammograms.[1] Three out of the 992 women will be diagnosed with an interval breast cancer before their next screening mammogram.[1] This could manifest symptomatically or be picked up incidentally either by clinical examination or through opportunistic screening. Out of 100 interval cancers, 80 cancers are called true interval cancers as they are not seen on previous screening mammogram and have either developed after or are occult (category 1). Twenty cancers are seen on the prior mammogram as a subtle finding (category 2) or as a definite abnormality (category 3).

The NHSBSP recommends that all interval cancers are reviewed as a feedback learning loop for mammography readers, as a quality improvement tool and to feedback to patients if they wanted to know whether their cancer was present on the most recent screening mammogram.[2–4]

In this essay, we are describing the mammographic features of interval cancers and learning points from such a review undertaken in the North Yorkshire breast screening program.

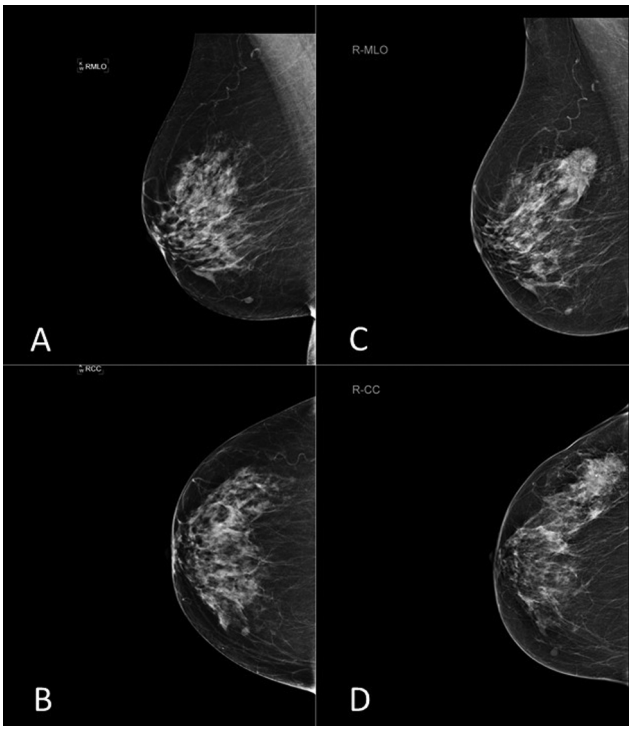

Fig. 1 Mediolateral oblique (above) and craniocaudal (below) views of the right breast show BI-RADS C density with a normal mammogram in December 2018 (**A, B**) and a new 5 cm mass requiring mastectomy and axillary node clearance in April 2021 (**C, D**). Category 1 interval cancer.

Learning Points

Type of Interval Cancer

Most interval cancers are not visible on the initial screening mammogram, and these category 1 intervals account for nearly 80% of cases.[1] The cancer could have developed in the interim, could be masked previously by the high-density breast, or could not be included in the mammogram due to its peripheral location (►**Figs. 1**–**3**). Interval cancers are generally higher grade and likely to be estrogen receptor negative in comparison to screen detected cancers.[5]

Mass Lesions

Most interval cancers present as mass lesions.[6] When these are small, they can be misinterpreted as benign (►**Fig. 4**). If there is a new mass in an incident screen, be cautious and recall especially if there is a past personal history of breast cancer, or a family history of breast cancer.

Calcification

The next common abnormality is microcalcification. As many cases of microcalcifications are benign, these are likely to be misinterpreted as such (►**Fig. 5**). When the microcalcifications are seen in dense breasts and mixed with bilateral benign calcification, they can be difficult to detect or easy to misinterpret. Ductal calcification could be misinterpreted as vascular calcification (►**Fig. 6**).

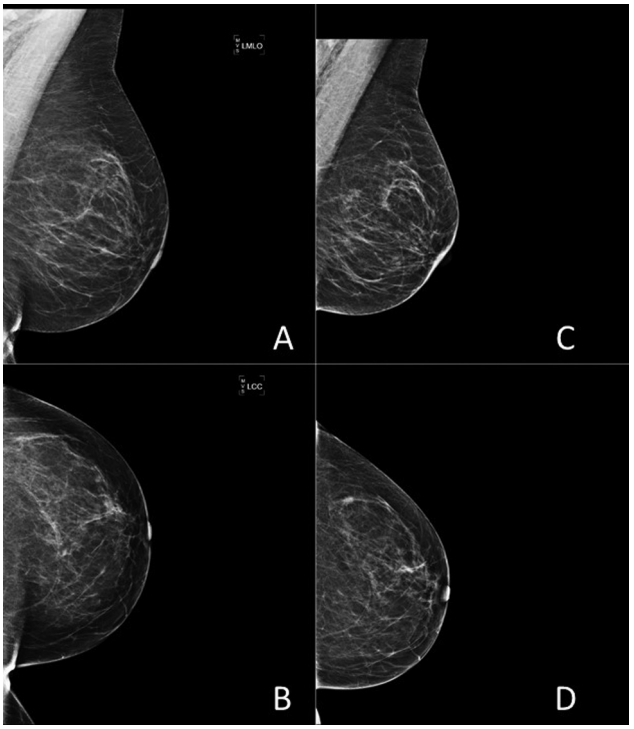

Fig. 2 Left breast mediolateral oblique view (above) and craniocaudal (CC) (below) shows BI-RADS B density with no focal abnormality on either view in 2019 (**A, B**). In 2021 (**C, D**), there is a new mass with calcification best seen in the CC view.

 © 2024. Indian Radiological Association. All rights reserved.

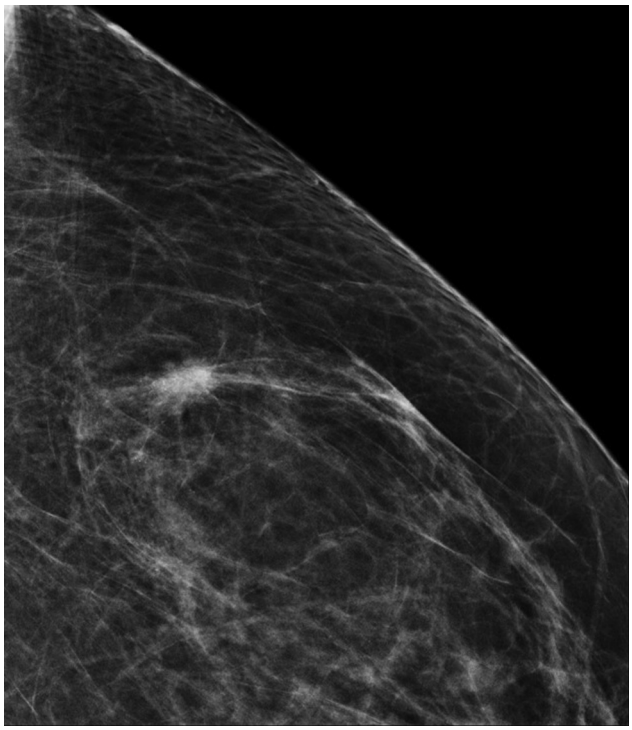

Fig. 3 Magnified view of the new mass with calcification that was a category 1 interval cancer.

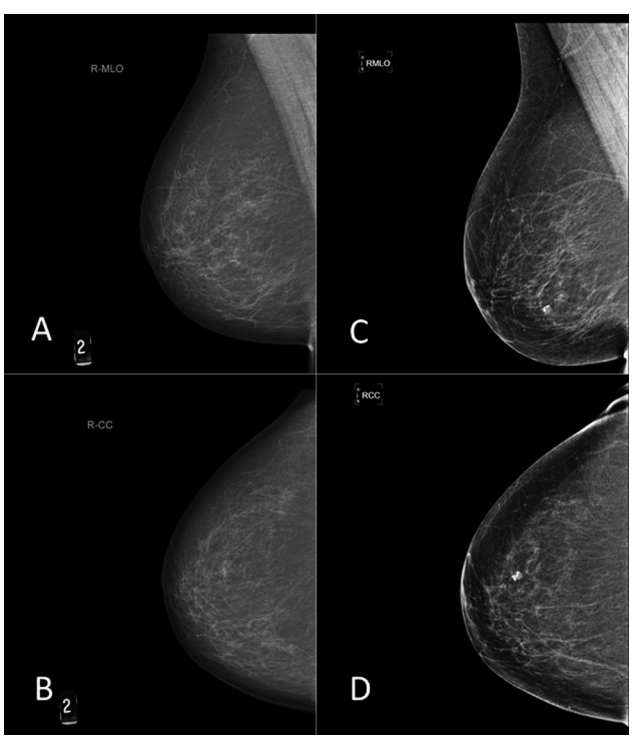

Fig. 4 Prior mammograms from 9 years ago (**A, B**). New mass with popcorn calcification misinterpreted as calcifying fibroadenoma (**C, D**). Grade 2 hormone receptor positive, HER 2 negative cancer.

 © 2024. Indian Radiological Association. All rights reserved.

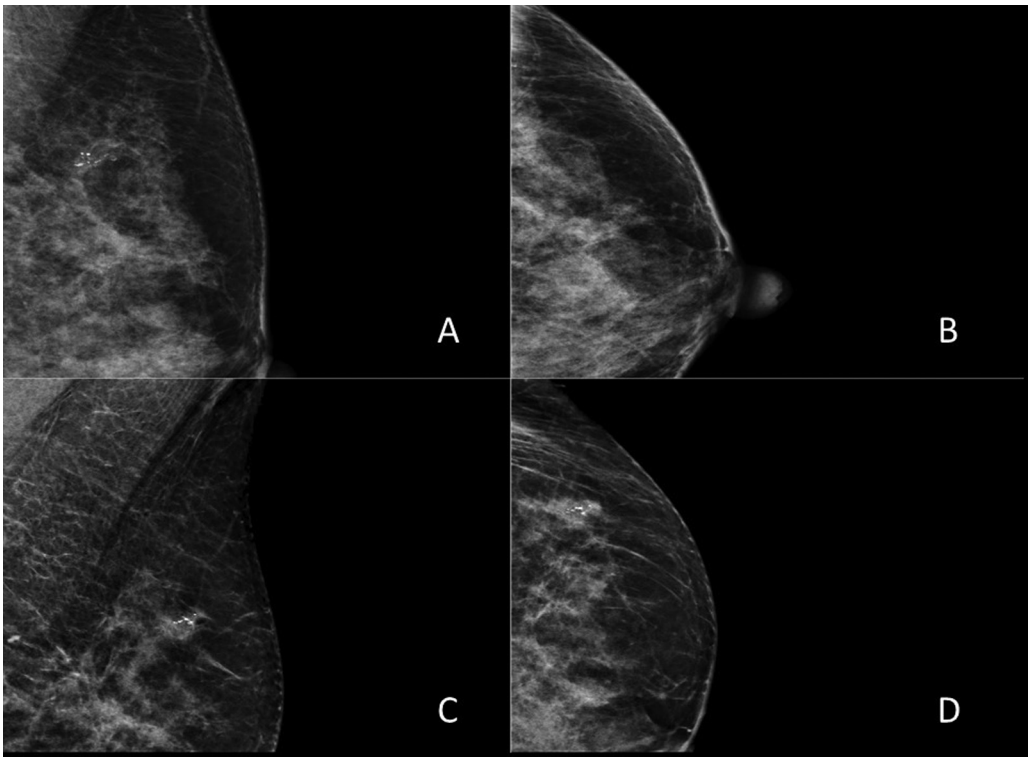

Fig. 5 Prevalent screen in January 2018 (**A, B**) shows solitary cluster of pleomorphic calcification seen best in part (**A**). It was misinterpreted as benign. Patient presented in December 2020 (**C, D**) with a lump and mass associated with the calcification.

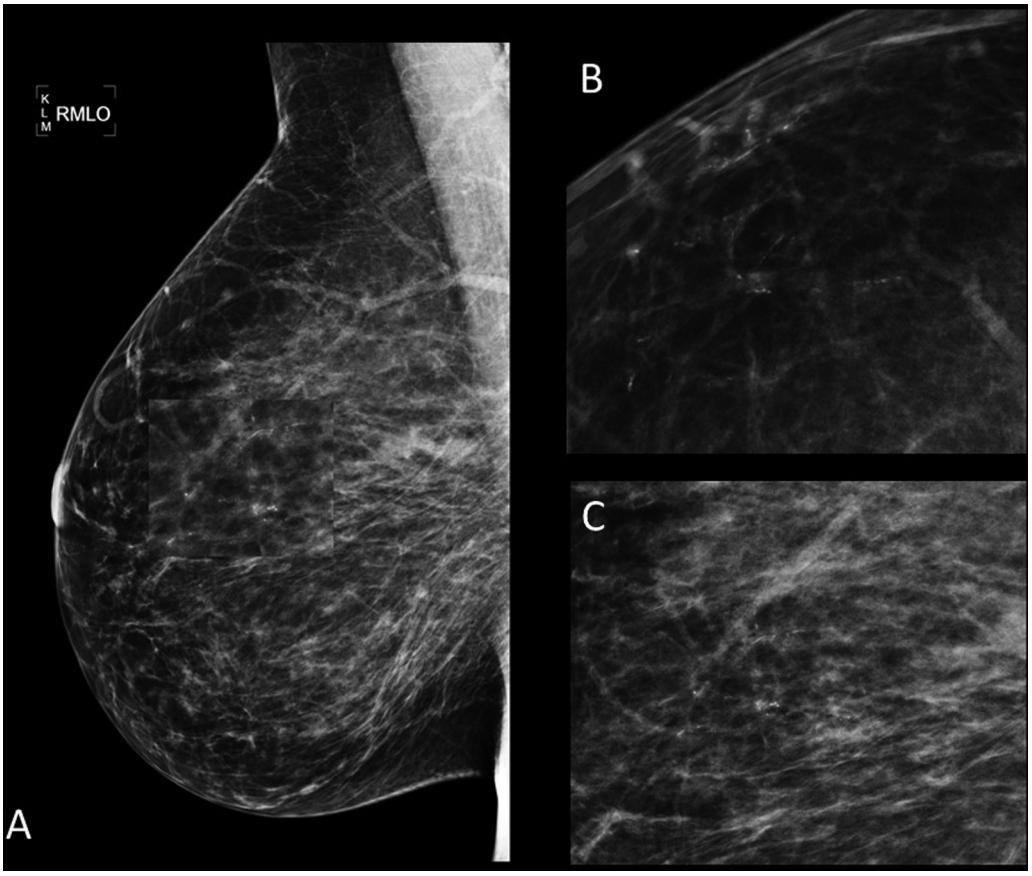

Fig. 6 Good case demonstrating how new branching ductal calcification can be misinterpreted as vascular calcification as this case was.

 © 2024. Indian Radiological Association. All rights reserved.

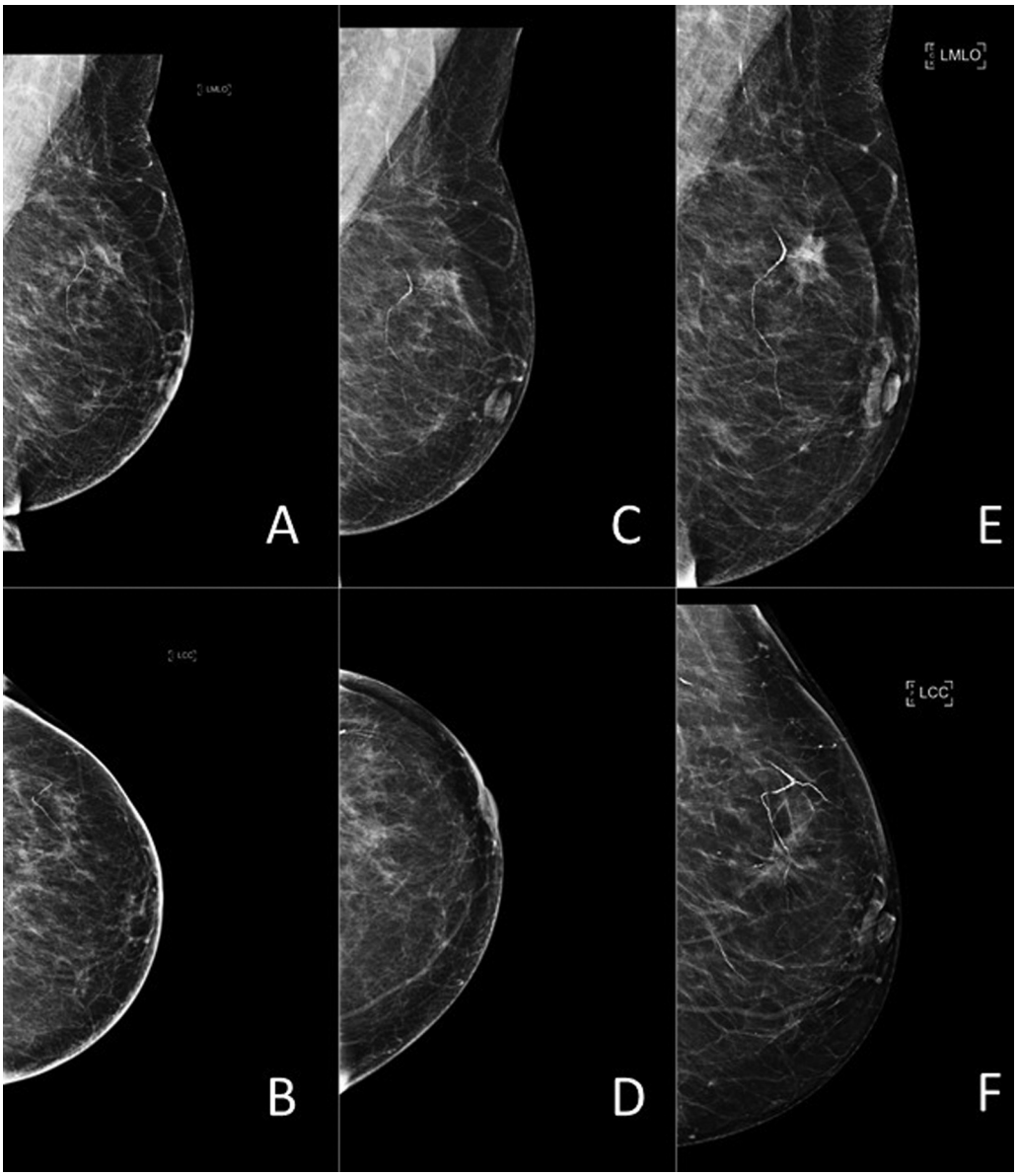

Fig. 7 This case demonstrates the importance of a well-positioned mammogram, especially in prior cancer surgery to show the site of post operative scar. This may have demonstrated the changing scar and resulted in an earlier pick up. (**A–D**) are prior mammograms while (**E, F**) are mammograms when the patient presented with a lump at the site of previous surgery.

Postsurgical Breast

Abnormalities are difficult to detect when there has been prior surgery. It is important that the surgical scar is included in the mammogram as best as possible to pick up subtle changes (►**Fig. 7**).

Distribution

Small prepectoral and pectoral masses can be mistaken for lymph nodes if not compared with priors carefully (►**Fig. 8**). Tomosynthesis may help characterize the lesion, but it is sometimes difficult to differentiate benign from suspicious appearance based on imaging alone and the lesion may require a biopsy. The screening with tomosynthesis or standard mammography trial suggested that there is a marginal reduction in interval cancer rates when tomosynthesis is used in screening, but the sample size and the number of interval cancers were small in this study. Tomosynthesis is currently not used in screening in the United Kingdom until further evidence emerges.[7]

Lesions close to nipple are particularly difficult to detect and characterize. It is important to have technically sound mammograms and to compare serial examinations to detect abnormalities (►**Fig. 9**). Subtle increase in density particularly on the craniocaudal view may be a sign of cancer.

Do not forget to check for abnormal lymph nodes overlying the pectoral muscle. These can represent locally advanced breast cancer, lymphoma, or axillary recurrence in a previous breast cancer patient (►**Fig. 10**).

 © 2024. Indian Radiological Association. All rights reserved.

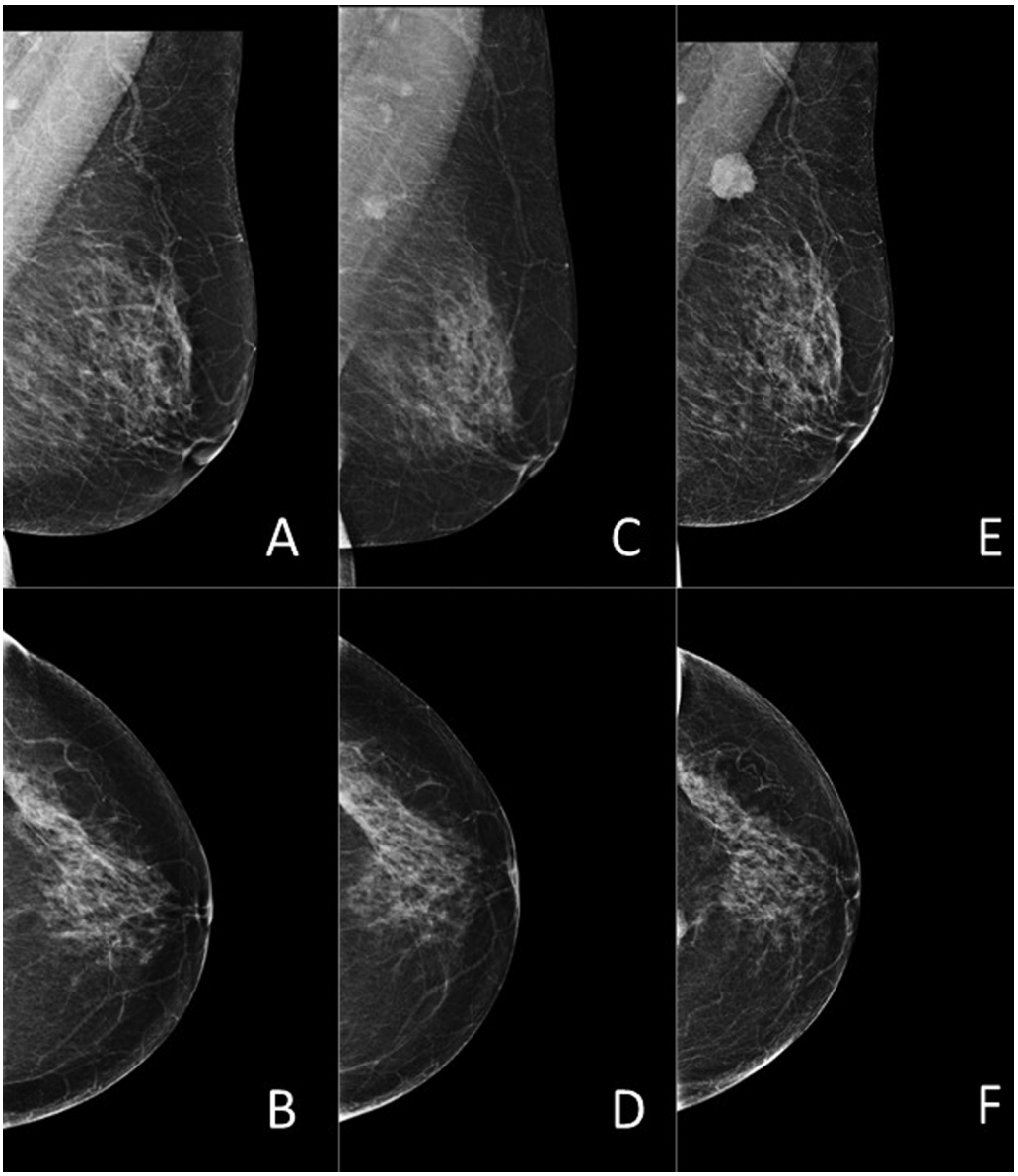

Fig. 8 Mass on the pectoral muscle. (**A, B**) A prior mammogram and (**C, D**) a new mass on the pectoral muscle that was misinterpreted as a lymph node. The patient presented with a symptomatic lump in the upper inner quadrant 9 months after her false-negative screening mammogram (**E, F**).

Temporal Evolution

Small changes are best appreciated on reviewing serial mammograms going back several years and not just the immediate priors (►**Figs. 11** and **12**). It is easy to overlook small and subtle abnormalities when compared with the immediate prior and assume that appearances are stable.

Technical Recalls

Diagnostic accuracy is enabled by a technically sound mammogram. Sometimes the images are blurred, the nipple is not in profile or due to inadequate compression, a mass or asymmetric density looks like composite overlap. The lesion may not be included if the positioning is inadequate. This highlights the importance of training mammography technicians to acquire optimal images and for those reading the mammograms to consistently recall women with suboptimal images unless there is a good reason not to (►**Figs. 7** and **13**).

Lesions Visible on One View Only

When mammographic abnormalities are small, they can be misinterpreted as composite overlap of fibroglandular tissue as they are best seen only on one view. Also, lesions are often only seen on one view in women with breast implants (►**Figs. 14** and **15**).

Conclusion

Interval cancers are an integral part of any screening program. Through adherence to robust quality standards such as regular reviews of false-negative screening, mammograms and application of the lessons learnt can improve the screening performance.

 © 2024. Indian Radiological Association. All rights reserved.

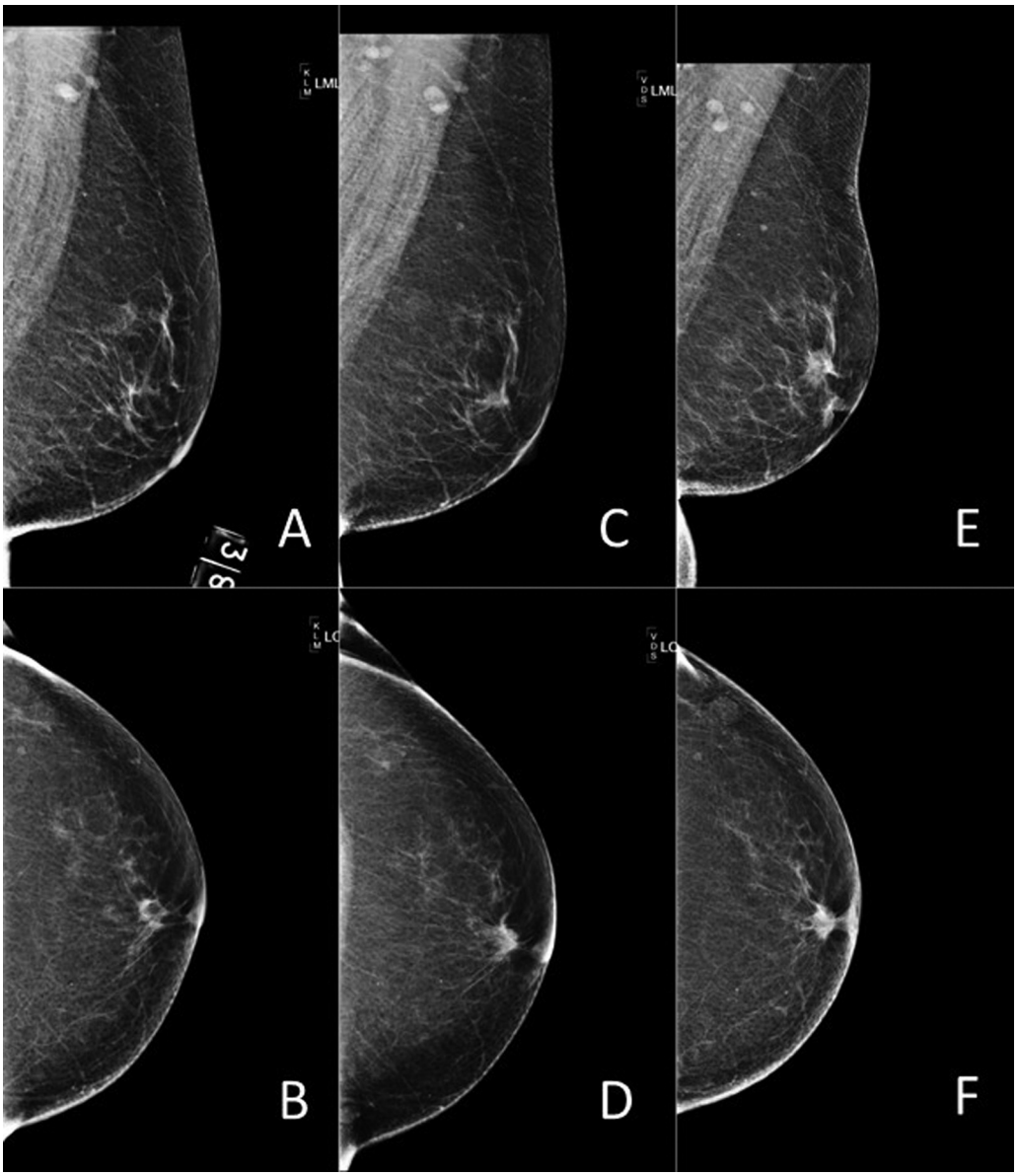

Fig. 9 Mammograms of the left breast from 2015 (**A, B**), 2018 (**C, D**) and 2021 (**E, F**). BI-RADS B breast density. The ill-defined mass seen only on the oblique view in 2018 was misinterpreted as composite; in retrospect the density has subtly increased on the craniocaudal. This is clearly seen on both views when it got bigger and became symptomatic in 2021. Category 2 interval cancer.

 © 2024. Indian Radiological Association. All rights reserved.

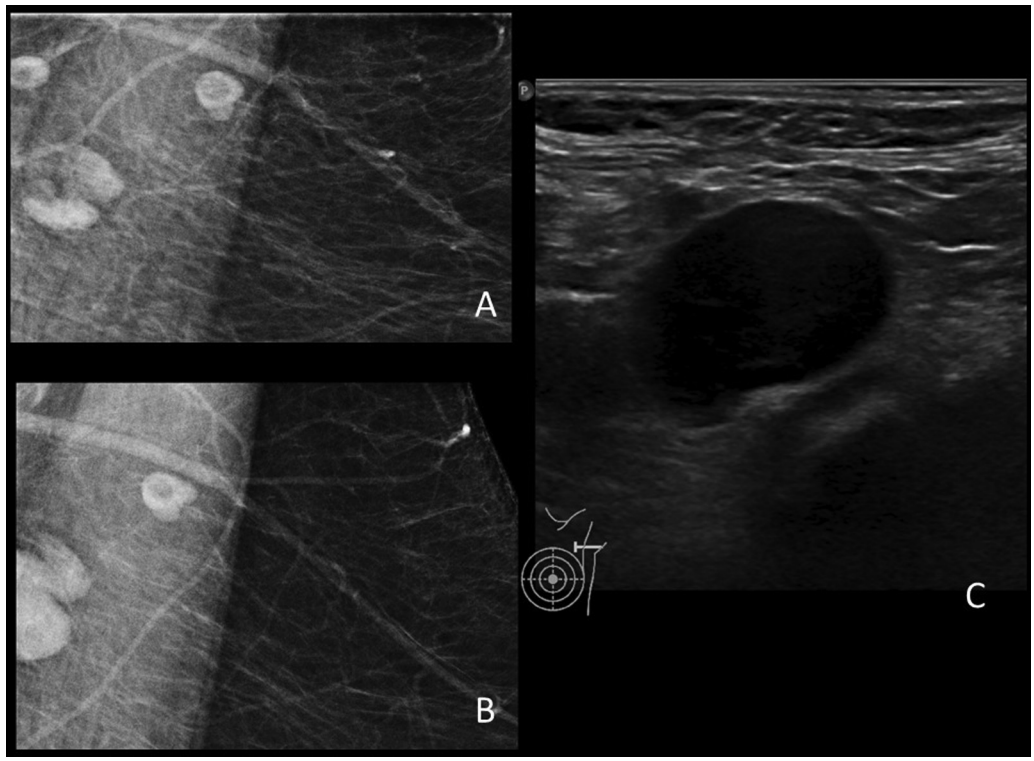

Fig. 10 Mammograms from 2015 (**A**) and 2018 (**B**). Changes in the lymph node cannot be appreciated if the image is technically inadequate and the periphery of the mammogram is not scrutinized. This lady presented 18 months after a screening mammogram with left axillary mass as seen on ultrasound (**C**), category 2 interval cancer.

 © 2024. Indian Radiological Association. All rights reserved.

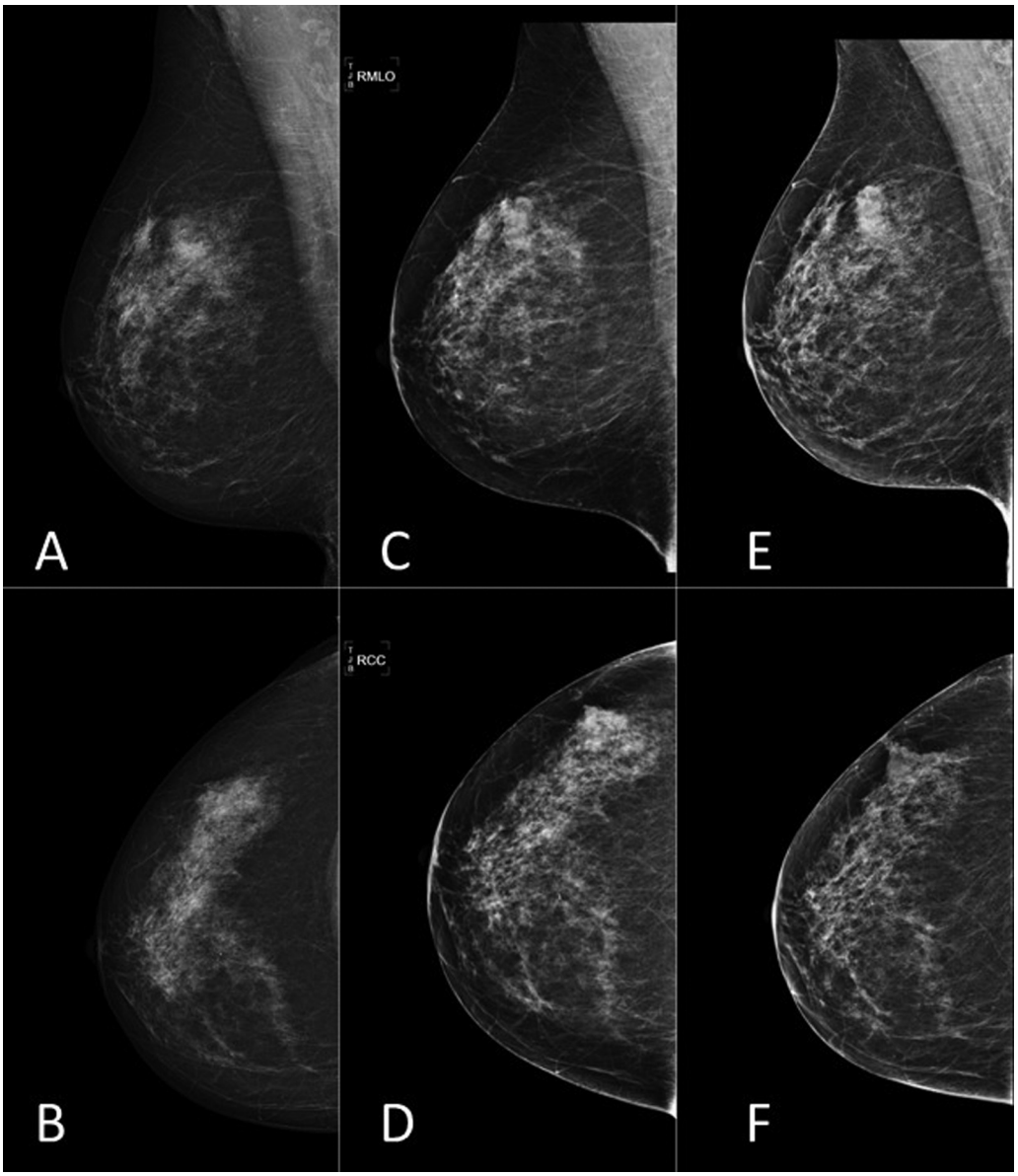

Fig. 11 Temporal evolution. In comparison to 2016 (**A, B**), there is a subtle increasing asymmetric density in the upper outer quadrant in 2019 (**C, D**) that was misinterpreted as composite overlap. Four months after the screening mammogram (**E, F**), the patient presents with a lump proven to be a cancer.

 © 2024. Indian Radiological Association. All rights reserved.

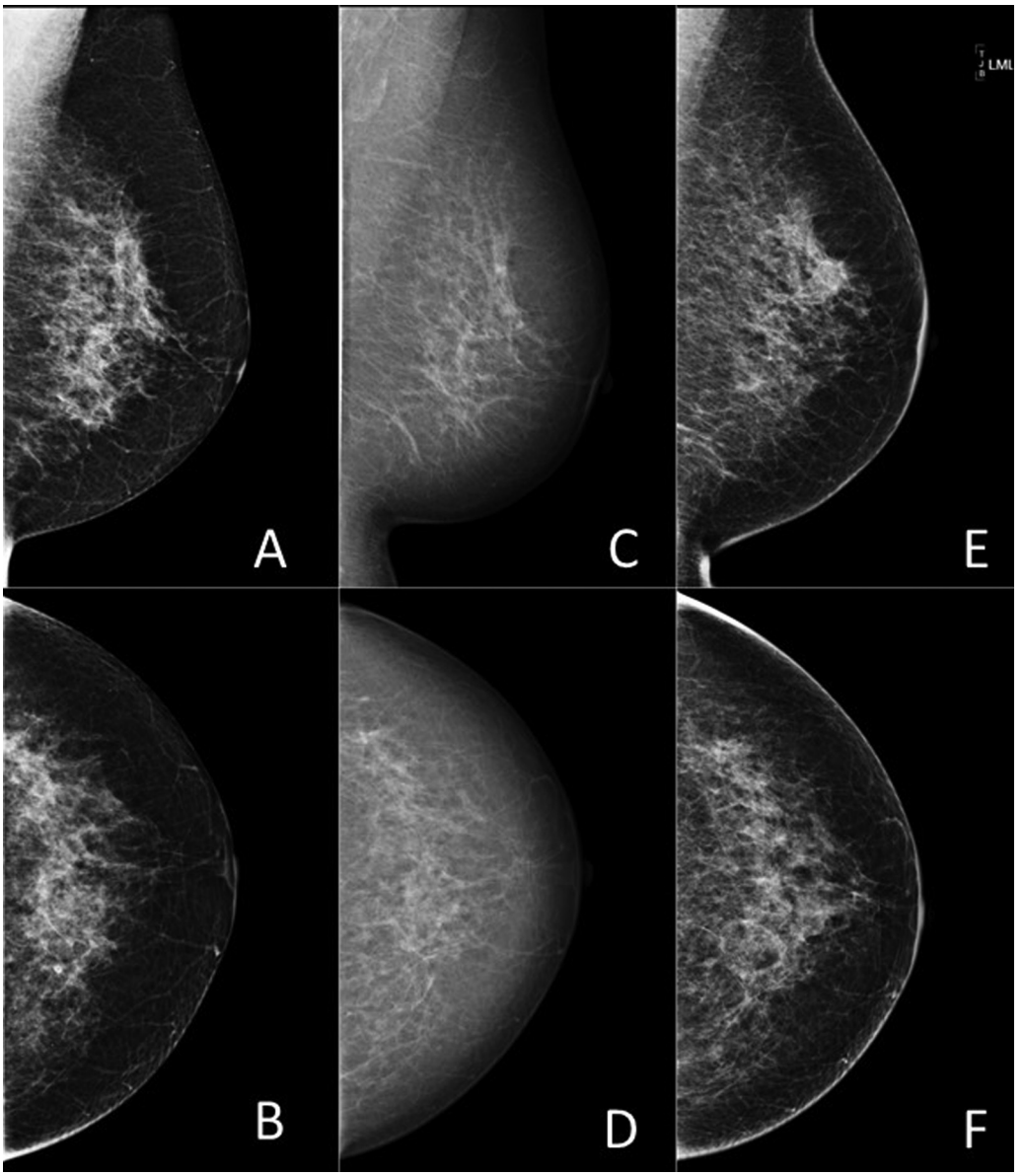

Fig. 12 Mass seen on mediolateral oblique view can be misinterpreted as composite, as lesion is subtle on craniocaudal. Review of serial mammograms (**A–F**) enables better detection.

 © 2024. Indian Radiological Association. All rights reserved.

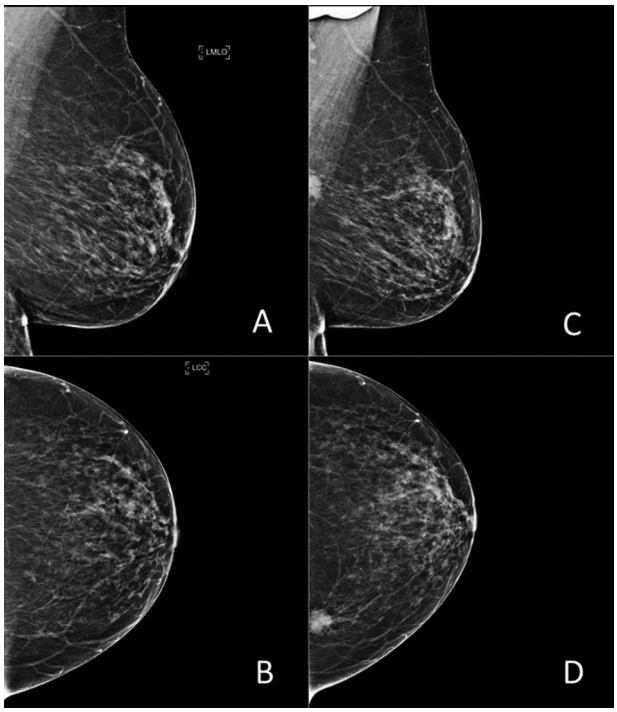

Fig. 13 Mammogram reported as normal in February 2019 (**A, B**) and presented with lump in May 2019 (**C, D**). Note that (A) does not include the lower pectoralis muscle as it is not a well-positioned mammogram. This was a 42 mm G3 node negative hormone receptor positive, Her 2 negative cancer. Patient had a left wide local excision and sentinel lymph node biopsy then died of progressive bone metastases in 2021.

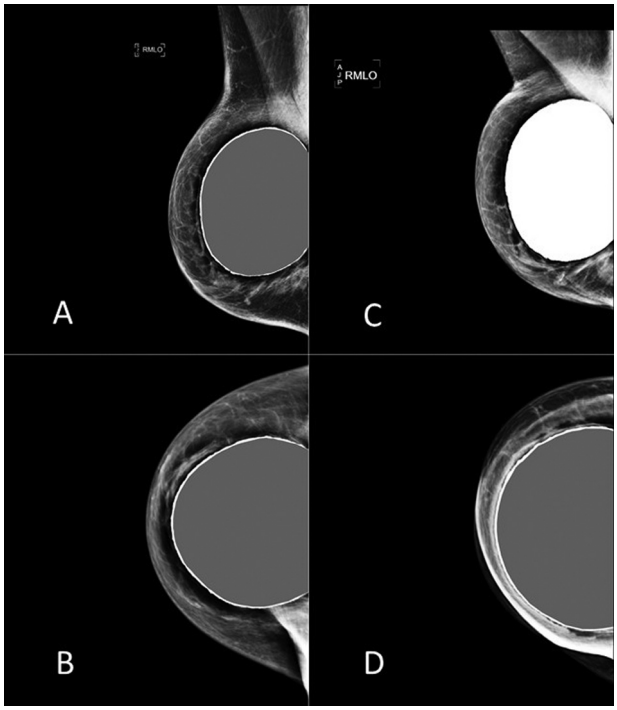

Fig. 14 Breast implants with new mass only seen on one view, in the lower half of the oblique view (**C**). Prior mammograms (**A**) and (**B**) are normal. Maintain a low threshold for abnormalities seen on 1 view in women with implants.

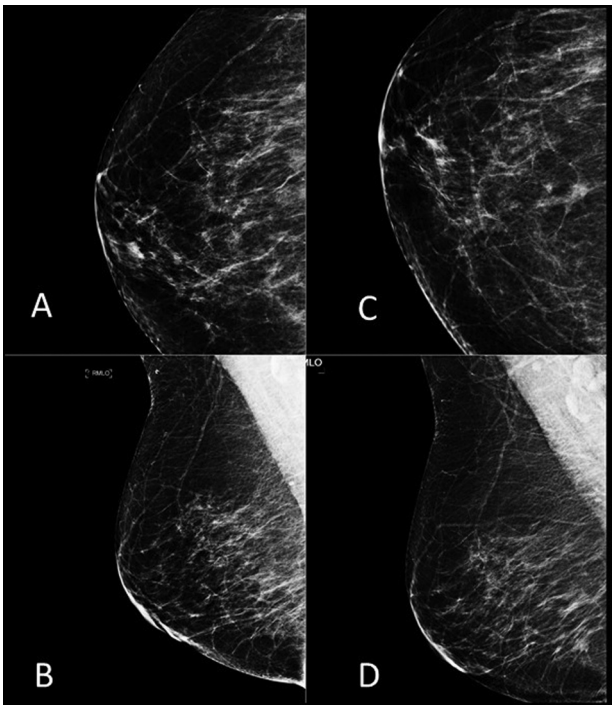

Fig. 15 Prior mammogram (**A, B**) with the back of breast excluded on the craniocaudal (CC) view. A subtle spiculated density can be seen in the lower half of the oblique view and at the back of the CC view on the current mammogram (**C, D**). This was overlooked as the prior CC was technically inadequate with the retromammary fat not pulled on. Note both CC views are zoomed in to illustrate the density better.

Funding
None.

Conflict of Interest
None declared.

References

1 Interval cancers explained in the NHS Breast Screening Programme [Internet]. GOV.UK. [cited 2023 Nov 25]. Accessed February 23, 2024 at: https://www.gov.uk/government/publications/nhs-screening-programmes-duty-of-candour/interval-cancers-explained-in-the-nhs-breast-screening-programme-notes-for-professionals-and-patients
2 Warren R, Duffy S, Duffy SW. Interval cancers as an indicator of performance in breast screening. Breast Cancer 2000;7(01): 9–18
3 Bennett RL, Sellars SJ, Moss SM. Interval cancers in the NHS breast cancer screening programme in England, Wales and Northern Ireland. Br J Cancer 2011;104(04):571–577
4 Breast screening: interval cancers [Internet]. GOV.UK. 2021 [cited 2023 Nov 4]. Accessed February 23, 2024 at: https://www.gov.uk/government/publications/breast-screening-interval-cancers
5 Niraula S, Biswanger N, Hu P, Lambert P, Decker K. Incidence, characteristics, and outcomes of interval breast cancers compared with screening-detected breast cancers. JAMA Netw Open 2020;3(09):e2018179
6 Hofvind S, Geller B, Skaane P. Mammographic features and histopathological findings of interval breast cancers. Acta Radiol 2008;49(09):975–981
7 Houssami N, Bernardi D, Caumo F, et al. Interval breast cancers in the 'screening with tomosynthesis or standard mammography' (STORM) population-based trial. Breast 2018;38:150–153

 © 2024. Indian Radiological Association. All rights reserved.