

Letter: Rectal Tuberculosis-An Uncommon Cause of Diarrhea

Brij Sharma¹ Vishal Bodh¹ Rajesh Sharma¹ Ashish Chauhan¹ Anshul Bhateja¹

¹Department of Gastroenterology, Indira Gandhi Medical College, Shimla, Himachal Pradesh, India

Address for correspondence Anshul Bhateja, MD, Department of Gastroenterology, Indira Gandhi Medical College, Shimla 171001, Himachal Pradesh, India (e-mail: dr.anshulabh@gmail.com).

J Gastrointest Infect

A 44-year-old male patient, a known case of bronchial asthma, presented with the chief complaints of fever for the last 3 weeks, shortness of breath, and passage of fresh blood in stools. There was a history of loose stools for the same duration, four to five times in frequency, small in volume. He also had anorexia and weight loss. The patient had low fever, intermittent, not associated with chills and rigors and it seldom crossed 100°F. The diarrhea was associated with tenesmus. There was a past history of pulmonary tuberculosis (TB; sputum positive) 11 years back for which the patient received antitubercular therapy for 6 months. Physical examination revealed mild pallor and chest examination was suggestive of tracheal shift to left side and crepts in left supraclavicular area. Except this, the rest of general and the systemic examination were essentially normal. Digital rectal examination was performed and it was normal.

Investigations revealed hemoglobin of 14.2 g/dL, total leucocyte count of 10,400/ cu mm (neutrophil: 49%, lymphocyte: 13%, and eosinophil: 7%), erythrocyte sedimentation rate of 80 mm/hr, and C-reactive protein of 95.5. The patient had fasting blood sugar of 85 mg/dL, urea of 35 mg/dL, and creatinine of 0.71 mg/dL. Liver function tests showed normal bilirubin and enzymes. Stool examination revealed six to eight leucocytes and five to six pus cells per cubic millimeter. On Mantoux test induration was 11 mm. Ultrasonography of the whole abdomen did not reveal any abnormality. Chest radiograph was within normal limits except for a fibrotic lesion in the left apical region. Sputum for acid fast bacilli (AFB) and cartilage based nucleic acid amplification test (CBNAAT) was reported negative. Colonoscopy was performed. It showed multiple punched out ulcers in the rectum with a necrotic base and undermined edges (► **Figs. 1–2**). Biopsy was taken from the margin of the ulcer. Histopathological examination showed caseating granulomas in the specimen,

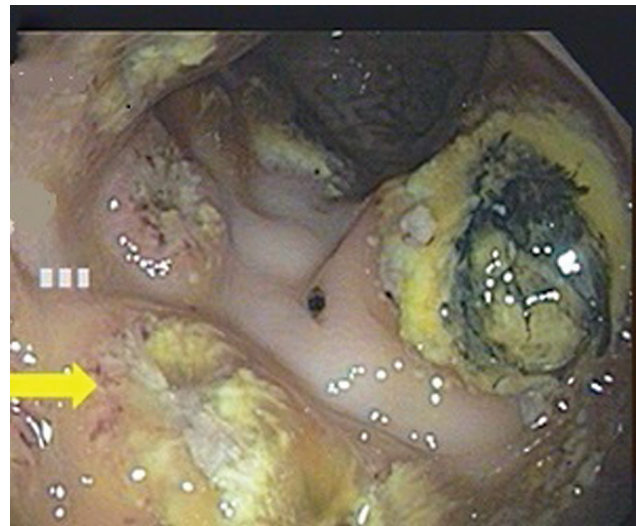


Fig. 1 Colonoscopic image of multiple punched out rectal ulcers with overlying slough.

along with Langerhans giant cells. There was no evidence of malignancy. Rectal ulcer smears were prepared and reported positive for AFB on ZN staining (► **Fig. 3**). It was diagnosed as a case of isolated rectal TB.

The patient was put on antitubercular drugs. A repeat colonoscopy done after 3 months of starting of antitubercular treatment showed visible healing of the ulcers. Meanwhile, his fever subsided, hematochezia had also stopped, pallor improved, and he gained 2 kg weight. His stool frequency also came down to one to two times per day. He has been doing well till date.

TB, one of the most common communicable diseases, continues to be a major health problem despite recent

received
October 21, 2023
first decision
November 10, 2023
accepted
December 15, 2023

DOI <https://doi.org/10.1055/s-0043-1778679>.
ISSN 2277-5862.

© 2024. Gastrointestinal Infection Society of India. All rights reserved.

This is an open access article published by Thieme under the terms of the Creative Commons Attribution-NonDerivative-NonCommercial-License, permitting copying and reproduction so long as the original work is given appropriate credit. Contents may not be used for commercial purposes, or adapted, remixed, transformed or built upon. (<https://creativecommons.org/licenses/by-nc-nd/4.0/>)

Thieme Medical and Scientific Publishers Pvt. Ltd., A-12, 2nd Floor, Sector 2, Noida-201301 UP, India

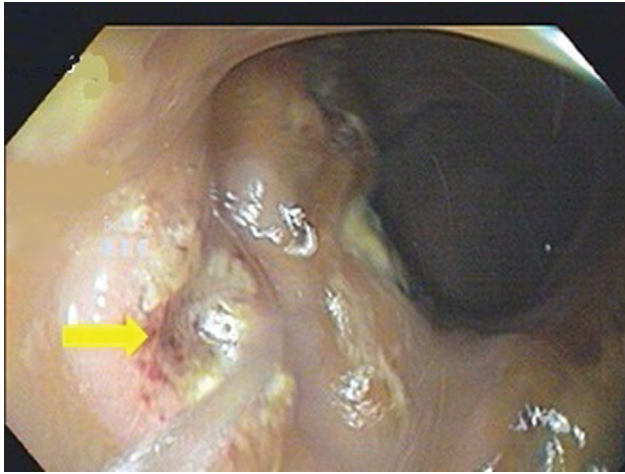


Fig. 2 Colonoscopic image of multiple punched out rectal ulcers after washing of slough.

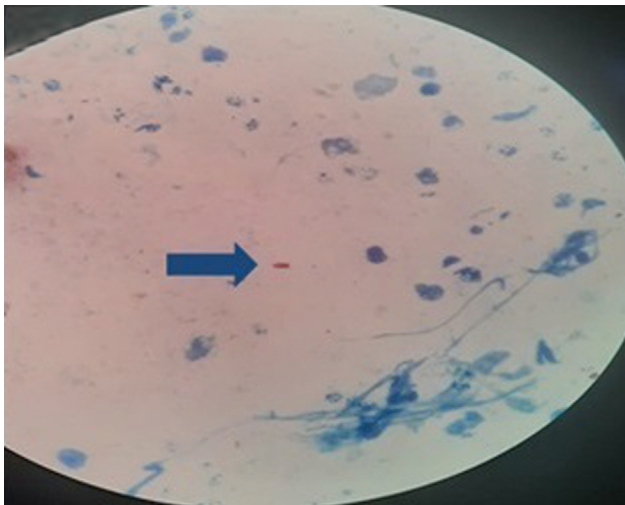


Fig. 3 Acid fast bacilli (blue arrow).

advances in its diagnosis and management. India is the global capital for TB with around 26% cases of the world TB cases, followed by China and South Africa.¹ Abdominal TB remains one of the common sites of extrapulmonary involvement, where it tends to involve the gastrointestinal tract, peritoneum, lymph nodes, and solid organs in that order.² Colonic

involvement in intestinal TB is seen in up to 10% of cases and is mostly seen in patients with concomitant ileocecal TB. However, isolated colonic TB is rare.^{3,4} The paucibacillary nature of the disease, a plethora of mimics, and the low yield of various microbiological tests make the diagnosis challenging.⁵

TB remains an uncommon cause of rectal ulcers and hence a high level of suspicion is required, especially in endemic regions. It will lead to timely detection and treatment with reasonably high cure rates.

Informed Consent

Patient provided informed consent to publish the included information.

Ethical Statement

Not applicable.

Authors' Contributions

All authors contributed equally to the article.

Data Availability Statement

There is no data associated with this work.

Funding

None.

Conflict of Interest

None declared.

Acknowledgments

None.

References

- 1 World Health Organization Global tuberculosis report 2019. Accessed December 31, 2023 at: <https://apps.who.int/iris/bitstream/handle/10665/329368/9789241565714-eng.pdf?ua=1>
- 2 Sharma V, Debi U, Mandavdhare HS, Prasad KK. Tuberculosis and other mycobacterial infections of the abdomen. In: Kuipers EJ, ed. *Encyclopedia of Gastroenterology*. 2nd ed. Academic Press; 2020: 646–659
- 3 Tishler JM. Tuberculosis of the transverse colon. *AJR Am J Roentgenol* 1979;133(02):229–232
- 4 Kochhar R, Sood A, Wig JD, et al. Spectrum of isolated colorectal tuberculosis. *Indian J Gastroenterol* 1989;8:A56–A57
- 5 Sharma V. Differentiating intestinal tuberculosis and Crohn disease: Quo Vadis. *Expert Rev Gastroenterol Hepatol* 2020;14(08):647–650