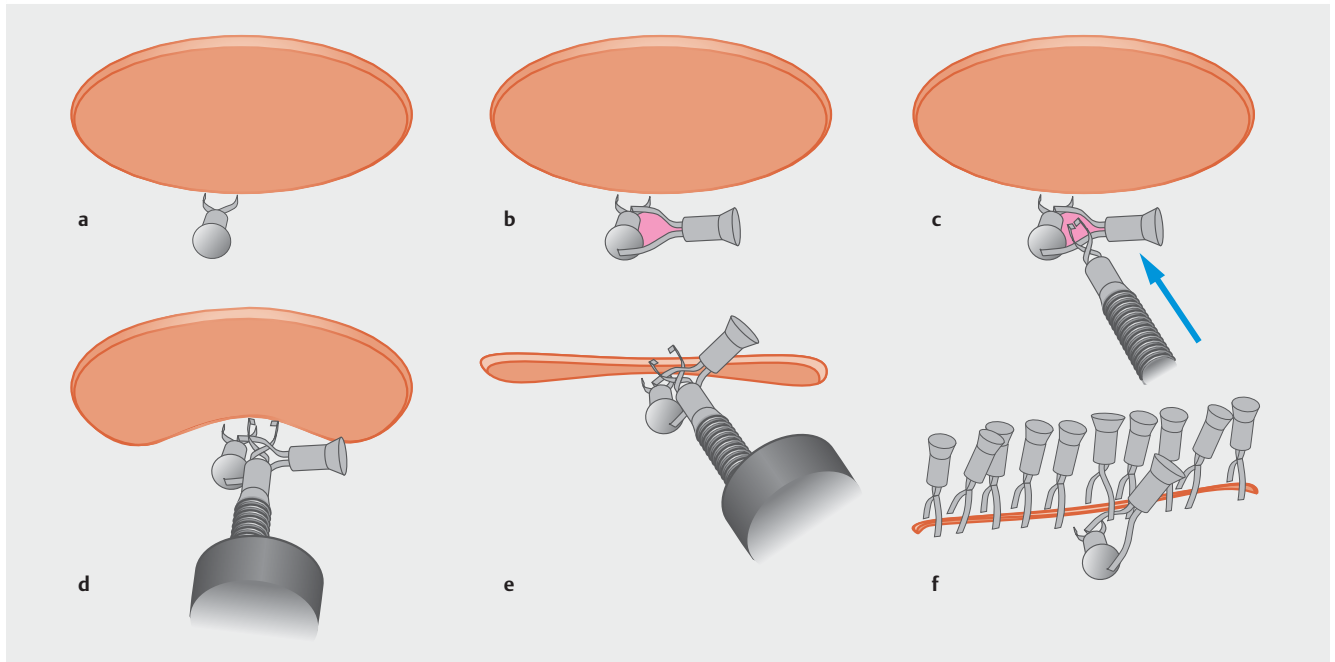


New closure method for a mucosal defect after endoscopic submucosal dissection: the clip-on-clip closure method



► Fig. 1 Schema of the clip-on-clip closure method (CCCM). **a** Place the first clip on the normal mucosa slightly away from the mucosal defect. **b** Place the second clip on the handle of the first clip. **c, d** Pass the teeth of a third clip through the gap (red area) between the teeth of the second clip, which serves as an anchor. **e** Attach the third clip to the normal mucosa on the contralateral side of the mucosal defect. **f** The postoperative mucosal defect is completely closed by the CCCM and additional clips.

Endoscopic submucosal dissection (ESD) is an effective method that enables simultaneous resection of early malignant tumors. However, postoperative bleeding and perforation are often problematic. Therefore, various postoperative mucosal defect closure methods have been reported. The 8-ring and endoscopic slip-knot clip suturing methods are closure methods that require additional devices, as well as regular clips [1, 2]. Recently, a useful mucosa – submucosa clip closure method using only clips has been reported [3]. However, these methods may require a special device or damage the muscular layer of the mucosal defect. We developed a new, simple method, named the clip-on-clip closure method (CCCM), which is described below.

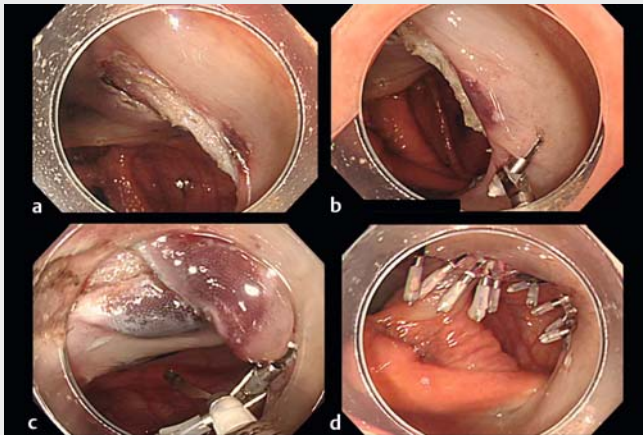
The steps of the CCCM are as follows:

1. Place the first clip on the normal mucosa slightly away from the mucosal defect (► Fig. 1 a).
2. Place the second clip on the handle of the first clip (► Fig. 1 b).
3. Pass the teeth of the third clip through the gap between the teeth of the second clip, which serves as an anchor (► Fig. 1 c, d).
4. After confirming that the clips are secure, pull the third clip across the defect and attach it to the contralateral side of the mucosal defect (► Fig. 1 e).
5. Finally, confirm that the third clip is securely attached to the mucosa on the opposite side of the mucosal defect. By placing additional clips, the mucosal defect is completely retracted.

► **Video 1** shows an example of CCCM after colon ESD. The mucosal defect area after ESD was somewhat bigger than 30mm and straddled the colon folds, so it was considered difficult to suture with a normal clip. CCCM for defect closure, as described, was successful (► Fig. 1 f).

The CCCM we developed is simple, does not require a special device, and does not damage the muscular layer of the postoperative mucosal defect area. Thus, CCCM is feasible for closing mucosal defects after ESD.

Endoscopy_UCTN_Code_TTT_1AQ_2AD



Video 1 Example of the clip-on-clip closure method after endoscopic submucosal dissection (ESD) of the colon. The following sequence is shown. **a** The mucosal defect area after ESD (> 30 mm). **b** The first clip is placed on the normal mucosa near the mucosal defect, and the second clip is placed on the handle of the first clip. **c** The teeth of the third clip are passed through the gap between the teeth of the second clip, and then the clip is attached to the opposite normal mucosa. **d** Ultimately, using normal clips, the mucosal defect is completely closed.

References

- [1] Fujii T, Ono A, Fu KI. A novel endoscopic suturing technique using a specially designed so-called “8-ring” in combination with resolution clips (with videos). *Gastrointest Endosc* 2007; 66: 1215–1220
- [2] Nishizawa T, Uraoka T, Sagara S et al. Endoscopic sliplink clip suturing method: an ex vivo feasibility study. *Gastrointest Endosc* 2016; 83: 447–450
- [3] Banno S, Nishizawa T, Kinoshita S et al. Endoscopic mucosa–submucosal clip closure method. *Endoscopy* 2017; 49: E307–E308

Bibliography

DOI <https://doi.org/10.1055/s-0044-100486>

Published online: 2.2.2018

Endoscopy 2018; 50: 547–548

© Georg Thieme Verlag KG

Stuttgart · New York

ISSN 0013-726X

ENDOSCOPY E-VIDEOS

<https://eref.thieme.de/e-videos>



Endoscopy E-Videos is a free access online section, reporting on interesting cases and new

techniques in gastroenterological endoscopy. All papers include a high quality video and all contributions are freely accessible online.

This section has its own submission website at

<https://mc.manuscriptcentral.com/e-videos>

Competing interests

None

The authors

Tatsuma Nomura^{1,2}, Akira Kamei², Shinya Sugimoto², Jun Oyamada²

1 Department of Gastroenterology, Kinan Hospital, Minamimuro, Japan

2 Department of Gastroenterology, Ise Red Cross Hospital, Ise, Japan

Corresponding author

Tatsuma Nomura, MD

Department of Gastroenterology, Kinan Hospital, 4750 Atawa, Mihama-cho,

Minamimuro-gun, Mie 519-5293, Japan

Fax: +815-9792-3357

m06076tn@icloud.com