



# MVP-Assisted Temporary Vascular Occlusion during $^{90}\text{Y}$ Radioembolization: A Case Report

John J. Park<sup>1</sup> Franz Edward Boas<sup>1</sup> Federico Pedersoli<sup>1</sup>

<sup>1</sup>Department of Radiology, Division of Interventional Radiology, City of Hope Comprehensive Cancer Center, Duarte, California, United States

**Address for correspondence** John J. Park, MD, PhD, Department of Radiology, Division of Interventional Radiology, City of Hope Comprehensive Cancer Center, 1500 E Duarte Rd, Duarte, CA 91010, United States (e-mail: johnpark@coh.org).

J Clin Interv Radiol ISVIR

## Abstract

Yttrium-90 radioembolization is an effective treatment for liver cancers. However, deposition of radioactive microspheres in nondiseased liver can result in parenchymal injury. Segmental and subsegmental radioembolization may reduce off-target liver damage but may not always be possible due to anatomy. In this case report, we highlight the use of a microvascular plug (MVP) to protect distal nondiseased liver and redirect flow into the proximal tumor-containing liver volume during radioembolization of a gallbladder cancer recurrence. Throughout the report, we describe the technique, advantages, and limitations of using MVP-assisted temporary vascular occlusion during organ protection.

## Keywords

- ▶ radioembolization
- ▶ temporary vascular occlusion
- ▶ microvascular plug

## Introduction

Transarterial radioembolization (TARE) with yttrium-90 ( $^{90}\text{Y}$ ) microspheres is an effective technique for the treatment of primary and secondary liver cancer. Although  $^{90}\text{Y}$  was initially administered in whole liver or lobar fashion, more recently, segmental or subsegmental therapy is being offered, often with tumor ablative dosimetry. Moreover, a selective treatment helps minimize the nontarget irradiation of nondiseased liver parenchyma, which is associated with higher incidence of postinterventional liver decompensation,<sup>1</sup> especially in heavily pretreated patients with multiple lines of systemic therapy. Therefore, methods enabling the preservation of nondiseased liver are paramount in TARE with  $^{90}\text{Y}$ . Recently, we described the use of retrievable microvascular plugs (MVPs) for temporary vascular occlusion (TeVO) of nondiseased angiosomes during TARE.<sup>2</sup> In the current case, we report the use of an MVP (Medtronic plc, Minneapolis, MN, United States) to occlude temporarily nontarget vessels to protect healthy liver tissue during TARE with emphasis on the technique of TeVO.

## Case Study

### Presentation

A 97-year-old patient with recurrence of gallbladder cancer was referred to interventional radiology for locoregional liver therapy. She underwent an R1 resection surgery 19 months earlier. She had been treated with a combination of gemcitabine and cisplatin, which was interrupted due to toxicities and at the time of the referral she was off all systemic therapy.

Latest surveillance computed tomography (CT) demonstrated progression with local intrahepatic recurrence within the gallbladder fossa in segment V; no additional intrahepatic masses were identified. Overall, the patient was in good performance status (Eastern Cooperative Oncology Group [ECOG] score of 0). She denied any symptoms related to liver decompensation and the liver function panel was within normal limits. The possible options discussed were surgery, image-guided needle ablation, locoregional therapy such as transarterial chemoembolization or radioembolization, external radiation therapy, further systemic

DOI <https://doi.org/10.1055/s-0044-1778701>.  
ISSN 2457-0214.

© 2024. Indian Society of Vascular and Interventional Radiology. All rights reserved.

This is an open access article published by Thieme under the terms of the Creative Commons Attribution-NonDerivative-NonCommercial-License, permitting copying and reproduction so long as the original work is given appropriate credit. Contents may not be used for commercial purposes, or adapted, remixed, transformed or built upon. (<https://creativecommons.org/licenses/by-nc-nd/4.0/>)

Thieme Medical and Scientific Publishers Pvt. Ltd., A-12, 2nd Floor, Sector 2, Noida-201301 UP, India

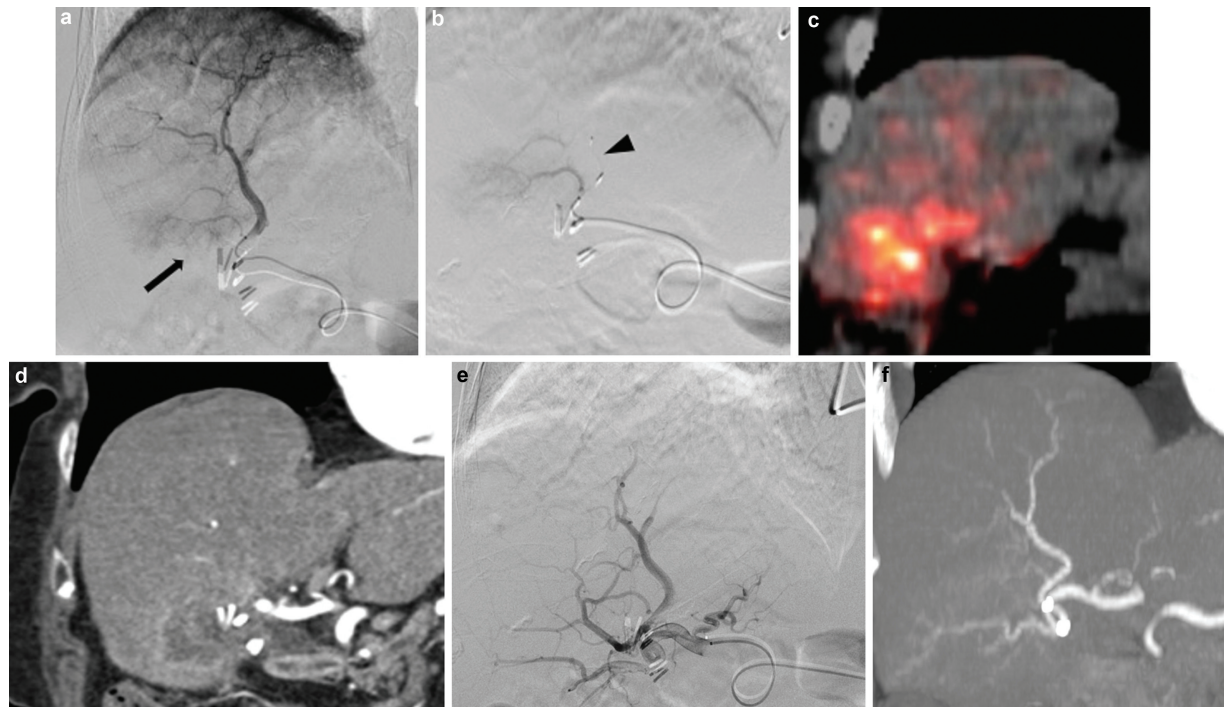
therapy, and conservative management with surveillance imaging.

After discussion with the referring service, and consulting with the patient and patient's family, the decision was made to proceed with subsegmental radioembolization to manage the focal, progressive liver disease.

### Procedure Description

The patient underwent a mapping angiographic evaluation of the liver, including cone-beam CT of the tumor supplying branches, and technetium-99m macroaggregated albumin ( $^{99\text{m}}\text{Tc-MAA}$ ) single-photon emission computed tomography (SPECT)/CT lung shunt study as part of her pretreatment workup. TARE was performed 1 week later under moderate sedation. Utilizing a right common femoral artery access, a short 6-Fr introducer sheath (Terumo Corporation, Tokyo, Japan) was placed, and the celiac artery was catheterized with a 5-Fr VS1 catheter (Cook Medical, Bloomington, IN, United States). A 2.8-Fr microcatheter (Progreat, Terumo Corporation) was used to select the segment VIII artery. A 5-mm MVP was deployed but not detached in the segment of the vessel that supplied the nondiseased liver parenchyma. The microcatheter was then pulled back in the proximal segment VIII vessel and a standard Y-adapter with hemostatic valve was attached to the end of the microcatheter using the previously described technique.<sup>2</sup> Distal occlusion and proximal flow redistribution into the parasitized tumoral branches of the segment VIII artery supplying tumor in

segment V (**Fig. 1a, b**) was achieved within 10 minutes as depicted on digital subtraction angiography. At this point, the  $^{90}\text{Y}$  delivery apparatus was set up per standard protocol to the delivery microcatheter.  $^{90}\text{Y}$  microspheres (Sirtex Medical, Woburn, MA, United States) were administered into the parasitized tumoral branches. Near the termination of the dose delivery, no further forward flow was seen within the parasitized tumoral branches and contrast was visualized flowing across the MVP, and the decision was made to terminate further administration. The MVP and the microcatheter were retracted as a single unit into the base catheter and disposed along with the dose vial. Due to the presence of additional tumoral branches arising from the segment V artery, a new microcatheter was used to catheterize the segment V artery and  $^{90}\text{Y}$  radioembolization was performed using a standard 2.4-Fr end-hole microcatheter (Terumo Corporation). Due to the small nondiseased volume in the segment V angiosome, TeVO was not utilized for distal protection. After the procedure,  $^{90}\text{Y}$  positron emission tomography (PET)/CT was performed demonstrating focal activity in the treated segment V and associated tumor volume within the gallbladder fossa. Minimal uptake was present in the MVP-protected superior right liver segments (**Fig. 1c, d**). The 20-mm voxel-based mean standardized uptake values (SUVs) for tumor, tumor-adjacent liver, and MVP-protected liver were 570, 233, and 60, respectively, resulting in 9.5:1 relative increased uptake in tumor: liver<sub>(MVP-protected)</sub> versus 2.4:1 relative increased tumor:liver<sub>(nonprotected)</sub> uptake.



**Fig. 1** (a) Digital subtraction angiography of the segment VIII artery demonstrating proximal parasitized flow to the tumor in segment V (arrow). (b) Digital subtraction angiography following deployment of a 5-mm microvascular plug (arrowhead) resulting in temporary distal vascular occlusion and proximal flow redistribution. (c) Yttrium-90 positron emission tomography with computed tomography (PET-CT) in coronal reconstruction and (d) preprocedure arterial phase coronal CT demonstrating increased uptake in the segment V tumor with minimal uptake in the protected angiosome. (e) Patent segment VII/VIII artery on digital subtraction angiography post-temporary vascular occlusion and (f) on 2-month follow-up coronal CT maximum intensity projection (MIP).



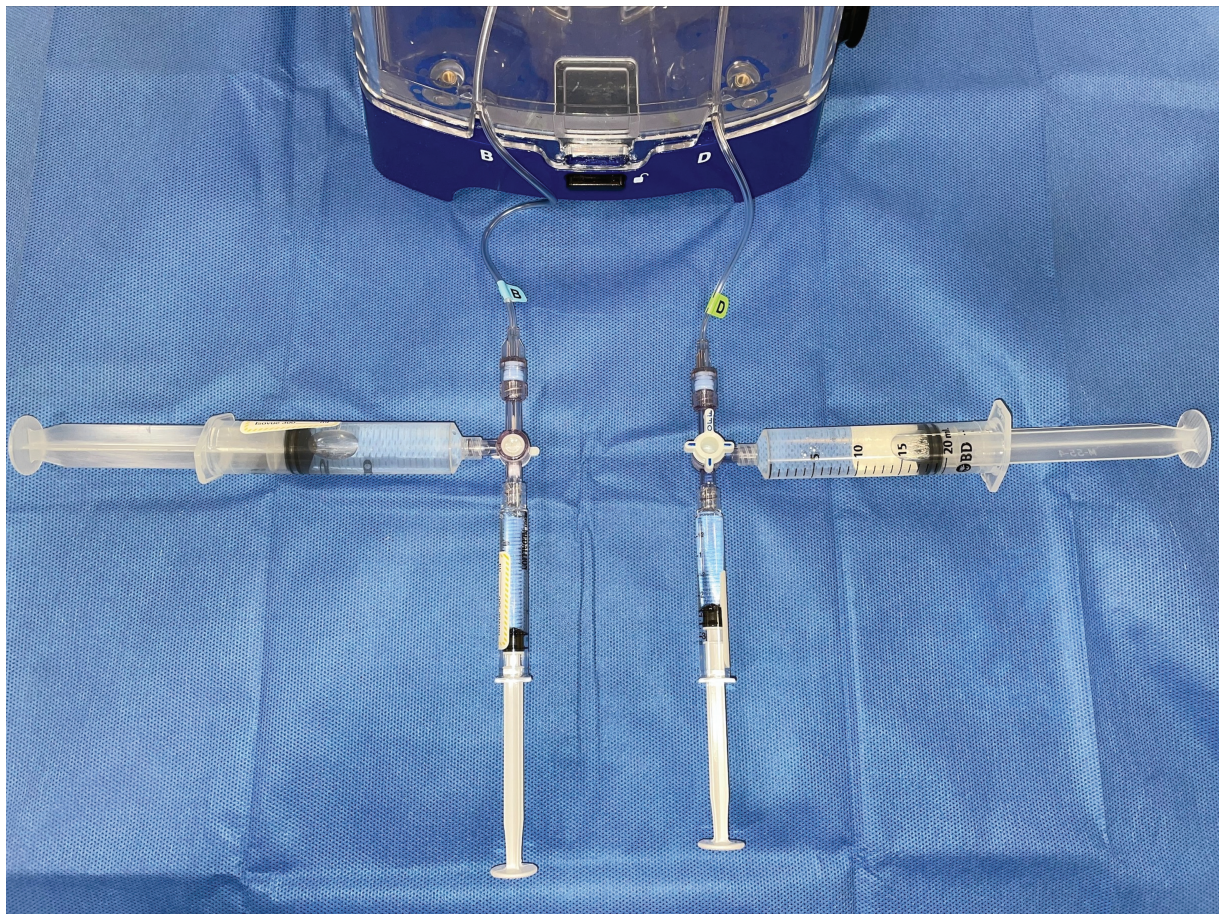## Discussion

Methods that are able to spare liver parenchyma during TARE have been described in the literature. These techniques mostly involve the injection of gelatin sponge slurry or degradable starch microspheres and/or use of a balloon catheter to temporarily occlude the vessel.<sup>3,4</sup>

The use of a retrievable MVP offers advantages compared to other embolic agents: the former can be deployed and retrieved several times during positioning and potentially preserves vessel patency for subsequent reintervention. In the case of degradable starch particles or flowable embolics, inadvertent embolization into the tumor feeders may result in unexpected occlusion of the treatment vessels requiring hours or days for particle degradation until the vessel is patent again to perform the radioembolization treatment. The technique of utilizing a balloon catheter to block the flow in the nontarget liver vessel and parallel placement of a microcatheter requires the use of a long 6- or 7-Fr introducer sheath within the hepatic artery, which can be difficult in cases of access vessel stenosis. In contrast, the technique we described can be performed with a 5-Fr base catheter using a single telescoping high-flow microcatheter. These aspects make the application of MVP-assisted TeVO more versatile when compared to other alternative strategies to spare liver parenchyma during radioembolization.

Currently, there are only two versions of the MVP (3 or 5 mm) that can be deployed using a microcatheter restricting its usage to smaller arteries during TeVO. Nevertheless, in vessels approaching the optimal occlusion size of the MVP, where complete occlusion is not possible, preferential flow redistribution may still occur, resulting in relative sparing of distal tissue. However, vessels equal to or larger than the sizing recommendations of the MVP should not be treated using this method as flow would not be slowed enough to offer any significant distal protection. With the addition of more sizing options, this technique may be useful in a larger range of vessel calibers. Due to the presence of the MVP delivery wire within the microcatheter, manual administration of the <sup>90</sup>Y microspheres may be difficult using larger-volume syringes. Hence, using lower-volume syringes and smaller aliquots of microspheres during loading and flushing of the microcatheter is recommended (► Fig. 2).

In our original case series, the MVP was recaptured by handling the noncontaminated external portion of the delivery wire outside of the closed Y-adaptor. In brief, without loosening the hemostatic valve on the Y-adaptor, one could still advance the microcatheter along the pinned delivery wire and minimize release and exposure of adherent microspheres as the potentially contaminated segment of the wire is pulled outside the Y-adaptor. The newly exposed “hot”



**Fig. 2** Syringe setup and configuration during microvascular plug (MVP) assisted temporary vascular occlusion (TeVO) for microsphere loading and flushing.

segment of wire was never directly manipulated and immediately covered with disposable towels. The recaptured MVP and microcatheter were then pulled into the base catheter, removed from the patient, and disposed of in the standard fashion. Once all devices were removed, postradiation monitoring was performed and no contamination was detected. In recognition of the potential for radiation contamination using the recapturing technique, subsequent cases are now done by retracting both the deployed/nondetached MVP and microcatheter as a unit into the base catheter without first recapturing the distal plug. In our experience, we have not seen any significant vessel compromise or nontreatable vasospasm following this maneuver, as demonstrated in this case (►Fig. 1e, f). At this time, we prefer this method of device disposal as it mitigates the possibility of contamination from exposing the involved segment of the delivery wire during recapture.

The use of proximal and distal occlusion devices during TARE has a theoretical risk of nontarget embolization of adherent radioactive microspheres as they are pulled back into the base catheter following <sup>90</sup>Y microsphere delivery. Despite the fact that microspheres come into contact with these occlusion devices during delivery, it is unclear if use of these devices has resulted in any known cases of clinically relevant intra- or extrahepatic <sup>90</sup>Y misadministration during the recapture step. Although similar concerns exist with the MVP, we have not experienced any extrahepatic deposition of <sup>90</sup>Y microspheres in our limited number of cases to date. MVPs are relatively expensive and may not be available in all medical centers. However, when available, the use of an MVP as a temporary occlusion device during <sup>90</sup>Y radioembolization may be justified in the setting of multiple split dose administrations requiring multiple delivery microcatheters and longer procedure/fluoroscopy times or for additional liver protection in patients with marginal liver function during segmental or subsegmental treatments.

In conclusion, MVP-assisted TeVO during <sup>90</sup>Y radioembolization of hepatic tumors is a useful technique in protecting

nondiseased liver angiosomes and potentially sparing hepatic function during sublobar, segmental, or subsegmental treatments.

#### Funding

J.J.P. is a proctor for Sirtex Medical, Inc., and medical advisory board member for Boston Scientific.

F.E.B. is a co-founder of Claripacs, LLC. He received research grants from Guerbet, Society of Interventional Oncology, Department of Defense, Thompson Family Foundation, Brockman Medical Research Foundation, and City of Hope. He received research support (investigator-initiated) from GE Healthcare. He received research supplies (investigator-initiated) from Boston Scientific. He is an investor in Labdoor, Qventus, CloudMedx, Notable Labs, Xgenomes, and Solugen. He is the inventor and assignee on U.S. patent 8233586.

#### Conflict of Interest

None declared.

#### References

- 1 Reincke M, Schultheiss M, Doppler M, et al. Hepatic decompensation after transarterial radioembolization: a retrospective analysis of risk factors and outcome in patients with hepatocellular carcinoma. *Hepatol Commun* 2022;6(11):3223–3233
- 2 Pedersoli F, Boas FE, Park JJ. Temporary vascular occlusion with retrievable microvascular plugs to protect normal liver during yttrium-90 radioembolization. *J Vasc Interv Radiol* 2023;34(06):978–982
- 3 Core JM, Frey GT, Sharma A, et al. Increasing yttrium-90 dose conformality using proximal radioembolization enabled by distal angiosomal truncation for the treatment of hepatic malignancy. *J Vasc Interv Radiol* 2020;31(06):934–942
- 4 Meyer C, Pieper CC, Ezziddin S, Wilhelm KE, Schild HH, Ahmadzadehfar H. Feasibility of temporary protective embolization of normal liver tissue using degradable starch microspheres during radioembolization of liver tumours. *Eur J Nucl Med Mol Imaging* 2014;41(02):231–237