



# Balloon-Assisted Stent Visualization: A Simple Technique for Precise Measurement of Previously Placed Stent Diameter

Manato Sakamoto<sup>1</sup> Shigeomi Yokoya<sup>1</sup> Hidesato Takezawa<sup>2</sup> Midori Ichihashi<sup>1</sup> Kengo Kishida<sup>1</sup> Hideki Oka<sup>1</sup>

<sup>1</sup> Department of Neurosurgery, Saiseikai Shiga Hospital, Imperial Gift Foundation Inc., Ritto, Shiga, Japan

<sup>2</sup> Department of Neurology, Saiseikai Shiga Hospital, Imperial Gift Foundation Inc., Ritto, Shiga, Japan

**Address for correspondence** Manato Sakamoto, MD, Department of Neurosurgery, Saiseikai Shiga Hospital, Imperial Gift Foundation Inc., Ritto, Shiga 520-3046, Japan (e-mail: mnt-skmt@koto.kpu-m.ac.jp).

Asian J Neurosurg

## Abstract

Stent-assisted coil embolization is effective for treating intracranial aneurysms, improving outcomes and reducing recurrence rates. However, accurately measuring the diameter of a previously placed stent during imaging can be challenging due to coil artifacts. This poses difficulties in determining the coil packing and size of additional stents needed during retreatment. In a reported case, the use of a balloon enabled precise assessment of stent deployment. A 50-year-old male with a history of basilar artery-left superior cerebellar artery aneurysm underwent coil embolization, direct clipping, and stent-assisted coil embolization (SAC) over a span of 14 years. However, the aneurysm showed reenlargement over time. To address the recurrence, a balloon was used to assess the previously placed Neuroform Atlas stent. Additional coils were inserted outside the stent, and a Low-profile Visualized Intraluminal Support Blue stent was added. Postoperatively, there were no new neurological issues, and a follow-up magnetic resonance imaging showed no ischemic lesions. Balloon-assisted stent visualization (BASV) may be a useful method in the retreatment of SAC. It has the potential to provide valuable information for treatment planning.

## Keywords

- ▶ balloon-assisted stent visualization (BASV)
- ▶ stent-assisted coil embolization (SAC)
- ▶ coil artifacts
- ▶ Super-Compliant balloon

## Introduction

Stent-assisted coil embolization (SAC) is known to be effective in the treatment of intracranial aneurysms.<sup>1</sup> It has shown improved therapeutic outcomes and reduced recurrence rates.<sup>2</sup> However, there are still cases that require retreatment. In cases where SAC was performed in previous treatments, accurately measuring the diameter of the previously placed

stent during imaging can be challenging due to the coil artifacts, even when using contrast medium. Therefore, determining how much to pack the coils and the size of additional stents during retreatment becomes problematic, as it depends on the position and expansion of the previously placed stent during the treatment planning.

Here, we report a case where the use of a balloon allowed for precise assessment of stent deployment.

DOI <https://doi.org/10.1055/s-0044-1779421>.  
ISSN 2248-9614.

© 2024. Asian Congress of Neurological Surgeons. All rights reserved.

This is an open access article published by Thieme under the terms of the Creative Commons Attribution-NonDerivative-NonCommercial-License, permitting copying and reproduction so long as the original work is given appropriate credit. Contents may not be used for commercial purposes, or adapted, remixed, transformed or built upon. (<https://creativecommons.org/licenses/by-nc-nd/4.0/>)

Thieme Medical and Scientific Publishers Pvt. Ltd., A-12, 2nd Floor, Sector 2, Noida-201301 UP, India

## Case Presentation

A 50-year-old male with a history of subarachnoid hemorrhage due to the rupture of a basilar artery-left (BA Lt.) superior cerebellar artery aneurysm 14 years ago. Coil embolization was performed as the initial treatment, but subsequent enlargement of the aneurysm was observed. Six years after the initial treatment, direct clipping was performed, followed by SAC 11 years later. During SAC, a Neuroform Atlas stent (4 mm × 21 mm; Stryker Neurovascular, Fremont, California, United States) was placed from the Lt. P1 segment to the BA trunk. Immediate postoperative angiography showed complete occlusion, but over time, re-enlargement of the aneurysm occurred.

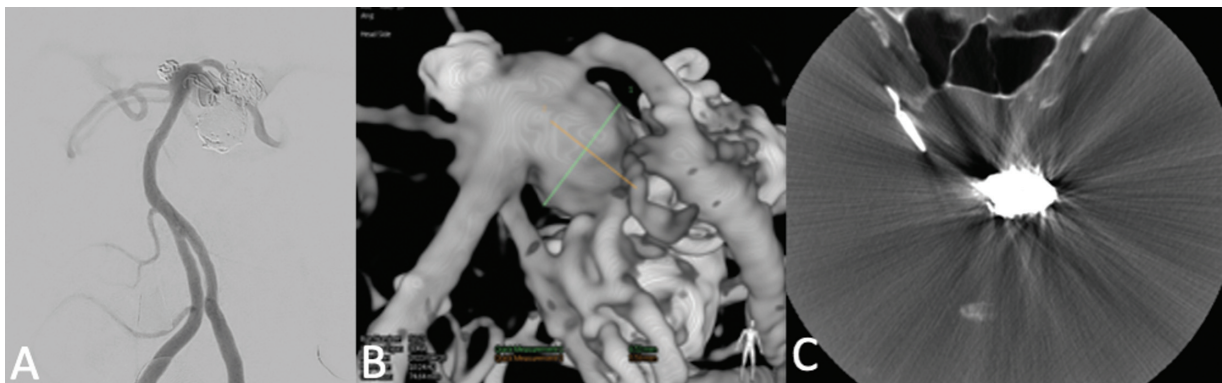
Two and a half years after the SAC, additional treatment was performed for the recurrent portion. Our angiography machine used was the Allura Clarity FD20/FD15 (Philips Healthcare) and the contrast agent we used was Iopamidol 300. However, it was unclear how the previously placed Neuroform Atlas stent in the Lt. P1 to BA trunk was deployed (▶Fig. 1). To assess the deployment of the stent, a balloon (SHOURYU HR 7 mm × 7 mm; Kaneka, Osaka, Japan) was navigated into the Neuroform Atlas stent (▶Fig. 2A) and

expanded. The balloon closely adhered to the lumen of the stent, allowing visualization of the stent's shape (▶Fig. 2B) and measurement of its size (▶Fig. 2C). Based on the measurements, additional coils were filled in the aneurysm outside the stent, and a Low-profile Visualized Intraluminal Support (LVIS) Blue stent (4.5 mm × 18 mm; MicroVention Inc, Tustin, California, United States) was placed as an additional stent. The treatment was completed with complete occlusion. Postoperatively, there were no new neurological abnormalities, and a head magnetic resonance imaging performed on the following day showed no ischemic lesions.

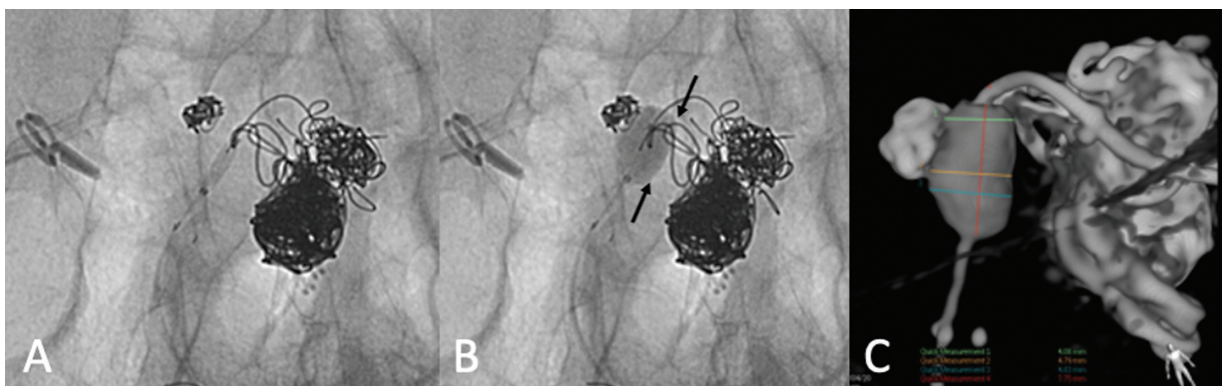
## Discussion

In this case, it was unclear how the Neuroform Atlas (4 mm × 21 mm) stent placed in the Lt. P1-BA trunk was deployed during the additional treatment after SAC. By introducing and expanding a balloon (SHOURYU HR 7 mm × 7 mm) into the Neuroform Atlas, the balloon adhered to the stent lumen, allowing visualization of the stent shape based on the balloon's form, and enabling size measurements.

From this case, several points were elucidated. The use of a balloon provides a simple method for visualizing the stent.



**Fig. 1** (A) In the right vertebral artery angiography, only the visibility markers of the previously placed Neuroform Atlas stent could be seen. (B) In three-dimensional (3D) rotational angiography (3DRA), measuring the size of the Neuroform Atlas stent was difficult due to the influence of the contrast agent filling the vessel. (C) In VasoCT (using a 10-fold diluted contrast agent), the stent diameter of the implanted Neuroform Atlas could not be measured due to artifacts caused by the surrounding coil mass.



**Fig. 2** (A) A balloon (SHOURYU HR 7 mm × 7 mm) was introduced into the lumen of the previously placed Neuroform Atlas during the prior treatment. (B) Upon inflation within the stent, the balloon intimately adhered to the luminal surface of the stent (indicated by the arrow), enabling visualization of the stent's configuration based on the form of the balloon. (C) By measuring the diameter of the expanded balloon, it was possible to estimate the configuration and diameter of the deployed stent.

The balloon used in our method is the same as that used for arterial embolization procedures, requiring no special preparations or techniques. Previous reports have suggested that cone-beam computed tomography is useful for assessing the deployment of previously placed stents during retreatment,<sup>3,4</sup> and advancements in angiographic imaging technology, such as the reduction of coil mass artifact, have improved stent visibility. However, in cases involving large aneurysms, there are still situations where the status of the deployed stent remains unclear.<sup>5</sup> Consequently, treatment decisions for additional stents or coils are often based on empirical size selection without accurately assessing the diameter of the deployed stent, potentially increasing the risk of complications such as thrombosis.

For this purpose, it is preferable to use a balloon made of a soft material. The balloon used in this case was a Super-Compliant balloon, commonly used as a remodeling technique during arterial embolization procedures. It is extremely soft and expands while fitting to the surrounding structures. In this instance, we used a 7-mm balloon instead of a 4-mm one, as the size of the implanted Neuroform Atlas stent was 4 mm, and there was a possibility that it had expanded up to a maximum of 4.5 mm. However, during the expansion, meticulous care was taken to prevent overexpansion and potential damage to the parent vessel. By using this balloon, it was possible to accurately assess the size and shape of the stent without causing damage or disruption to the stent.

The method reported in this study is utilized when retreatment is being considered for cases where an intracranial stent was previously placed. Neuroform Atlas is an open-cell stent with variable diameters upon deployment, making it particularly useful in cases of fusiform or wide-neck aneurysms where the exact deployment of the stent is unclear.

However, there are some drawbacks to using a balloon. It temporarily occludes the parent vessel, posing a risk of embolism. Additionally, overexpansion of the balloon may cause stent damage or result in the balloon getting caught in the stent struts, potentially leading to balloon rupture or displacement of the stent's position. Caution is required in these situations.

We selected the LVIS Blue stent as an additional stent, opting for it due to its closed-cell structure and with the expectation of achieving a flow diverter effect. Previous reports have indicated the effectiveness and safety of treatments that involve placing a different type of closed-cell stent within an open-cell stent, with the expectation of additional effects.<sup>6</sup>

In conclusion, visualizing the degree of stent deployment during retreatment in SAC has been challenging. However, using a balloon for stent visualization may provide a solution to this problem.

## Conclusion

Balloon-assisted visualization of stents may be a useful method in the retreatment of SAC. It has the potential to provide valuable information for treatment planning.

### Ethical Approval Statement

This study was approved by the ethics committee of our hospital (Approval Number: 586).

### Informed Consent

We obtained written informed consent from the patient for the publication of this case report and accompanying images.

### Authors' Contributions

M.S., S.Y., and H.T. contributed to study conception and design. M.S. helped in data collection as well as analysis and interpretation of results. M.S., and S.Y., contributed to draft manuscript preparation. All authors (M.S., S.Y., H.T., M.I., K.K., H.O.) reviewed the results and approved the final version of manuscript.

### Funding

None.

### Conflict of Interest

None declared.

## References

- Lynch J, Sciacca S, Siddiqui J, Kanagarajah L, Derakhshani S. Safety and efficacy of the Neuroform Atlas stent for treatment of intracranial aneurysms : a systematic review and meta-analysis. *Clin Neuroradiol* 2021;31(04):1167–1180
- Mine B, Aljishi A, D'Harcour JB, Brisbois D, Collignon L, Lubicz B. Stent-assisted coiling of unruptured intracranial aneurysms: long-term follow-up in 164 patients with 183 aneurysms. *J Neuroradiol* 2014;41(05):322–328
- Richter G, Engelhorn T, Struffert T, et al. Flat panel detector angiographic CT for stent-assisted coil embolization of broad-based cerebral aneurysms. *AJNR Am J Neuroradiol* 2007;28(10):1902–1908
- van der Bom IMJ, Hou SY, Puri AS, et al. Reduction of coil mass artifacts in high-resolution flat detector conebeam CT of cerebral stent-assisted coiling. *AJNR Am J Neuroradiol* 2013;34(11):2163–2170
- Patel NV, Gounis MJ, Wakhloo AK, et al. Contrast-enhanced angiographic cone-beam CT of cerebrovascular stents: experimental optimization and clinical application. *AJNR Am J Neuroradiol* 2011;32(01):137–144
- Liu XL, Wang B, Zhao LB, Jia ZY, Shi HB, Liu S. Overlapping stents-assisted coiling for vertebral artery dissecting aneurysm: LVIS stent within Neuroform EZ stent. *J Korean Neurosurg Soc* 2022;65(04):523–530