



# Masculinization of the Chest in Transmen with Large Breasts

Thalaivirithan Margabandu Balakrishnan<sup>1</sup> Shramya Shodhan Kumar<sup>1</sup> M. Aruchamy<sup>2</sup>  
U. Rasheedha Begum<sup>1</sup> M. Sridharan<sup>1</sup>

<sup>1</sup>Department of Plastic, Reconstructive, Facio-maxillary, Aesthetic Surgery, Madras Medical College, Chennai, Tamil Nadu, India

<sup>2</sup>Department of Plastic Surgery, PSG Institute of Medical Sciences and Research, Coimbatore, Tamil Nadu, India

**Address for correspondence** Thalaivirithan Margabandu Balakrishnan, MBBS, MS, MS, DNB, FRCS(E), MCh, DNB, Old no.15, New no.10, Thiruvallur Street, NTR Road, Rangarajapuram, Kodambakkam, Chennai 600024, Tamil Nadu, India (e-mail: thalaiviri.b@gmail.com).

Indian J Plast Surg

## Abstract

**Background and Objectives** Surgery to masculinize the chest is a frequently sought-after procedure by transmen who wish to conform their physical appearance to their gender identity. In our study, the outcomes of surgical masculinization comprising subcutaneous mastectomy through a modified elliptical incision, liposuction, reduced inert nipple–areola grafting, and quilting stitches were analyzed.

**Materials and Methods** Thirty-two transmen with large breasts and hypertrophied nipples and areolae underwent the above-mentioned masculinizing procedure in this prospective cohort study. Our statistically validated institutional aesthetic outcome assessment score (IAOAS) was used to analyze the outcomes at the end of the follow-up period.

**Results** The average period of follow-up was 24.5 months. The average final IAOAS was 23.1. The rate of complications was found to be associated with using breast binders. In all, 22 of 32 patients (68.75%) had an excellent outcome score, while 10 patients (31.25%) had a good outcome score ( $p = 0.025$ ).

**Conclusion** Top surgery is crucial for transmasculine patients to achieve their desired gender identity as males. It is imperative that this procedure is performed to their complete satisfaction. Our single-staged comprehensive approach of subcutaneous mastectomy and liposuction with reduced inert nipple and areola grafts, which aids in a swift transition to a male role, is a prerequisite for bottom surgery at our institute.

## Keywords

- ▶ transgender
- ▶ transmen
- ▶ free nipple–areola grafting
- ▶ mastectomy
- ▶ adjunctive liposuction
- ▶ top surgery
- ▶ masculinization

## Introduction

Gender dysphoria refers to an individual's incongruence between the phenotypic sex and perceived gender.<sup>1,2</sup> Masculinizing the female chest in transmen is a significant phenotypic change to enhance and physically align them with their perceived male sex. In our institute, this is the first and most sought-after surgery for all assigned female at birth (AFAB)

individuals. Aesthetically executed masculinization of the chest boosts the self-image and morale of a transgender man, which augments their confidence and involvement in undergoing subsequent bottom surgery. In addition, it gives immense relief from breast binders and their related complications. Hormonal therapy in transmen does not bring enough atrophy and involution of the breast. So, all of them require a surgical intervention to masculinize the chest. We use a

DOI <https://doi.org/10.1055/s-0044-1779481>.  
ISSN 0970-0358.

© 2024. Association of Plastic Surgeons of India. All rights reserved. This is an open access article published by Thieme under the terms of the Creative Commons Attribution-NonDerivative-NonCommercial-License, permitting copying and reproduction so long as the original work is given appropriate credit. Contents may not be used for commercial purposes, or adapted, remixed, transformed or built upon. (<https://creativecommons.org/licenses/by-nc-nd/4.0/>)  
Thieme Medical and Scientific Publishers Pvt. Ltd., A-12, 2nd Floor, Sector 2, Noida-201301 UP, India

combination of liposuction and subcutaneous mastectomy with reduced inert nipple-areola grafting to eliminate feminine features in transmen with well-developed large breasts despite hormonal therapy. Adjunct liposuction targets the axillary tail of the breast and the inferolateral border of the pectoralis major (PM), potentially resulting in a more masculine chest in transmen. The outcome of this surgical procedure is evaluated in this prospective cohort study.

## Materials and Methods

The Institutional Scientific and Ethical Committee approved the study (11/2015). Informed consent was obtained from all patients to use clinical materials, such as photographs and videos, for research and publication. From March 2015 to March 2021, 32 transmen (► **Table 1**) with large breasts (B and C cups<sup>2</sup> with hypertrophied nipples and areolae)

**Table 1** Patient data

Sl. no.	Age (y)	Breast cup size	Follow-up period (mo)	Duration of breast binder usage (y)	Quality of breast skin	Institutional aesthetic outcome assessment score (IAOAS)	Complications
1	24	B	30	1	GQS	22	Nil
2	22	B	18	0.75	GQS	22	Nil
3	23	C	24	9	TAI	20	Nil
4	23	C	18	7.5	TAI	21	Nil
5	35	B	24	5	TAI	22	Nil
6	34	C	24	6	TAI	20	Nil
7	18	B	18	0.5	GQS	21	Nil
8	19	C	30	4	TAI	23	Nil
9	29	B	24	2	TAI	22	Nil
10	26	C	24	6	TAI	22	Nil
11	29	B	24	10	TAI	19	Mild seroma
12	33	B	18	2	TAI	22	Nil
13	29	C	30	12	TAI	19	Hypertrophic scar, hypopigmentation of free nipple-areola graft
14	29	C	30	6.5	TAI	21	Nil
15	22	C	30	6	TAI	20	Nil
16	19	C	24	2	TAI	22	Nil
17	25	C	24	3	TAI	23	Nil
18	39	C	30	4	TAI	23	Nil
19	26	B	30	1.5	TAI	23	Nil
20	21	B	18	0.25	GQS	21	Nil
21	28	B	30	4	TAI	22	Nil
22	20	C	30	2	TAI	21	Nil
23	28	C	24	2.5	TAI	20	Nil
24	24	C	24	5	TAI	19	Mild seroma
25	23	C	18	2.5	TAI	21	Nil
26	28	C	24	3	TAI	20	Nil
27	24	C	24	4	TAI	22	Nil
28	19	B	18	0.5	GQS	20	Nil
29	28	C	24	12	TAI	19	Hypertrophic scar, hypopigmentation of free nipple-areola graft
30	35	C	24	3	TAI	21	Nil
31	27	B	30	2	TAI	21	Nil
32	22	C	24	2.5	TA	22	Nil

Abbreviations: GQS, good quality skin; TAI, thin, atrophic inelastic skin.

**Table 2** Institutional Aesthetic Objective Assessment Score System (IAOAS)

	I	II	III	IV
Stigmata of IMF	Prominently seen with the residual breast tissue	Lateral half of IMF seen evidently	Lateral half of IMF seen evidently	Lateral half of IMF not seen
NAC	Absent	Large, deformed	Mildly deformed	Symmetrical
Axillary tail of Spence	Evidently seen	Moderately visible	Mildly visible	Not seen
Scar	Hyperpigmented, hypertrophied, stretched	Moderately visible, stretched scar	Mildly visible, hyper-/hypopigmented	Pencil-line scar
Sensation and color of the NAC at the end of follow-up	Hypersensitivity/complete insensitivity, hypopigmented NAC	Moderately insensate, mild color change of NAC in few quadrants	Mildly insensate, negligible color change of the NAC	Good sensation, good retention of the color of the NAC
Definition of PM	Poorly defined	Mildly good definition	Moderately good definition	Good definition

Abbreviations: IMF, inframammary fold; NAC, nipple–areola complex; PM, pectoralis major.

Score:

Maximum score: 24; minimum score: 4.

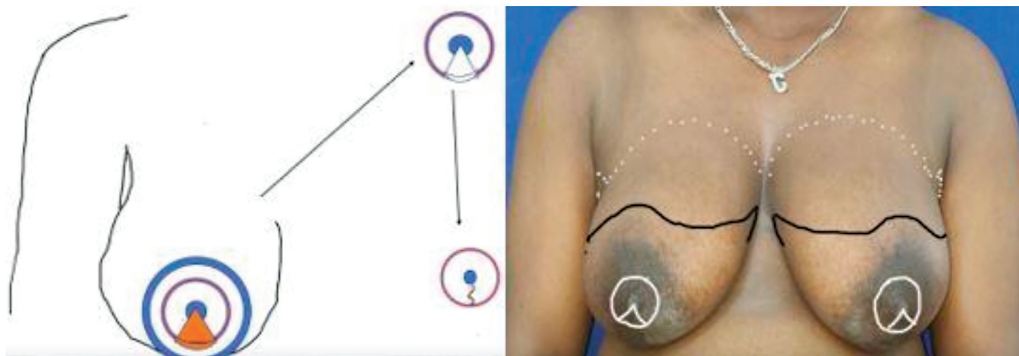
21–24: excellent; 18–20: good; 14–17: fair; <14: poor.

underwent liposuction, subcutaneous mastectomy with inert reduced nipple–areola grafting. Those included in this prospective cohort study were selected based on the following three criteria formulated by the joint group of transgender clinic of our institution, which are partly modified from the factors given by the World Professional Association for Transgender Health<sup>3</sup>: (1) persistent, well-documented gender dysphoria for more than 5 years; (2) good cognition and ability to make a fully informed decision and to consent for surgery; and (3) age  $\geq 18$  years. The following transmen were excluded from the study: those with comorbidities like diabetes mellitus, history of smoking, deep-seated mental disturbances, poor prospectus for follow-up, and clinical pathology and radiological studies suggestive of breast pathologies. Those transmen with A cup wherein different techniques were followed were excluded from the study. Hormone therapy is not mandatory for inclusion in our study. Competent mental health professionals assessed all the patients before performing the procedure. They analyzed the diathesis for gender dysphoria, the effects of societal stigma on psychosocial adjustment, and the support system available to the patient.<sup>3</sup> They certified mental fitness to undergo top surgery. Physicians and endocrinologists ruled out significant comorbidities and standardized their hormonal therapy. For all transmen, as per the protocol

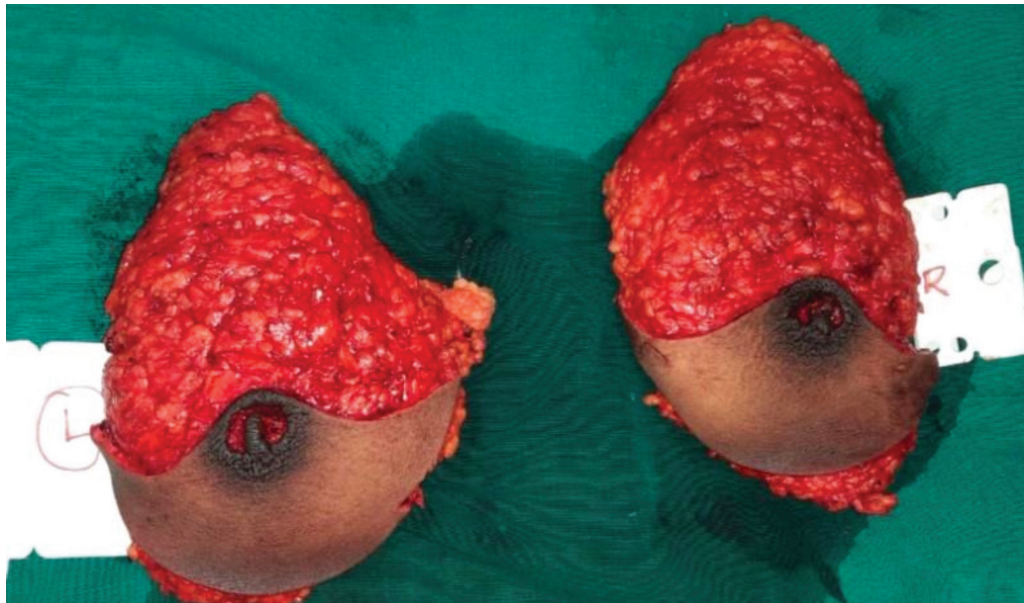
of our institute, this is the first surgical intervention that helps align them with their perceived sex. Our institutional aesthetic outcome assessment score (IAOAS; **Table 2**) analyzed all the patients at the end of the follow-up.

### Surgical Technique

Preoperatively, patients were discontinued from hormonal therapy 4 weeks before the proposed surgical intervention. All patients who were included in this study had used breast binders; therefore, the following characteristics of skin were critically assessed: elasticity, thickness, stretchability, and the presence of stretched striae. With the patient in the standing posture and arms by the side, the upper and lower markings of the elliptical incision were made. The lateral end of the elliptical incision was slightly deviated toward the axillary tail and not carried beyond the midaxillary line. The medial and lateral ends of the elliptical incisions were marked subtending not more than 30 degrees to avoid cone formation (**Fig. 1**). In those patients with prominent axillary breasts ( $n=3$ ), the lateral apex of the elliptical incision is centered over that to give access during the excision. By removing all the loose skin, approximation of the upper and lower markings of the incision was assessed through breast tissue. The presence of loose skin prompted



**Fig. 1** (Left) Schematic diagram showing the technique of reduction of nipple–areola complex (NAC) with a cookie cutter and triangular wedge resection. (Right) Marking on the NAC with a cookie cutter and triangular wedge resection.



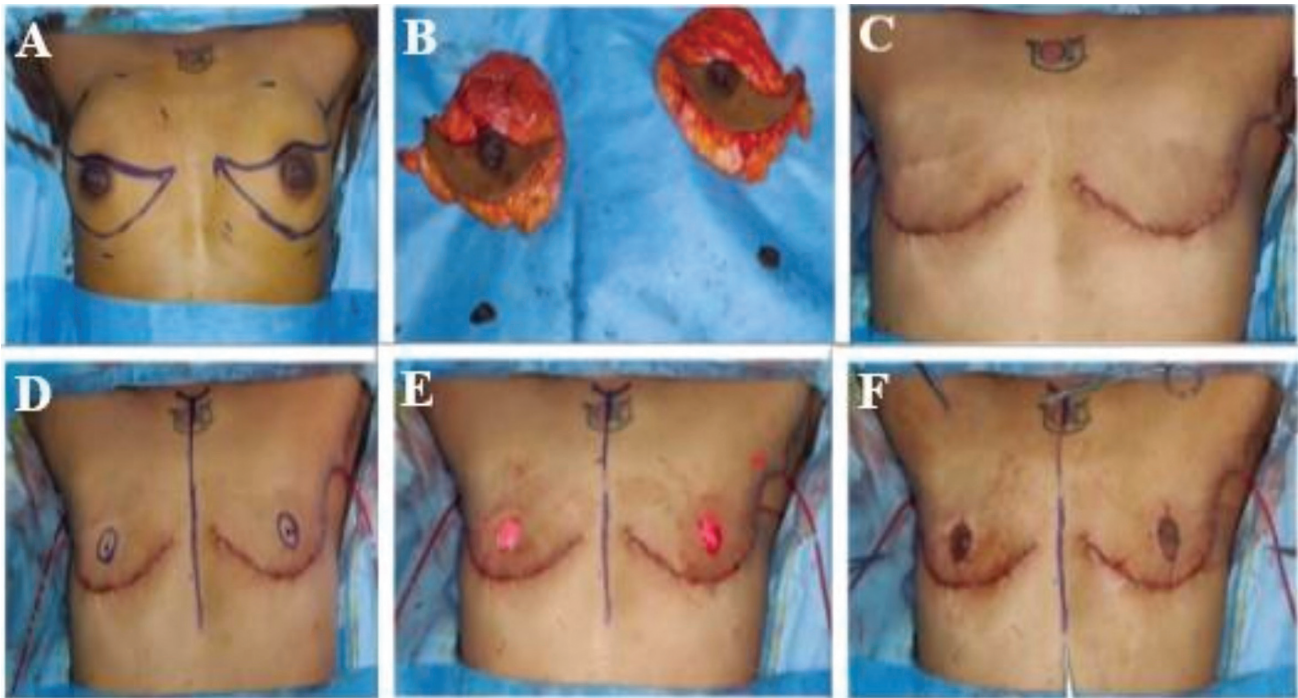**Fig. 2** Showing the excised specimen with residual nipple–areola complex (NAC) after harvesting the reduced free NAC graft.

the alteration of the upper marking, which was steered upward. The lower incision was always placed in the apex of the inframammary fold (IMF), encircling the inferior confinement of the breast tissue (►Figs. 1 and 3A). The areas of excess fat along the anterior axillary fold and upper portion of the inferolateral border of the PM were marked for liposuction. Skin fold thickness over the infraclavicular region was assessed by a pinching test that would guide the thickness of the superior flap to be raised. The breast tissue's superior, medial, and lateral boundaries were marked by interrupted lines.

All the patients were operated on under general anesthesia with the patient in the supine position, and both arms abducted at 90 degrees. The marked incision lines for subcutaneous mastectomy were infiltrated with 1:200,000 adrenaline-saline solution. A liposuction cannula was introduced through a small stab incision between the anterior and midaxillary lines (within the upper and lower marking of excision), and excess subcutaneous fat was sucked out from the anterior axillary fold while carefully protecting the axillary neurovascular bundle. In patients with poor skin quality, the tip of the liposuction cannula was directed parallel to the skin to avoid contusion and subsequent dermal vascular insufficiency. Using a cookie cutter with a 1.5- to 2-cm diameter and stretching the nipple–areola complex (NAC), a circular marking was made centered over the nipple (►Fig. 1). A cone-shaped marking was then made with the apex over the center of the nipple and base equaling three-eighths the circumference of the cookie cutter marking, and this was the excess of the NAC that would be left behind on the excised specimen (►Fig. 1). The NAC was harvested, leaving the excess nipple core and areola on the breast (►Figs. 2, 3B). The undersurface of the harvested NAC was thinned out (along the line of full-thickness skin graft), reduced, and reconstructed using a 5–0 Poligle-caprone suture (►Fig. 3B) and placed in cold saline. First, the

upper incision was deepened to the planned depth, and the plane was developed between the superior skin flap and the glandular tissue. This step was critical in avoiding a “dish deformity” that could occur if excess globular fat was removed from the flap. On the other hand, if excess globular fat was left behind, it produced an irregular bulging deformity. The superior flap was carried up to the breast tissue's superior, medial, and lateral boundaries. The inferior incision was deepened to the serratus anterior fascia and rectus sheath. Retro-glandular dissection was performed in a relatively avascular loose areolar tissue plane, leaving behind the serratus anterior fascia and fascia over the PM. The inferior flap was raised by releasing all skin tethering ligaments for approximately 1.5 cm. The excess of elliptical breast skin with all the breast tissue was removed (►Fig. 3B). After achieving complete hemostasis, skin staplers were used to approximate the wound edges with windows, which permitted later quilting stitches and also this maneuver facilitated checking the symmetry and positioning of the neo-NAC. The inferolateral border of the PM was marked on the upper skin flap. The deep globular fat was trimmed along the marking of the inferolateral border of the PM. Quilting stitches were taken with 2–0 delayed absorbable suture material to exaggerate the contour of the inferolateral border of the PM and subdermal fat tissue. After placing a suction drain, layered closure (►Fig. 3C) was performed with deep layered splinting, with delayed absorbable suture material and 4–0 Poliglecaprone acid suture for subcuticular skin closure to get a thin pencil-line scar. The unequal wound edges, which invariably happen, were adjusted with differential bites during closure. Now, using the same cookie cutter, the sites of neo-NACs were marked symmetrically at the junction of the inferolateral border of the PM and the fourth intercostal space on the upper skin flap (►Fig. 3D). The symmetry of the NAC was assessed by breaking the table and looking from the foot end of the operating table (►Fig. 3D).





**Fig. 3** (A) Markings of elliptical incisions for bilateral (B/L) subcutaneous mastectomy and liposuction. (B) Excised breast specimens with harvested reduced free nipple-areola grafts. (C) Closure of mastectomy incisions. (D) Marking for de-epithelialization for neo-NAC. (E) De-epithelialized skin for neo-NAC. (F) Fixed B/L reduced inert NAC graft.

De-epithelialization was done in the marked area of neo-NAC (► **Fig. 3E**), and after achieving hemostasis, the reduced free nipple-areola graft was sutured edge to edge with 5-0 Poliglecaprone (► **Fig. 3F**). A compressive dressing was applied.

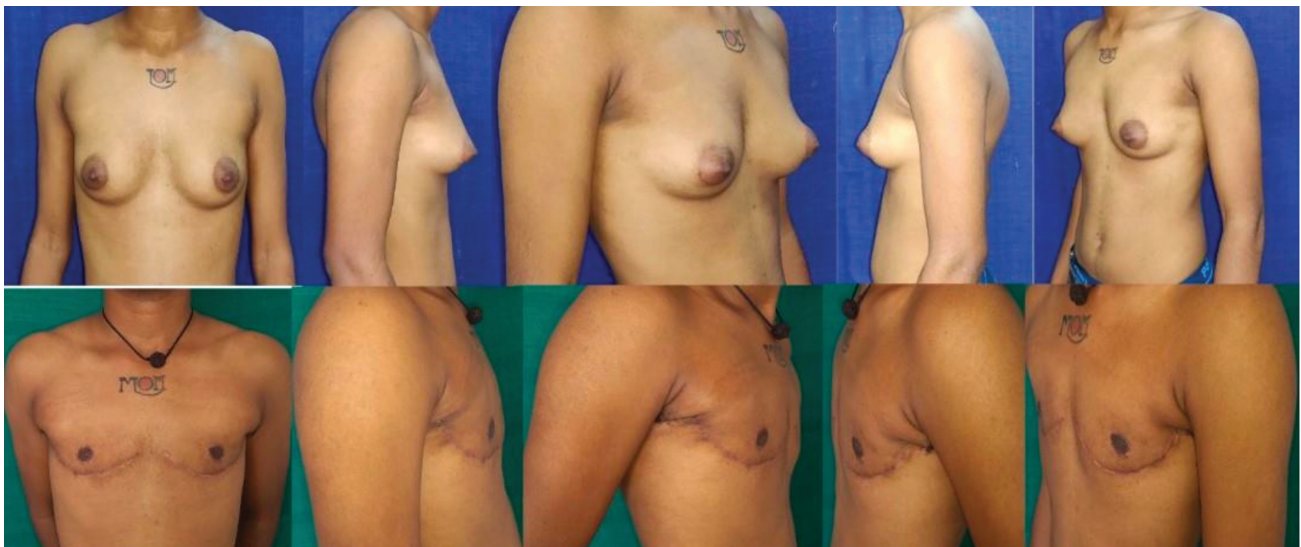#### Postoperative Care

The next day, the dressing was changed, and the vitality of the flaps was evaluated. The drains were removed on the 7th to 10th post-op day. With padding over the NAC, compressive garments were worn for a period of 2 to 3 weeks. The patients were followed up at monthly intervals. At the end of the

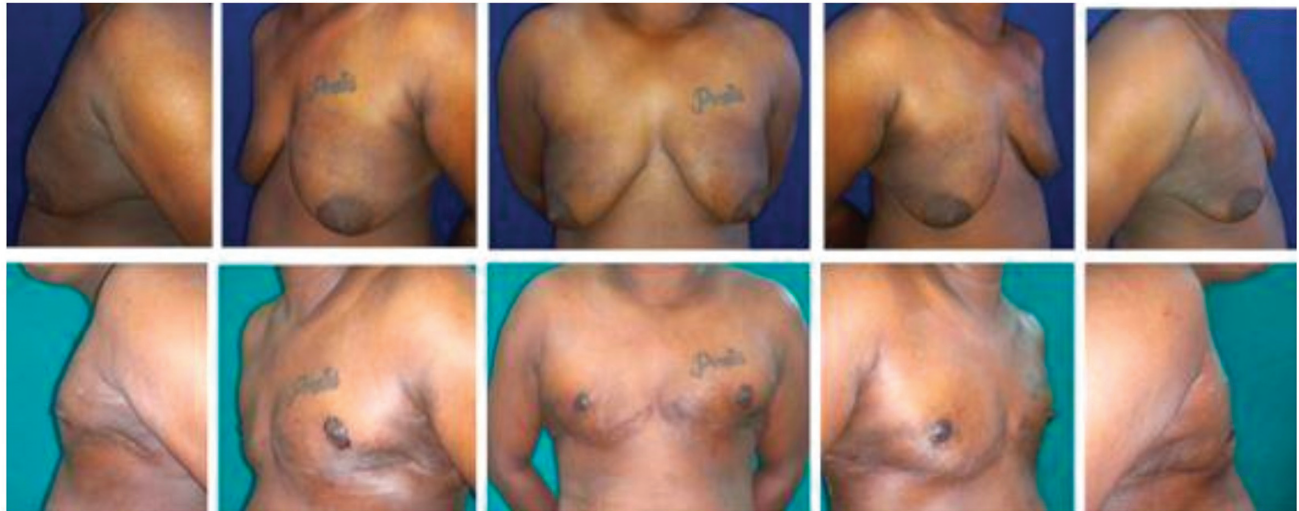follow-up, two independent observers assessed the patients with IOAS (► **Table 2**), and the final computed average score was obtained and recorded for analysis. Immediate, early, and late postoperative complications were recorded. After 10 weeks, patients were advised to do PM resistance exercises to maintain their masculinized chest contour.

#### Illustration of Case 1

A 21-year-old transman came to the transgender clinic and opted for top surgery as the first gender-confirming surgery (► **Fig. 4**). The patient gave a history of cross-dressing for 8 years and using breast binders for the past 3 months. On



**Fig. 4** Preoperative and late postoperative photographs of case 1.



**Fig. 5** Pre- and postoperative photographs of case 2.

examination, the patient had a B cup breast size with a hypertrophied NAC, surplus fat over the anterior axillary fold, well-defined axillary tail, and good-quality skin. The patient was assessed in the multispecialty integrated transgender clinic for suitability of top surgery. The patient had undergone a combination of liposuction, subcutaneous mastectomy, and free, reduced nipple–areola grafting. The patient had an uneventful postoperative recovery. The patient was followed up for 18 months with a final computed IAOAS score of 21.

### Illustration of Case 2

A 24-year-old transman (►Fig. 5) with history of cross-dressing for 12 years and breast binders for 5 years presented to the transgender clinic for top surgery. There were no known acute/chronic medical illnesses. The patient had a C cup breast with ptosis and large, hypertrophied NAC. The patient had thin, atrophic, inelastic skin with color changes due to the chronic usage of breast binders. The patient had undergone liposuction, subcutaneous mastectomy, and inert, reduced NAC grafting. In the early postoperative period, the patient developed a seroma on the left side after the accidental avulsion removal of the drain on the fourth day. The patient recovered with needle aspiration and appropriate antibiotics. After this, the patient had an uneventful healing (►Fig. 5). At the end of the follow-up period of 24 months, the patient had an IAOAS of 19.

### Results

The average age of the transmen in our study was 25.9 years (►Table 1). The age ranged from 18 to 39 years (►Table 1). The average body mass index (BMI) of the patients was 23.5. The number of patients in the B cup group was 12 (37.5%). The number of patients in the C cup group was 20 (62.5%). The average duration of breast binder usage in our study was 4.2 years. The average operating time was 175 minutes. The average period of follow-up was 24.5 months. The average final IAOAS was 23.1. In all, 68.75% ( $n = 22$ ) patients had an

excellent outcome score ( $p = 0.025$ ) and 31.25% ( $n = 10$ ) patients had a good outcome score. Two (6.25%) patients had mild seroma collection and two (6.25%) patients had hypertrophic scar and hypopigmentation of the NAC. The overall complication rate in our study was 13%, and all these were managed conservatively, except for the case 2 patient as mentioned earlier. The complication of stretched/hypertrophic scar, as shown by the regression analysis study, is closely correlated with breast binder usage and poor preoperative skin quality. Five patients had good-quality skin and 27 patients had thin, inelastic atrophic skin. The average duration of breast binder usage in those with good-quality skin was 0.6 years and that in thin, inelastic skin was 4.7 years. None of our patients required any revision surgeries. The agreement between two independent observers was evaluated by the kappa coefficient for each single item of IAOAS (►Table 2). Bland and Altman plot analysis assessed the coefficient of repeatability. The Cronbach  $\alpha$  test evaluated the internal consistency. The final computed score of IAOAS was analyzed by the chi-squared test.<sup>4</sup>

### Discussion

To date, there is a paucity of literature on the surgical masculinization of the chest in transmen. Although there is a common claim that this surgery is similar to subcutaneous mastectomy for cancer resection, multiple innuendos must be practiced to get the best aesthetic outcome during the masculinization procedure.<sup>5</sup> The following are the salient technical features of masculinization in our patients: (1) Complete removal of the breast tissue with redraping of the superior flap without any loose skin; (2) complete eschewing of the IMF stigmata (by cutting, dissecting all skin-tethering ligaments, and undermining the lower flap for 1.5 cm in the suprafascial plane); (3) fully define the PM contour at the anterior axillary fold and all along its inferolateral border by combining liposuction, directed least dissection, and quilting stitches. The flaps and skin closure are adjusted in such a way that the resultant scar becomes less perceptible (the medial



three-fourths of the scar following the contour of PM, lateral one-fourth of the scar in the lower part of the hollow of the axilla); (4) ideally positioning the reduced free nipple–areola graft with symmetry with proper shape and size; (5) reducing and thinning the NAC along the line of full-thickness skin graft and facilitating the uptake as a free graft over the de-epithelialized site of the upper skin flap; (6) complete removal of the axillary tail of the breast with the directed liposuction and least directed dissection; (7) in the presence of thin, atrophic, inelastic skin, maintaining the correct plane of dissection to have adequate thickness of the upper flap to prevent “dish deformity” or necrosis and irregular bulge; (8) maintenance of the PM fascia and serratus anterior fascia to reduce the incidence of seroma collection; (9) depending upon the quality of the skin, the upper incision has to be modified by steering away from the classical elliptical incision to avoid loose, excess skin (a deformity that mandates another surgery). The extremes of the modified elliptical incision must subtend less than 30 degrees<sup>6</sup> to avoid any cone deformity. At the same time, differential bites are required to adjust and approximate unequal wound length. (10) Layered suturing with deep layered splinting with delayed absorbable suture material promotes a thin scar. One large relatable study by McEvenue et al<sup>7</sup> used the keyhole and double-incision free nipple graft (DIFNG) mastectomy techniques, but there was no usage of liposuction and PM contour-defining techniques. In our study, we used a combination of liposuction, least directed dissection, and quilting stitches for defining the PM contour, and we also encouraged them to postoperatively perform PM-resistant strengthening exercises, which add to the accentuation of the contour. Their average aesthetic outcome was comparable to our study. There were no data on the usage of breast binders and their implications in the surgical technique. However, in our study, we have analyzed the significant impact caused by the poor skin quality resulting from the chronic usage of breast binders. We also confined our study to the large breast size and analyzed the effectiveness of our surgical technique. According to Ammari et al,<sup>8</sup> mastectomy with free nipple graft is the most commonly employed procedure in this patient population. Attention to atraumatic surgical technique, elimination of contour irregularities and standing cone deformities, and meticulous wound closure are most important. We concur with their finding, as our surgical technique is the mainstay in facilitating excellent outcomes for most of our patients. Knox et al<sup>9</sup> used the circular concentric technique in the low BMI and small breast group. This technique resulted in many deformities, envisaging correction surgeries. In our study, the modified elliptical incision and subcutaneous mastectomy addressed the hypertrophied NAC in the B cup breast group, and contour deformities were not found. None of our patients required any secondary revision surgeries. Hage and Bloem<sup>10</sup> used the combination of concentric circular technique with subcutaneous mastectomy in small to large breasts and found that it produced a high rate of complications. They were of the opinion that subcutaneous mastectomy with free nipple–areola graft is a better technique in this group. Our study

established that a combination of modified elliptical incision and subcutaneous mastectomy produces excellent aesthetic results for both B and C cup breast sizes. In their case report, Vigneswaran et al<sup>11</sup> showed that a mini-skate flap for nipple formation has a better aesthetic outcome with good projection. However, our study proved that the reduced free nipple–areola graft prepared in the lines of full-thickness dermal skin graft often results in an aesthetically looking male NAC. Donato et al,<sup>12</sup> Berry et al,<sup>13</sup> and van de Grift et al<sup>14</sup> compared the complication rates of revision surgery between peri-areolar and inframammary technique groups performed for moderate to large breasts. They concluded that the peri-areolar technique had high rates of revision surgeries. This study again reinforces our preferred technique of subcutaneous mastectomy with reduced free NAC grafting and is the best way to acquire masculine features in a single surgery. Antoszewski et al<sup>15</sup> compared various techniques for masculinization of the chest in transmen, from simple Webster’s to McKissock’s pedicled breast reduction technique, and concluded that all the techniques that were stratified based on the breast volume had a high rate of patient satisfaction. However, this article does not use any validated scoring system and our IAOAS is statistically validated. Cregten-Escobar et al,<sup>16</sup> in their study, concluded that complications of seroma, hematoma, and large scars were correlated with large-volume breasts. In our study, relatively fewer complications of seroma and hematoma may be related to the technique of preserving the serratus anterior fascia and PM fascia and using a postoperative suction drain. Monstrey et al<sup>17</sup> formulated an algorithmic approach based on the volume of the breast and skin excess. They also concluded that in congruence with our technique, subcutaneous mastectomy with free reduced NAC grafting in moderate to large breasts brought good aesthetic results. Takayanagi and Nakagawa<sup>18</sup> had performed staged masculinization surgery in a comparably smaller group. Although the dysvascularity of the NAC had never occurred in their series, the nipple remained unaesthetically large in size. In our study, careful thinning of the NAC graft after reduction and good approximation to the de-epithelialized dermis in the upper flap at the appropriate site had optimized take of the NAC graft in almost all cases. The dysvascularity causing hypopigmentation of the NAC graft was noted only in two patients in our study, but we have achieved all these results in a single surgery.

The strength of our study is the establishment of the technique of diligent dissection of the upper and lower flaps with appropriate thickness, adjunctive liposuction, quilting stitches, and final scar orientation—all anatomically conceived steps that were based on the quality and excess skin, and size of breasts, which yielded excellent results. The relatively small sample size is the limitation of our study. A large-scale study may establish the versatility of our technique.

## Conclusion

Top surgery is crucial for transmasculine patients to achieve their desired gender identity as males. It is imperative that

this procedure is performed to their complete satisfaction. Our single-staged comprehensive approach of subcutaneous mastectomy and liposuction with reduced, inert nipple and areola grafts, which aids in swift transition to a male role, is a prerequisite for bottom surgery at our institute.

#### Conflict of Interest

None declared.

#### References

- Balakrishnan TM, Nagarajan S, Jaganmohan J. Retrospective study of prosthetic augmentation mammoplasty in transwomen. *Indian J Plast Surg* 2020;53(01):42–50
- Zheng R, Yu W, Fan J. Development of a new Chinese bra sizing system based on breast anthropometric measurements. *Int J Ind Ergon* 2007;37(08):697–705
- Coleman E, Radix AE, Bouman WP, et al. Standards of care for the health of transgender and gender diverse people, version 8. *Int J Transgender Health* 2022;23(01):S1–S259
- Altomare DF, Spazzafumo L, Rinaldi M, Dodi G, Ghiselli R, Piloni V. Set-up and statistical validation of a new scoring system for obstructed defaecation syndrome. *Colorectal Dis* 2008;10(01):84–88
- Schechter LS, Safa B. *Gender Confirmation Surgery: An Issue of Clinics in Plastic Surgery*. Amsterdam, the Netherlands: Elsevier Health Sciences; 2018
- Keyes GR, Tenta LT. Surgery of the parotid gland and the viscer-overtebral angle. *Clin Plast Surg* 1985;12(03):323–330
- McEvenue G, Xu FZ, Cai R, McLean H. Female-to-male gender affirming top surgery: a single surgeon's 15-year retrospective review and treatment algorithm. *Aesthet Surg J* 2017;38(01):49–57
- Ammari T, Sluiter EC, Gast K, Kuzon WM Jr. Female-to-male gender-affirming chest reconstruction surgery. *Aesthet Surg J* 2019;39(02):150–163
- Knox ADC, Ho AL, Leung L, et al. A review of 101 consecutive subcutaneous mastectomies and male chest contouring using the concentric circular and free nipple graft techniques in female-to-male transgender patients. *Plast Reconstr Surg* 2017;139(06):1260e–1272e
- Hage JJ, Bloem JJ. Chest wall contouring for female-to-male transsexuals: Amsterdam experience. *Ann Plast Surg* 1995;34(01):59–66
- Vigneswaran N, Lim J, Lee HJ, Ong WC, Rasheed MZ, Lim TC. A novel technique with aesthetic considerations in female-to-male transsexuals nipple areola complex reconstruction. *J Plast Reconstr Aesthet Surg* 2013;66(12):1805–1807
- Donato DP, Walzer NK, Rivera A, Wright L, Agarwal CA. Female-to-male chest reconstruction: a review of technique and outcomes. *Ann Plast Surg* 2017;79(03):259–263
- Berry MG, Curtis R, Davies D. Female-to-male transgender chest reconstruction: a large consecutive, single-surgeon experience. *J Plast Reconstr Aesthet Surg* 2012;65(06):711–719
- van de Grift TC, Elfering L, Bouman MB, Buncamper ME, Mullender MG. Surgical indications and outcomes of mastectomy in transmen: a prospective study of technical and self-reported measures. *Plast Reconstr Surg* 2017;140(03):415e–424e
- Antoszewski B, Bratoś R, Sitek A, Fijałkowska M. Long-term results of breast reduction in female-to-male transsexuals. *Pol Przegl Chir* 2012;84(03):144–151
- Cregten-Escobar P, Bouman MB, Buncamper ME, Mullender MG. Subcutaneous mastectomy in female-to-male transsexuals: a retrospective cohort-analysis of 202 patients. *J Sex Med* 2012;9(12):3148–3153
- Monstrey S, Selvaggi G, Ceulemans P, et al. Chest-wall contouring surgery in female-to-male transsexuals: a new algorithm. *Plast Reconstr Surg* 2008;121(03):849–859
- Takayanagi S, Nakagawa C. Chest wall contouring for female-to-male transsexuals. *Aesthetic Plast Surg* 2006;30(02):206–212, discussion 213–214