



# Grading Congenital Anomalies of the Hand for Defining Outcomes and Improved Patient Communication: A Practical Approach

Devi Prasad Mohapatra<sup>1</sup>  Satyaswarup Tripathy<sup>2</sup>  Biswajit Mishra<sup>3</sup>

<sup>1</sup> Department of Plastic Surgery, Jawaharlal Institute of Postgraduate Medical Education and Research (JIPMER), Pondicherry, India

<sup>2</sup> Department of Plastic Surgery, Post Graduate Institute of Medical Education and Research, Chandigarh, India

<sup>3</sup> Department of Plastic, Reconstructive, and Aesthetic Surgery, AMRI Hospitals, Bhubaneswar, Odisha, India

**Address for correspondence** Devi Prasad Mohapatra, MCh, Department of Plastic Surgery, Superspeciality Block, Jawaharlal Institute of Postgraduate Medical Education and Research (JIPMER), Pondicherry 605006, India (e-mail: devimohapatra1@gmail.com).

Indian J Plast Surg

Dear Sir,

Congenital anomalies of the hand present a wide array of clinical challenges due to their diverse nature. Each case can significantly differ in terms of anatomical involvement, severity, functional impairment, and associated conditions. As a result, treatment plans must be highly individualized, balancing surgical interventions, physical therapy, and sometimes prosthetics or adaptive devices. Some cases may require multiple surgeries over time, especially as a child grows, while others might benefit from noninvasive management strategies. This diversity necessitates a multi-disciplinary approach and careful long-term planning to optimize functional outcomes and patient quality of life.

Defining outcomes early in the management of congenital anomalies is essential. Early outcome definition guides the treatment strategy, setting realistic expectations for both health care providers and patients. It enables tailored interventions suited to the specific anomaly or deformity, considering functional and aesthetic goals. This proactive approach can also help in monitoring progress effectively, adjusting treatments as needed, and ensuring that all interventions align closely with the desired outcomes, ultimately leading to improved patient satisfaction and functional results.

Effective communication with patients or caregivers is necessary in these conditions, which often require long-term, complex treatment plans, including surgeries and rehabilitation. Clear communication ensures that patients and their caregivers fully understand the diagnosis, treat-

ment options, and potential outcomes. It helps in setting realistic expectations, which is vital for emotional and psychological preparedness. Additionally, effective dialogue fosters a stronger patient–clinician relationship, enhances adherence to treatment plans, and ultimately leads to better overall patient satisfaction and outcomes.<sup>1</sup>

Congenital hand anomalies have been classified in many ways, for example, the Swanson classification, the Oberg–Manske–Tonkin (OMT) classification, while hand functional outcomes are scored using the Disabilities of the Arm, Shoulder, and Hand (DASH) score, QuickDASH score, etc.<sup>2–5</sup> However, conveying the severity of the anomalies or deformity to a patient is always a challenge for the caregiver.

Recognizing the challenges in consistently evaluating and communicating the complexities of hand anomalies and deformities, we are proposing a novel grading system (► **Table 1**) to bridge this gap.

Our aim was to empower health care providers (particularly hand surgeons) with a simple tool that goes beyond anatomical descriptions or complex scoring to offer a framework for informing clinical decision-making, streamlining communication, and setting realistic expectations for patients.

The Hand Anomalies and Deformity (HANd) grading system is based on two key factors: characteristics and treatment outcome. It grades anomalies on a scale from I (mild) to IV (profound), with grade III (severe) further divided into A and B subcategories for nuances in complexity and associated syndromes (► **Fig. 1**).

DOI <https://doi.org/10.1055/s-0044-1781444>.  
ISSN 0970-0358.

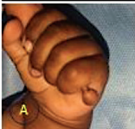










© 2024. Association of Plastic Surgeons of India. All rights reserved. This is an open access article published by Thieme under the terms of the Creative Commons Attribution-NonDerivative-NonCommercial-License, permitting copying and reproduction so long as the original work is given appropriate credit. Contents may not be used for commercial purposes, or adapted, remixed, transformed or built upon. (<https://creativecommons.org/licenses/by-nc-nd/4.0/>)

Thieme Medical and Scientific Publishers Pvt. Ltd., A-12, 2nd Floor, Sector 2, Noida-201301 UP, India

**Table 1** The Hand Anomalies and Deformity (HANd) grading system

Grade	Severity	Characteristics	Treatment outcome	Examples
I	Mild anomalies	Minimal functional impairment; anomalies primarily cosmetic	Excellent functional and cosmetic outcomes expected with or without surgical intervention	Slight syndactyly without bone fusion, minor polydactyly, small accessory digits
II	Moderate anomalies	Some functional impairment; may have significant cosmetic concerns	Good functional outcomes expected with surgical intervention; cosmetic results may vary	Complete simple syndactyly, moderate polydactyly, mild camptodactyly
III	A	Severe anomalies with compromised function	Significant functional impairment and cosmetic issues; may affect multiple digits or the whole hand	Complex syndactyly (with bone fusion), severe polydactyly, severe camptodactyly, congenital constriction band syndrome with limb involvement
	B	Severe anomalies with associated syndromes	Functional outcomes vary widely; multiple surgeries often required; multidisciplinary approach critical for management	Radial club hand, severe cases of arthrogryposis affecting the hand, Apert's syndrome with complex syndactyly
IV	Profound anomalies with poor functional outcome	Extreme deformities with very limited potential for normal function	Focus on maximizing residual function and prosthetic adaptation; limited surgical benefit for functionality	Major aplasia/hypoplasia of the hand, severe phocomelia

Note: This grading system aims to assist health care providers in categorizing congenital hand anomalies, aiding in communication, planning treatment strategies, and setting realistic expectations for outcomes, and would be beneficial in both clinical and educational settings.

Grade	Severity	Examples
I	Mild Anomalies	
II	Moderate Anomalies	  
III	A	  
	B	  
IV	Profound Anomalies with Poor Functional outcome	

**Fig. 1** Selective examples of hand anomalies representing different grades. Grade I: (A) ulnar polydactyly. Grade II: (A) trigger thumb (older child); (B) macrodactyly; (C) simple complete syndactyly. Grade IIIA: (A) brachydactyly; (B) severe constriction ring syndrome; (C) severe camptodactyly. Grade IIIB: (A) bilateral ulnar deficiency; (B) Apert's hand deformity; (C) synpolydactyly in Saethre–Chotzen syndrome. Grade IV: (A) unilateral adactyly of digits 2 to 5 with thumb hypoplasia (transverse limb deficiency).

These deformities will often need additional physical therapy to achieve optimum function. The system outlines the expected functional and cosmetic outcomes for each grade. This system thus helps health care providers accurately classify and communicate the nature of the hand condition to the patient or the caregiver.

Some additional features of the HAnD grading system include the following:

- *Emphasis on function:* The system prioritizes the impact of the deformity on hand function, aiding in treatment planning, and setting realistic expectations for patients.
- *Consideration of associated syndromes:* Recognizing the presence of associated syndromes like Apert's syndrome allows for a more holistic approach to management.
- *Focus on treatment feasibility:* The system acknowledges the limitations of surgical intervention for severe anomalies, guiding treatment decisions toward maximizing the remaining function.

#### Conflict of Interest

None declared.

#### References

- 1 Franzblau LE, Chung KC, Carlozzi N, Chin AYT, Nellans KW, Waljee JF. Coping with congenital hand differences. *Plast Reconstr Surg* 2015;135(04):1067–1075
- 2 Oberg KC. Classification of congenital upper limb anomalies: towards improved communication, diagnosis, and discovery. *J Hand Surg Eur Vol* 2019;44(01):4–14
- 3 Goldfarb CA, Ezaki M, Wall LB, Lam WL, Oberg KC. The Oberg-Manske-Tonkin (OMT) classification of congenital upper extremities: update for 2020. *J Hand Surg Am* 2020;45(06):542–547
- 4 Changulani M, Okonkwo U, Keswani T, Kalairajah Y. Outcome evaluation measures for wrist and hand: which one to choose? *Int Orthop* 2008;32(01):1–6
- 5 Gummesson C, Ward MM, Atroshi I. The shortened disabilities of the arm, shoulder and hand questionnaire (QuickDASH): validity and reliability based on responses within the full-length DASH. *BMC Musculoskelet Disord* 2006;7:44