



# Mother and Daughter Technique Using a Low-Profile Microcatheter for Navigating a Complete Radial Artery Loop

Vikas Bhatia<sup>1</sup> Keshu Meghashyam<sup>1</sup>

<sup>1</sup>Department of Radio-diagnosis and Imaging, PGIMER, Chandigarh, India

Indian J Neurosurg

**Address for correspondence** Vikas Bhatia, MD, DNB, DM, Associate Professor, Neuroradiology Section, Department of Radio-Diagnosis, PGIMER, Chandigarh, India 160012 (e-mail: drvikasbhatia@gmail.com).

## Abstract

Radial loops are infrequent; however, they are a major cause for failure of radial access for procedure. Interventionists should be familiar with bail-out techniques when a radial loop is encountered to avoid spasm/injury. We describe our experience with two cases with 360 degrees radial loop in which we used low-profile microcatheter system to successfully complete the procedure

## Keywords

- ▶ angiography
- ▶ image-guided neurosurgery
- ▶ radial access
- ▶ Neurointervention

## Introduction

Transradial access route has gained considerable popularity in cardiology literature and becoming an increasingly used route in neurointervention procedures.<sup>1</sup> Many recent publications have shown that the radial route is safe and feasible for performing neurointerventions. In addition to the unique challenges of overcoming the learning curve of radial access, the anatomical variants particularly the presence of radial loops can pose a significant challenge to the operator. Careful assessment and strategies to negotiate the radial loop should be employed to avoid injury, spasm, or need for access site conversion.<sup>2</sup>

We describe two cases of complete 360-degree tight loops in which we used a special technique to negotiate the loop and complete the endovascular procedure.

## Case Report

**Case 1:** A 36-year-old male who had undergone flow diversion treatment for a postclipping residual ACom aneurysm was posted for a diagnostic cerebral angiography to assess status of the aneurysm. As the patient was on dual antiplatelet

treatment, a right transradial route was taken for cerebral angiography.

The right radial artery was punctured under ultrasound guidance and a 5 French (F) short radial Glidesheath (Terumo, Japan) was placed. Radial cocktail consisting of verapamil, nitroglycerin, and heparin was given through the sheath. A Radial angiogram was taken and a 5F diagnostic catheter (Glidesheath, Terumo, Japan) was advanced over a 0.035-inch hydrophilic wire through the radial sheath.

At the level of cubital fossa, there was resistance in passing the wire across an apparent partial loop with patient experiencing pain on repeated attempts. The position of the X-ray tube and the arm was changed, which revealed a complete 360 degrees loop that was not allowing the 0.035-inch wire to take the curve and go distal to the loop.

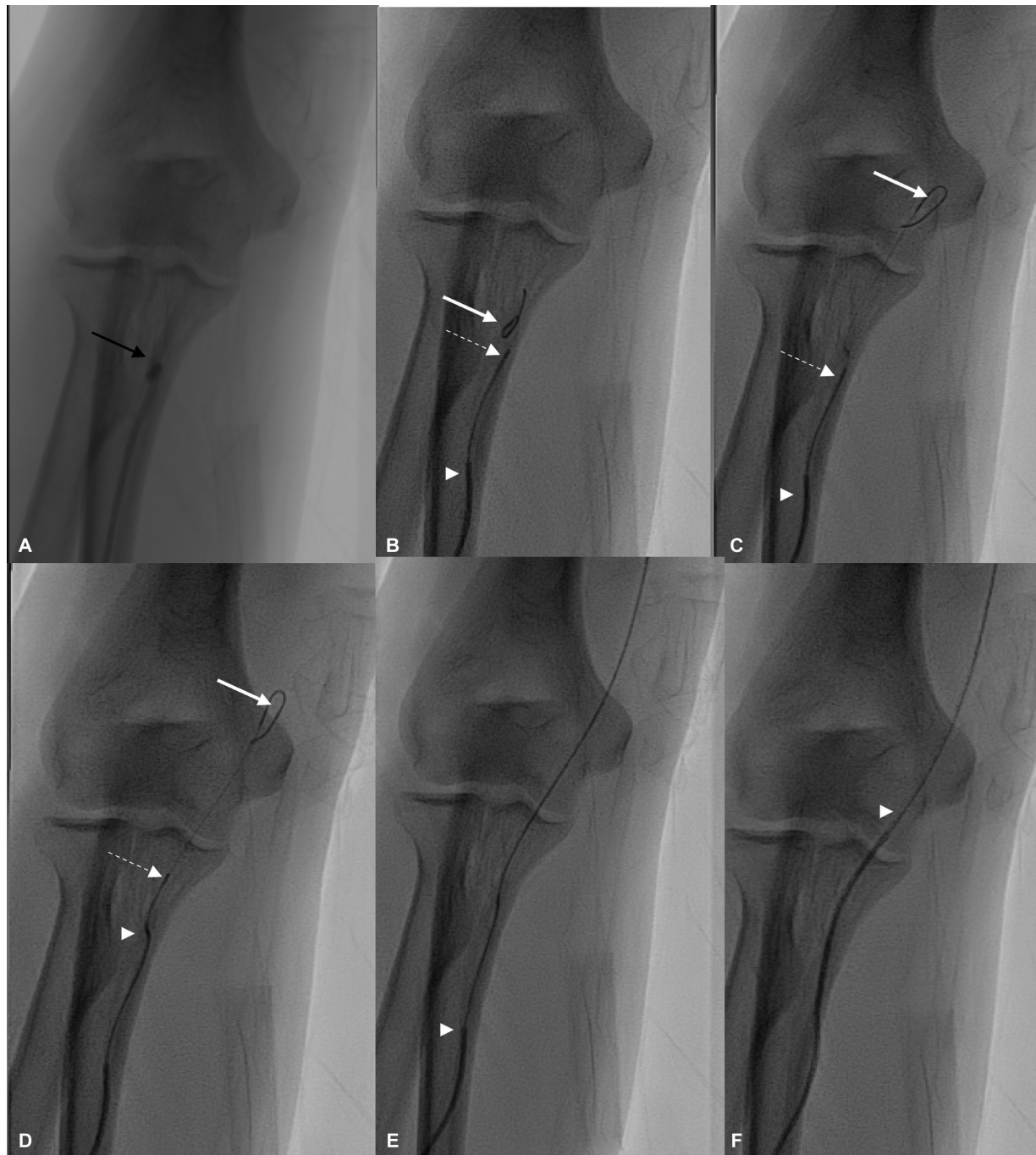
We then took a low-profile microcatheter (Progreat, Terumo, Japan) that was placed inside the 5F diagnostic catheter. Progreat microcatheter is an 0.027-inch microcatheter with hydrophilic coating that has its own preloaded hydrophilic, 0.21-inch wire. We gave a J shape to the distal portion of the wire to facilitate smooth passage across the loop. The wire of the Progreat microcatheter could easily navigate through the radial loop, followed by smooth advancement of the

DOI <https://doi.org/10.1055/s-0044-1782204>.  
ISSN 2277-954X.

© 2024. The Author(s).

This is an open access article published by Thieme under the terms of the Creative Commons Attribution License, permitting unrestricted use, distribution, and reproduction so long as the original work is properly cited. (<https://creativecommons.org/licenses/by/4.0/>)

Thieme Medical and Scientific Publishers Pvt. Ltd., A-12, 2nd Floor, Sector 2, Noida-201301 UP, India



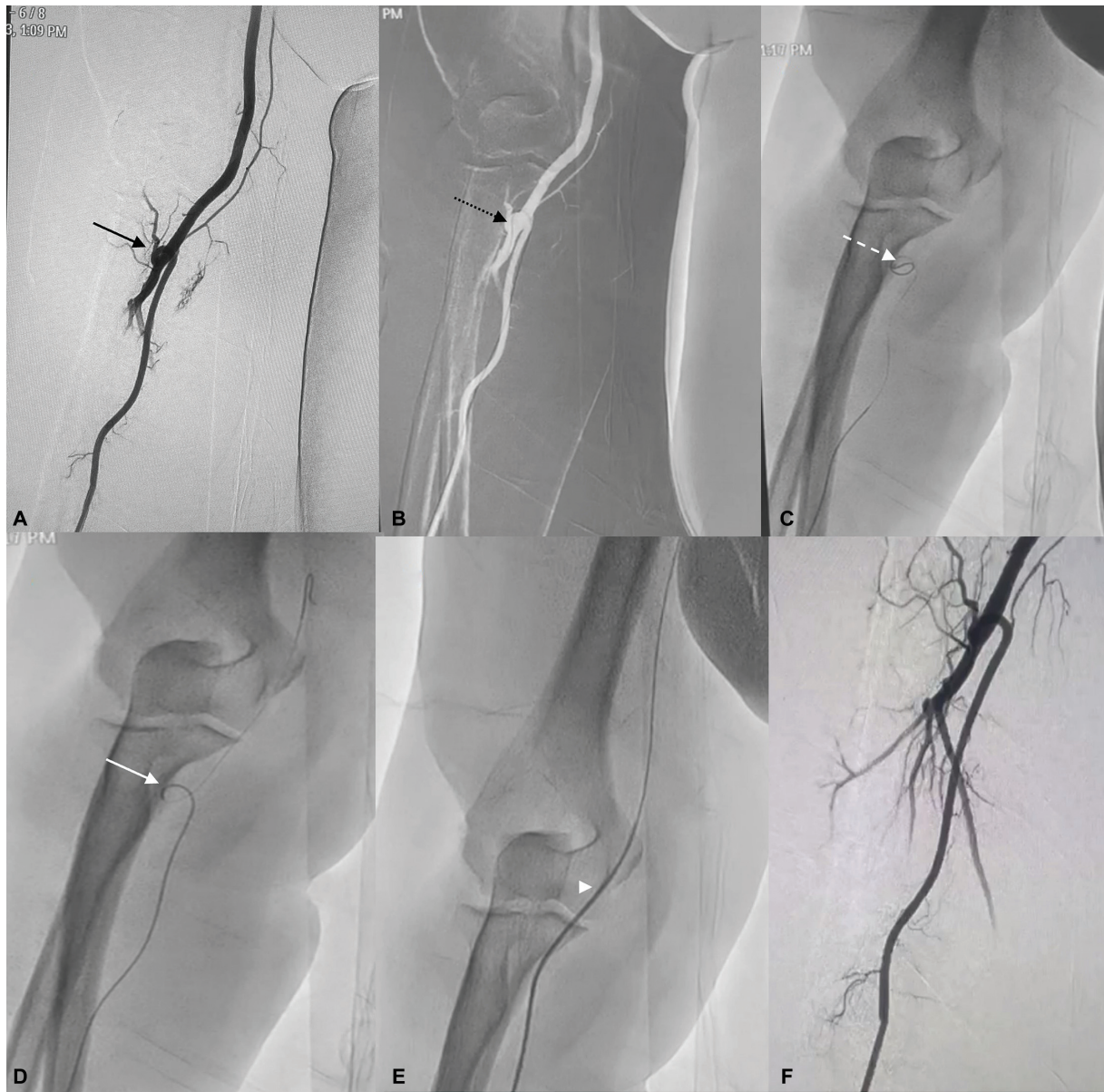
**Fig. 1** (A) Right radial angiogram showing presence of tight 360 degrees loop (black arrow). (B) The loop was gently crossed with the microwire (white arrow), tip of microcatheter (dashed arrow), tip of 5 French (F) diagnostic catheter (arrowhead). (C) Microwire advanced into the brachial artery. (D) Microcatheter advanced into the brachial artery with resultant straightening of loop. (E) Microwire and microcatheter advanced into axillary artery. (F) Crossing the 5F diagnostic catheter across the loop.

microcatheter that partially straightened the radial loop (→Fig. 1).

After taking the microcatheter and wire into the axillary artery, the 5F diagnostic catheter was advanced across the loop and taken into aorta for completion of the diagnostic procedure. No pain was perceived by the patient, throughout the procedure at the loops site.

Check angiography after the procedure, through the radial sheath showed reformation of the loop with no evidence of any trauma or vasospasm.

**Case 2:** A 54-year-old female posted for diagnostic cerebral angiography as a follow-up of previous Acom coiling. Right radial access with 5F radial sheath was taken. Right radial angiogram revealed a 360-degree loop at the level of cubital fossa. There was difficulty in tracking the 0.035-inch wire through the loop. Again, the similar strategy as in case 1 was employed using a Progreat microcatheter and wire to first cross the loop followed by advancement of the 5F diagnostic catheter. No pain was experienced by the patient throughout the procedure that was successfully



**Fig. 2** (A) Right radial angiogram shows presence of 360-degree loop (black arrow). (B) The loop was not negotiable with 0.035 wire. (C) It was gently crossed with the microwire (dashed black arrow). (D) Microcatheter advanced into the brachial artery through the loop (dashed white arrow). (E) Microwire and microcatheter advanced into axillary artery with crossing of the 5 French diagnostic catheter (arrowhead) across the straightened loop. (F) Check angiogram after procedure shows lack of spasm/injury.

completed. Check angiography after the procedure, through the radial sheath showed reformation of the loop with no evidence of any trauma or vasospasm (►Fig. 2).

## Discussion

Radial access route is gaining momentum among the neuroendovascular community for diagnostic and therapeutic neurointervention procedures. We had previously published our study on learning curve of radial access. For those who are new to the radial access we recommend performing 50 to 100 transradial angiographies for overcoming the learning curve.<sup>3</sup> Technical failures after overcoming the learning curves are seen in up to 5% of patients due to tortuosity, atherosclerosis, radial spasms, anatomical variants, and small caliber.

Radial artery spasm and anatomical variants are the most common challenges for failure of transradial access. Radial loops are one of the most difficult causes resulting in conversion to alternative access route.<sup>2,3</sup> Most of the literature regarding negotiation of these loops come from cardiology but recently this issue is being identified and addressed in neurointervention communities.<sup>2,4</sup>

Radial loops are found to be present in up to 2% of cases and are formed due to tethering of recurrent radial artery as the arm growth takes place.<sup>5</sup>

Most of the partial loops/tortuous vessels can be safely negotiated with the 0.035 wire and get straightened when the catheter is advanced. Sometimes recurrent radial artery can be used for the procedure when it has sufficient diameter.



**Table 1** A summary of described techniques for radial loop negotiation<sup>3,4</sup>

Identifying the loop	Take multiple views Use of roadmap technique
Downsizing the guidewire	Using an 014' wire to negotiate the loop, followed by attempt to take the catheter. Exchange the wire if less support
Using buddy wire	Use of two 014' wires to provide adequate support
Straightening the loop	Manual reduction after passage of wire and microcatheter Gently pull on both the catheter and wire after they are sufficiently advanced distal to straighten the loop
Exchange of guidewire	Advance the catheter as much as possible into the loop over 014' wire. Exchange with 025' or 035' wire
Using a low-profile microcatheter and microwire	Can result in straightening of the loop
Mother and daughter techniques	Balloon-assisted tracking: Using a partially inflated 2–3 mm coronary balloon at the catheter edge over an 014' wire Pigtail-assisted tracking: Using a pigtail catheter to assist in tracking of the catheter through the loop
Completing procedure through recurrent radial artery	Recurrent radial artery of not hypoplastic can be used to perform the procedure
Access conversion	If loop remains non-negotiable after all the maneuvers to avoid injury/dissection

Multiple strategies have been described for negotiating the radial loop that are summarized in **Table 1**.

Mother and daughter techniques using the balloon-assisted tracking and pigtail assisted tracking have been described before in cardiology literature.<sup>4,6</sup> The major benefit is avoiding the razor-blade effect of the catheter tip as it crosses the radial loop.

The technique similar to us has been suggested in previous neurointervention papers.<sup>2,7</sup>

Luther et al<sup>5</sup> have described in their cases use of 0.014-inch wire and 0.027 microcatheter for negotiating the radial loop in few of their cases. They advised to change the wire to 0.018 inch if there is less support with the 0.014 wire. This strategy could result in straightening of the loop and the diagnostic catheter can be subsequently advanced. They advised recurrent radial artery can be used for the procedure if it has a sufficient diameter.

Dossani et al in their case series encountered two cases of 360 degrees loop. They described use of a 0.014 wire with either a 0.0165 inch or 0.025-inch microcatheter for navigating the loop.<sup>6</sup>

We have used a 0.027-inch Progreat microcatheter which comes with 0.021 microwire for tracking the radial loops. This microcatheter is specifically designed for navigation into tortuous vessels and has tungsten coil reinforcement for kink resistance. The combination of this 0.027 microcatheter with its 0.021 hydrophilic wire provides sufficient support and trackability for these 360 degrees loops. This results in straightening of the loop as described by Luther and Dossani et al.<sup>2,7</sup> Additionally, the greater diameter of the microwire and microcatheter also mitigates the razor-blade effect from the subsequent passage of diagnostic/guiding catheter similar to balloon/pigtail assisted techniques. There is also no need for upgrading to a greater diameter microwire for increased

support as the 0.021 hydrophilic wire provides sufficient support and trackability. Due to these potential advantages, we include our technique into the “mother and daughter techniques” previously described.

Balloon-assisted tracking and pigtail-assisted tracking has been described as mother and daughter technique for overcoming challenges of difficult radial access. Balloon-assisted technique was described by Patel et al and principal advantage is to reduce the razor-blade effect of the catheter on the artery.<sup>6</sup> They have shown advantage of the technique mainly in small caliber radial arteries and with marked tortuosity. Only very small population in their study had complete radial loops. The complete radial loop case demonstrated in their study had a wider loop diameter that can be navigated with the help of balloon-assisted tracking. Our cases had very tight complete 360-degree loops that could not be navigated with the hydrophilic soft 5F catheter. We assume that balloon can be challenging in both these cases as the purpose is to track across the tight loop as well as mitigating the razor-blade effect. Our low-profile catheter technique can be easily extended to small radial arteries as in balloon-assisted technique. In their study they had shown failure in one case with small radial artery and 360-degree loop. Pigtail-assisted tracking method is also based on minimizing the razor-blade effect. Pigtail catheter is a stiffer catheter and we believe that navigating it through a very tight loop will be very difficult.<sup>6</sup> Using a low-profile microcatheter such as Progreat can help in easily navigating these tight loops as seen in our cases as well as provide protection from the razor-blade effect.

Mother and daughter technique using a low-profile microcatheter has been successfully shown to navigate complete tight radial loops in both cases. However, risk of dissection and perforation will be there, so a gentle negotiation should be done. Although risk of these

complications should be less than balloon-assisted tracking and pigtail-assisted tracking as there is no need for balloon inflation and catheter profile is small as compared to pigtail catheter. Further studies comparing these techniques can throw some light on the utility in complex radial loops.

Check angiograms in both cases showed no evidence of spasm or injury in the radial vessel with maintained loops. Use of additional catheter adds to the cost of the procedure; however, it can be balanced by the benefit of using the radial access which has been shown to be more cost-effective and better accepted by the patients as compared to femoral approach. Use of low-profile microcatheter can be relatively more expensive than balloon-assisted or pigtail catheter techniques. But this catheter is easily available in neurointervention labs and we believe that this technique is better suited for very tight radial loops. One additional benefit is with cost as this catheter is preloaded with the microwire and additional wires are not required for tracking the loops.

## Conclusion

Complete radial loops are a frequent cause of radial access failure and injury. A proper understanding of the anatomy is important. Our technique has shown successful use in both

cases. Further case studies are required to see utility of technique in patients with complete radial loops.

## Conflict of Interest

None declared.

## References

- 1 Bhatia V, Kumar A, Chauhan R, Singla N. Transradial approach in neurointervention: Part-II: diagnostic and therapeutic intervention. *J Neurosci Rural Pract* 2023;14(01):16–20
- 2 Luther E, Burks J, Abecassis IJ, et al. Navigating radial artery loops in neurointerventions. *J Neurointerv Surg* 2021;13(11):1027–1031
- 3 Yaser Arafath M, Bhatia V, Kumar A, et al. Adapting to transradial approach in cerebral angiography: factors influencing successful cannulation. *Neuroradiol J* 2023;36(02):163–168
- 4 Patel T, Shah S, Pancholy S, et al. Working through complexities of radial and brachial vasculature during transradial approach. *Catheter Cardiovasc Interv* 2014;83(07):1074–1088
- 5 Luther E, Chen SH, McCarthy DJ, et al. Implementation of a radial long sheath protocol for radial artery spasm reduces access site conversions in neurointerventions. *J Neurointerv Surg* 2021;13(06):547–551
- 6 Patel T, Shah S, Pancholy S, Rao S, Bertrand OF, Kwan T. Balloon-assisted tracking: a must-know technique to overcome difficult anatomy during transradial approach. *Catheter Cardiovasc Interv* 2014;83(02):211–220
- 7 Dossani RH, Waqas M, Tso MK, et al. Endovascular management of radial artery loop for neuroangiography: case series. *Interv Neuroradiol* 2021;27(04):566–570