



A Case Report of the First CEA Transplant in an HIV-Positive Burn Patient in South Africa Using a Novel Composite Culture Technique

Wayne George Kleintjes^{1,2} Tarryn Kay Prinsloo^{3,4}

¹ Department of Surgical Sciences, Faculty of Medicine and Health Sciences, Stellenbosch University Medical School, Parow, Cape Town, Western Cape, South Africa

² Western Cape Provincial Adult Tertiary Burns Centre, Tygerberg Hospital, Tygerberg, Parow, Cape Town, Western Cape, South Africa

³ Department of Biomedical Sciences, Faculty of Health and Wellness Sciences, Cape Peninsula University of Technology, Bellville, Cape Town, Western Cape, South Africa

⁴ Department of Emergency Medical Sciences, Faculty of Health and Wellness Sciences, Cape Peninsula University of Technology, Bellville, Cape Town, Western Cape, South Africa

Address for correspondence Wayne George Kleintjes, MMed, MPhil, PhD, Department of Surgical Sciences, Faculty of Medicine and Health Sciences, Stellenbosch University Medical School, Francie van Zijl Avenue, Parow, 7505, Cape Town, Western Cape, South Africa (e-mail: wayne.kleintjes@westerncape.gov.za; waynekleintjes@yahoo.com).

Indian J Plast Surg

Abstract

Resource-limited burn centers are usually devoid of cultured epithelial autografts (CEA) owing largely to prohibitive costs. A modified CEA technique at our burn center incorporated cost-effective, routinely-used dressings with favorable outcomes. One unknown concern was the immunosuppressive effect that extensive burns and potentially human immunodeficiency virus (HIV) infection may have on graft take. This case study reports on the graft take outcomes of the first CEA transplanted in an HIV-positive patient with extensive burns in South Africa, using this technique. Graft take was determined after 21 days at 80% and a long-term follow-up of 8 years indicated good pigmentation return and skin pliability. Delayed diagnosis of pyoderma gangrenosum caused partial graft loss; however, successful regrafting occurred after pyoderma gangrenosum treatment and eradication. The case was considered clinically successful. HIV may not directly affect graft take, but may result in immunosuppressive conditions that delay graft take success.

Keywords

- ▶ cultured epithelial autografts
- ▶ human immunodeficiency virus
- ▶ pyoderma gangrenosum

Introduction

Despite various prevention campaigns and treatment techniques, burns still remain a global public health problem. Public sectors can seldomly afford the cost and logistics that accompanies the more modern techniques such as with cultured epithelial autografts (CEAs). Thermal injury alters important physiological functions of cutaneous tissues causing impaired

physiological, increasing the susceptibility to complications, which in turn increases the risk of mortality.¹ Pre-existing medical comorbidities in burn patients were also reported to have poor prognosis, particularly human immunodeficiency virus (HIV).² Along with burns, HIV was also reported to independently cause immunosuppression.³ While the two have been explored to a minimal extent in literature, the

DOI <https://doi.org/10.1055/s-0044-1782540>.
ISSN 0970-0358.

© 2024. Association of Plastic Surgeons of India. All rights reserved. This is an open access article published by Thieme under the terms of the Creative Commons Attribution-NonDerivative-NonCommercial-License, permitting copying and reproduction so long as the original work is given appropriate credit. Contents may not be used for commercial purposes, or adapted, remixed, transformed or built upon. (<https://creativecommons.org/licenses/by-nc-nd/4.0/>)
Thieme Medical and Scientific Publishers Pvt. Ltd., A-12, 2nd Floor, Sector 2, Noida-201301 UP, India

potential relationship between HIV, burns, and CEA graft take in South Africa at the only dedicated adult burn center in Tygerberg Hospital, Western Cape Province, Cape Town, has not yet been elucidated. Therefore, the aim of this case study was to report on the observations relating to graft take in an HIV patient using the novel CEA technique⁴ in the Western Cape Provincial Adult Tertiary Burns Centre.

Case Report

A 34-year-old female sustained 60% total body surface area flame burns with an Abbreviated Burn Severity Index (ABSI) score of 11. Overall, the degree of injury was 50% full- and partial-thickness burns with 10% added for inhalation injury presence that was diagnosed using a high index of clinical suspicion (hoarseness, singed nasal hairs, redness of the pharynx, and soot between the teeth and palate). The patient was referred intubated and ventilated in the burns intensive care unit for 3 weeks. She was known with HIV, her CD4 count was 18 and remained low throughout length of stay. Standard sterile contact precautions and personal protective equipment were adhered to. She responded well to the acute resuscitation.

Several bouts of septic shock followed, which were treated with appropriate antibiotics. Multiple skin grafts and CEAs were provided for the affected burn areas within 72 hours of admission (→ Fig. 1A). The waiting period for reharvesting from unhealed donor sites would increase chances to complications, which demonstrated the need for CEA due to the large extent of her burn wounds and poor nutritional status (low albumin <16 was associated with poor donor site and wound healing). This meant that alternative grafting options with minimal impact on donor site morbidity had to be considered.

A 3 × 2 cm skin biopsy was taken from the left inguinal region on day 3 during the first operation. The skin biopsy was immediately prepared, cultured and maintained on Cutimed Sorbact dressing pads (Cutimed Sorbact, BSN, Pinetown, RSA) as previously described.⁴ Xenografts (EZDerm, Molnlycke Health Care, UC LLC, Norcross, Georgia, United States) were temporarily used during the culture period. Dressings incorporating nanocrystalline silver with paraffin gauze were applied as a contact layer. For high contamination (perineum), regular dressing changes and silver sulfadiazine ointment was used. Once culture confluency was reached (microscopically indicated by a brown, gelatinous-like cellular monolayer) on

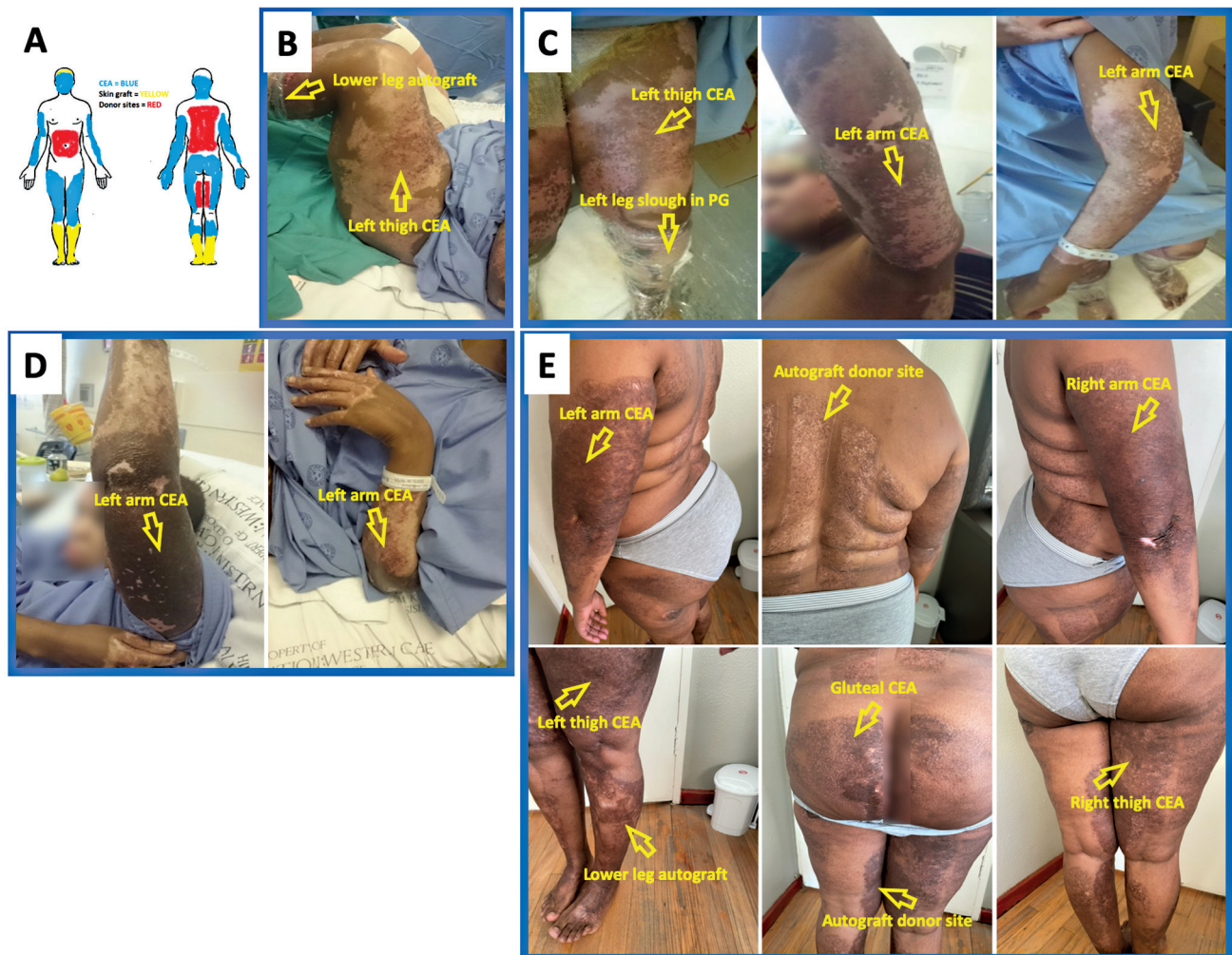


Fig. 1 Wound and treatment regions following post-transplant healing. (A) Designated autograft/CEA-treated and donor site areas; (B) Healing with CEA and autografts 4 months post-transplant; (C) Healing with CEA and autografts 5 months post-transplant; (D) Healing with CEA and autografts 7-month post-transplant; (E) Healing with CEA and autografts 8 years post-transplant. CEA, cultured epithelial autografts.

day 14, the CEA-contained dressing was taken to theater and then transferred directly onto the prepared wound bed areas (► **Fig. 1A**). Prior to transplant, the xenograft was superficially removed using the Versajet hydro-debridement system (Versajet, Smith + Nephew, Inc., Fort Worth, Texas, United States) for wound bed preparation. ► **Fig. 1A** illustrates the graft areas and donor sites of the patient. Graft take was assessed on a weekly basis and the final assessment after 21 days. Follow-up assessment took place after 3 and 7 months postdischarge and after 3, 5, and 8 years. CEA graft take was calculated as a percentage of graft take for the total area of the CEA transplanted. The Vancouver scar scale (VSS)⁵ was used throughout the follow-up period that graded pigmentation, vascularity, pliability, and height.

Up to 3 weeks postgrafting, no significant complications pertaining to graft take were observed. The CEA take was 80% (surface area calculation of skin graft to CEA = 1:5) and stronger presence of hyperpigmentation and the good skin pliability was noted. After 2 months, delayed healing was observed on the leg areas and presented with recurring slough (► **Fig. 1B and C**) despite two failed attempts at debridement and autografting. Slough samples were sent from every theater debridement for microscopy, culture, and sensitivity. She was treated accordingly for *Pseudomonas aeruginosa* and *Proteus mirabilis*. Tissue breakdown continued and a diagnosis (up to 5 months after injury) of pyoderma gangrenosum (PG) was made after exclusion of other pathologies. Typical biopsies were not performed since histology for PG is nonspecific due to the chronic inflammatory state. Steroids, prednisone 5 mg daily, were used for treatment with a good response. The wounds stabilized quickly (within a week) and traditional skin grafting commenced with good graft take. Patient was discharged after prolonged rehabilitation. The VSS scores progressively decreased for each follow-up period as follows: VSS of 9 at 5 months (► **Fig. 1C**), VSS of 8 at 7 months (► **Fig. 1D**), and a VSS of 4 and 2 for years 3 and 6, respectively. ► **Fig. 1E** illustrates the CEA and traditional autografts transplanted after 8 years. Ideal vascularity was observed and most areas displayed hyperpigmentation, with minor areas of hypopigmentation. Normal pliability and scar height were also determined.

Discussion

Few studies address burn outcomes in the presence of HIV infection, with none addressing HIV and CEA. Immunosuppressive effects of a similar nature resulted in delayed healing and autograft loss,⁶ which raised obvious concerns for this case. One late complication was graft loss on the lower legs due to PG. PG diagnosis in burns is difficult and not previously made in this burn center. The dermatology department did not support a PG diagnosis; however, after further recurrent slough, the burn surgeon made the diagnosis. It was postulated that the causative agent of PG could be HIV, since others reported the association between the two.⁷ PG did not impact the overall CEA graft take, but impacted morbidity causing repeated surgery and prolonged hospitalization.

Conclusion

The CEA in the HIV patient was effective and displayed long-term stability despite late PG complications. Future studies should expand on the relationship between CEA, graft take, and pre-existing comorbidities (not limited to HIV) for a better understanding of CEA graft take and failure.

Ethical Approval

The CEA application was approved for ongoing case studies and the publication of the related data by the Health Research Ethics Committee of the Faculty of Medicine and Health Sciences, Stellenbosch University (REF: C15/01/001). Written informed patient consent was obtained from the patient and for the use of clinical figures for publishing or academic purposes.

Authors' Contributions

Both authors have contributed equally to the study design, data analysis/interpretation, and writing of manuscript. Additionally, W.G.K. was responsible for the conceptualization and collection of data, while T.K.P. also contributed by data preparation and literature acquisition.

Conflict of Interest

The skin culture technique is patented and owned by Stellenbosch University (SU, Stellenbosch, Cape Town, South Africa). Dr. Wayne George Kleintjes is the founder of the modified technique. For the remaining author, none are declared.

Acknowledgments

The authors would like to thank Tygerberg Hospital management and staff, Prof. E. Steyn and the Department of Surgical Services, Stellenbosch University, Faculty of Medicine and Health and Mr. Marcel Golding for support. No funding was received for this study.

References

- 1 Lachiewicz AM, Hauck CG, Weber DJ, Cairns BA, van Duin D. Bacterial infections after burn injuries: impact of multidrug resistance. *Clin Infect Dis* 2017;65(12):2130–2136
- 2 Thombs BD, Singh VA, Halonen J, Diallo A, Milner SM. The effects of preexisting medical comorbidities on mortality and length of hospital stay in acute burn injury: evidence from a national sample of 31,338 adult patients. *Ann Surg* 2007;245(04):629–634
- 3 Sjöberg T, Mzezewa S, Jönsson K, Salemark L. Immune response in burn patients in relation to HIV infection and sepsis. *Burns* 2004;30(07):670–674
- 4 Kleintjes W, Thomas G, Thaele BSS, Stevenson N, Warren B. A novel technique for composite cultured epithelial autograft in a patient with extensive burn wounds: a case report. *Clin Surg* 2017;2:1579
- 5 Sullivan T, Smith J, Kermodie J, McIver E, Courtemanche DJ. Rating the burn scar. *J Burn Care Rehabil* 1990;11(03):256–260
- 6 DeLaney AR, Damato RA, Ikeda CJ. Delayed autograft loss in HIV-positive patients: two cases. *J Burn Care Rehabil* 1990;11(01):67–70
- 7 Kleintjes W, Kotzee E, Leng T, Johnson C, Daniels S, Steyn E. Challenges in diagnosing pyoderma gangrenosum in a severely burned patient: case report and literature review. *South African J Plast Reconstr Aesthetic Surg Burn* 2021;4(01):17–20