







A Pilot Real-World Study of Ultrasonography Findings of Hidradenitis Suppurativa in Indian Patients and Its Diagnostic and Therapeutic Implications

Siddharth Gogate¹ Raghav Aggarwal² Kabir Sardana¹ Sheetal Yadav¹ Bulli Babu Boyidi³
Siddharth Siddharth⁴ Pankaj Sharma⁵

¹ Department of Dermatology, Venerology and Leprosy, Ram Manohar Lohia Hospital and Atal Bihari Vajpayee Institute of Medical Sciences, New Delhi, India

² Dr M L Aggrawal Imaging Center, New Delhi, India

³ Department of Plastic and Reconstructive Surgery, Ram Manohar Lohia Hospital and Atal Bihari Vajpayee Institute of Medical Sciences, New Delhi, India

⁴ Ram Manohar Lohia Hospital and Atal Bihari Vajpayee Institute of Medical Sciences, New Delhi, India

⁵ Department of Diagnostic and Interventional Radiology, All India Institute of Medical Sciences, Rishikesh, Uttarakhand, India

Address for correspondence Raghav Aggarwal, MD (Radiodiagnosis), Dr M L Aggrawal Imaging Center, New Delhi 110029, India (e-mail: aggarwalraghav73@gmail.com).

Indian J Radiol Imaging

Abstract

Keywords

- ▶ hidradenitis suppurativa
- ▶ Cutaneous Ultrasound
- ▶ Soft-tissue Ultrasound
- ▶ Ultrasound in Dermatology
- ▶ Ultrasound in Plastic Surgery
- ▶ High-frequency Ultrasound
- ▶ Treatment
- ▶ Surgery
- ▶ Biological

Introduction Hidradenitis suppurativa (HS) is a multifactorial chronic inflammatory follicular disorder affecting apocrine gland-bearing areas of the body. We conducted an observational study to assess the ultrasonography (USG) findings in suspected HS patients at a tertiary care center in North India over 6 months.

Aim The aim of this article was to study the USG findings in HS and correlate clinical and USG findings and scoring systems in HS with stage wise treatments.

Materials and Methods All patients with a clinical suspicion of HS underwent an USG examination after clinical examination with a probe of 18 Hz frequency. Hurley's staging of patients was used to stage clinically, and the HS-SOS scoring and Doppler changes were assessed on USG. The treatment was revised in case of a change in the USG grading of severity.

Results A total of 23 patients suspected of HS underwent USG evaluation, of which 12 (52%) were male and 9 (48%) were females, with the mean age being 25.3 years (range: 14–40 years). Based on the HS clinical grading, eleven patients (47.8%) were Hurley's stage I, six patients (26%) were stage II, and six patients (26%) were stage III. USG demonstrated that three patients had been misdiagnosed and had folliculitis (8.6%) and Crohn's disease (4.3%). Out of the remaining twenty patients with USG features of HS, based on HS SOS grading, three patients (15%) were grade I, seven (35%) were grade II, and ten (50%) were grade III. Of these, nineteen patients (95%) had axillary

DOI <https://doi.org/10.1055/s-0044-1782624>.
ISSN 0971-3026.

© 2024. Indian Radiological Association. All rights reserved.
This is an open access article published by Thieme under the terms of the Creative Commons Attribution-NonDerivative-NonCommercial-License, permitting copying and reproduction so long as the original work is given appropriate credit. Contents may not be used for commercial purposes, or adapted, remixed, transformed or built upon. (<https://creativecommons.org/licenses/by-nc-nd/4.0/>)
Thieme Medical and Scientific Publishers Pvt. Ltd., A-12, 2nd Floor, Sector 2, Noida-201301 UP, India

involvement, which was bilateral in 84% of cases. The other region affected was the groin in five patients (26.3%), while two had inframammary involvement (10.5%). On further characterization of the type of lesion, nodules (41; 40.6%) were the most common type of lesion by sinuses and thickened hair follicles in 31 (30.6%) patients. Based on USG findings, the management of 26% of patients was changed from medical to surgical intervention.

Conclusion USG and Doppler are noninvasive bedside tools for the examination of HS, which helps to rule out differentials and delineate the extent and depth of the disease better by picking up subclinical lesions and help in determining disease activity by Doppler, which in turn helps in planning appropriate medical and surgical management of patients. It also identifies radiological parameters that help identify patients who could fail medical management.

Introduction

Hidradenitis suppurativa (HS) is a chronic inflammatory dermatological disorder of multifactorial etiology affecting the apocrine gland-bearing intertriginous regions of the body. Besides causing significant morbidity, HS's psychosocial impact on patients' quality of life is tremendous, with increasing loss of workdays, social stigma, depression, anxiety, and suicidal tendencies affecting patients.¹⁻⁵ While initially believed to be a disorder of the apocrine glands, it has now been established that it is a follicular disorder with inflammation commencing in the hair follicles. A multimodal etiology including genetic (mutations in the Notch and γ -secretase pathways and the inflammasome), dysfunctional cutaneous microbiome and environmental factors like diet, smoking, obesity, hormonal factors, and mechanical stress have been postulated to play a role in disease development.⁶⁻¹²

The first attempt at radiological imaging of HS was via mammography in 1990,¹³ while the use of ultrasonography (USG) in HS has been more recent. USG evaluation of the skin was first used by Alexander in 1979 to measure cutaneous thickness.¹⁴ The major limitation in initial attempts to use USG as a modality in skin disorders was the limited resolution of USG machines. With the advent of dedicated high-frequency transducer probes and advanced software, USG can readily delineate the epidermis, dermis, subcutaneous tissue and fascia in detail and is used to aid differentiation between benign and malignant tumors, detect foreign bodies and subdermal implants, detect skin changes in systemic diseases, and provide objective assessments for various cutaneous disorders.

With varied clinical presentation and treatment-modified morphological presentation and lack of knowledge of primary lesions, there are chances of missing out on the diagnosis of HS and, at times, overdiagnosing it (► **Table 1**: Differentials of HS).¹⁵ Thus, USG may help as a noninvasive modality with good sensitivity and specificity.

USG examination has a definitive role in managing HS as an adjunct to clinical examination, differentiating it from clinical mimics and establishing the diagnosis, staging the

disease, assessing disease activity, and predicting response to treatment.

Criteria for diagnosing HS on USG have been well established¹⁶ (► **Table 2**), and a grading system for assessing the severity of the disease has also been proposed¹⁶ (► **Table 3**).

There is a paucity of data on the utility of USG in HS among dermatologists, radiologists, and surgeons alike, especially in India, with the lack of standard reporting systems making it difficult to manage HS and assess therapeutic response. The data regarding HS patients in India is scarce, and the role of USG in managing HS in Indian centers has not been established. We aimed to assess the severity of HS by clinical and sonographic methods in suspected cases of HS and determine if the predecided therapy based on clinical severity was appropriate. We also aimed to identify the risk factors on USG findings that can predict the failure to respond to treatment and changing the management line from medical to surgical. Our secondary aim was to exclude differentials and define the classical skin features of HS on USG.

Table 1 Differential diagnosis of HS

| Differential diagnosis of HS | |
|------------------------------|---------------------------|
| Early lesions | Late lesions |
| Acne vulgaris | Actinomycosis |
| Carbuncle | Anal fistula |
| Cellulitis | Cat scratch disease |
| Cutaneous blastomycosis | Crohn's disease |
| Dermoid cyst | Granuloma inguinale |
| Erysipelas | Ischiorectal abscess |
| Folliculitis | Lymphogranuloma venereum |
| Furuncle | <i>Nocardia</i> infection |
| Inflamed epidermoid cysts | Noduloulcerative syphilis |
| Lymphadenopathy | Pilonidal disease |
| Perirectal abscess | Tuberculosis abscess |
| Pilonidal cyst | Tularemia |

Abbreviation: HS, hidradenitis suppurativa.

Table 2 Criteria for the diagnosis of HS on ultrasonography

| Criteria for diagnosis of HS on ultrasonography | |
|---|---|
| | <ul style="list-style-type: none"> • Widening of the hair follicles • Thickening or abnormal echogenicity of the dermis • Dermal pseudocystic nodules (round or oval-shaped hypoechoic or anechoic nodular structures) • Fluid collections (anechoic or hypoechoic fluid deposits in the dermis or hypodermis connected to the base of widened hair follicles) • Fistulous tracts (anechoic or hypoechoic band-like structures across skin layers in the dermis or hypodermis connected to the base of widened hair follicles) |

Abbreviation: HS, hidradenitis suppurativa.

Table 3 HS SOS Grading

| Sonographic system for HS | |
|---------------------------|---|
| I | Single fluid collection and dermal changes (hypoechoic or anechoic pseudocystic nodules, widening of the hair follicles, alterations in the dermal thickness or echogenicity) affecting a single body segment (e.g., axilla, groin, breast, buttock) (uni- or bilateral) without fistulous tracts |
| II | Two to four fluid collections or a single fistulous tract with dermal changes affecting up to two body segments (uni- or bilateral) |
| III | Five or more fluid collections or two or more fistulous tracts with dermal changes or involvement of three or more body segments (uni- or bilateral) |

Abbreviation: HS, hidradenitis suppurativa.

Materials and Methods

An observational cross-sectional study involving the patients suspected of HS was conducted at the Department of Dermatology and Department of Plastic Surgery at Dr Ram Manohar Lohia Hospital.

The study population consisted of patients who met the clinical diagnostic criteria of HS, defined by recurrent painful or suppurating lesions more than or equal to two times over 6 months. These lesions were described as nodules, abscesses, fistulous tracts, and scarring, involving more than or equal to one of the following areas: axilla, genitofemoral area, perineum, gluteal area, and the inframammary area in women.

All study participants were subjected to a detailed history and examination for the detection of inflammatory or non-

inflammatory nodules, abscesses, fistula tracts and sinuses in the axilla, the mammary region, inguinal region, periumbilical area, buttocks, thighs, and perineal area and Hurley's clinical staging was done for the same. Based on Hurley's grading, patients are divided into three stages: Stage I being single or multiple isolated nodules and abscesses without sinus tracts or scarring, stage II showing recurrent abscesses with more than or equal to one sinus tract and scarring, separated by normal skin, and stage III denoting multiple lesions coalescing into inflammatory plaques, with extensive sinuses and scarring involving the entire region. Images of representative lesions graded by Hurley's grading are given in **Fig. 1**. The USG assessment and color Doppler were done after the clinical examination using the Mindray i9 Resona with L20-5S probe and GE Voluson E8 with the ML6-15

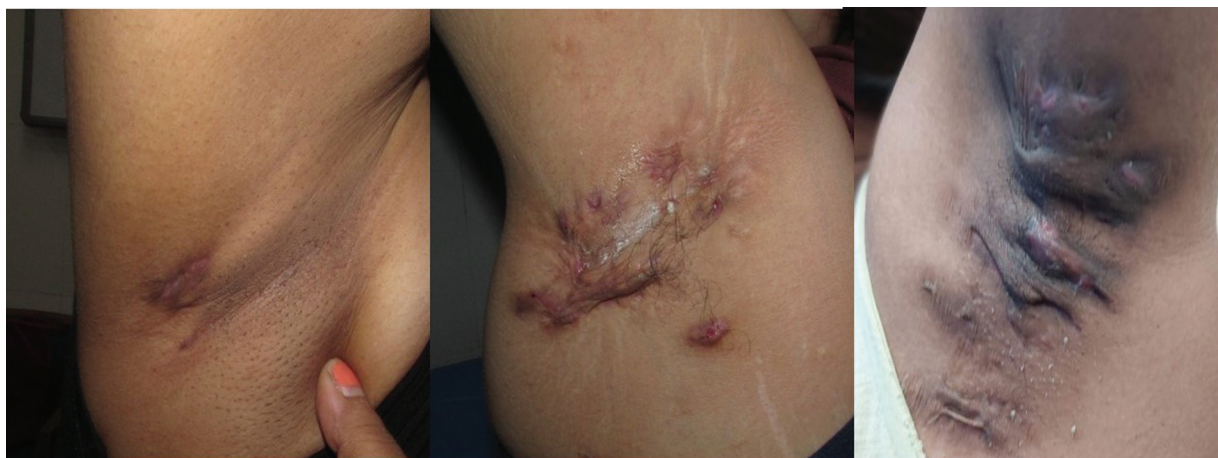


Fig. 1 Clinical image of the right axilla of a patient with Hurley's staging, left to right, grade I, II, and III, respectively.

probe, and patients were graded per the HS SOS by a consultant radiologist.

The primary outcome was to correlate the clinical and sonographic staging and assess the difference in the diagnostic staging between both examinations (clinical vs. USG).

All patients were treated per institutional protocols, based on existing evidence and antibiograms and changes in active line of management post-USG were documented. Patients with Hurley's grade I and II were managed medically with minocycline 100 mg twice daily, linezolid 600 mg twice daily for 2 to 3 weeks along with adapalene 2.5%, and benzoyl peroxide 2.5%, following which they were maintained on 100 mg of minocycline and topical agents. In the case of nonresponders, adalimumab (ADA) was administered, with an initial dose of 80 mg followed by 40 mg weekly till remission or 12 weeks. Patients with Hurley's grade III were advised operative management for axillary disease with wide local excision with a 2 cm margin and reconstruction with a pedicled latissimus dorsi flap with medical management of other sites involved.

Statistical Analysis

Descriptive statistics, consisting of demographic variables and disease characteristics, including USG and clinical findings, were applied to our data.

Results

The patient details and findings are summarized in ►**Supplementary Table S1**. The salient features of HS seen on USG are shown in ►**Fig. 2**. Of the 23 patients who underwent USG, 12 patients (52%) were male, and the mean age of the patients was 25.3 years (range: 14–40 years). Among the 23 patients, 11 patients (47.8%) were Hurley's stage I, six patients (26%) were Hurley's stage II, and six patients (26%) were Hurley's stage III. While on HS-SOS staging, three patients were found not to have HS, and among the remaining twenty patients, three patients (15%) were categorized as HS-SOS Grade I, seven patients (35%) were HS-SOS grade II, and ten patients (50%) were HS-SOS grade III. A comparison of clinical and USG grading has been done in ►**Fig. 3**. Of the patients with USG features suggestive of HS, nineteen patients (95%) had axillary involvement, which was bilateral in all but three cases. The other region involved was the groin in five patients (26.3%), while two had infra-mammary involvement (10.5%). Of all 20 patients with USG features of HS, nodules were the most common type of lesions, followed by sinuses, thickened hair follicles, and fistulas. Twelve patients showed dermal thickening, and four abscesses were seen. Most patients showed

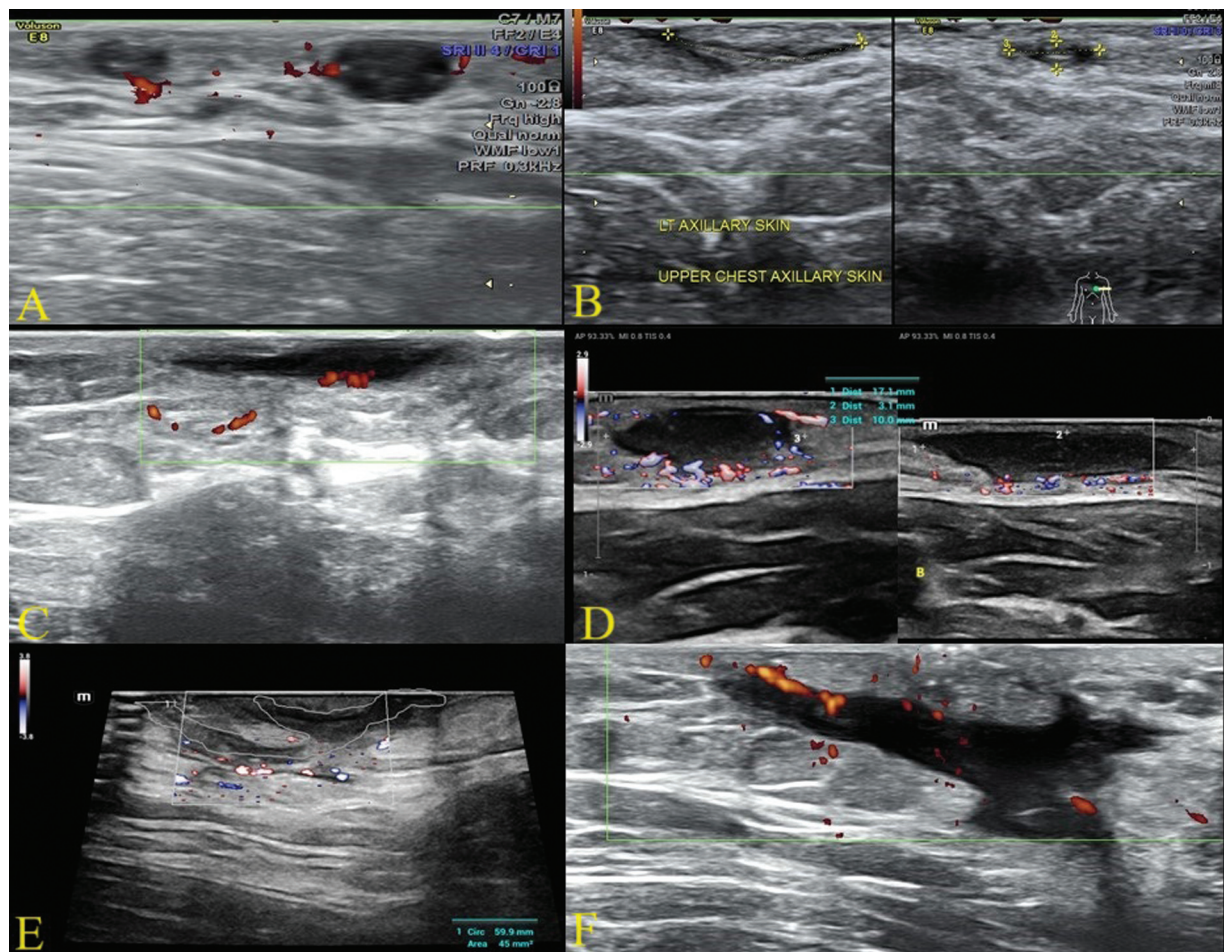


Fig. 2 Ultrasound findings in hidradenitis suppurativa. (A) Dermal pseudonodules. (B) A thickened hair follicle with images showing the length and breadth of the hair follicle. (C) A dermal fluid collection. (D) Dermal abscess with increased vascularity. (E) An interconnecting fistula in the dermis connecting the base of many hair follicles. (F) An interconnecting fistula extending into the subcutaneous tissue.

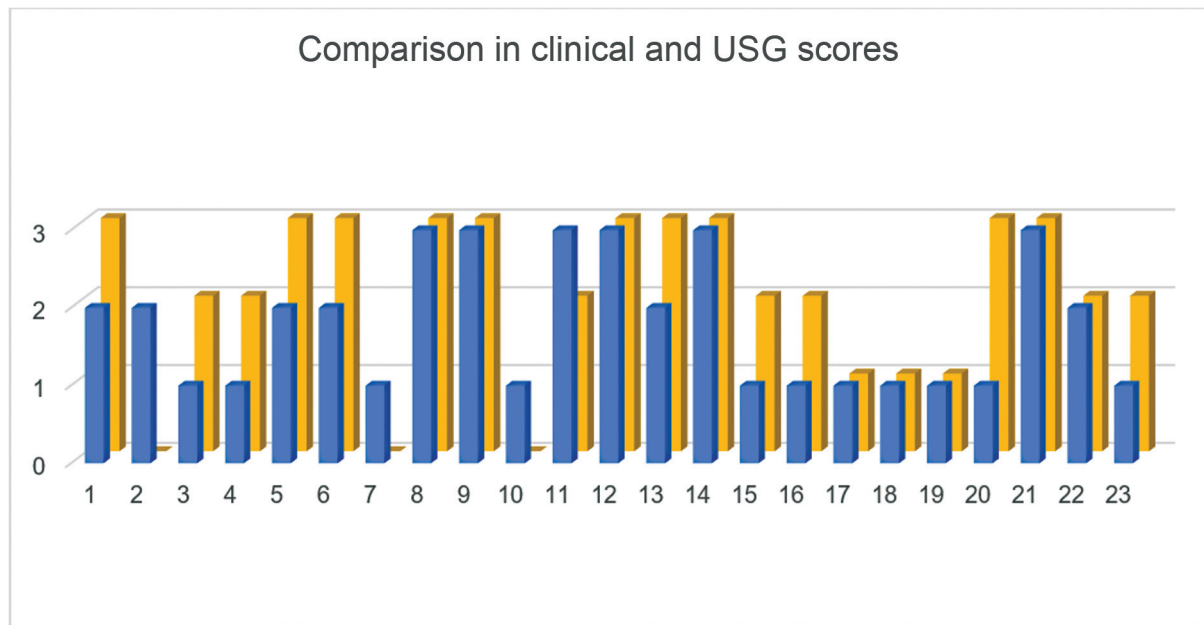


Fig. 3 Comparison between Hurley's and HS-SOS scoring systems of patients. Blue bars represent Hurley's staging of patients, while the yellow bars represent the HS-SOS scoring. An HS-SOS score of zero was given to patients who did not show any ultrasonography (USG) features of HS. HS, hidradenitis suppurativa.

lymphadenopathy, which was always reactive. The findings are tabulated in ►Table 4.

Our study showed that the grading of HS was underestimated in ten (50%) patients on clinical examination when compared to USG and clinical misdiagnosis was seen in three (13%) patients, while USG misdiagnosed a single patient (5%). One patient with perianal and scrotal involvement had extensive intra-anal fistulas seen on USG and was found to have Crohn's disease, while two patients were diagnosed with recurrent folliculitis. A patient with a single dermal nodule diagnosed as HS SOS grade I on USG was followed up, and a retrospective diagnosis of folliculitis was made. The extent of involvement on USG was more significant than that found on clinical examination, with subclinical nodules, thickened hair follicles, and dermal thickening delineated on USG examination.

In established cases of HS, the USG scores (mean score of 2.04) were found to be higher than the clinical scores (mean score of 1.78). Thus in, six patients (26%) the management

was changed from medical to surgical treatment, and three patients (13%) had an alternate diagnosis.

Discussion

While the prevalence of HS in India has not been well-established, global studies have reported varying prevalence of HS in different parts of the world, ranging from 0.03 to 4%.¹⁷ In our study, among the 20 USG-confirmed cases of HS 11 patients (55%) were male, while the remainder were female. Our findings were in concordance with an Indian study in a tertiary hospital which demonstrated that out of 22 patients assessed over 2 years, 10 patients (45%) were male and more than half the patients presented with Hurley's stage III.¹⁸ The varied presentation and large differentials of HS misdiagnosis at early stages could explain the predominance of an advanced presentation apart from the fact that tertiary hospitals have a referral bias of late-stage patients. In our study, 26% of patients were Hurley's stage III, while 50% were HS SOS grade III on USG, indicating that USG

Table 4 Frequency of USG findings in HS

| Sl. no. | USG finding | Number | Percentage |
|---------|-------------------|--------|------------|
| 1 | Nodules | 41 | 40.6 |
| 2 | Sinus | 31 | 30.7 |
| 3 | Fistula | 13 | 12.9 |
| 4 | Dermal thickening | 12 | 11.9 |
| 5 | Abscess | 4 | 3.9 |
| | Total | 101 | 100 |

Abbreviations: HS, hidradenitis suppurativa; USG, ultrasonography.

is more sensitive in picking up the severity of the disease than plain clinical examination and can further guide management appropriately.

In our study, on comparing clinical examination and USG, HS was wrongly diagnosed in three of twenty-three patients (13%). This is significant as the diagnosis of HS is a chronic and often recalcitrant disease and misdiagnosis can have profound psychological impact on patients. In contrast, of the USG-confirmed cases, a single patient (5%) was wrongly diagnosed as HS. Details of the patients who were misdiagnosed are enumerated in **►Supplementary Table S2**.

Human skin consists of three layers, the epidermis, dermis and subcutis, from superficial to deep. On USG, the epidermis appears as a hyperechoic line, with thickness ranging from 0.3 to 0.6 mm. This could be attributed to the high keratin content in the epidermis, which reflects USG waves. The dermis appears hypoechoic and has a thickness between 0.5 and 3 mm. It can be further differentiated into the papillary and reticular dermis. The subcutis is also hypoechoic, with hyperechoic elements representing fatty tissue and fibrous septae. The thickness of the epidermis ranges from 5 to 20 mm.²⁰ The color Doppler of the lesions can show a change in vascularity with slow arterial and venous flow and can be used as an adjunct modality to assess active inflammation.

In our study, inflammatory nodules were the most common USG finding, followed by sinuses and fistulas. USG examination of the normal hair follicles reveals elongated low echogenic parallel strands spaced at regular intervals, angled at 45 to 60 degrees to the skin surface, while increased diameter and distorted shape was evident in follicles involved in HS.¹⁹ Ultrahigh-frequency USG probes show fragmentation of keratin from hair shafts and keratin bands as an early change in HS.²⁰ It is hypothesized that fragmented keratin can mount an inflammatory response, and the stiff keratin bands that connect pus-emanating ostia could act as a scaffold for fibrosis, leading to tunnel formation. Another early change in HS is the presence of widened hair follicles (with the widening of the base of the hair follicle christened

as the champagne bottle sign).²¹ In our study, we found thickened hair follicles in multiple patients. We could also demonstrate echogenic hair follicles within the sinus tracts, which are the hair shafts embedded within the tracts consistent with previous reports of these findings.^{19,21} We saw thickened hair follicles and sinuses in 30% of total lesions demonstrated on USG. Inflammation may lead to the formation of dermal pseudocystic nodules and fluid collections. Within abscesses and pseudocysts, the retained hair shafts appear as bilaminar hyperechoic structures,²² with the prevalence of retained hair shafts being greater in pediatric HS patients than in adults.²³ Ultimately, fibrosis and the formation of fistulous tracts may occur. We noted sinuses in 30% and fistulas in 13% of cases. Fistulous tracts are visualized as anechoic and hypoechoic dermal/hypodermal structures running across skin layers connected to the base of the hair follicle.²¹ Sinus tracts in HS have also been classified as A-D, with different subclasses showing different responses to medical management (**►Table 5**).²⁴ Another proposed classification scheme for the classification of fistula, which uses color Doppler, divides it into three subtypes.²⁵

We also found lymph node enlargement in many of our patients on USG, which was more common in higher HS SOS grading. The lymph node enlargement was reactive and secondary to infection in all cases. Our findings were consistent with previously described findings that enlargement of lymph nodes may be seen on USG examination in late and severe disease due to infection rather than being a part of the disease process.²¹

We did not note any comedones on USG, although it has been reported that USG may also visualize tombstone comedones better. Tombstone comedones are visualized as hypoechoic oval lesions that have undefined edges. They might have minute hyperechoic components with bilateral skin openings.²⁶

A potential benefit of USG examination is therapeutic modification and depending on the findings some patients can be switched from medical to surgical line of

Table 5 Classification of fistulous tracts on ultrasonography

| Type | Feature | Therapeutic implication |
|------|--|--|
| A | Dermal fistula: nonscarring fistula that represents the result of the coalescence of 2 or more abscesses that are located in the dermal layer with no connections with the epidermis and the subcutaneous fat tissue | Early disease stage, good response to antibiotics, dapsone as well as adalimumab |
| B | Dermoepidermal fistula: nonscarring fistula that shows a connection with the dermo-epidermal junction | With lesser response rates than type A fistula, suppressing inflammation is more suitable than treating acute flares |
| C | Complex fistula: scarring fistula composed of one or more tracts that coalesce in a localized skin area, surrounded by scarring tissue in the periphery | A surgical approach may yield better results than medical management |
| D | Subcutaneous fistula: fistula that penetrates through the subcutaneous fat tissue and muscular fascia without extension to the bowel complex | Aggressive treatment to prevent extension to underlying tissue. An MRI may be done to rule out rectal, anal, bladder involvement or deeper extension |

Abbreviation: MRI, magnetic resonance imaging.

management. In our study treatment was modified from medical to surgical in 26% of patients. In contrast, in a study that used USG for evaluating HS, a change in medical management was instituted in 84% of cases.¹⁶ Among previous studies that assessed a change in management, the change was even more significant in pediatric HS as the condition is more challenging to diagnose in this age group and there was a modification in the treatment after USG in 11 of 12 pediatric patients.²³

USG can also be used preoperatively to delineate the extent of involvement, mark surgical borders, and might result in better surgical outcomes.²⁷ It can also guide intralesional triamcinolone injections, which have some role in managing HS.²⁸ Complete resection of involved skin can be curative, and wide local excision, a major surgical procedure, can be associated with a recurrence rate of 13 to 33%.^{29,30} Thus, excising all the involved skin in a single setting is helpful to reduce the recurrences in HS. By picking up subclinical lesions and changes in adjacent skin, surgical borders could be chosen more objectively, reducing recurrence and avoiding excessive excision, improving cosmesis, and decreasing patient morbidity.

Color Doppler of the lesions shows increased vascularity with slow arterial and venous flow. This vascularity has been demonstrated to reduce following ADA injection. Though the vascularity of lesions decreases markedly after ADA injection, the amount of fibrosis increases. This might explain why traditional scoring systems like Hurley's staging do not show a corresponding decrease in severity after ADA injection, as noninflammatory fibrotic lesions continue to be counted in severity scorings. Doppler changes in USG have been divided according to resistivity index into high (>0.7) and low (<0.7).³¹ It has also been shown that this resistivity index drops with progression from the nodular to the fistular stage of the disease, probably due to increased vascularity and vasodilation in the chronic inflammatory stage. In our study, we observed Doppler changes in eighteen (75%) patients. Patient number 18 in our series was managed with rifampicin and clindamycin for 1 year for two nodules in the axilla. There were no new nodules since the initiation of therapy. Doppler showed no vascularity, and the medications were ceased. Doppler thus helps assess disease activity and may help avoid unnecessary and prolonged antibiotics. Patient 20 had hyperemia in the left axilla and groin lesions but not in the right axilla. Observations like these could help assess therapy response and plan surgical interventions. Another potential use of Doppler could be to assess which lesions are

active as we observed that hyperemia in only few of the involved sites and not all areas. Limited areas of activity could be managed by local therapy like intralesional steroids, avoiding the side effects associated with systemic treatments.

In our study, USG assessment found a higher staged severity in 10 patients (50%). It has been established that solely relying on clinical examination underestimates the severity of HS, with USG being able to detect and differentiate lesions like abscesses, nodules, and fistulae better and also visualize subclinical lesions, revealing more severe HS. This may explain the lack of concurrence between USG and clinical scoring in higher grades. Multiaxial imaging done by USG can measure the three-dimensional size of the lesions in millimeters, which adds objectivity and helps assess the depth, which is particularly difficult in the body's folds.

Another therapeutic challenge in the Indian subcontinent is the coexisting endemicity of tuberculosis and the emerging threat of multidrug resistant tuberculosis, which limits the use of rifampicin monotherapy and newer fluoroquinolones in HS management to prevent drug resistance. Most centers in India do not conduct routine USG on HS patients due to a lack of awareness among dermatologists, radiologists, and plastic surgeons. Limited financial resources of a significant proportion of patients and high tuberculosis prevalence also preclude the use of ADA in most cases. In our experience, women with HS, who may have clinically less severe disease, experience more stigma and are frequently socially isolated compared to their male counterparts. Many patients suffer from stigma due to the disease being attributed to a contagious nature. People with sole perineal involvement may be ostracized due to the disease being attributed to a sexually transmitted nature. At the same time, some patients may be vilified as the disease, though multifactorial is attributed to be related to obesity and considered to be due to patients' unhealthy lifestyle. To the best of our knowledge, this is the first study from India assessing USG as an evaluation tool for HS with the notable finding of a change in treatment based on change HS staging of USG and clinicians should implement the potential advantages of USG (→ **Table 6**).

Limitations

Our single-center study consisted of only the North Indian population with a short follow-up time. Furthermore, the study was conducted in a tertiary care referral center, with a significant proportion of advanced, recalcitrant,

Table 6 Potential uses of USG

| Uses of USG in HS |
|---|
| 1. Guiding Biopsies for diagnosing HS |
| 2. USG-guided interventions like injection of steroids, drainage of abscesses |
| 3. Establishing USG Biomarkers for disease severity and predicting response to treatment |
| 4. Assessing disease activity by Doppler and studying the effect of medical therapy on the inflammatory process |
| 5. Marking of the surgical borders preoperatively |
| 6. Detecting postoperative recurrence |
| 7. Delineating perianal fistulas clearly |

Abbreviations: HS, hidradenitis suppurativa; USG, ultrasonography.

misdiagnosed, and mismanaged cases. Due to the small sample size, a correlation between clinical and USG staging was not found to be significant. Follow-up USG and Doppler could not be undertaken after patients were started on medications.

Its major limitation of USG in HS is its inability to visualize lesions less than 0.1 mm³² and the difficulty in differentiating between acne, pilonidal sinus, and folliculitis lesions.^{13,33} This seems consistent with our series in which a patient diagnosed with folliculitis and acne vulgaris showed features identical to HS on USG. Other limitations include impediments in imaging extrasphincteric and suprasphincteric extensions attributable to poor beam penetration.¹³ We encountered this limitation while evaluating perianal lesion in a suspect HS patient, although we could rule out HS using USG. Extensive fibrosis has also been shown to reduce the utility of USG, even intraoperatively.³⁴ We, however, did not encounter such difficulties as marginal skin surrounding the tissue and other sites showed features of HS features.

Conclusion

USG forms a valuable tool in managing HS by helping to rule out differentials and assessing the extent and severity of involvement more accurately. USG, however, fails to differentiate HS from disorders of similar pathology, characterized by follicular hyperkeratosis followed by the formation of nodules and cysts such as folliculitis, acne, and probably pilonidal sinus. Clinical correlation is inescapable in these cases as these disorders commonly coexist. USG is a non-invasive imaging modality that can be readily utilized in pediatric and pregnant populations. According to recent evidence, it is prudent to do an USG at baseline and then monitor according to the severity of the lesions.³⁵ Detecting features like extensive fistula and subcutaneous involvement, which is more recalcitrant to medical therapy, help expeditiously plan surgical management, avoiding morbidity and unnecessary medical therapy. More extensive multicenter studies are required to assess the relevance and cost-benefit ratio of USG in India and its role in both initiating medical therapy and surgical intervention and follow-up.

Conflict of Interest

None declared.

Acknowledgements

We want to acknowledge Dr. Sanjeet Panesar, Ms. Sonia Jain, and Mr. Jatin for their contributions to the manuscript.

References

- Singh R, Kelly KA, Senthilnathan A, Feldman SR, Pichardo RO. Stigmatization, a social perception which may have a debilitating impact on hidradenitis suppurativa patients: an observational study. *Arch Dermatol Res* 2023;315(04):1049–1052
- von der Werth JM, Jemec GB. Morbidity in patients with hidradenitis suppurativa. *Br J Dermatol* 2001;144(04):809–813
- Matusiak Ł, Bieniek A, Szepletowski JC. Hidradenitis suppurativa markedly decreases quality of life and professional activity. *J Am Acad Dermatol* 2010;62(04):706–708, 708.e1
- Machado MO, Stergiopoulos V, Maes M, et al. Depression and anxiety in adults with hidradenitis suppurativa: a systematic review and meta-analysis. *JAMA Dermatol* 2019;155(08):939–945
- Thorlaciuc L, Cohen AD, Gislason GH, Jemec GBE, Egeberg A. Increased suicide risk in patients with hidradenitis suppurativa. *J Invest Dermatol* 2018;138(01):52–57
- Jfri AH, O'Brien EA, Litvinov IV, Alavi A, Netchiporouk E. Hidradenitis suppurativa: comprehensive review of predisposing genetic mutations and changes. *J Cutan Med Surg* 2019;23(05):519–527
- Chung MG, Preda-Naurescu A, Yusuf N. Hidradenitis suppurativa: consequences of microbiome dysbiosis on immune dysregulation and disease severity. *Indian J Dermatol* 2022;67(06):699–704
- Danby FW. Diet in the prevention of hidradenitis suppurativa (acne inversa). *J Am Acad Dermatol* 2015;73(5, Suppl 1):S52–S54
- Garg A, Papagermanos V, Midura M, Strunk A. Incidence of hidradenitis suppurativa among tobacco smokers: a population-based retrospective analysis in the U.S.A. *Br J Dermatol* 2018;178(03):709–714
- Kaleta KP, Nikolakis G, Hossini AM, et al. Metabolic disorders/obesity is a primary risk factor in hidradenitis suppurativa: an immunohistochemical real-world approach. *Dermatology* 2022;238(02):251–259
- Karagiannidis I, Nikolakis G, Sabat R, Zouboulis CC. Hidradenitis suppurativa/Acne inversa: an endocrine skin disorder? *Rev Endocr Metab Disord* 2016;17(03):335–341
- Boer J, Jemec GBE. Mechanical stress and the development of pseudo-comedones and tunnels in hidradenitis suppurativa/acne inversa. *Exp Dermatol* 2016;25(05):396–397
- Gutfilen-Schlesinger G, Lopes de Souza SA, Gutfilen B. Should we scan hidradenitis suppurativa patients? A systematic review of radiologic findings. *Adv Skin Wound Care* 2021;34(07):1–10
- Alexander H, Miller DL. Determining skin thickness with pulsed ultra sound. *J Invest Dermatol* 1979;72(01):17–19
- Okoye GA. *Hidradenitis Suppurativa*. In: Kang S, Amagai M, Enk A, Eds. *Fitzpatrick's Dermatology*. 9th ed New York: McGraw-Hill; 2019:1485
- Wortsman X, Moreno C, Soto R, Arellano J, Pezo C, Wortsman J. Ultrasound in-depth characterization and staging of hidradenitis suppurativa. *Dermatol Surg* 2013;39(12):1835–1842
- Jemec GBE, Kimball AB. Hidradenitis suppurativa: epidemiology and scope of the problem. *J Am Acad Dermatol* 2015;73(5, Suppl 1):S4–S7
- Kamat D, Gaba S, Kumaran MS. Clinico-epidemiological characteristics of hidradenitis suppurativa: a retrospective cohort study from a tertiary care centre in Northern India. *Indian Dermatol Online J* 2021;12(04):561–565
- Jemec GB, Gniadecka M. Ultrasound examination of hair follicles in hidradenitis suppurativa. *Arch Dermatol* 1997;133(08):967–970
- Wortsman X, Calderon P, Castro A. Seventy-MHz ultrasound detection of early signs linked to the severity, patterns of keratin fragmentation, and mechanisms of generation of collections and tunnels in hidradenitis suppurativa. *J Ultrasound Med* 2020;39(05):845–857
- Wortsman X. Imaging of hidradenitis suppurativa. *Dermatol Clin* 2016;34(01):59–68
- Nazzaro G, Zerboni R, Passoni E, et al. High-frequency ultrasound in hidradenitis suppurativa as rationale for permanent hair laser removal. *Skin Res Technol* 2019;25(04):587–588
- Wortsman X, Rodriguez C, Lobos C, Eguiguren G, Molina MT. Ultrasound diagnosis and staging in pediatric hidradenitis suppurativa. *Pediatr Dermatol* 2016;33(04):e260–e264

- 24 Martorell A, Giovanardi G, Gomez-Palencia P, Sanz-Motilva V. Defining fistular patterns in hidradenitis suppurativa: impact on the management. *Dermatol Surg* 2019;45(10):1237–1244
- 25 Wortsman X, Castro A, Figueroa A. Color Doppler ultrasound assessment of morphology and types of fistulous tracts in hidradenitis suppurativa (HS). *J Am Acad Dermatol* 2016;75(04):760–767
- 26 Oranges T, Vitali S, Benincasa B, et al. Advanced evaluation of hidradenitis suppurativa with ultra-high frequency ultrasound: a promising tool for the diagnosis and monitoring of disease progression. *Skin Res Technol* 2020;26(04):513–519
- 27 Lyons AB, Zubair R, Kohli I, Hamzavi IH. Preoperative ultrasound for evaluation of hidradenitis suppurativa. *Dermatol Surg* 2019;45(02):294–296
- 28 Salvador-Rodríguez L, Arias-Santiago S, Molina-Leyva A. Ultrasound-assisted intralesional corticosteroid infiltrations for patients with hidradenitis suppurativa. *Sci Rep* 2020;10(01):13363
- 29 Mehdizadeh A, Hazen PG, Bechara FG, et al. Recurrence of hidradenitis suppurativa after surgical management: a systematic review and meta-analysis. *J Am Acad Dermatol* 2015;73(5, Suppl 1):S70–S77
- 30 Ovardja ZN, Zugaj M, Jacobs W, van der Horst CMAM, Lapid O. Recurrence rates following reconstruction strategies after wide excision of hidradenitis suppurativa: a systematic review and meta-analysis. *Dermatol Surg* 2021;47(04):e106–e110
- 31 Power Doppler ultrasound assessment of vascularization in hidradenitis suppurativa lesions - PubMed [Internet]. [cited 2023 Aug 30]. Accessed February 29, 2024 at: <https://pubmed.ncbi.nlm.nih.gov/29224229/>
- 32 Wortsman X, Wortsman J. Clinical usefulness of variable-frequency ultrasound in localized lesions of the skin. *J Am Acad Dermatol* 2010;62(02):247–256
- 33 Wortsman X, Castro A, Morales C, Franco C, Figueroa A. Sonographic comparison of morphologic characteristics between pilonidal cysts and hidradenitis suppurativa. *J Ultrasound Med* 2017;36(12):2403–2418
- 34 de Vasconcelos PT, Dácio-Ferreira J, Filipe PL. Scrotal elephantiasis secondary to recalcitrant hidradenitis suppurativa. *Indian J Dermatol Venereol Leprol* 2015;81(05):524–525
- 35 Reyes-Baraona F, Herane MI, Wortsman X, et al. [Chilean clinical guideline for the management of hidradenitis suppurativa - executive summary]. *Rev Med Chil* 2021;149(11):1620–1635