



A Composite Seton for the Management of Fistula in Ano

Sujith Philip¹ Geethu Rachel Iype¹ Meera Muralee¹

¹Department of Gastrointestinal Surgery, Believers Church Medical College Hospital, Thiruvalla, Kerala, India

J Coloproctol 2024;44(2):e95–e97.

Address for correspondence Sujith Philip, MS, DNB, MNAMS, Department of Gastrointestinal Surgery, Believers Church Medical College Hospital, St Thomas Nagar, Kuttapuzha, Thiruvalla, Kerala, India 689103 (e-mail: drsujithphilip@gmail.com).

Abstract

Treatment of fistula in ano by seton has become less in vogue due to the complications and disadvantages associated with its use. In its place, more technically demanding and expensive procedures, with less morbidity but more recurrence, such as endorectal advancement flaps and laser, are being employed more commonly. To overcome some of the limitations of conventional seton, we have designed a composite seton. In the present study, we evaluated our experience with a composite seton made from two silastic vessel loops sutured together with 5-0 polypropylene. The composite seton was found to not present many of the disadvantages of the conventional seton. The use of the composite seton resulted in low incontinence and recurrence rates, less pain, and high quality of life. This technically simple and cheaper material may have a wider applicability.

Keywords

- fistula in ano
- composite seton

Introduction

Fistula in ano is thought to originate from cryptoglandular infection with resultant perirectal abscess. An abscess is suggestive of an acute inflammatory event, whereas a fistula is suggestive of a chronic event. Surgery remains the treatment of choice. The aims of surgery are to control sepsis, to remove the fistulous tract, to prevent recurrence, and to preserve sphincter function.¹

Simple fistulas can be treated easily with fistulotomy. However, fistulas which involve more than 30 % of the sphincter complex require alternative treatment options. Techniques with the use of seton still occupy an important position in the treatment of high anal fistulas and in specific settings in simple fistulas².

Based on the type of fistula and associated conditions, cutting seton or drainage seton may be used. A cutting seton can be used in a single or staged procedure. Currently, cutting setons are not commonly used in modern settings

because of the pain associated with treatment, the uncontrolled cutting of sphincter muscles, the chance of incontinence, prolonged discharge and interference with the patient's quality of life, numerous visits to check and adjust the seton, and other complications, like the seton falling off.^{3,4}

To overcome some of the limitations of conventional setons, we have been using an indigenously designed composite seton for the past five years. Due to its unique design, it does not present many of the disadvantages associated with the conventional seton, as it will be explained later. The present study evaluates our experience with this composite seton.

Materials and Methods

In the present study, we have performed a prospective review of the data of 28 patients treated with composite seton, which was used in the following settings:

received

May 27, 2023

accepted after revision

February 7, 2024

DOI <https://doi.org/>

10.1055/s-0044-1782628.

ISSN 2237-9363.

© 2024. The Author(s).

This is an open access article published by Thieme under the terms of the Creative Commons Attribution 4.0 International License, permitting copying and reproduction so long as the original work is given appropriate credit (<https://creativecommons.org/licenses/by/4.0/>).

Thieme Revinter Publicações Ltda., Rua do Matoso 170, Rio de Janeiro, RJ, CEP 20270-135, Brazil

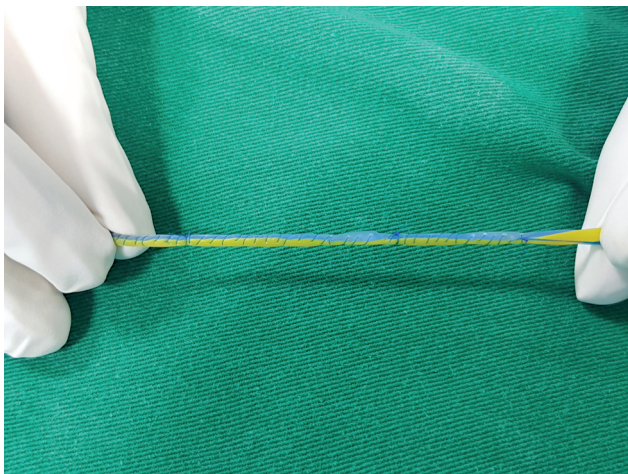


Fig. 1 Preparation of the composite seton by suturing together 2 vessel loops with 5-0 polypropylene.

- Complex fistulas (high transsphincteric, suprasphincteric, extrasphincteric) or multiple fistulas;
- Recurrent fistulas after previous fistulotomy;
- Anterior fistulas in female patients;
- Poor preoperative sphincter pressures;
- Patients with Crohn disease or patients who are immunosuppressed; and
- Transsphincteric fistula with more than 30% of involvement of the sphincter

A magnetic resonance imaging (MRI) fistulogram was performed in patients suspected to be in any of the aforementioned settings based on history and clinical examination. Surgery was performed with the patients in lithotomy position. After a partial fistulotomy, the composite seton was placed across the sphincter.

The composite seton was made by suturing together two silastic vessel loops of different colors (to help suturing) with 5-0 polypropylene continuous sutures for

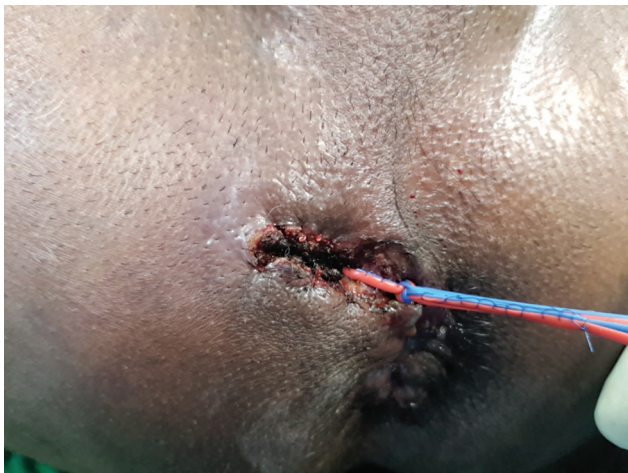

Fig. 2 The composite seton after application.

a length of at least 10cm. The length of suture is determined by the amount of sphincter muscle being traversed. The vessel loop part of the composite seton functions as the draining part. The loop's soft nature ensures less discomfort while the thin but stiff 5-0 polypropylene sutures with which the vessel loops are sutured together in the middle function as the cutting part. The size and nature of the thin gauze monofilament suture ensures gradual cutting through the sphincter. The vessel loops are then tied with only two square knots. The vessel loops are tied snugly and are neither loose nor tight (figures 1,2).

Patients are usually discharged on day 1 and called for review on weeks 2, 4, and 8 if seton has not fallen off, and then, at 12 and 24 weeks. If the fistula has healed before review, then follow-up over the telephone is performed.

The composite seton is inspected during review and if it becomes loose then it is made snug again, with care taken not to make it too tight nor too loose. The parameters mentioned in ►Table 1 were measured. Pain was measured with Visual Analogue Scale (VAS).⁵

Results

Table 1 Demographics and results

Features	Number	Percentage
Mean age	54	—
Male patients	18	64.28
Female patients	10	35.72
Complex fistula	2	7.14
Transsphincteric with more than 30% of sphincter involvement	10	35.71
Crohnsdisease	2	7.1
Recurrent	5	17.85
Anterior fistula in female patient	8	28.57
Poor sphincter pressure	1	3.57
Seton falling off after surgery	1	3.57
Incontinence to flatus at 1 month	11	39.28
Incontinence to liquid stool at 1 month	0	—
Incontinence to solid stool at 1 month	0	—
Complete healing by 24 weeks	26	92.86
Recurrence/Non-healing at 1 year	2	7.1
Pain at 1 week on the Visual Analogue Scale < 30 mm	27	96.42

Discussion

Cutting setons work by progressively transecting the encircled sphincter muscle as a result of pressure necrosis and minimal separation of the cut ends. Several setons and tightening techniques, including silk, rubber band, chemically-treated linen, silastic, Penrose drain, and elastic nylon, have been used.^{6,7} The results of a seton will depend on the type of fistula, the material used, and the tension applied.⁸ An ideal seton should: a) be relatively comfortable to the patient; b) induce fibrosis so that it can cut through, as in the case of cutting setons; c) be able to be easily tightened in outpatient procedures; e) not fall off easily; and f) be easily available. Most setons do not meet all of these criteria. Setons which are comfortable (such as silastic vessel loop) do not induce fibrosis like silk or polypropylene sutures. Sometimes setons need to be kept in the long term; hence, comfort to the patient is important. Those that induce fibrosis (such as thick silk and metal setons) are uncomfortable to the patient.

In the present study, we have endeavored to test a seton which meets all of the aforementioned criteria. Since the seton is made of a silastic vessel loop, which, in turn, is made of soft rubber, it is comfortable to the patient. The 5-0 polypropylene suture is very thin; hence, it doesn't cause discomfort such as thick silk or other types of polypropylene sutures. The polypropylene suture also induces fibrosis. A seton made of only of silastic material doesn't induce fibrosis nor cuts through. The silastic material, when reinforced with polypropylene, can be easily tied and untied in outpatient procedures, since the ends of the vessel loops are left unsutured. The combination of polypropylene suture and silastic material ensures that the knot is secure due to friction and that the seton does not fall off easily. Silastic vessel loops and 5-0 polypropylene are easily available in most operation theatres. Moreover, the nature of this composite seton enables it to be tied neither too loose nor too tight, but just snug enough so that it is comfortable to the patient and time induces fibrosis at the same time.

In the sample of the present study, there were more male patients, as shown in **Table 1**. The seton used as a cutting seton, and the most common indications were transsphincteric fistula with great sphincter involvement, or low anterior fistula in women. One of the main disadvantages of a conventional fistula is the high rate of incontinence.⁹ However, in the present study, there was no incontinence to stool in any of the patients. Though there was incontinence to flatus in 11 patients, it was temporary. There was a 92.9% healing rate when composite seton was used for the aforementioned indications. There was one patient whose fistula did not heal and required another procedure, while another had recurrence; both of them presented complex fistulas. One of the main advantages of complex fistulas is the low level of pain experienced by the patient as measured by the VAS. In the present study, 27 out of 28 patients had a score < 30 mm on the VAS. In the one patient with pain, a fissure developed at the site of seton insertion.

Thus, this composite seton does not present many of the disadvantages associated with the conventional seton

treatment of fistula in ano. Therefore, this technically-simple procedure compared to more technically-demanding or expensive techniques – like endorectal advancement flaps, ligation of the intersphincteric tract (LIFT), and laser – could have wider applicability.

The limitations of the present study were the low number of patients and the short duration of the follow-up. However, considering the nature of the study and the heterogeneity of indications, it is likely that the results will be applicable to a larger population.

Conclusion

The treatment of fistula in ano by seton has become less in vogue due to the complications associated with its use. In its place, more technically demanding procedures, with less morbidity but more recurrence, such as endorectal advancement flaps, laser and LIFT, are being employed more commonly. The present study shows that this indigenously designed composite seton does not present many of the disadvantages of conventional seton, including incontinence. Thus, this procedure, which is technically simpler and with lower rates of recurrence, may have wider applicability due to its low morbidity. However, studies with larger samples are recommended to substantiate the findings.

Conflict of Interests

The authors have no conflict of interests to declare.

References

- Davis BR, Kasten KR. Anorectal abscess and fistula. In: Steele SR, Hull TL, Read TE, Saclarides TJ, Senagore AJ, Whitlow CB, eds. The ASCRS Textbook of Colon and Rectal Surgery. 3rd ed. Vol. 1. New York: Springer; 2016:215–44
- Subhas G, Singh Bhullar J, Al-Omari A, Unawane A, Mittal VK, Pearlman R. Setons in the treatment of anal fistula: review of variations in materials and techniques. *Dig Surg* 2012;29(04): 292–300. Doi: 10.1159/000342398
- Pearl RK, Andrews JR, Orsay CP, et al. Role of the seton in the management of anorectal fistulas. *Dis Colon Rectum* 1993;36 (06):573–577, discussion 577–579
- McCourtney JS, Finlay IG. Setons in the surgical management of fistula in ano. *Br J Surg* 1995;82(04):448–452
- Owen HA, Buchanan GN, Schizas A, Cohen R, Williams AB. Quality of life with anal fistula. *Ann R Coll Surg Engl* 2016;98(05): 334–338. Doi: 10.1308/rcsann.2016.013
- Ritchie RD, Sackier JM, Hodde JP. Incontinence rates after cutting seton treatment for anal fistula. *Colorectal Dis* 2009;11(06): 564–571
- Ege B, Leventoğlu S, Menteş BB, Yılmaz U, Öner AY. Hybrid seton for the treatment of high anal fistulas: results of 128 consecutive patients. *Tech Coloproctol* 2014;18(02):187–193. Doi: 10.1007/s10151-013-1021-z
- Subhas G, Singh Bhullar J, Al-Omari A, Unawane A, Mittal VK, Pearlman R. Setons in the treatment of anal fistula: review of variations in materials and techniques. *Dig Surg* 2012;29(04): 292–300. Doi: 10.1159/000342398
- Vial M, Parés D, Pera M, Grande L. Faecal incontinence after seton treatment for anal fistulae with and without surgical division of internal anal sphincter: a systematic review. *Colorectal Dis* 2010; 12(03):172–178. Doi: 10.1111/j.1463-1318.2009.01810.x