




# Anatomy of the Prostate Gland: Modalities and Techniques for Its Assessment

Gowtham S Mahadevan<sup>1</sup>  Venkatesh Kasi Arunachalam<sup>1</sup> Sriman Rajasekaran<sup>1</sup> Ravindar Kashyap<sup>1</sup>  
Kannan Gunasekaran<sup>1</sup> Suruthi Thirumoorthi<sup>1</sup>

<sup>1</sup> Department of Radiology, Kovai Medical Center and Hospital, Coimbatore, Tamil Nadu, India

J Gastrointestinal Abdominal Radiol ISGAR

**Address for correspondence** Venkatesh Kasi, DMRD, DNB, FRCR, MOI, Department of Radiology, Kovai Medical Center and Hospital, Coimbatore, Tamil Nadu 641014, India (e-mail: radvenki79@gmail.com).

## Abstract

Prostate imaging is indispensable for the diagnosis and management of prostatic carcinoma and other prostate lesions. Understanding imaging anatomy is the basis for accurate diagnosis and standardized reporting of the prostatic lesions. In this article, we will discuss about general anatomy of the prostate, zonal anatomy, imaging techniques for its assessment, modality specific appearance of different zones of the prostate in detail.

## Keywords

- ▶ prostate anatomy
- ▶ prostate cancer
- ▶ prostate imaging
- ▶ prostate MRI
- ▶ prostate USG

## Introduction

The evaluation of prostatic lesions requires knowledge of prostate anatomy, as imaging features may vary depending on the location of the lesions. Exact anatomical localization of lesions is also essential for biopsy targeting and tailoring local therapies. The imaging anatomy of the prostate will be discussed in depth in this article, with different imaging appearances in different imaging modalities.

## General Anatomy

The prostate is a male reproductive organ that surrounds the urethra, inferior to the urinary bladder. Prostate measures approximately  $3 \times 3 \times 5$  cm and 25 mL in volume.<sup>1</sup> The size of prostate varies with age and it weighs around 20 g between 20 and 50 years of age and 30g between 60 and 80 years of age.<sup>2</sup> Prostate produces an alkaline prostatic fluid that is a component of semen. Prostate is an inverted pyramid-shaped structure surrounding the prostatic urethra and extends from the base of the bladder superiorly to the urogenital diaphragm inferiorly (→ **Fig. 1**). Anteriorly prostate is related to the retropubic space of Retzius (retropubic

fatty space), posteriorly it is related to the rectum and separated from it by Denonvilliers fascia. Denonvilliers fascia acts as a barrier to the spread of prostate cancer to the rectum, and it is also closely related to the neurovascular bundle.<sup>3</sup> Inferolaterally, the prostate is related to the levator ani and pelvic side wall muscles. The puboprostatic ligament runs from the pubic bone to the anteroinferior aspect of the prostate anteriorly.

The seminal vesicles are paired structures located posterolateral to the prostate. Each seminal vesicle is around 3 to 5 cm in length and 1 cm in diameter. The seminal vesicles contribute around two-thirds of volume of semen and its secretions are rich in fructose that provides nutrition to sperms. The ducts from the seminal vesicle join the vas deferens and form ejaculatory ducts along the posterolateral margin of the prostate. Ejaculatory ducts measure approximately 1 to 2 cm in length and 2 mm in diameter and traverse through the central zone and drain into the verumontanum.<sup>4</sup> Verumontanum is visualized as a focal prominence in the midprostatic urethra in posterior aspect.

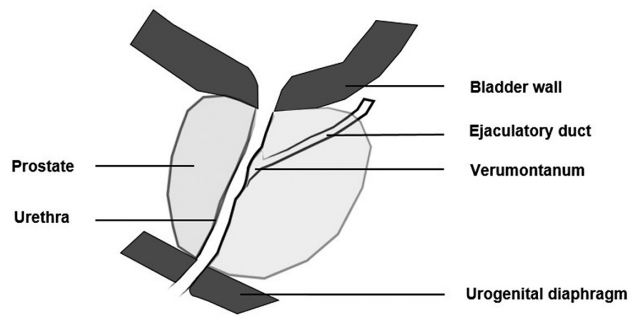
Traditional lobar anatomy dividing the prostate into anterior, posterior, median, and two lateral lobes is superseded by zonal anatomy due to the clinical relevance of the latter,<sup>5</sup> and

DOI <https://doi.org/10.1055/s-0044-1785197>  
ISSN 2581-9933.

© 2024. The Author(s).

This is an open access article published by Thieme under the terms of the Creative Commons Attribution License, permitting unrestricted use, distribution, and reproduction so long as the original work is properly cited. (<https://creativecommons.org/licenses/by/4.0/>)

Thieme Medical and Scientific Publishers Pvt. Ltd., A-12, 2nd Floor, Sector 2, Noida-201301 UP, India



**Fig. 1** General anatomy of prostate gland.

traditional lobar anatomy will not be discussed further in this article.

### Zonal Anatomy of Prostate (-Figs. 2 and 3)

McNeal proposed a zonal anatomy of the prostate based on histology, which is also relevant embryologically.<sup>6</sup> The prostate is composed of three glandular zones: central, transition, and peripheral zones, as well as an anterior fibromuscular stroma that is nonglandular. Embryologically, the prostate is formed by the growth of cells in the urogenital sinus during the third month of gestation.<sup>7</sup> Transition and peripheral zones are derived from the urogenital sinus, while the central zone is derived from the Wolffian duct.<sup>2</sup>

The transition zone surrounds the prostatic urethra. The central zone lies posterior to the transition zone and surrounds both the right and left ejaculatory ducts. The anterior fibromuscular stroma forms the anterior aspect of the prostate and is anterior to the transition zone. The peripheral zone envelops the central and transition zones posteriorly and laterally.

Craniocaudally, the prostate is divided into three equal portions: base, midgland, and apex. The peripheral zone and anterior fibromuscular stroma extend from the base to the apex, while the central zone is seen predominantly at the base of the prostate. The transition zone in young males extends to the verumontanum in the middle of the gland, while in old age it extends to the apex due to nodular hyperplasia of the transition zone.

#### Basic MRI Protocol

Magnetic resonance imaging (MRI) and transrectal ultrasound (TRUS) are two imaging modalities that are commonly used to assess the prostate. MRI is superior to TRUS in the evaluation of the prostate gland. On MRI, T2-weighted axial sequences are ideal for visualizing the zonal anatomy of the prostate. The imaging field in MRI should extend from the superior border of the seminal vesicles to the inferior aspect of the prostatic apex. The axial images are acquired either as true axial sections or perpendicular to the long axis of the prostate. T2 sequences are usually acquired by either fast spin echo or turbo spin echo depending on the vendor, with a 3mm slice thickness and no interslice gap. Ideal field of view is 12 to 20 cm with an in-plane resolution of less than or equal to 0.4mm in the frequency encoding direction and less than or equal to 0.7mm in the phase encoding direction.<sup>8</sup>

#### Prostatic Capsule

The prostate gland does not have a true capsule. Instead, outer fibrous sheath is formed from pelvic fascia inseparable from prostatic stroma. This is visualized as a T2 hypointense structure on MRI in the periphery of the gland that is better seen posteriorly and posterolaterally and is incomplete anteriorly and apically. It is important to identify the fibrous sheath on imaging as it is an important anatomical structure to evaluate extraprostatic extension.

Another pseudocapsule is seen between the transition zone and peripheral zone due to compressed prostatic tissue, which is called a surgical capsule.

#### Neurovascular Bundles

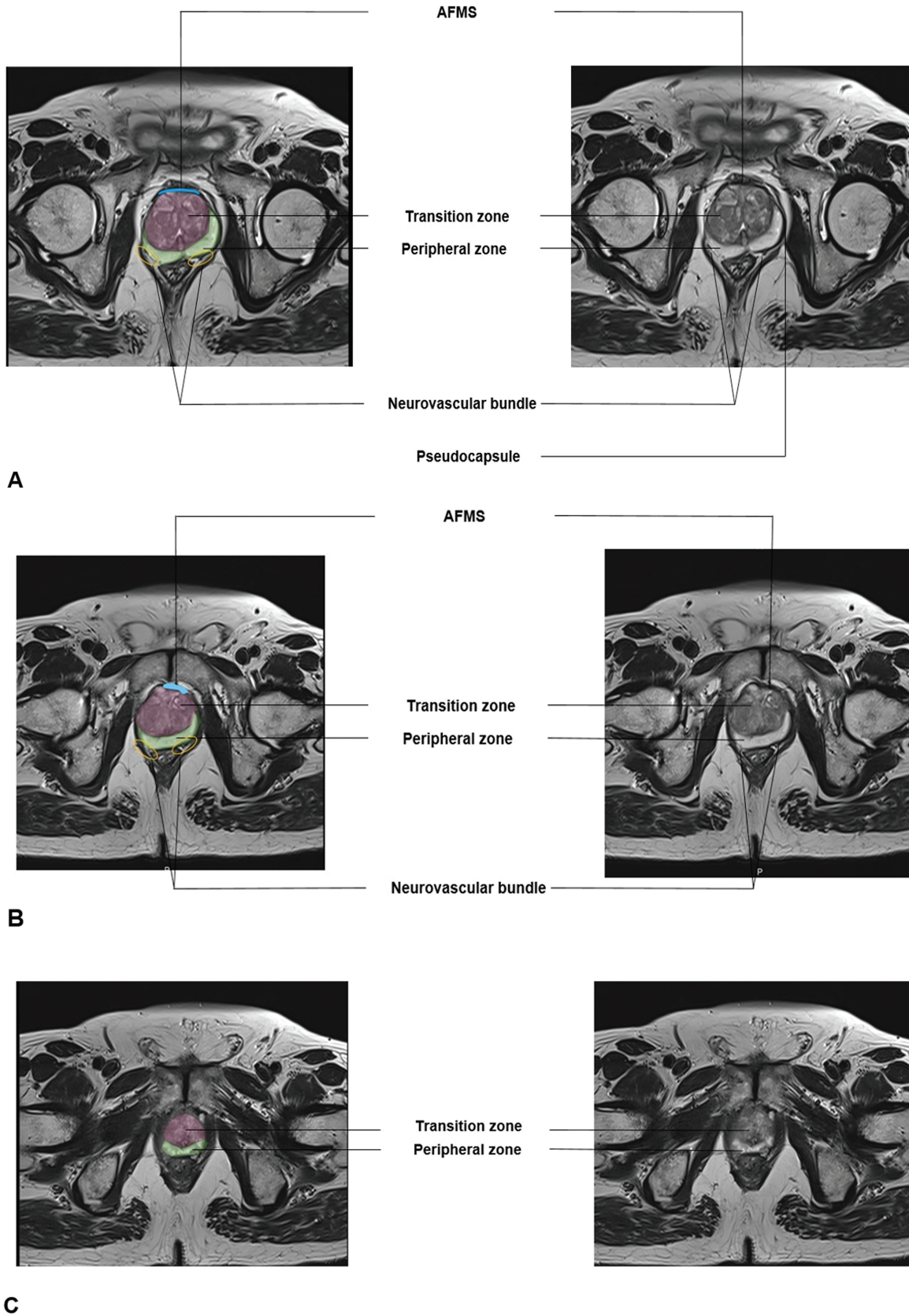
The neurovascular bundles contain small vessels and cavernosal nerves responsible for erectile function and are seen extending craniocaudally posterolateral to the gland in periprostatic fat at the 5 to 7 o'clock position. It is bounded by the prostatic capsule anteromedially, Denonvillier's fascia posteriorly, and pelvic fascia laterally. It has branches that penetrate the prostatic capsule as it descends caudally. Though classically located at 5 to 7 o'clock, the position of the neurovascular bundle is variable and can extend laterally along the lateral surface of the gland and anteriorly.<sup>9</sup> The neurovascular bundle is visualized as clustered punctate T2 hypointense foci posterolateral to a gland in periprostatic fat, better seen in the base and midgland. It is less distinct in the apex.

#### Peripheral Zone

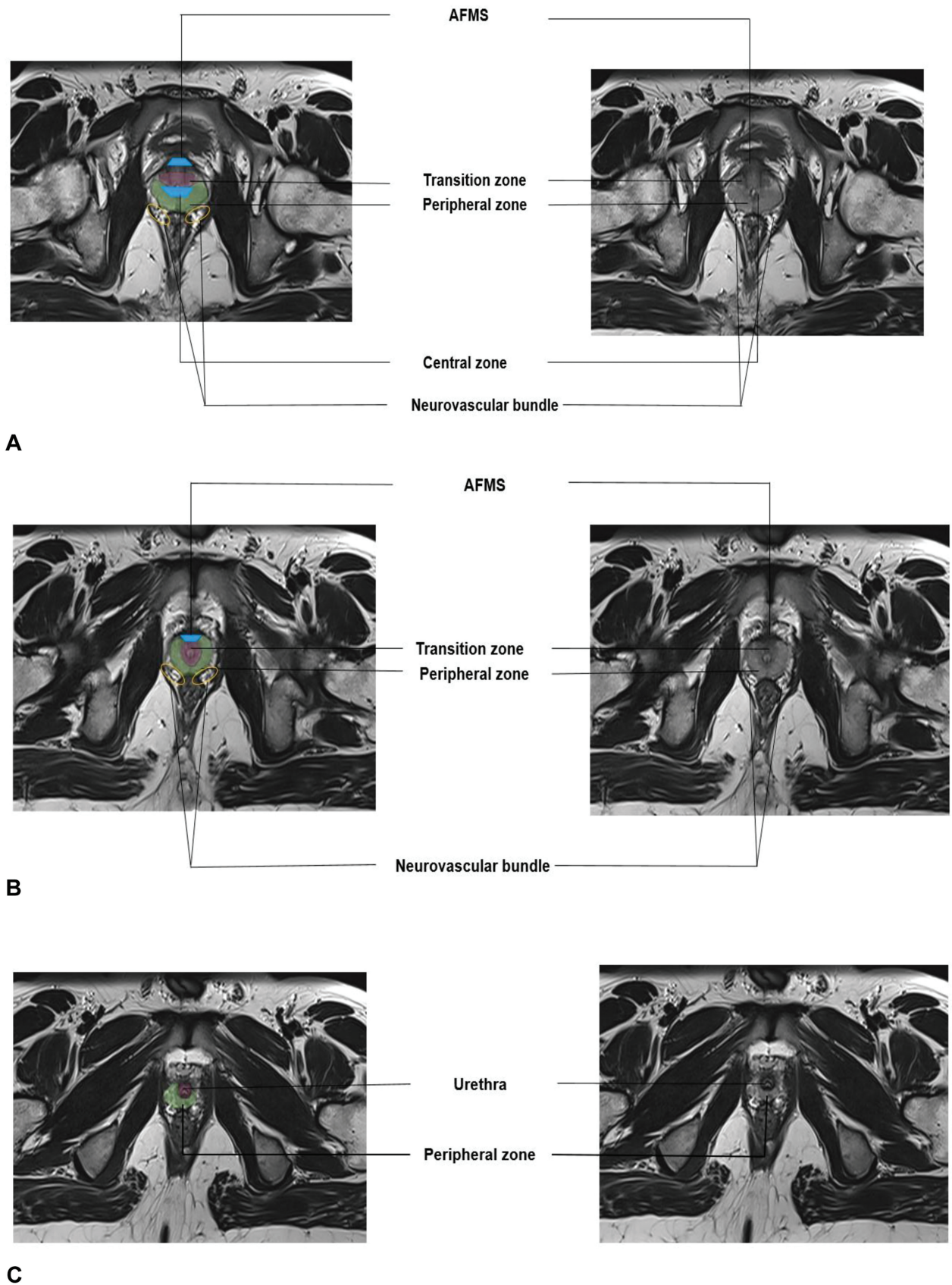
The peripheral zone extends from the base of the prostatic gland to the apex and accounts for up to 70% of the glandular tissue in young men. Around 70 to 75% of prostatic cancer arises from the peripheral zone. The peripheral zone surrounds the transition zone and central zone in the base posteriorly and laterally. Anteriorly and anterolaterally, it is limited by anterior fibromuscular stroma. In the midgland, it also extends anterolaterally. Almost the entire gland is made up of the peripheral zone at the apex in young age. In T2, the peripheral zone appears homogeneously hyperintense because of high glandular elements with less muscular and stromal components.

#### Transition Zone

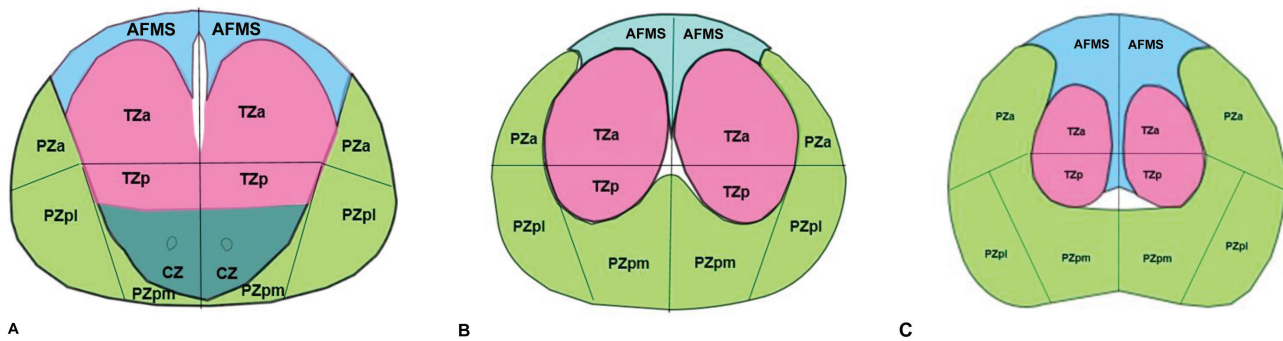
Up to 5% of the glandular tissue of the prostate is formed by the transition zone in young men and forms the majority of the prostate in old age due to glandular hyperplasia. Approximately 20 to 25% of prostatic carcinoma originates from the transition zone.<sup>10</sup> The transition zone extends from the base, surrounding the prostatic urethra proximal to the verumontanum. It is absent in the apex in young men. The transition zone's increased muscular components and dense stroma contribute to its relative T2 hypointensity compared to the peripheral zone. Hyperplastic changes in the transition zone can lead to T2 heterointense signal nodules within the gland. The transition zone and the peripheral zone are separated by the T2 hypointense surgical pseudocapsule.



**Fig. 2** Magnetic resonance imaging T2 axial sections of prostate in 65 years old man with zonal anatomy in base (A), midgland (B), and apex (C). AFMS, anterior fibromuscular stroma.



**Fig. 3** Magnetic resonance imaging T2 axial sections of prostate in young man with zonal anatomy in base (A), midgland (B), and apex (C).



**Fig. 4** Sectoral anatomy of prostate in base (A), midgland (B), and apex (C). AFMS, anterior fibromuscular stroma; CZ, central zone; PZa, peripheral zone anterior, PZpm, peripheral zone posteromedial; PZpl, peripheral zone posterolateral; TZa, transition zone anterior; TZp, transition zone posterior.

### Central Zone

The central zone is seen in base along both ejaculatory ducts with apex directed toward verumontanum and makes up approximately 25% of the glandular tissue of the prostate. Approximately 5 to 10% of prostate cancer originates from the central zone.<sup>10</sup> The central zone surrounds both ejaculatory ducts in the base. The central zone's volume decreases with age. The central zone can be separated from the transitional and peripheral zones in MRI, as confirmed by recent studies. It appears as homogenous T2 hypointensity surrounding ejaculatory ducts at the base of the prostate.<sup>11</sup> Therefore, the term central gland, which includes both transition and central zones, should be avoided.

### Anterior Fibromuscular Stroma

The anterior fibromuscular stroma is a non glandular portion of the prostate gland that extends from the base to the apex of the gland. It merges with the muscles of the bladder superiorly and blends with the urogenital diaphragm inferiorly. It is broader at the base and appears as homogeneous T2 hypointense structure along the anterior aspect of the prostate.

### Sectoral Anatomy<sup>12</sup> (–Fig. 4)

The prostate is divided into 41 sectors/regions in the PIRADS 2.1 version for better localization of lesions and uniform interpretation by radiologists, urologists, and pathologists.

The prostate is divided into right and left by a straight line passing anteroposteriorly through the prostatic urethra. A plane passing through the center of the gland divides it into anterior and posterior portions.

The central zone is located at the base of the gland and is divided into two sectors, right and left.

The peripheral zone is divided into anterior, posteromedial, and posterolateral sectors on each side at the base, midgland, and apex (18 sectors).

The transition zone is divided into anterior and posterior on both sides in the base, midgland, and apex (12 sectors).

The anterior fibromuscular stroma is divided into right and left on base, midgland, and apex (6 sectors).

Two sectors are represented by right and left seminal vesicles, and one by an external urethral sphincter.

### Ultrasound Anatomy

Though MRI is the superior imaging modality because of better delineation of zonal anatomy and high contrast resolution, TRUS is also one of the commonly used modalities to image the prostate gland. The most commonly used probe design is an end-viewing transducer with probe frequency of 5 to 11 MHz.<sup>13</sup> The sections obtained with end-firing probes are relatively more oblique compared to side-firing probes. As a result, the images along the axial plane are semicoronal in orientation and are more oblique compared to axial sections in MRI.

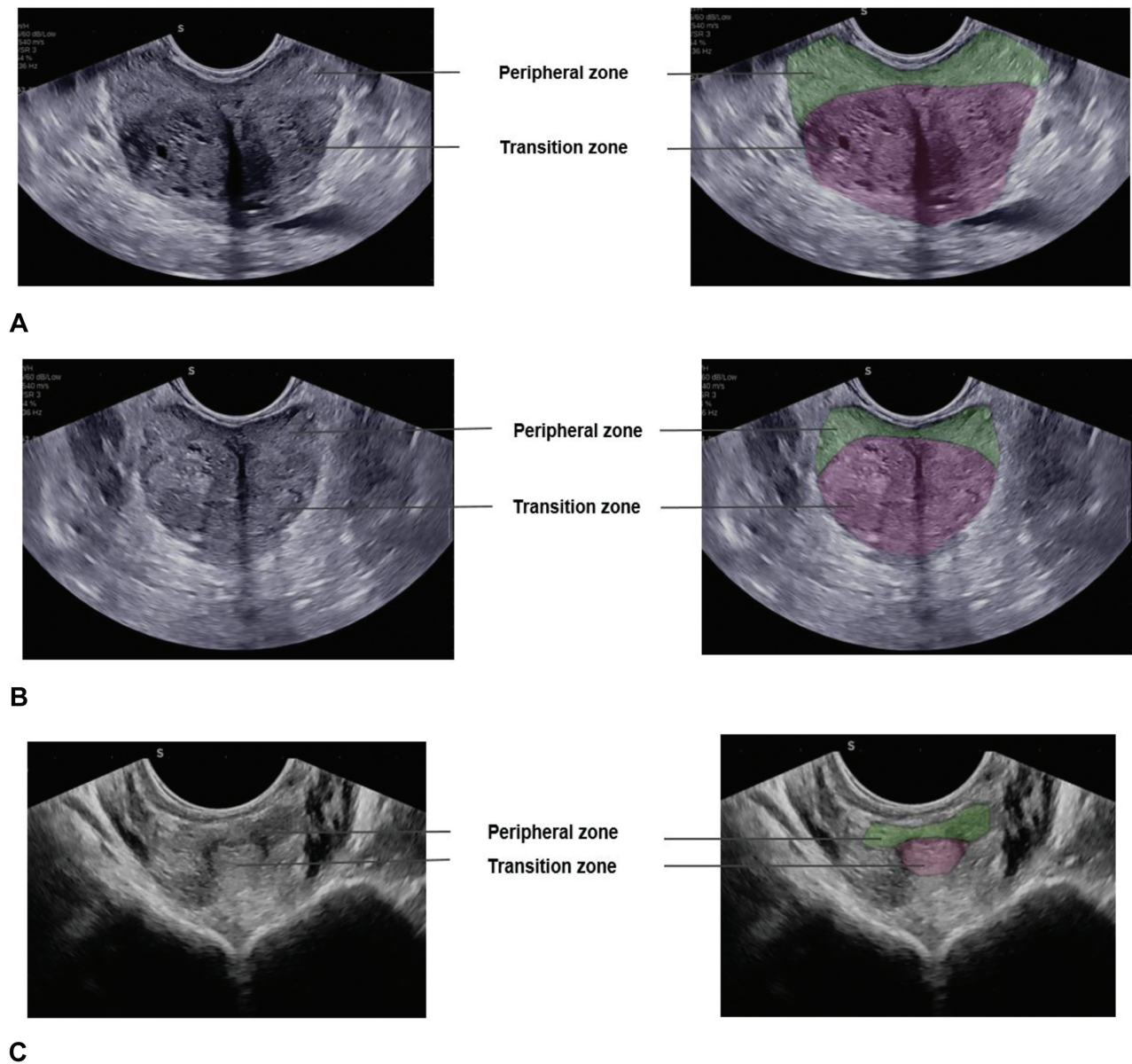
Before the procedure, rectal preparation is generally done with laxatives or an enema. The patient is placed in a left lateral decubitus position. After adequate lubrication, the probe is gently inserted into the rectum. Sequential assessments are performed from the seminal vesicles to the apex in an axial/semicoronal plane. By rotating the probe to 90 degrees, sagittal images can be obtained and the prostate can be scanned from one end to the other.

Peripheral zone appears echogenic compared to slightly hypoechoic hyperplastic transition zone<sup>13</sup>(–Fig. 5). The central zone and anterior fibromuscular stroma cannot be reliably differentiated in ultrasound. Neurovascular bundles can be localized along posterolateral aspect of prostate and it is useful as a site of local anesthesia during prostate biopsy.

### Vascular Anatomy

The arterial supply of the prostate is highly variable. The arteries that supply the prostate gland can be classified as vessels supplying the transition zone and vessels supplying the peripheral zone. These arteries are called anterolateral and posterolateral pedicles. These branches can arise separately from internal iliac branches or as a single artery from an inferior vesical artery. The anterolateral pedicle course anteriorly and medially supplies the transition zone predominantly and is the target of prostatic artery embolization in benign prostatic hyperplasia. The posterolateral pedicle courses inferiorly and predominantly supply the peripheral zone and apex.<sup>14</sup>

The prostatic venous plexus surrounds the prostate along its anterior and lateral margins and drains into the internal



**Fig. 5** Transrectal ultrasound axial/semicoronal images in 64 years old man with zonal anatomy in base (A), midgland (B), and apex (C).

iliac veins. The internal iliac veins are interconnected with the vertebral venous plexus, which might be the route of metastatic spread in prostatic carcinoma.<sup>15</sup>

Regional lymph nodes of the prostate include the obturator, internal iliac, external iliac, and presacral nodes, whereas common iliac, inguinal and paraaortic lymph nodes are considered nonregional nodes.<sup>16</sup>

### Conclusion

Understanding the imaging appearance of prostate and zonal anatomy is essential for accurate localization of various pathologies. Further, anatomical knowledge is important for accurate diagnosis and standardized reporting, which enables better patient care.

### Conflict of Interest

None declared.

### References

- 1 Mitterberger M, Horninger W, Aigner F, et al. Ultrasound of the prostate. *Cancer Imaging* 2010;10(01):40–48
- 2 Tirkes T. *Prostate MRI Essentials: A Practical Guide for Radiologists*. Springer Nature; Berlin/Heidelberg, Germany, 2020
- 3 Tzelvels L, Protogerou V, Varkarakis I. Denonvilliers' fascia: the prostate border to the outside world. *Cancers (Basel)* 2022;14(03):688
- 4 Onur MR, Orhan I, Firdolas F, Onur R, Kocakoç E. Clinical and radiological evaluation of ejaculatory duct obstruction. *Arch Androl* 2007;53(04):179–186 [published correction appears in *Arch Androl*. 2007 Sep-Oct;53(5):295] [published correction appears in *Arch Androl*. 2007;53(4):295. Orhan, Yrfan [corrected

- to Orhan, Irfan]; Fýrdolaş, Fatih [corrected to Firdolas, Fatih]] Doi: 10.1080/01485010701426448
- 5 Ryan S, McNicholas M, Eustace SJ. *Anatomy for Diagnostic Imaging*. 3rd edition London: Elsevier Health Sciences UK; 2011
  - 6 McNeal JE. Normal histology of the prostate. *Am J Surg Pathol* 1988;12(08):619–633
  - 7 Devi VS. *Inderbir Singh's human embryology*. 11th ed JP Medical Ltd; New Delhi, 2017
  - 8 Scott R, Misser SK, Cioni D, Neri E. PI-RADS v2.1: what has changed and how to report. *SA J Radiol* 2021;25(01):2062
  - 9 Walz J, Burnett AL, Costello AJ, et al. A critical analysis of the current knowledge of surgical anatomy related to optimization of cancer control and preservation of continence and erection in candidates for radical prostatectomy. *Eur Urol* 2010;57(02):179–192
  - 10 Verma S, Rajesh A. A clinically relevant approach to imaging prostate cancer: review. *AJR Am J Roentgenol* 2011;196(3, Suppl):S1–S10, Quiz S11–S14
  - 11 Vargas HA, Akin O, Franiel T, et al. Normal central zone of the prostate and central zone involvement by prostate cancer: clinical and MR imaging implications. [published correction appears in *Radiology*. 2012 Aug;264(2):617] *Radiology* 2012; 262(03):894–902
  - 12 Turkbey B, Rosenkrantz AB, Haider MA, et al. Prostate imaging reporting and data system version 2.1: 2019 update of prostate imaging reporting and data system version 2. *Eur Urol* 2019;76(03):340–351
  - 13 Rumack CM, Wilson SR, Charboneau JW, Levine D. *Diagnostic Ultrasound*. 4th Edition, MosbyMaryland Heights, 2011
  - 14 Picel AC, Hsieh TC, Shapiro RM, Vezeridis AM, Isaacson AJ. Prostatic artery embolization for benign prostatic hyperplasia: patient evaluation, anatomy, and technique for successful treatment. *Radiographics* 2019;39(05):1526–1548
  - 15 Singh O, Bolla SR. *Anatomy, Abdomen and Pelvis, Prostate*. [Updated 2023 Jul 17]. In: StatPearls [Internet]. Treasure Island (FL): StatPearls Publishing; 2023 Jan-. Accessed March 7, 2024 at: <https://www.ncbi.nlm.nih.gov/books/NBK540987/>
  - 16 Pedersen CK, Babu AS. Understanding the lymphatics: an updated review of the N category of the AJCC 8th edition for urogenital cancers. *AJR Am J Roentgenol* 2021;217(02): 368–377