



# Pancarpal Arthrodesis Using Antibiotic-Impregnated Calcium Sulfate Beads in a Dog with Septic Arthritis and Osteomyelitis

Amy Davenport<sup>1</sup>  Frances Bird<sup>1</sup> Rosario Vallefuoco<sup>1</sup>

<sup>1</sup>Department of Small Animal Surgery, Pride Veterinary Referrals, Derby, United Kingdom

VCOT Open 2024;7:e40–e45.

**Address for correspondence** Amy Davenport, BVSc, MRCVS, Department of Small Animal Surgery, Pride Veterinary Referrals, Riverside Road, Derby, DE24 8HX, United Kingdom (e-mail: amy-davenport@hotmail.com).

## Abstract

A 6-year-old Lurcher dog was referred for evaluation and treatment of a septic carpal arthritis, associated osteomyelitis of the radius and radial carpal bone and antebrachiocarpal luxation following a previous articular surgery 14 weeks prior to presentation. A staged approach was elected and following removal of the original implants, a pancarpal arthrodesis was performed using autologous bone graft and gentamicin-impregnated bioabsorbable calcium sulfate beads. At 12 weeks postoperatively, lameness had resolved on the operated limb and complete joint fusion was confirmed on radiographic evaluation. The purpose of this case report is to describe the successful short- and long-term outcome of a pancarpal arthrodesis using antibiotic medication-impregnated calcium sulfate beads, providing details about the surgical technique used for management of a destructive septic arthritis and osteomyelitis.

## Keywords

- ▶ local antibiotic medication therapy
- ▶ bioabsorbable beads
- ▶ arthrodesis
- ▶ septic arthritis
- ▶ infection

## Introduction

The estimated rate of surgical site infections (SSI) in clean veterinary orthopaedic procedures ranges from 1.3 to 21.3%.<sup>1,2</sup> Osteomyelitis and/or septic arthritis are common sequelae to implant-associated infections,<sup>3</sup> with septic arthritis in dogs commonly associated with previous articular surgery.<sup>4</sup> Implant-associated infections remain challenging to treat due to the formation of a bacterial biofilm that adheres to the surface of an implant. Bacteria in a biofilm may be up to 1,000 times more resistant to antimicrobials than planktonic bacteria.<sup>5</sup> Therefore, preventing and treating SSI remains a major challenge. The use of local antibiotic medication therapy, either prophylactic or therapeutic, is an area of increasing interest in veterinary medicine.<sup>6,7</sup> Potential advantages of local antibiotic medication delivery include increased antibiotic concentration at the surgical site, increased penetration of biofilms, combined with reduced

systemic absorption and therefore reduced systemic toxicity.<sup>8</sup> The delivery of local antibiotic-impregnated therapy in veterinary patients has been reported using antibiotic-impregnated cements, calcium sulfate beads, hydrogels, and sponges.<sup>7–11</sup>

Pancarpal arthrodesis (PCA) is a salvage procedure in dogs used to treat carpal hyperextension, fractures, luxations, congenital deformities, neurogenic injury, and severe osteoarthritis.<sup>12,13</sup> PCA is considered a clean, elective, orthopaedic procedure. Placement of metallic implants into a potentially contaminated environment is likely to increase the risk of infection and the necessity of future implant removal.<sup>14</sup> The purpose of this case report is to describe the successful short- and long-term outcome of a PCA using antibiotic-impregnated calcium sulfate (AICS) beads, detailing the surgical technique used for management of a destructive septic carpal arthritis and osteomyelitis in a dog.

received  
October 30, 2023  
accepted after revision  
January 11, 2024

DOI <https://doi.org/10.1055/s-0044-1785214>.  
ISSN 2625-2325.

© 2024. The Author(s).

This is an open access article published by Thieme under the terms of the Creative Commons Attribution License, permitting unrestricted use, distribution, and reproduction so long as the original work is properly cited. (<https://creativecommons.org/licenses/by/4.0/>)  
Georg Thieme Verlag KG, Rüdigerstraße 14, 70469 Stuttgart, Germany

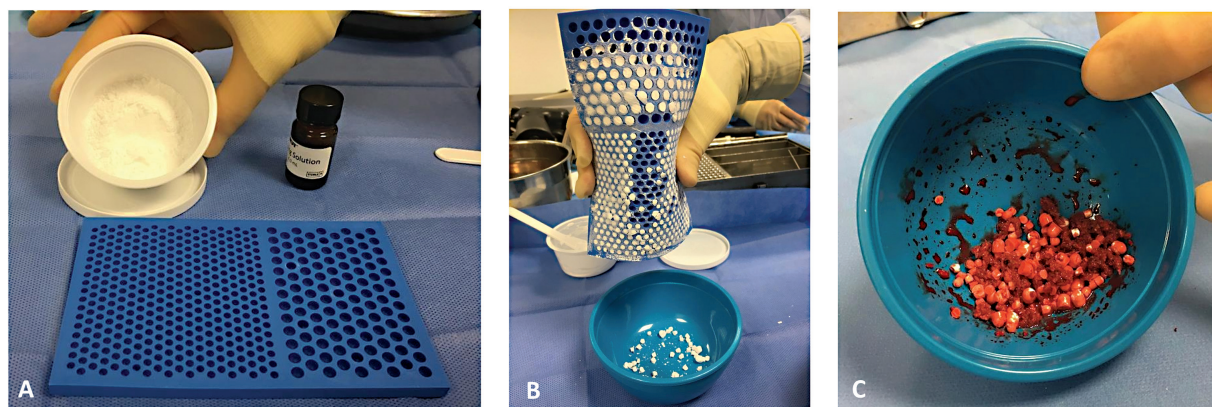
## Case Report

A 6-year-old, 29-kg, male neutered Lurcher was referred for treatment of a septic bacterial arthritis of the left carpus following a previous articular surgical procedure. Fourteen weeks prior to presentation, the dog underwent surgical stabilization of a left antebrachioacarpal joint luxation and comminuted distal ulnar fracture using two temporary radiocarpal transarticular cross-pins and two ulnar K-wires. A splinted bandage was applied postoperatively and was planned to be maintained for 6 weeks. However, implant migration and partial exposure occurred 12 days postoperatively. The exposed implants were removed and cephalexin (25 mg/kg, every 12 hours, orally) was prescribed. Clinical improvement was initially noted, but the dog developed a fistulous tract and deterioration in lameness 10 days later. Radiocarpal joint arthrocentesis and bacterial culture identified a multidrug-resistant *Proteus* sp. and *Staphylococcus* sp. While the *Staphylococcus* sp. was sensitive to cephalexin, the *Proteus* sp. was resistant. Both were sensitive to enrofloxacin and therefore enrofloxacin (5 mg/kg, every 24 hours, orally) was prescribed with initial clinical improvement. Following completion of the 14-day course, a fistulous tract recurred on the dorsal aspect of the carpus and the dog's lameness deteriorated, prompting referral of the case.

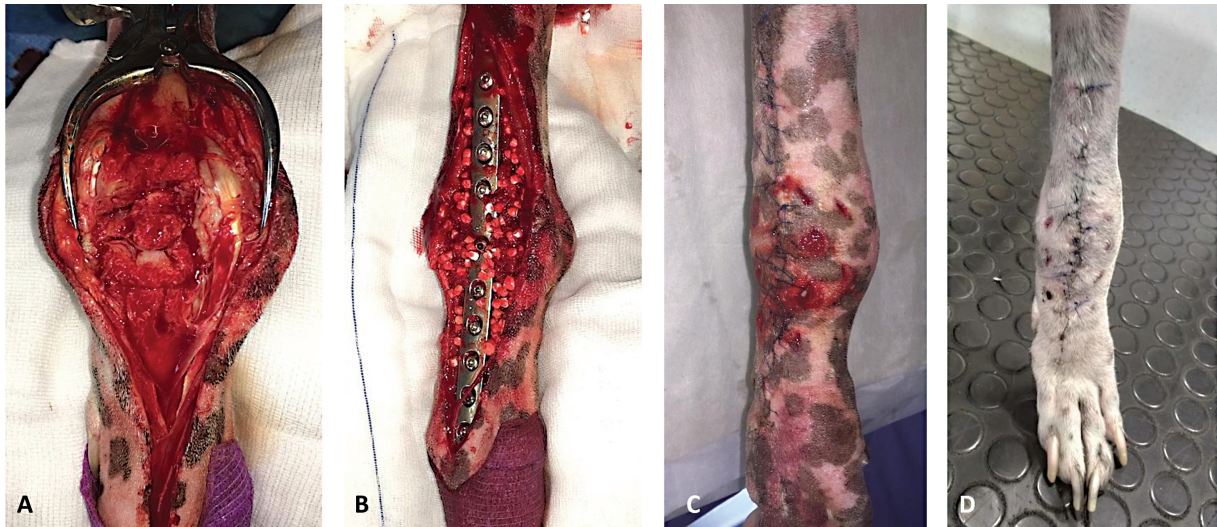
On presentation, the dog was non-weight-bearing on the left forelimb, with a discharging sinus on the dorsal aspect of the carpus and a large radiocarpal joint effusion. Orthogonal radiographs of the left carpus revealed dorsopalmar luxation of the antebrachioacarpal joint, a heterogenous and lytic appearance of the distal radius, severe lysis of the cranio-dorsal aspect of the radial carpal bone, and increased articular and periarticular soft-tissue opacity of the left carpus. The remaining implants were migrated but not exposed. Arthrocentesis of the radiocarpal joint was performed for synovial fluid cytology examination and bacterial culture. Cytology examination revealed a predominantly neutrophilic cell population, supportive of septic arthritis, but bacterial culture was negative. Remaining implants were removed, and the joint was irrigated using 500 mL of sterile saline via ingress and egress needles. PCA was advised as a salvage procedure and the owners were counseled regarding in-

creased risk of infection. Enrofloxacin was continued until the time of revision surgery 3 weeks later. Weekly clinical assessments confirmed a progressive reduction of the articular–periarticular swelling, but persistent non-weight-bearing lameness.

At the time of surgery, the skin had healed over the previous fistulous tract. The dog was positioned in dorsal recumbency following aseptic preparation of the limb. The affected limb was pulled caudally with the shoulder flexed and the elbow extended. A standard dorsal approach to the distal radius, carpus, and metacarpal was performed. Marked thickening of the joint capsule was present. Debridement and resection of the abnormal tissue and synovectomy were performed. The necrotic bone and the articular cartilage of the antebrachioacarpal, middle carpal, and carpometacarpal joints were removed via pneumatic burr, bone rongeurs, and curettage. A sample of cartilage and joint capsule were submitted for bacterial culture. A 1.5-mm drill bit was used for osteostixis of the radius, carpal, and metacarpal bones. A 3.5-/2.7-mm hybrid pancarpal dynamic compression plate (Veterinary Instrumentation, Sheffield, UK) was contoured to provide 15 degrees of extension and was temporarily applied using the central, most proximal and most distal screws. All the remaining screw holes were predrilled and then the plate was removed. AICS beads were aseptically prepared according to the manufacturer's instructions (Kerrier, Palm Beach Gardens, FL, United States), mixing 4 mL of gentamicin (20 mg/mL) with 15 g of powdered calcium sulfate to form a paste. The paste was spread into the provided bead mold mat for 3-mm-diameter beads and allowed to set for 20 minutes (→Fig. 1). Autogenous cancellous bone graft harvested from the greater tubercle of the left humerus was mixed with the AICS beads, acting as a graft extender, and packed into all joint spaces. The plate and screws were applied again, without interfragmentary compression. Further AICS beads were distributed around the plate (→Fig. 2). The fascia and subcutaneous layers were closed using 3-0 poliglecaprone; however, due to the amount of AICS beads and autograft used, closure of the skin was not possible without tension. Multiple tension-relieving skin incisions parallel to the surgical wound enabled primary closure of the wound with minimal tension.



**Fig. 1** (A,B) Intraoperative preparation of the gentamicin-impregnated calcium sulfate bead kit (Kerrier). (C) Mixing with autologous bone graft.



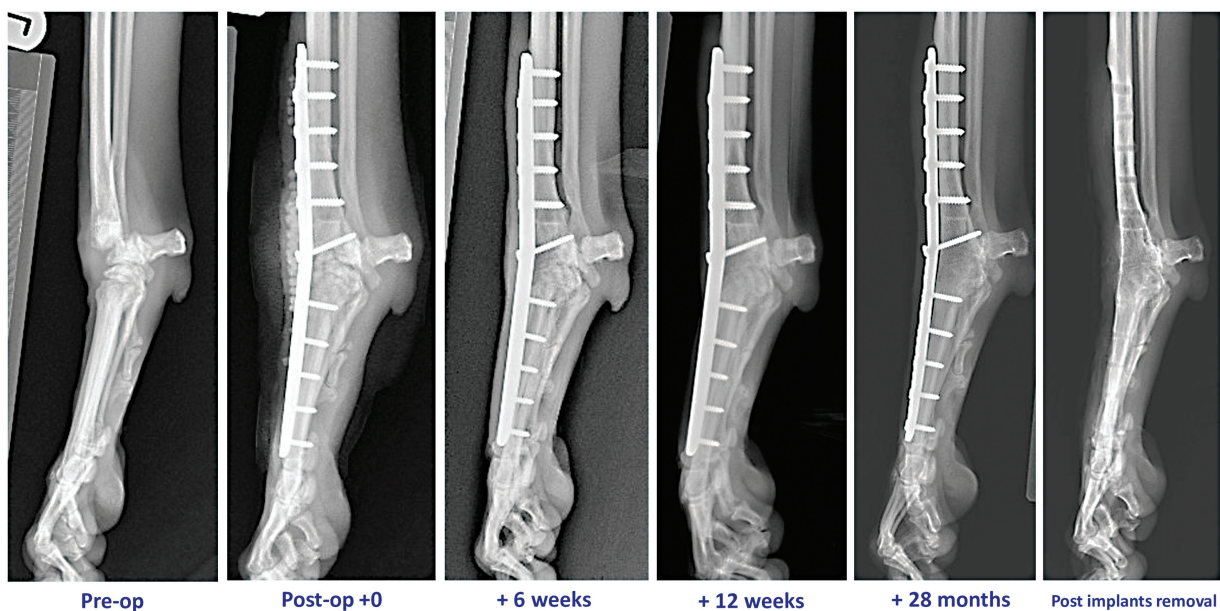
**Fig. 2** (A) Intraoperative view of the dorsal aspect of the carpus following debridement and synovectomy. (B) Following application of the 3.5-/2.7-mm hybrid pancarpal plate (Veterinary instrumentation) and packing of the joint spaces with bone graft and gentamicin-impregnated beads. (C) Dorsal aspect of the carpus demonstrating the tension-relieving incisions parallel to the surgical wound, 2 days postoperatively and (D) 15 days postoperatively.

Orthogonal radiographs revealed appropriate alignment of the distal limb and implant positioning. The AICS beads were visible in the joint spaces and surrounding the implants. A modified, three-layer, Robert Jones dressing was placed to limit postoperative swelling and protect the tension-relieving incisions. A sterile, absorbent foam dressing (Allevyn, Smith & Nephew) was used as the primary layer, providing a moist environment to favor healing. The dog was discharged 2 days after surgery with enrofloxacin (5 mg/kg oral every 24 hours for 10 days), tranexamic acid (10 mg/kg oral every 8 hours for 7 days), and paracetamol (10 mg/kg oral every 8 hours for 10 days). The dressing was changed daily for the first 2 days, and then every 3 days until healing of the releasing incisions was

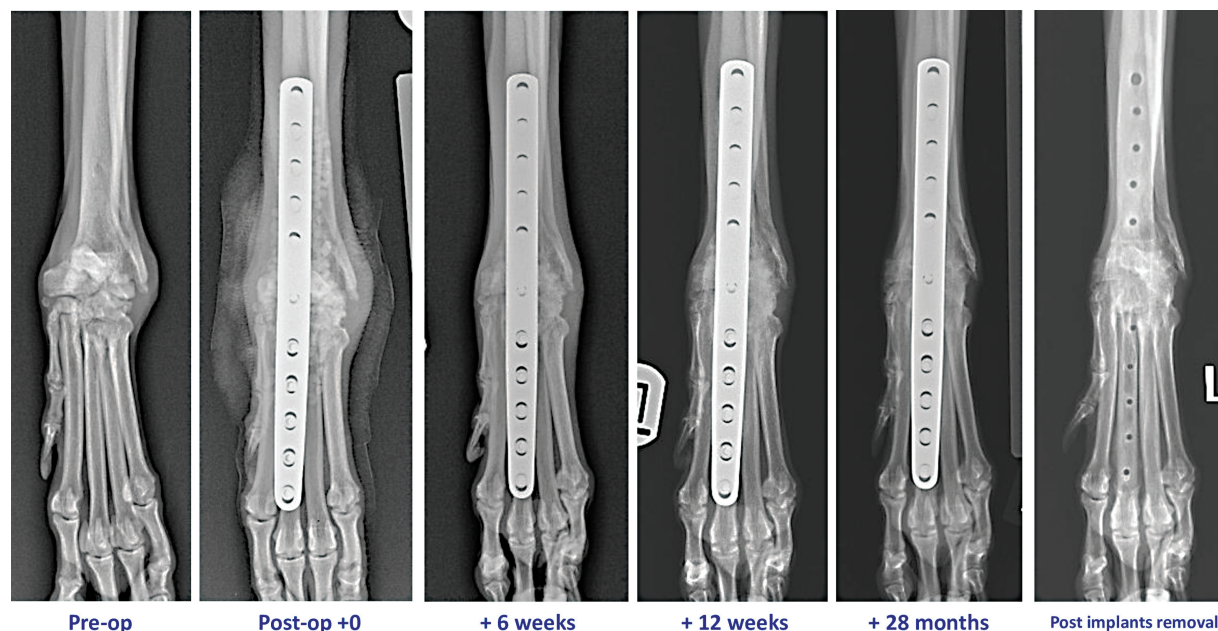
observed at 15 days. No clinical signs of infection were observed at suture removal 3 weeks postsurgery. Bacterial culture of cartilage and joint capsule taken at surgery were negative. Strict exercise restriction was advised for 12 weeks.

Orthopaedic examination at 6 and 12 weeks revealed a continual improvement in lameness, with only a minimal mechanical gait abnormality present by 12 weeks. No pain was elicited on palpation of the implants and swelling had markedly reduced.

Radiographs performed at 6 weeks revealed maintained alignment of the limb and implant positioning. The AICS beads were no longer visible, and signs of early joint fusion were present (→Figs. 3 and 4). By 12 weeks, radiographic



**Fig. 3** Serial mediolateral of the affected carpus prepancarpal arthrodesis and immediate, 6 weeks, 12 weeks, and 28 months postoperatively and following implant removal. The calcium sulfate beads are evident in the immediate postoperative radiographs and are radiographically absent by 6 weeks. Advanced joint fusion is observed by 12 weeks postoperatively.



**Fig. 4** Serial dorsopalmar radiographs of the affected carpus prepancarpal arthrodesis and immediate, 6 weeks, 12 weeks, and 28 months postoperatively and following implant removal. The calcium sulfate beads are evident in the immediate postoperative radiographs and are radiographically absent by 6 weeks. Advanced joint fusion is observed by 12 weeks postoperatively.

joint fusion was observed and no implant-related complications were identified. A gradual return to normal exercise was advised. Elective implant removal was advised but declined by the owner.

Twenty-eight months after the PCA, the dog presented to the primary care practice for evaluation of a small skin vesicle on the dorsal aspect of the distal left carpus. No lameness was noted although soft-tissue swelling was palpable over the implants. Radiographs did not identify any implant-related concerns; however, due to the palpable soft-tissue swelling and skin vesicle, implant removal was elected. Bacterial culture of deep peri-implant tissue was negative. The surgical wound healed uneventfully, and no lameness was noted 15 days postoperatively. Examination and radiographic follow-up at 7 weeks confirmed the absence of lameness and there was no pain on palpation of the limb. Radiographs confirmed progressive healing of the bony defects left by removal of the screws, and no further abnormalities were noted (►Figs. 3 and 4).

Telephone follow-up with the owner 2 years postsurgery confirmed that the dog remained free of lameness and there were not any further complications or signs of recurrent infection.

## Discussion

Septic arthritis is most commonly caused by direct introduction of bacteria into a joint, such as via articular surgery.<sup>4,15</sup> Diagnosis of septic bacterial arthritis is made when analysis of the affected joint fluid or synovial membrane reveals an elevated cell count of greater than  $3 \times 10^9$  cells/mL with neutrophils making up greater than 40% and/or a positive bacterial culture.<sup>4</sup> *Staphylococcus* species are the most commonly isolated bacteria in implant-associated infections and

septic arthritis in human and veterinary patients.<sup>4,8,16</sup> Septic arthritis may be treated with an extended antibiotic-impregnated course, ideally based on culture and sensitivity results, sometimes combined with surgical joint irrigation or drainage.<sup>15</sup> In our case, septic arthritis was associated with osteomyelitis of the distal radius and radial carpal bone, likely secondary to the primary surgical intervention. Osteomyelitis can be challenging to treat due to presence of implant-associated bacterial biofilms and impaired vascular supply, meaning that the efficacy of systemic antibiotic-impregnateds can be reduced.<sup>8</sup> In our case, it is possible that an extended antibiotic-impregnated course may have resolved the septic arthritis and osteomyelitis following removal of the original implants; however, carpal instability persisted, and further surgical intervention was required.

Reported suspected or confirmed SSI rates for PCA are between 17.6 and 66.7%,<sup>12,13,17,18</sup> which is considerably higher than SSI rates reported for other veterinary orthopaedic procedures.<sup>2</sup> Performing a PCA in the presence of septic arthritis and osteomyelitis posed a significant challenge. Local antibiotic-impregnated therapy was chosen as an adjunctive treatment to allow increased therapeutic concentrations of the drug at the infected site, while minimizing systemic toxicity.<sup>8</sup> Choosing the appropriate antibiotic-impregnated for local therapy should ideally be guided by culture and sensitivity results.<sup>6,8</sup> In this case, a multi-resistant *Proteus* sp. and *Staphylococcus* sp. were cultured prior to removal of the initial implants, and systemic enrofloxacin was administered based on these results. Subsequent bacterial cultures of joint fluid, joint capsule, and cartilage were negative. Positive bacterial cultures are only obtained in approximately half of septic arthritis cases.<sup>4,19</sup> The dog had been receiving continued systemic antimicrobials, which likely contributed to subsequent negative

cultures. Enrofloxacin would have been the preferred choice for the AICS beads based on the initial culture; however, the manufacturer stated this antibiotic-impregnated was not compatible with the preparation kit. In our case, gentamicin was not a tested antibiotic-impregnated in the original culture, yet it was chosen based on the broad spectrum of activity against both gram-positive and gram-negative bacteria<sup>20</sup> and compatibility with the AICS kit. Due to subsequent negative cultures, the antimicrobial benefit of the AICS in this case remains uncertain. However, risk of infection and surgical failure was considered too high and the use of AICS beads was elected for either prophylactic or therapeutic purposes.

Numerous methods of local antibiotic-impregnated delivery have been reported.<sup>8</sup> AICS beads were chosen due to their bioabsorbable nature and were radiographically absent by 6 weeks. AICS beads have been used as an effective treatment for chronic osteomyelitis in humans,<sup>21</sup> and have recently been reported in veterinary patients.<sup>6,11</sup> Calcium sulfate has been reported as an effective bone graft substitute and as an expander when combined with autogenous bone graft.<sup>22,23</sup> Calcium sulfate is osteoconductive, providing a scaffold for new bone formation and a supportive environment for the ingrowth of new blood vessels and osteogenic cells.<sup>24</sup> A recent human case series has reported successful arthrodesis using AICS beads, hydroxyapatite, and autograft to manage infected bone defects.<sup>25</sup> Autogenous bone graft is considered the “gold standard” for enhancing new bone formation via osteogenesis, osteoconduction, and osteoinduction.<sup>26</sup> However, its use after surgical debridement of osteomyelitis may be questioned, due to enhanced resorption in infected and inflammatory environments.<sup>27</sup> A combination of autograft and AICS beads was chosen in this case for sustained antibiotic-impregnated release and to enhance osteogenesis as a graft expander.

Due to the bulk of the implants and AICS beads, primary closure of the surgical wound was not possible without tension. Multiple parallel skin incisions were utilized as a tension-relieving technique. This technique is reported in extremity limb trauma in humans, known as pressure reducing skin pie-crusting (PRSPC), documenting a significant reduction in the tension required for wound closure and a decreased risk of superficial skin necrosis.<sup>28,29</sup> Wound closure with excess tension may compromise blood supply, leading to a higher risk of wound healing complications, skin necrosis, and SSI. Suggested reasons for the higher risk of SSI in PCA include limited soft-tissue coverage, difficult wound closure, and therefore an increased risk of wound dehiscence.<sup>12</sup> PRSPC was used in this case to enable wound closure and allow drainage of edema from the limb. The surgical wound and relieving incisions healed without complications in 15 days.

Although this is a single case report, it highlights the successful use of AICS beads for treating septic arthritis and osteomyelitis in a revision arthrodesis surgery. Successful joint fusion occurred, suggesting that AICS beads can be beneficial both as a graft expander and to provide sustained antimicrobial release. Further research is needed to deter-

mine the efficacy of AICS beads in a larger series of cases, but this report demonstrates that their use may improve treatment of septic complications in veterinary orthopaedics.

#### Funding

The IVC Evidensia Research Fund has provided support for the publication of this manuscript.

#### Conflict of Interest

None declared.

#### References

- Verwilghen D, Singh A. Fighting surgical site infections in small animals: are we getting anywhere? *Vet Clin North Am Small Anim Pract* 2015;45(02):243–276, v
- Weese JS. A review of post-operative infections in veterinary orthopaedic surgery. *Vet Comp Orthop Traumatol* 2008;21(02):99–105
- Gieling F, Peters S, Erichsen C, Richards RG, Zeiter S, Moriarty TF. Bacterial osteomyelitis in veterinary orthopaedics: pathophysiology, clinical presentation and advances in treatment across multiple species. *Vet J* 2019;250:44–54
- Clements DN, Owen MR, Mosley JR, Carmichael S, Taylor DJ, Bennett D. Retrospective study of bacterial infective arthritis in 31 dogs. *J Small Anim Pract* 2005;46(04):171–176
- Trampuz A, Zimmerli W. Diagnosis and treatment of implant-associated septic arthritis and osteomyelitis. *Curr Infect Dis Rep* 2008;10(05):394–403
- Peterson LC, Kim SE, Lewis DD, Johnson MD, Ferrigno CRA. Calcium sulfate antibiotic-impregnated bead implantation for deep surgical site infection associated with orthopedic surgery in small animals. *Vet Surg* 2021;50(04):748–757
- Smith JJ, Chou PY, Filliquist B, Marcellin-Little DJ, Kapatkin AS. Number of previous surgeries and antibiotic resistance decreases the success of local administration of antibiotic-impregnated poloxamer 407 hydrogel when managing orthopedic surgical site infections in dogs. *J Am Vet Med Assoc* 2023;261(08):1186–1192
- Hayes G, Moens N, Gibson T. A review of local antibiotic implants and applications to veterinary orthopaedic surgery. *Vet Comp Orthop Traumatol* 2013;26(04):251–259
- Ham K, Griffon D, Seddighi M, Johnson AL. Clinical application of tobramycin-impregnated calcium sulfate beads in six dogs (2002–2004). *J Am Anim Hosp Assoc* 2008;44(06):320–326
- Owen MR, Moores AP, Coe RJ. Management of MRSA septic arthritis in a dog using a gentamicin-impregnated collagen sponge. *J Small Anim Pract* 2004;45(12):609–612
- Guthrie JW, Fitzpatrick N. Single-stage revision of an infected total hip replacement using antibiotic-impregnated bioabsorbable beads in a canine patient. *VCOT Open* 2019;02(01):e5–e12
- Bristow PC, Meeson RL, Thorne RM, et al. Clinical comparison of the hybrid dynamic compression plate and the castless plate for pancarpal arthrodesis in 219 dogs. *Vet Surg* 2015;44(01):70–77
- Brown G, Kalfs S, Gemmill TJ, et al. Highly comminuted, articular fractures of the distal antebrachium managed by pancarpal arthrodesis in 8 dogs. *Vet Surg* 2016;45(01):44–51
- Sandness BM, Perry KL, Bruce M. Single institution retrospective study evaluating the frequency of implant removal and associated risk factors following open fracture fixation in 80 cases (2010–2020). *BMC Vet Res* 2023;19(01):119
- Marchevsky AM, Read RA. Bacterial septic arthritis in 19 dogs. *Aust Vet J* 1999;77(04):233–237
- Hetrick EM, Schoenfisch MH. Reducing implant-related infections: active release strategies. *Chem Soc Rev* 2006;35(09):780–789

- 17 Ramirez JM, Macias C. Pancarpal arthrodesis without rigid coaptation using the hybrid dynamic compression plate in dogs. *Vet Surg* 2016;45(03):303–308
- 18 Tuan J, Comas N, Solano M. Clinical outcomes and complications of pancarpal arthrodesis stabilised with 3.5 mm/2.7 mm locking compression plates with internal additional fixation in 12 dogs. *N Z Vet J* 2019;67(05):270–276
- 19 Mielke B, Comerford E, English K, Meeson R. Spontaneous septic arthritis of canine elbows: twenty-one cases. *Vet Comp Orthop Traumatol* 2018;31(06):488–493
- 20 Plumb DC. *Plumb's Veterinary Drug Handbook*. Stockholm, WI: PharmaVet Inc. 2011
- 21 Shi X, Wu Y, Ni H, et al. Antibiotic-loaded calcium sulfate in clinical treatment of chronic osteomyelitis: a systematic review and meta-analysis. *J Orthop Surg Res* 2022;17(01):104
- 22 Turner TM, Urban RM, Gitelis S, Kuo KN, Andersson GB. Radiographic and histologic assessment of calcium sulfate in experimental animal models and clinical use as a resorbable bone-graft substitute, a bone-graft expander, and a method for local antibiotic delivery. One institution's experience. *J Bone Joint Surg Am* 2001;83-A(Pt 1, Suppl 2):8–18
- 23 Kelly CM, Wilkins RM, Gitelis S, Hartjen C, Watson JT, Kim PT. The use of a surgical grade calcium sulfate as a bone graft substitute: results of a multicenter trial. *Clin Orthop Relat Res* 2001;(382):42–50
- 24 Blaha JD. Calcium sulfate bone-void filler. *Orthopedics* 1998;21(09):1017–1019
- 25 Howard T, Reichert I, Giddie J, Ahluwalia R. Treatment of infected nonunions with bone defects using autologous bone graft and absorbable antibiotic-loaded calcium sulfate-hydroxyapatite paste. *Foot Ankle Int* 2022;43(08):1007–1021
- 26 Harasen G. Stimulating bone growth in the small animal patient: grafts and beyond!. *Can Vet J* 2011;52(02):199–200
- 27 Lew DP, Waldvogel FA. Osteomyelitis. *Lancet* 2004;364(9431):369–379
- 28 Akgun U, Canbek U, Kilinc CY, Acan AE, Karalezli N, Aydogan NH. Efficacy of pie-crusting technique on soft tissues in distal tibia and fibula fractures. *J Foot Ankle Surg* 2019;58(03):497–501
- 29 Capo J, Liporace F, Yingling JM, et al. Pressure reducing skin pie-crusting in extremity trauma: an in-vitro biomechanical study and human case series. *Injury* 2020;51(06):1266–1270