




Modified Technique to Protect the Superior Sagittal Sinus in Cranial Vault Reconstruction for Scaphocephaly

Técnica modificada para proteger o seio sagital superior em reconstrução da calota craniana por escafocefalia

Leopoldina Peixoto Pereira¹ Joana Oliveira² Patrícia Santos² Patrícia Polónia² Rui Vaz² Josué Pereira²

¹Neurosurgery Service, Centro Hospitalar Vila Nova de Gaia/Espinho, Vila Nova de Gaia, Portugal

²Neurosurgery Department, Neurosurgery Service, Centro Hospitalar Universitário do São João, Faculdade de Medicina da Universidade do Porto, Porto, Portugal

Address for correspondence Leopoldina Peixoto Pereira, Resident of Neurosurgery, Neurosurgery Service, Centro Hospitalar Vila Nova de Gaia/Espinho, Rua Conceição Fernandes s/n, 4434-502, Vila Nova de Gaia, Portugal (e-mail: leopoldinappereira@gmail.com).

Arq Bras Neurocir

Abstract

Scaphocephaly remains the most prevalent form of isolated single-suture synostosis. In most Pediatric Neurosurgery Centers, the treatment consists of extensive calvarial reshaping operations which are performed in relatively late ages. We described a modified open technique of cranial vault reconstruction for scaphocephaly and we report the anesthetic approach and how it influences our results and enables the performance of this surgery at earlier ages. A total of 47 patients with an average age of 11 ± 2.72 months underwent to the same surgical technique. Blood transfusion during the surgical intervention was needed in 25 patients (53%), and 22 patients (46.8%) did not need blood transfusion. None of the 14 patients who used tranexamic acid (TXA) needed blood transfusions. We reported a statistically significant association between the use of TXA and blood transfusion ($p < 0.0001$), with a decreased need for blood transfusion with the use of TXA. Besides sagittal suturectomy, we create new parasagittal sutures by replacing the prematurely fused one, and 1.5 cm of the anterior segment of bone of those 2 rectangular structures are cut before fixation, to enable the immediate shortening of the anteroposterior (AP) diameter of the skull. Finally, we put a mesh plate (SonicWeld Rx, KLS Martin Group, Tuttlingen, Baden-Wuerttemberg, Germany) over the superior sagittal sinus (SSS), which is fixed anteriorly and posteriorly with pins (SonicPins Rx, KLS Martin Group). This procedure enables an immediate reduction of the AP diameter of the skull, with no further therapies needed, and promotes a wide decompression and remodeling of the skull. With an experienced

Keywords

- ▶ scaphocephaly
- ▶ superior sagittal sinus

received
July 2, 2023
accepted
February 21, 2024

DOI <https://doi.org/10.1055/s-0044-1786049>.
ISSN 0103-5355.

© 2024. Sociedade Brasileira de Neurocirurgia. All rights reserved. This is an open access article published by Thieme under the terms of the Creative Commons Attribution-NonDerivative-NonCommercial-License, permitting copying and reproduction so long as the original work is given appropriate credit. Contents may not be used for commercial purposes, or adapted, remixed, transformed or built upon. (<https://creativecommons.org/licenses/by-nc-nd/4.0/>)
Thieme Revinter Publicações Ltda., Rua do Matoso 170, Rio de Janeiro, RJ, CEP 20270-135, Brazil

surgical team and an anesthesiologic protocol, we were able to perform this surgery at early ages, requiring no blood transfusions.

Resumo

A escafocefalia continua sendo a forma mais prevalente de sinostose isolada de sutura única. Na maioria dos Centros de Neurocirurgia Pediátrica, o tratamento consiste em extensas operações de remodelação calvária, realizadas em idades relativamente tardias. Descrevemos uma técnica aberta modificada de reconstrução da calota craniana para escafocefalia e relatamos a abordagem anestésica e como ela influencia nossos resultados e permite a realização desta cirurgia em idades mais precoces. Um total de 47 pacientes com idade média de $11 \pm 2,72$ meses foram submetidos à mesma técnica cirúrgica. A transfusão sanguínea durante a intervenção cirúrgica foi necessária em 25 pacientes (53%) e 22 pacientes (46,8%) não necessitaram de transfusão sanguínea. Nenhum dos 14 pacientes que usaram ácido tranexâmico (TXA) precisou de transfusões de sangue. Relatamos uma associação estatisticamente significativa entre o uso de TXA e transfusão de sangue ($p < 0,0001$), com diminuição da necessidade de transfusão de sangue com o uso de TXA. Além da suturectomia sagital, criamos novas suturas parassagitais substituindo a fundida prematuramente, e 1,5 cm do segmento anterior do osso dessas duas estruturas retangulares são cortados antes da fixação, para permitir o encurtamento imediato do diâmetro ântero-posterior (AP) do crânio. Por fim, colocamos uma placa de tela (SonicWeld Rx, KLS Martin Group, Tuttlingen, Baden-Wuerttemberg, Alemanha) sobre o seio sagital superior (SSS), a qual é fixada anterior e posteriormente com pinos (SonicPins Rx, KLS Martin Group). Este procedimento permite uma redução imediata do diâmetro AP do crânio, sem necessidade de terapias adicionais, e promove ampla decompressão e remodelação do crânio. Com uma equipe cirúrgica experiente e um protocolo anestesiológico, conseguimos realizar esta cirurgia em idades precoces, sem necessidade de transfusões sanguíneas.

Palavras-chave

- escafocefalia
- seio sagital superior

Introduction

The premature fusion of the sagittal suture, known as scaphocephaly, remains the most prevalent form of isolated single-suture synostosis, accounting for 40% to 60% of all cases of craniosynostosis.^{1,2} The cranium acquires an elongated form with an enhancement of anteroposterior (AP) distance, which is typically accompanied by a bulging forehead and/or a prominent occiput, due to the shape of the coronal and lambdoid sutures. The aim of surgery is to oppose the abnormal longitudinal growth of the skull favoring its latero-lateral enlargement.³

The first surgical treatment for sagittal craniosynostosis was performed by Lannelongue in 1892, which consisted in a simple linear sagittal suture craniectomy.¹ Between 1969 and 1990, inadequacies in the results secondary to early reossification led to modifications in this technique to more extensive calvarial reshaping operations, such as the *Renier H* technique and *Pi* procedure.^{2,4,5}

More recently, after 1990, there has been a renewed interest in simple linear sagittal suturotomy with spring-assisted surgery or with minimally-invasive endoscopic procedures. However, with the spring-assisted procedure, a second surgery is necessary to remove the metal springs, and with the endoscopic approach, a molding helmet therapy is required

to obtain a good long-term cosmetic outcome.^{6,7} The esthetic results are not immediately visible in the postoperative period with both of these techniques.

There are many surgical options and opinions about the best operative treatment, but no definitive guidelines have been established, and there is a lack of studies to support or favor a particular surgical technique.⁸

The purpose of the present paper is to describe a modified technique of cranial vault reconstruction, an open approach, that we have used at Centro Hospitalar Universitário São João (CHUSJ) for scaphocephaly. Clinical observation and physical examination with head measurements were the main parameters to propose surgery – elongated head, manual palpation of a bony prominence over the sagittal suture, and biparietal and bitemporal narrowing are the main criteria for early surgery.

With the present technical note, the surgery immediately enables the reduction of the AP diameter of the skull, and does not require the use of a helmet.

Extensive blood loss is common in pediatric craniosynostosis reconstruction surgery. Tranexamic acid (TXA) is increasingly used to reduce perioperative blood loss in various settings, but data on its efficacy in children are limited.⁹ Here, we also aimed to report the anesthetic approach with the use of TXA, and how it has influenced our results,

as far as blood loss is concerned, enabling the performance of this surgery at earlier ages.

Materials and Methods

We designed a retrospective study to analyze the children with scaphocephaly who were surgically treated by an individual team and with a modified technique of cranial vault reconstruction, from January 2010 to December 2021 at CHUSJ.

Only children with isolated sagittal synostosis were included in the study, while those diagnosed with closing of other cranial sutures in addition to the sagittal and patients with syndromic or complex craniosynostosis were excluded.

All patients underwent a preoperative physical examination and three-dimensional computed tomography (CT). The following determinants were evaluated: age at the time of the surgery, gender, need for blood transfusion, use or not of TXA, and surgery complications.

Statistical Analysis

The continuous variables were expressed as mean, median, standard deviation, minimum, and maximum values, whereas the categorical variables were reported as frequencies and percentages. For the correlation analysis regarding the continuous variables, with normal distribution or not, the Pearson coefficient and Spearman correlation were used respectively. For the correlation analysis involving the categorical variables, the Chi-squared test was used. Values of $p < 0.05$ were considered statistically significant. The IBM SPSS Statistics for Windows (IBM Corp., Armonk, NY, United States) software, version 23.0, was used for the statistical analyses.

Surgical Technique

The operation is performed with the patient in the prone position with the head positioned on a horseshoe headrest to protect the eyes. The head is slightly elevated, retroflexed, and we use antidecubitus gel cushion to protect the shoulders and hip. An air-warming blanket is placed over the patient's body. The head is shaved in the operating theater and the skin is thoroughly prepared with antiseptic-colored tincture.

We perform a skin scalp incision in the retrocoronal plane from one ear to the other. A unique subgaleal and pericranium flap is elevated to visualize the calvarium from the anterior fontanel region and coronal suture to the lambdoid suture. This *one-layer flap* helps to preserve the pericranium, which is important to further promote osteosynthesis. Meticulous hemostasis of the soft tissue and bone is performed using bipolar cautery and bone wax.

The modified technique of cranial vault reconstruction started with a classic sagittal suturectomy by removing all the sagittal strip craniectomy of bone from the superior sagittal sinus (SSS). With the present technical note, we additionally create 2 AP rectangular structures by performing a strip craniotomy with 1.5 cm in width, parallel and

1.5 cm next to the SSS, stuck by a posterior pedicle of bone to the lambdoid suture but free of the coronal suture. With this maneuver, we create new parasagittal sutures replacing the prematurely fused sagittal suture.

Before fixation, 1.5 cm of the anterior segment of bone of those 2 rectangular structures parallel to the SSS are cut, to enable the immediate shortening of the AP diameter of the skull (► Fig. 1).

Laterally, on the parietal bones, toward the squamosal sutures, parallel barrel stave osteotomies with 0.5 to 1 cm in width are performed, as well as removal of the most anterior precoronal bone barrel on each side.

Then, a force-compressing maneuver shortens the AP skull distance and the 2 rectangular structures, parallel to the SSS, advance toward the frontal bone and are fixed with absorbable 2/0 stitches in this new position (► Fig. 2).

With the 1.5-cm osteotomy and fixation, we immediately reduce the AP diameter. The extent of calvary shortening in the AP diameter is notorious since then, with correspondent widening in latero-lateral cranial diameter.

Finally, we put a mesh plate (SonicWeld Rx, KLS Martin Group, Tuttlingen, Baden-Wuerttemberg, Germany) over the SSS, which is fixed anteriorly and posteriorly with pins (SonicPins Rx, KLS Martin Group). These mesh and pins are made from *poly-D, L-Lactic Acid* (PDLLA), which is a synthetic total absorbable and osteoinductive material (► Fig. 3). The mesh can be easily and flexibly adapted to the bone surface after softening in a water bath heated to 60° C, and once cooled down, the material reliably retains its new shape, turning rigid again.

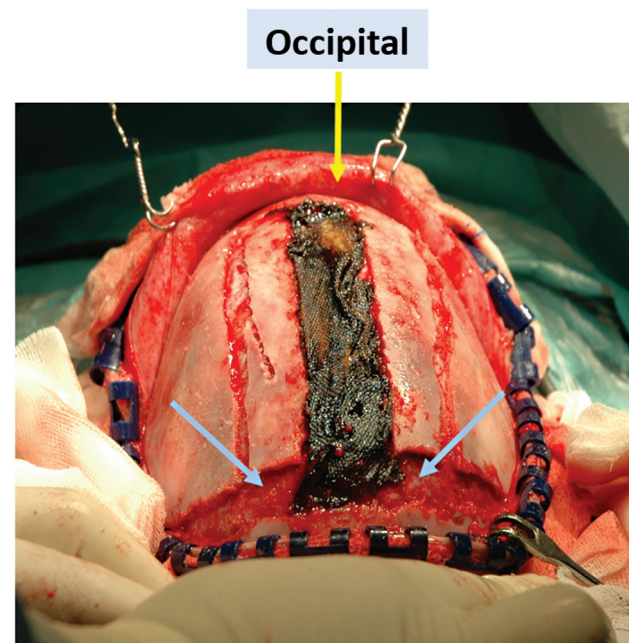


Fig. 1 Sagittal suturectomy and creation of two anteroposterior (AP) rectangular structures with 1.5 cm in width, parallel to the superior sagittal sinus (SSS), stuck by a posterior pedicle of bone and free of the coronal suture. Cut of 1.5 cm of the anterior segment of bone of the two rectangular structures parallel to the SSS (blue arrow).

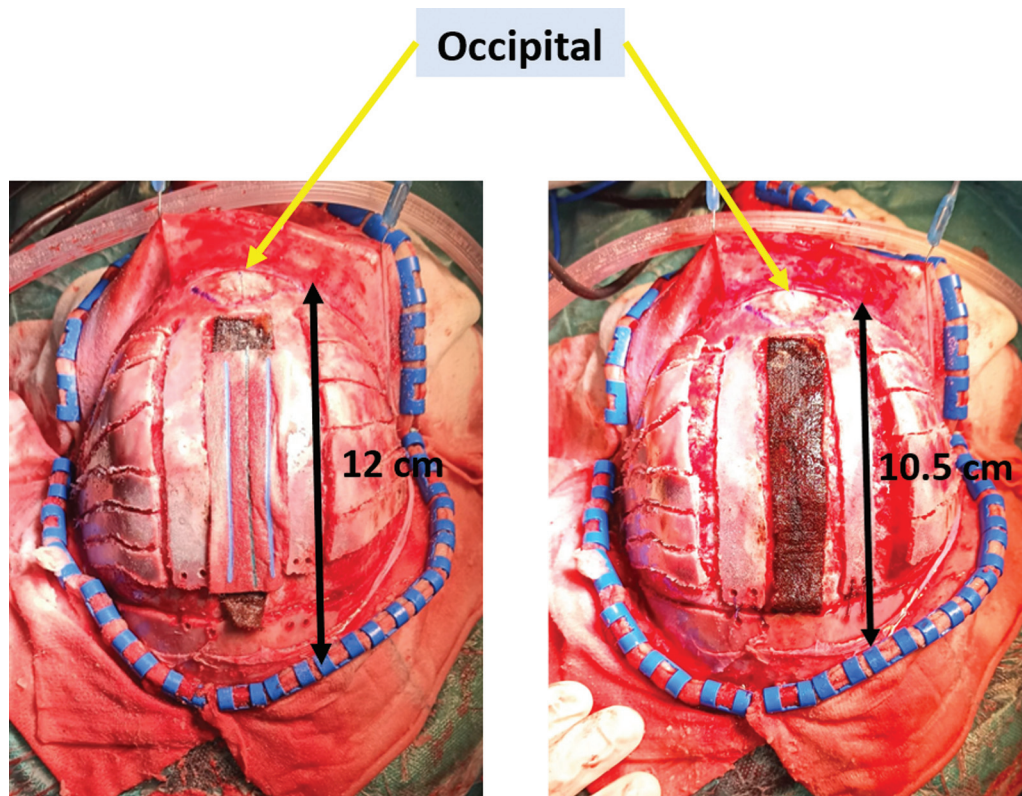


Fig. 2 Left side: cranial vault before the fixation and reduction of the AP cranial diameter; right side: after the force-compressing maneuver and fixation with immediate reduction of the AP cranial diameter.

The periosteal and subcutaneous flap and skin incision are then closed; a subgaleal drain is not used.

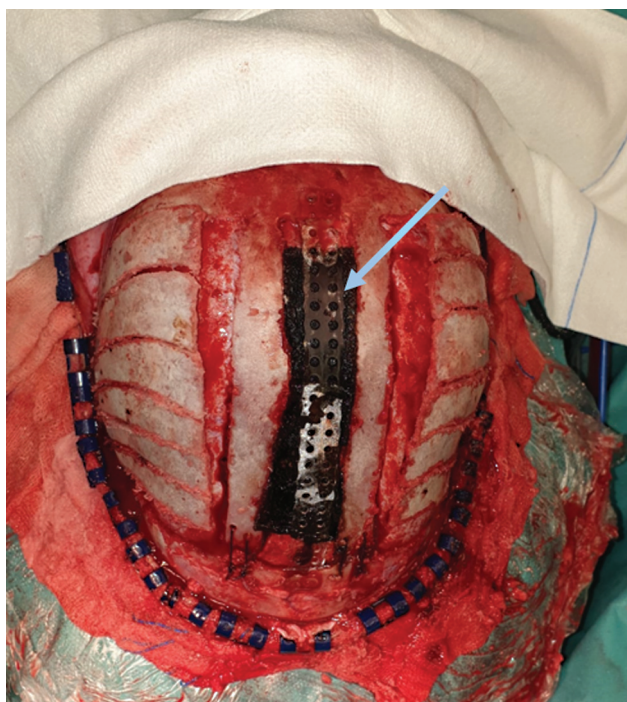


Fig. 3 Mesh plate (SonicWeld Rx, KLS Martin Group) over the SSS (blue arrow).

Results

In total, 47 (42 male and 5 female) patients underwent to the same surgical technique performed by the same surgical team. All patients underwent preoperative CT scans, but, as a matter of routine, postoperative CT scans were not performed, unless the patient showed signs of complications.

In the whole sample, the surgical procedure was performed at an average age of 11 ± 2.72 months. Before the use of TXA (before 2019), the mean age of the children at the time of the surgery was of 12 ± 2.93 months. After 2019, the mean age of the children was of 10 ± 2.31 months.

Blood transfusion during the surgical intervention was needed in 25 patients (53%), and 22 patients (46.8%) did not need blood transfusion. Regarding TXA, it was used in 14 patients (30%), and 33 patients (70.2%) did not receive it. None of the 14 patients who received TXA needed blood transfusions. Of the 33 patients who did not receive TXA, 8 did not need a blood transfusion, but 25 did (→ **Table 1**). With the Chi-Square test, we reported a statistically significant association between the use of TXA and blood transfusion ($p < 0.0001$), with a decreased need for blood transfusion with the use of TXA.

No intraoperative complication for the proposed operative technique was identified. We reported 2 postoperative complications (4.26%): 1 wound infection with no need of revision surgery and 1 case of cervical cellulitis which was resolved with antibiotic therapy. The average postoperative follow-up was of 11 ± 3.7 (minimum: 6; maximum: 16) months.

Table 1 Crosstabulation of blood transfusion and administration of tranexamic acid

		Tranexamic acid		Total
		No	Yes	
Blood transfusion	No	8	14	22
	Yes	25	0	25
	Total	33	14	47

Discussion

The one intraoperative advantage of an open cranial vault reconstruction is related to the large exposition of the skull, which enables the safe removal of the sagittal strip craniectomy of bone from the SSS. This enables a safer control of the SSS and the possibility of controlling any dural tears that might occur.

With our modified technique, first we create 2 rectangular bone pillars parallel to the SSS and remove 1.5 cm of the anterior segment of bone of those rectangular structures for frontal fixation. With this technical note, we immediately reduce the AP diameter of the skull, with cosmetic correction visible at the end of the surgery. The location and the number of the parietal barrel stave osteotomies can be easily tailored on the deformed cranium, enabling a targeted enlargement in the regions where the narrowing is greater. The surgical planning can be made in a digital workstation or even manufacturing some cutting guides (KLS Martin Group).

Despite the minimally-invasive nature of endoscopic surgery, it also carries some surgical risks and difficulties during the procedure. The detachment of the dura mater from the inner surface of bones in the craniotomy area can be difficult due to the small opening, increasing the risk of durotomies. Hemostasis is another important problem in this kind of procedure, and it should be performed at each stage during the surgery. There is a high risk of damage to the SSS and its repair can be complex in a minimally-invasive approach. It is important to note that a successful long-term outcome with endoscopic repair is critically dependent on postoperative molding with helmet (orthotic) therapy to augment the cranial index, which increases the costs associated with the procedure as well as its complications, such as alopecia.⁷

Spring-assisted cranioplasty has been proposed as an alternative to total calvarial remodeling. However, some of the major drawbacks include the need for a second procedure for removal, the lack of published long-term follow-up, and the fact that, in groups of older patients, further remodeling surgery is required.¹⁰

With the type of technique herein described, there is no need for any postoperative or preoperative molding therapy or later surgeries; therefore, further treatment is not required.

Comparing our modified technique of cranial vault reconstruction with other extensive calvarial reshaping operations, such as the *Renier H* technique and the *Pi* procedure,

we create new parasagittal sutures replacing the prematurely fused one and we immediately reduce the AP diameter of the skull. With the unique application of the mesh plate over the SSS, we can protect it from traumatic brain injury, which is so common at these ages. Additionally, it is a reinforcement of the bone suture performed to obtain the shortening of the AP diameter of the skull. This technique with this type of mesh and pins has never been described before, and the patients do not need further surgeries to remove the material incorporated.

Reducing blood loss and transfusion requirements has been an endless question in this type of cranial vault reconstruction.^{11,12} Tranexamic acid is an antifibrinolytic drug which has demonstrated a significant reduction in perioperative blood loss in many pediatric surgical procedures. Interest in using TXA in craniostomy surgery has risen since the publication of randomized controlled studies in 2011.⁹ Goobie et al.⁹ stated that TXA is effective in reducing blood loss and transfusion requirements in children undergoing craniostomy surgery; they reported a mean blood loss of 65 mL in the group that received TXA, and a mean blood loss of 119 mL among the patients who did not receive TXA ($p < 0.001$).

In the sample of the present study, we observed a statistically significant association between the use of TXA and blood transfusion, with a decreased of need for blood transfusion with the use of TXA ($p < 0.0001$). According to Martin et al.,¹³ TXA administration decreased blood loss both during and after surgery, reduced the volume of red-blood-cell transfusions, and resulted in complete elimination of the transfusion of other blood products, such as platelets and fresh frozen plasma. In most of the articles reviewed, all patients, even those who were administered TXA,^{1,3-5,9,13-15} received some type of transfusion, even if in smaller amounts than the group that did not receive TXA. In the sample of the present study, none of the patients who received TXA ($N = 14$) underwent any type of blood product transfusion (–Table 1).

In the present study, with the administration of TXA, we reduced the mean age of the child at the time of surgery to 10 ± 2.31 months, and, according to the literature,¹⁶ we know that we can achieve better cognitive and cosmetic results with earlier surgery. Therefore, the use of TXA may help to reduce the need for blood transfusion during and after the surgery and promote earlier surgery.

It is important to underline the importance of an experienced surgical team. The morbidity of the procedure, in the present study, was very low (of 4.26%), and there were no cases of mortality. According to Kajdic et al.,¹⁷ the mortality and morbidity rate is of 0.1%, and it may reach up to 50% in the case of severe blood loss.

Conclusion

The modified technique of cranial vault reconstruction for scaphocephaly herein described is a safe procedure, which enables the immediate reduction of the AP diameter of the skull, and no further therapies are needed. It also results in a

head with a normal appearance right after the procedure. The wide decompression of the brain and remodeling of the skull that can be obtained with the procedure are the most rewarding surgical results. With the combination of a careful anesthesiologic protocol, we were able to perform this surgery at early ages, requiring no blood transfusions.

Institution Where the Work Was Conducted

The Neurosurgery Service at Centro Hospitalar Universitário do São João.

Conflict of Interests

The authors have no conflict of interests to declare.

References

- Mehta VA, Bettegowda C, Jallo GI, Ahn ES. The evolution of surgical management for craniosynostosis. *Neurosurg Focus* 2010;29(06):E5
- Micovic M, Zivkovic B, Bascarevic V, Mijalčić R, Rasulic L. Triple square extended osteotomies for treatment of scaphocephaly (Renier's "H" technique modification). *Neurosurg Rev* 2016;39(01):115–122, discussion 122
- Melo JRT, Portella Junior CS, Lelis LC, Pires de Lima E. Scaphocephaly and cranial vault reconstruction: Renier's 'H' technique. *Pediatr Neurosurg* 2013;49(04):223–228
- Di Rocco F, Knoll BI, Arnaud E, et al. Scaphocephaly correction with retrocoronal and prelamdoid craniotomies (Renier's "H" technique). *Childs Nerv Syst* 2012;28(09):1327–1332
- Raposo-Amaral CE, Denadai R, Takata JPI, Ghizoni E, Buzzo CL, Raposo-Amaral CA. Progressive frontal morphology changes during the first year of a modified Pi procedure for scaphocephaly. *Childs Nerv Syst* 2016;32(02):337–344
- Lee BS, Hwang LS, Doumit GD, et al. Management options of non-syndromic sagittal craniosynostosis. *J Clin Neurosci* 2017; 39:28–34
- Goyal A, Lu VM, Yolcu YU, Elminawy M, Daniels DJ. Endoscopic versus open approach in craniosynostosis repair: a systematic review and meta-analysis of perioperative outcomes. *Childs Nerv Syst* 2018;34(09):1627–1637
- Yilmaz E, Mihci E, Nur B, Alper ÖM, Taçoş Ş Recent Advances in Craniosynostosis. *Pediatr Neurol* 2019;99:7–15
- Goobie SM, Meier PM, Pereira LM, et al. Efficacy of tranexamic acid in pediatric craniosynostosis surgery: a double-blind, placebo-controlled trial. *Anesthesiology* 2011;114(04):862–871
- Rodgers W, Glass G, Tahim A, et al. Spring Assisted Cranioplasty for the Correction of Non-Syndromic Scaphocephaly: A Quantitative Analysis of 100 consecutive cases. *Br J Oral Maxillofac Surg* 2016;54(10):167–168
- Boop FA, Chaddock WM, Shewmake K, Teo C. Outcome analysis of 85 patients undergoing the pi procedure for correction of sagittal synostosis. *J Neurosurg* 1996;85(01):50–55
- Guimarães-Ferreira J, Gewalli F, David L, Olsson R, Friede H, Lauritzen CG. Clinical outcome of the modified pi-plasty procedure for sagittal synostosis. *J Craniofac Surg* 2001;12(03): 218–224, discussion 225–226
- Martin DT, Gries H, Esmonde N, et al. Implementation of a Tranexamic Acid Protocol to Reduce Blood Loss During Cranial Vault Remodeling for Craniosynostosis. *J Craniofac Surg* 2016;27(06):1527–1531
- Eustache G, Riffaud L. Reducing blood loss in pediatric craniosynostosis surgery by use of tranexamic acid. *Neurochirurgie* 2019; 65(05):302–309
- Fischer S, Maltese G, Tarnow P, Wikberg E, Bernhardt P, Kölby L. Comparison of Intracranial Volume and Cephalic Index After Correction of Sagittal Synostosis With Spring-assisted Surgery or Pi-plasty. *J Craniofac Surg* 2016;27(02):410–413
- Arnaud E, Renier D, Marchac D. Prognosis for mental function in scaphocephaly. *J Neurosurg* 1995;83(03):476–479
- Kajdic N, Spazzapan P, Velnar T. Craniosynostosis - Recognition, clinical characteristics, and treatment. *Bosn J Basic Med Sci [Internet]*. 17 de junho de 2017 [citado 8 de outubro de 2022]; Disponível em: <https://www.bjbms.org/ojs/index.php/bjbms/article/view/2083>