



Polymorphous Low-Grade Neuroepithelial Tumor of the Young (PLNTY): Scoping Review of Case Reports and Case Series

Daulat Singh¹ Vijay P. Joshi² Sanjeev Pattankar³ Ved Prakash Maurya³^{ORCID} Rakesh Mishra⁴
Rafael Cincu⁵ Luis Rafael Moscote-Salazar⁶^{ORCID} Amit Agrawal⁷^{ORCID}

¹ Department of Radiotherapy and Clinical Oncology, Government Doon Medical College, Dehradun, Uttarakhand, India

² Sparsh Neuro and Superspeciality Hospital, Solapur, Maharashtra, India

³ Department of Neurosurgery, Sanjay Gandhi Postgraduate Institute of Medical Sciences, Lucknow, Uttar Pradesh, India

⁴ Department of Neurosurgery, Institute of Medical Sciences, Trauma Centre and Mahamana Centenary Superspeciality Hospital, Banaras Hindu University, Varanasi, Uttar Pradesh, India

⁵ Department of Neurosurgery, General University Hospital, Valencia, Spain

Address for correspondence Ved Prakash Maurya, MCh, Department of Neurosurgery, Sanjay Gandhi Postgraduate Institute of Medical Sciences, Lucknow, Uttar Pradesh 226014, India (e-mail: vpmsurgery@gmail.com; vpmaurya@sippi.ac.in).

⁶ Neurocritical Care, Colombian Clinical Research Group in Neurocritical Care, Bogota, Colombia

⁷ Department of Neurosurgery, All India Institute of Medical Sciences, Saket Nagar, Bhopal, Madhya Pradesh, India

Asian J Neurosurg 2024;19:126–136.

Abstract

Polymorphous low-grade neuroepithelial tumor of the young (PLNTY) is considered one of the low-grade neuroepithelial tumors, as per the World Health Organization 2021 classification of brain tumors. First described in 2016, these morphologically variable tumors are characterized by oligodendroglioma-like cellular components, infiltrative growth patterns, and cluster of differentiation 34 immunopositivity. A literature search of the PubMed/MEDLINE, SCOPUS, ScienceDirect, and COCHRANE databases (from inception to 20th June 2022) was carried out to identify relevant studies. To identify additional studies, we performed a recursive search of the bibliographies of the selected articles and published systematic reviews on this topic. The search yielded a total of 64 results. After removing duplicates, 26 articles were eligible for the review. The diagnostic criteria for these glioneuronal variants, representing a broad neuropathological spectrum, are not distinct and hence impede proper diagnosis and prognosis. Frequent genetic abnormalities involving mitogen-activated protein kinase pathway constituents, such as B-Raf proto-oncogene or fibroblast growth receptor 2/3, are harbored by PLNTYs. Recent advances in molecular diagnostics have resulted in more accurate tumor classification systems, based on gene expression profiles and DNA methylation patterns. Gross total resection seems curative, with a low recurrence rate. Malignant transformation is rare; however, adjuvant radiation therapy and chemotherapy may be beneficial in selected cases.

Keywords

- ▶ polymorphous low-grade neuroepithelial tumor of the young (PLNTY)
- ▶ scoping review
- ▶ low-grade neuroepithelial tumor
- ▶ calcification
- ▶ pseudorosetting

article published online
May 27, 2024

DOI <https://doi.org/10.1055/s-0044-1786700>.
ISSN 2248-9614.

© 2024. Asian Congress of Neurological Surgeons. All rights reserved.

This is an open access article published by Thieme under the terms of the Creative Commons Attribution-NonDerivative-NonCommercial-License, permitting copying and reproduction so long as the original work is given appropriate credit. Contents may not be used for commercial purposes, or adapted, remixed, transformed or built upon. (<https://creativecommons.org/licenses/by-nc-nd/4.0/>)

Thieme Medical and Scientific Publishers Pvt. Ltd., A-12, 2nd Floor, Sector 2, Noida-201301 UP, India

Introduction

Polymorphous low-grade neuroepithelial tumor of the young (PLNTY) was introduced in the World Health Organization (WHO) 2021 classification of central nervous system tumors as a diffuse low-grade glioma variety. Huse et al first described this novel entity in 10 patients who fulfilled the criteria for PLNTY.¹ Approximately 55 such cases have since then been reported.² Since Huse et al's pioneering work, every additional case has contributed valuable information to understanding this rare disease entity. These morphologically variable tumors are characterized by oligodendroglioma-like cellular components, infiltrative growth pattern, and a cluster of differentiation 34 (CD34) immunopositivity.¹ Because the topic of PLNTY has not been adequately reviewed and is complex and heterogeneous with a variable presentation, we conducted a scoping review to summarize the literature.^{3,4} This scoping review of case reports and case series was conducted to search all relevant cases of PLNTY in the literature from the selected electronic databases, and to understand the demographics, clinical presentations, imaging findings, management offered, and the overall outcome of this newly recognized entity. This review aimed to map the existing literature regarding patient characteristics, disease characteristics, and newer understanding. The review also aims to identify the literature gaps to guide future research.

Methods

The study design was a scoping review of case reports and series. We conducted the scoping review following the Arksey O Mailley guidance and definition of scoping reviews comprising six iterative stages and the Joanna Briggs Institute manual for scoping reviews.^{3,5} Preferred Reporting Items for Systematic Reviews and Meta-Analyses extension for scoping reviews (PRISMA ScR) guidelines were adhered to in synthesizing and reporting this scoping review.⁶

Stage I: Identifying the Research Question—Purpose

Relevant research questions for this review were: What are the clinical and radiological characteristics of the PLNTY? What are the histopathological characteristics of PLNTY? What are the immunopathological, molecular and genetic alterations in PLNTY? What is the outcome of PLNTY patients?

Stage II: Identifying Relevant Data Sources and Searches

The literature search included PubMed/MEDLINE, SCOPUS, Science Direct, and COCHRANE databases (till 20th June 2022). To identify additional studies, we performed a

recursive search of the bibliographies of the selected articles and published systematic reviews on this topic. Details of the search strategy and keywords are listed in ►Table 1. For this review, case reports, case series, and letter to editors were considered as relevant studies. The case should include the patients' demographics, clinical presentation, radiology, management details, histopathology, and outcome.

Stage III: Study Selection

We included studies that reported histopathologically confirmed PLNTY cases. Reviews and commentaries were excluded. The abstracts presented in conferences were searched in different search engines to identify if they were published as article. If the conference presentations were not published or did not have sufficient details, the same were excluded from the review. There were no restrictions applied on the language and year of publication.

Stage IV: Data Extraction

Two reviewers (VPM and AA) screened the titles and abstracts of all articles, the full text of the selected articles was reviewed, and any discrepancies between the two reviewers were evaluated and sorted by a third independent reviewer (RM). Detailed data were collected in a predesigned proforma. The details included study authors, year, type of publication, country of the corresponding author, number of cases, demographic details (gender and age), clinical presentation, imaging findings, offered management, histopathological details, and overall outcome of the patient (including follow-up clinical and imaging characteristics or any malignant transformation)

Stage V: Summarizing, Reporting and Collating the Results

We summarized and characterized the patient demographics, clinic-radiological characteristics, histopathology, immunopathology, and outcome in patients with PLNTY.

Results

The search yielded a total of 64 results. After removing duplicates, 27 articles were found to be eligible for inclusion in the review.^{1,2,7-30} One article was excluded as there was a publication available in English by the same authors with similar reported findings.³¹ The details of the study selection process in the form of a flowchart are shown in ►Fig. 1. This review consists of a total of 80 reported PLNTY patients. The mean age of the patients was 18.2 years (range: 4–57 years). There were 34 males and 46 females. The most common

Table 1 Details of search terms and strategy

ScienceDirect	Title, abstract, keywords: polymorphous low-grade neuroepithelial tumor of the young
SCOPUS	Title, abstract, keywords: polymorphous low-grade neuroepithelial tumor of the young
PubMed	"Polymorphous" [All Fields] AND "Low"[All Fields] AND "grade"[All Fields] AND "Neuroepithelial"[All Fields] AND "tumor"[All Fields] AND "young"[All Fields]
COCHRANE	Title, abstract, keywords: polymorphous low-grade neuroepithelial tumor of the young

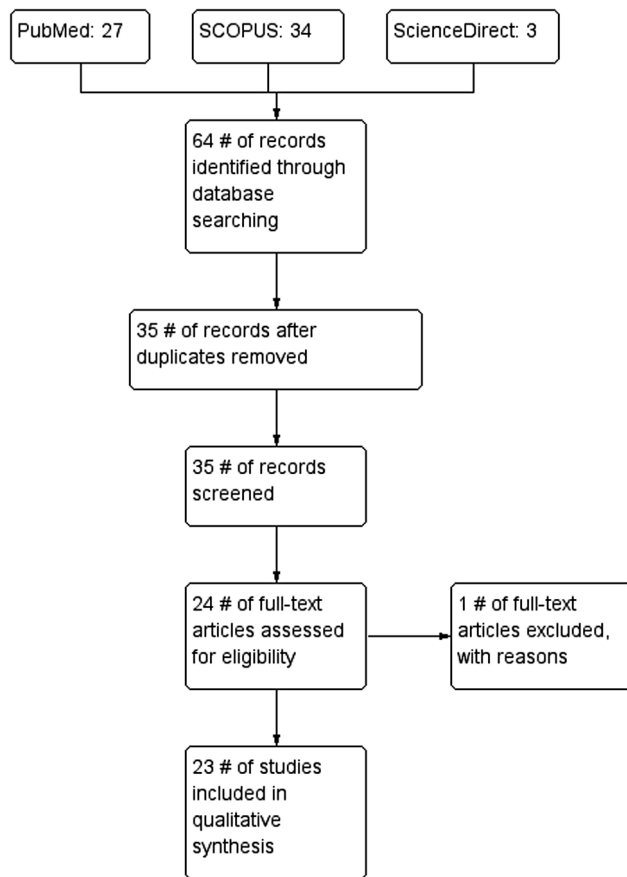


Fig. 1 Study flow diagram.

presenting symptom was seizures (in 59/80 patients) and nonseizure symptoms (in 27/80 patients). Presenting symptom of seizure was not reported in four patients. The non-seizure symptoms consist of headache, depression/manic depressive psychosis (esp., suicidal ideations), and visual disturbance. The lesion was located in temporal lobe in 65% of cases (52/28), followed by parietal lobe 12.5% (10/80), frontal 8.7% (7/80), and occipital 5% (4/80) lobes. There were two reports of intraventricular lesion, one in caudate nucleus, one in insula, one in temporoparietal, one in temporooccipital location, and not reported in one patient. The characteristics of the included studies is listed in ►Table 2. Excluded studies with reason for exclusion is mentioned in ►Table 3.

Discussion

Low-grade neuroepithelial tumors (LGNTs) are a diverse group of epileptogenic lesions that are encountered in children and young adults.³² LGNT exhibits a varying spectrum of histological features and glial or glioneuronal differentiation. The LGNT subtypes include diffuse astrocytomas, pilocytic astrocytomas, gangliogliomas, pleomorphic xanthoastrocytomas (PXA), dysembryoplastic neuroepithelial tumors, angiocentric gliomas, and oligodendrogliomas.²⁴ The diagnostic criteria for these LGNTs (especially glioneuronal variants), which represent a broad neuropathological spectrum, are not distinct, and hence impede proper diagnosis and prognosis. In contrast,

recent advances in molecular diagnostics have resulted in more accurate tumor classification systems based on gene expression profiles and DNA methylation patterns.

Patients' Characteristics

PLNTY is the recently described distinct type of LGNT and as the name suggest, it is seen in children and young adults. As per the literature, the median age described for PLNTY is 16 years. In this review of cases, the mean age of PLNTY patients was 18.2 years. PLNTY is reported more in females. In this review, we found 42.5% (34/80) males and 57.5% (46/80) females. About 73.7% patients presented with seizures followed by headache.

As consistent with most of the case series, the most common location was temporal in 65% of patients. However, there were reports of tumor in intraventricular location, caudate nucleus, and insula.

Clinicoradiological Characteristics

PLNTYs are derived from the cortex layer and appear as a solid or solid cystic mass with an unclear boundary with normal brain tissue. It is most commonly located in the temporal lobe, followed by occipital and frontal lobes. Tumors in most of the cases was well-circumscribed, cortical or subcortical, had calcifications and peripheral cystic components with minimal mass effect. Radiologically, PLNTYs are T1 iso-or-hyperintense and T2 hyperintense with slight or no contrast enhancement.^{11,33} Though the age predilection for PLNTYs has been reported to be 2 to 57 years, most cases are under 30 years of age.^{1,2,7-27} It has an equal sex preponderance. Among the 49 cases accounted for in ►Table 1, only five cases (including the index case) had nonepileptic clinical presentations, such as headache, imbalance, and behavioral abnormalities.^{1,9,24} These nonepileptic presentations are predominantly associated with extratemporal lesions, which account for about one-third of the cases.^{1,24} Kurokawa et al described the radiological features of PLNTY.²¹ They found PLNTY to be exclusively supratentorial tumors, with characteristic radiological features, such as cortical or subcortical masses (95.8%) in the temporal lobe (66.7%), calcification (83.3%), circumscribed margins (72.7%), solid cystic components (66.6%), and T2-weighted imaging hyperintensity (50.0%). The “trans-mantle-like” T2 /FLAIR (fluid-attenuated inversion recover) hyperintense signal was observed in 47.1% of the patients and was reported to be associated with a longer seizure duration (24 vs. 5 months) and cortical dysplasia.

Histopathology

Majority of the long-term epilepsy-associated brain tumors (LEAT) are low grade (WHO grade I or WHO grade II) with many morphological variants.¹¹ The pathological features of PLNTY include a polymorphous appearance, presence of cellular components, infiltrative growth pattern, and intense CD34 positivity. The addition of new term PLNTY in 2016 WHO update of brain tumor classification represents a molecularly unique category of LGNT representing a significant portion of oligodendroglioma like tumor noted in

Table 2 Characteristics of included studies

Author	Year	Country	Patients, n	Age in years	Gender, n	Symptoms, n	Tumour location	Radiological characteristics	Outcome at last follow-up (surgical outcome)	Reported mutations
Huse et al ¹	2017	USA	10	17.5 (4–32) ^a	Male: 4 Female: 6	Epileptic: 8 Nonepileptic: 2	Temporal: 7 Frontal: 1 Occipital: 2	Calcified, cystic, enhancing lesions	Stable: 8 (GTR 7, STR: 1) Recurrence: 1 ^c (GTR) NR: 1	BRAF V600E: 3 FGFR2: 3 ^c FGFR3: 1 NR: 3 (Temporal 2, occipital 1)
Bitar et al ⁹	2018	USA	1	31	Male	Epileptic	Temporal	NR	Stable (GTR)	BRAF V600E
Riva et al ²⁴	2018	Italy	1	57	Male	Nonepileptic	Frontal	Cystic lesion	Stable (NR)	FGFR3
Zhang and Sassooun ²⁸	2018	China	2	12	Female	Epileptic	Temporal	Heavily calcified, solid, cystic	Stable (GTR)	GFAP+, CD34+, IDH-, BRAF 600VE-, P53-ATRX retained, 1p-19Q codeletion absent, FGFR2 mutation +
Gupta et al ¹⁵	2019	USA	1	12	Female	Epileptic	Parietal	Heavy calcifications	Stable (GTR)	GFAP+, CD34+, IDH-, BRAF 600VE-, P53-ATRX retained, 1p-19Q codeletion absent, FGFR2 mutation absent
Johnson et al ¹⁸	2019	USA	9	16 (5–34) ^a	Male: 2 Female: 7	NR	Temporal: 6 Parietal: 2 3 rd ventricular: 1	Circumscribed lesion	Stable (GTR)	BRAF V600E
Kamalboor et al ¹⁹	2019	Saudi Arabia	1	23	Female	Epileptic	Temporal	NR	NR	BRAF V600E: 4 BRAF Fusion: 1 FGFR2: 3 None.: 1
Sumdani et al ²⁵	2019	USA	1	19	Male	Epileptic	Parietal	Calcified, cystic, circumscribed, enhancing lesions	NR	NR
Surrey et al ²⁶	2019	USA	6	12 (7–16) ^a	Male: 4 Female: 2	Epileptic: 6	Temporal: 3 Parietal: 1 Temporo-parietal: 1 Temporo-occipital: 1	Calcified, circumscribed lesion	Stable (NR)	BRAF V600E
Kamalboor et al ¹⁹	2019	Saudi Arabia	1	23	Female	Epileptic	Temporal	NR	GTR	NR
Benson et al ⁸	2020	USA	1	44	Female	Nonepileptic	Temporal	Calcified lesion	Stable (GTR)	BRAF V600E

(Continued)

Table 2 (Continued)

Author	Year	Country	Patients, n	Age in years	Gender, n	Symptoms, n	Tumour location	Radiological characteristics	Outcome at last follow-up (surgical outcome)	Reported mutations
Chen et al ¹¹	2020	China	3	15 (14–16) ^a	Male: 2 Female: 1	Epileptic: 3	Temporal: 2 Frontal: 1	Calcified, circumscribed lesions cystic lesion (frontal lesion)	Stable: 3 (GTR 3)	BRAF V600E: 1 FGFR3: 1 NR: 1 (Frontal)
Lelotte et al ²²	2020	Belgium	1	33	Female	Epileptic	Temporal	Cystic, circumscribed, cortical lesion	NR	BRAF V600E
Tateishi et al ²⁷	2020	Japan	1	14	Male	Epileptic	Temporal	Circumscribed, calcified, cystic lesion	Stable (GTR)	BRAF V600E
Gilani et al ²⁹	2020	USA	2	6	Female	NA	Insula	Ill-defined solid cystic mass lesion	Stable (GTR), no residual lesion at 13 months follow-up	FGFR2:K1AA1598
				11	Female	NA	Temporal	Heterogenous mass with numerous small cystic components	No recurrence at 9 months follow-up	FGFR3:TACC3
Bale et al ⁷	2021	USA	1	15	Female	Epileptic	Temporal	Circumscribed, calcified, cystic, enhancing lesion	Recurrence (GTR); additional NTR + adjuvant radiation & chemotherapy given.	FGFR3
Broggi et al ¹⁰	2021	Italy	1	50	Female	Epileptic	Temporal	Calcified lesion	NR (GTR)	BRAF V600E: absent FGFR2/3: NR
Danyeli et al ¹²	2021	Turkey	1	33	Female	Epileptic	Parietal	Circumscribed, noncystic, focal enhancing	Stable (GTR)	BRAF and FGFR: absent EGFR mutation (probably not driver mutation)
Ge et al ¹³	2021	China	2	19.5 (14–25) ^a	Female: 2	Epileptic: 2	Temporal: 1 Occipital: 1	Mixed-signal cortical lesions	Stable: 2 (GTR 2)	BRAF V600E: 1 NR: 1
Gupta et al ¹⁴	2021	USA	5	17.4 (11–38) ^a	Male: 3 Female: 2	Epileptic: 5	Temporal: 4 Frontal: 1	NR	Stable: 5 (GTR 5)	BRAF V600E: NR FGFR2: 5

Table 2 (Continued)

Author	Year	Country	Patients, n	Age in years	Gender, n	Symptoms, n	Tumour location	Radiological characteristics	Outcome at last follow-up (surgical outcome)	Reported mutations
Hendrych et al ¹⁶	2021	Czech Republic	1	27	Male	Epileptic	Parietal	Noncircumscribed, nonenhancing, calcified	Stable (GTR)	BRAF V600E
Ida et al ¹⁷	2021	USA	13	16 (5–52) ^b	Male: 3 Female: 10	Epileptic: 9 Nonepileptic: 3 NR: 1	Temporal: 9 Parietal: 3 NR: 1	Calcification: 10 (out of 11 available radiologies)	Stable: 7 (GTR 6) Outcome data available in 7 cases	BRAF V600E: 6 FGFR2: 5 QKI-NTRK2: 1 KIAA1549-BRAF: 1
Kikuchi et al ²⁰	2021	Japan	1	18	Male	Epileptic	Temporal	NR	Stable (NR)	NR
Fei et al ²	2022	Italy	8	8.5 (2–50) ^a	Male: 7 Female: 1	Epileptic: 8	Temporal: 4 Frontal: 3 Occipital: 1	Circumscribed, calcified, cystic lesions	Stable: 8 (GTR 8)	BRAF V600E: 4 NR: 4
Palejwala et al ²³	2022	USA	1	31	Female	Epileptic	Temporal	Circumscribed, cystic, calcified lesion	Stable (NR)	BRAF V600E
Zhao et al ³⁰	2022	China	5	25 (10–39)	Male: 2 Female: 3	Epileptic: 3 Nonepileptic: 2	Temporal: 3 Lateral ventricle: 1 Caudate nucleus: 1	NR	Stable (NR)	BRAF V600E: 2 PAK5-Q337R missense mutation: 1 FGFR2-CTNNA: 1 FGFR2-INA & FGFR2-PPRC1 fusion: 1

^aMean (range).

^bMedian (range).

^cRecurrence in FGFR2 tumor; FGFR, fibroblast growth factor receptor; GTR, gross total resection; NR, not reported; NTR, near total resection; STR, subtotal resection.

Table 3 List of excluded articles with reasons

Sl. no.	Study authors	Year of publication	Title	Journal	Country	Reason for exclusion
1.	Ge et al ¹³	2020	Clinicopathological features of polymorphous low-grade neuroepithelial tumor of the young	Chinese Journal of Pathology	China	A similar article in the English language in another journal present
2.	Métais et al ³⁴	2022	Low-grade epilepsy-associated neuroepithelial tumours with a prominent oligodendrogloma-like component: the diagnostic challenges	Neuropathology and Applied Neurobiology	France	PLNTY was not reported separately and did not include the information required for the review
3.	Slocum et al ³⁵	2022	Cerebellar tumor with FGFR2-KIAA1598 fusion and features of polymorphous low-grade neuroepithelial tumor of the young	Journal of Neuropathology and Experimental Neurology	USA	It was a meeting abstract. The abstract did not have the details required for the review, and the full-length abstract could not be retrieved
4.	Cases-Cunillera ³⁶	2022	Heterogeneity and excitability of BRAF(V600E)-induced tumors is determined by Akt/mTOR-signaling state and Trp53-loss	Neuro-oncology	Germany	Animal study
5.	Kurokawa et al ²¹	2022	Neuroradiological features of the polymorphous low-grade neuroepithelial tumor of the young: five new cases with a systematic review of the literature	Pediatric Neuroradiology	USA	Systematic review and details of fresh cases was not provided separately
6.	Golub et al ³⁷	2022	Polymorphous low-grade neuroepithelial tumor of the young with FGFR3-TACC3 fusion mimicking high-grade glioma: case report and series of high-grade correlates	Neuro-oncology	USA	It was a meeting abstract. The abstract did not have the details required for the review, and the full-length abstract could not be retrieved
7.	Vandenhoevel et al ³⁸	2022	A case of polymorphous low-grade neuroepithelial tumor of the young with polysomy of chromosome 1 and 19 lacking BRAF mutation	Pediatric Blood and Cancer	USA	It was a meeting abstract. The abstract did not have the details required for the review, and the full-length abstract could not be retrieved
8.	Majeed et al ³⁹	2021	Polymorphous low-grade neuroepithelial tumor of the young in a 47-year-old man presenting with headache and visual deficits	Journal of Neuropathology and Experimental Neurology	USA	It was a meeting abstract. The abstract did not have the details required for the review, and the full-length abstract could not be retrieved
9.	Sharma et al ⁴⁰	2018	Polymorphous low-grade neuroepithelial tumor of the young: a case report with genomic findings	Journal of Neuropathology and Experimental Neurology	USA	It was a meeting abstract. The abstract did not have the details required for the review, and the full-length abstract could not be retrieved

Abbreviations: FGFR, fibroblast growth factor receptor; PLNTY, polymorphous low-grade neuroepithelial tumor of the young.

pediatric age group. These tumors behave indolently and gross total resection leads to surgical cure of the patient. The molecular alterations of PLNTY in the form of MAP Kinase pathway activation are potential target for small molecular inhibitors. These lead to options for targeted therapy in patients of PLNTY with supposedly better outcome in the days to come.¹

Calcification and fibrous astrocyte formation were also observed. Tumor mitosis, necrosis, and microvascular proliferation are rare.² This neoplasm is associated with a history of epilepsy in young people, diffuse growth patterns, the frequent presence of components similar to oligodendroglioma, calcification, CD34 immunoreactivity, and genetic abnormalities that activate the mitogen-activated protein kinase (MAPK) pathway.³²

According to Vornetti et al, the expression of CD34 in considerable number of patients with PLNTY harboring B-raf (BRAF) mutation and BRAF wild-type represents a subset of LEATs. Presence of these immunomodulations and mutations lead to appearance of a variety of seizures as well as persistence of seizure for long time.⁴¹ The surgical management in DRE needs attention with regard to the localization of exact seizure discharging foci. Special attention is warranted with regard to DRE cases in contrast to resections for oncological cases because of the modulation in neuronal network and fresh recruitment of neuronal population acts as source of seizures. Hence, electrophysiological identification of seizure foci is mandatory beside clinicoradiological localization during surgical resection of such cases.¹ Although morphologically variable, they are found to have oligodendroglioma-like cellular components, infiltrative growth patterns, and intense CD34 immunopositivity. The DNA methylation signature of PLNTY closely resembled that of gangliogliomas. The cases described in the pilot study demonstrated a predominance in the temporal region, were right-sided, and had cystic components. Histopathological examination showed an infiltrative pattern, intra- and inter-tumor heterogeneity, variation in nuclei, perinuclear halo, and pseudorosetting. Calcification was defined as discrete calcospherules and confluent calcified masses. Imaging studies revealed unifocal regions of FLAIR hyperintensity with increased or mixed signal intensities on T2-weighted images.¹ The 2021 WHO central nervous system-5 (CNS-5) classification incorporated molecular advancements and recognized six new tumor types in LGNTs alone.³² Frequent genetic abnormalities in PLNTY involve components of the MAPK pathway, such as the B-raf proto-oncogene (BRAF) or fibroblast growth receptor 2/3 (FGFR 2/3). Radiologically, these are well-circumscribed lesions with calcified and cystic components that primarily affect the temporal lobe. Clinically, they present with seizures/epilepsy in young adults (aged <30 years).¹

Immunopathological Characteristics

PLNTY's low-grade nature of PLNTY, the presence of infiltrating oligodendrocyte-like cells, and their common association with cortical dysplasia are well established.²³ The exclusive immunopositivity of the PLNTYs solves the diagnostic dilemma of

differentiating these tumors from oligodendroglioma.¹ CD34, a transmembrane phosphoglycoprotein of early neurulation, is not expressed in mature brain cells. The presence of CD34 has been shown to correspond to drug-resistant epilepsy. Markers of glial differentiation (GFAP and Olig2) may be positive in both tumors. Notably, PLNTYs also lack immunopositivity for markers of neuronal differentiation, such as NeuN, which plays a pivotal role in differentiating them from other LGNTs.³⁴ In every case, the final diagnosis should be made only after considering the molecular profile and not on a pure histology basis. Despite their oligodendrogliomatous appearance, they did not show labelling for IDH1 R132H or chromosome 1p / 19q.¹ Consistent expression of CD 34, as seen in the PLNTY, is not found in the adult CNS and is generally foreign to infiltrating the lower grade and neoplasms of the oligodendroglioma group.¹ It has been hypothesized that CD34 expression originates from dysplastic and/or differentiating differently.¹⁰ Extravascular CD 34 positivity is commonly found in large neural or ramifying neuroepithelial cells.¹⁰

Genetic Alterations in PLNTY

DNA methylation signature for PLNTYs, along with frequent genetic abnormalities involving either B-Raf proto-oncogene (BRAF) or FGFR2, FGFR3, has been reported.¹ Identification of FGFR mutations in low-grade histological entities generated enthusiasm for the therapeutic potential and describing histological hallmarks. However, the FGFR genetic alterations are heterogenous concerning age (adult vs. pediatric) and grade of the tumor (low-grade and high-grade). Because of the heterogenous nature of FGFR alterations and its impact on the natural history of LGNTs, it has not yet been incorporated for classification of CNS tumors. Further, the challenge is that many cases reporting LGNTs or PLNTY do not report the genetic alterations present. Genetic changes in PLNTY involve MAP kinase pathways such as BRAF-V600E mutations or FGFR3 transforming acidic coiled coil containing protein 3 (TACC3), FGFR2- KIAA 1598, and FGFR- CTNNA3 fusion.¹⁰ Notably, FGFR fusions are mutually exclusive with BRAF V600E mutations.¹ Ki- 67 labelling index is typically less than 5%.²³

PLNTYs are known to harbor MAPK pathway alterations in the form of demonstrable BRAF or FGFR2/FGFR3 mutations.¹⁷ On the contrary, their typical mimic, oligodendrogliomas, have IDH mutations and 1p/ 19q co-deletions. Consistent with their low-grade classification, PLNTYs have a Ki-67 labelling index typically less than 5%. BRAF V600E mutations are not unique to PLNTYs alone. They also have associations with other LGNTs (like gangliogliomas, and PXAs).¹⁷ Alterations in FGFR2/3, belonging to the transmembrane tyrosine kinase receptor family, have been described with several different fusion partners (such as FGFR3TACC3, FGFR2-KIAA198, FGFR2-CTNNA3). The result of these fusions is an alteration of downstream effectors enhancing activation of the MAPK pathway.¹⁷ Although thought to be benign, one case of malignant transformation has been documented to date by Bale et al.⁷ The case presented by Bale et al demonstrated that a pediatric patient diagnosed with PLNTY with FGFR3- TACC3 fusion had a recurrence within less than

18 months. The recurrent lesion did not express CD 34 and had a high-grade focus similar to WHO grade IV. Associated with an indolent course, seizure control in PLNTY can be achieved with gross-total resection.²³ FGFR3-TACC3 (also described in a few glioblastomas) has been reported from the only PLNTY with malignant transformation.⁷ FGFR-TACC fusion has most of the features of PLNTY; however, the difference is that the FGFR-TACC fusion tends to occur more in elderly and has more invasive nature. Till date, there has been no case reported of PLNTY with FGFR2-CTNNA3 fusion suggesting a high-grade or aggressive tumor. Though FGFR2-CTNNA3 fusion is the signature genetic alteration found in PLNTY, other mutations like BRAF and FGFR3 are also seen in PLNTY cases and therefore, it should not be interpreted that these alternative mutations also suggest indolent and benign nature of these tumors and portend a favorable prognosis.⁴² In Huse et al's original series, three out of seven patients had BRAF 600VE mutation; however, no BRAF fusion was detected. More studies on genetic alterations in PLNTY will enhance the understanding the natural history of these rare tumors. The available literature on PLNTY strongly supports the association of focal cortical dysplasia, especially Focal cortical dysplasia (FCD) type IIIb. This association with FCD is a surrogate marker for increased frequency of seizure disorder in this subset of PLNTY. This is due to the fact that FCD is noticed in the developing brain and may infiltrate in the adjacent neocortex as tumor deposits which acts as source of increased epileptogenicity.^{43,44}

Outcome and Follow-Up

Gross total resection appears to be curative. Only three cases with radiological recurrence have been reported during follow-up periods.^{1,7,26} Adjuvant radiation therapy and chemotherapy were predominantly used in cases of malignant transformation.⁷ Data on seizures in PLNTYs need further elaboration. Fei et al observed that the epileptic zone identification is critical for every case of PLNTY, and an enlarged surgical resection (vs. recommended gross total resection) may provide better postoperative seizure controls.² At present there are very limited literature available regarding suicidal ideations having implications on other general neurological symptoms such as depression and personality changes. Commenting on these symptoms would be too early and we should wait for more convincing data soon.

Strengths and Limitations

The whole process of this scoping evaluation was conducted using exacting and open standards. A research group with knowledge synthesis and scoping review experience conducted the study. The search approach utilized two online search engines, the reference lists of several publications, four electronic bibliographic databases, the websites of pertinent organizations, and the snowball method to ensure a thorough literature search. The main strength is the comprehensive inclusion of articles from different study designs. Articles presenting relevant information even if they were meeting abstracts were included as per the criteria laid in the methodology. All reviewers reviewed and agreed

to the screening and data characterization forms, which were adjusted as necessary before being used. Two impartial reviewers looked at each reference and piece and got together regularly to work out any issues.

Even though we conducted the scoping review with iterative steps and an extensive search of the literature, there remains the possibility of missing an article in grey literature. We included several keywords in our search algorithm, but as PLNTYs is a relatively newer entity, some other words may also exist that have escaped the search strategy. Our search was conducted using only English terms, which introduces publication bias. It is also possible that we might not have captured all the case reports published in other languages, which is one of the limitations of the present review. Furthermore, we did not contact any researchers or experts for additional cases we may have missed.

Arksey and O'Malley's³ definition for scoping reviews was generally valuable for guiding study selection. However, we encountered challenges as many articles did not use the word PLNTY in the title or the abstract. Though PLNTY was present in the title and abstract in most of the included studies, some studies have used the term low-grade dysembryoplastic to indicate PLNTY. Two authors performed unbiased inclusion, screening, and interpretation of the literature in this review. Still, the reviewer bias could not be entirely removed as the individual judgment of the authors on screening, inclusion, characterization, and interpretation could be subjective.

Conclusion

LGNTs are an array of epileptogenic lesions encountered that originate from the cortex layer appearing as a solid or solid cystic mass with an ill-defined boundary with normal brain tissue. PLNTY has emerged as a substantial differential for low-grade glioma and should be considered during the diagnosis. The diagnostic criteria for these glioneuronal variants, representing a broad neuropathological spectrum, are not distinct and hence impede proper diagnosis and prognosis. Recent advances in molecular diagnostics have resulted in more accurate tumor classification systems based on gene expression profiles and DNA methylation patterns. Gross total resection seems curative, with a low recurrence rate (only three cases have been reported). Malignant transformation is rare; however, adjuvant radiation therapy and chemotherapy may need to be treated. All in all, introducing PLNTY as a variant of LGNTs has not changed its overall incidence, but has helped better manage and prognostic this patient cohort.

Note

PLNTY has emerged as one of the differential diagnoses for low-grade glioma. The diagnostic criteria and optimum management are not well defined in view of rarity of the condition. Well-circumscribed tumors situated in temporal lobe, with variegated appearance, central calcifications, and peripherally located cysts with minimal mass effects are characteristic radiological features. Gross total resection seems curative, with a low recurrence rate.

Funding

None.

Conflict of Interest

None declared.

References

- Huse JT, Snuderl M, Jones DT, et al. Polymorphous low-grade neuroepithelial tumor of the young (PLNTY): an epileptogenic neoplasm with oligodendroglioma-like components, aberrant CD34 expression, and genetic alterations involving the MAP kinase pathway. *Acta Neuropathol* 2017;133(03):417–429
- Fei X, Zhao J, Wei W, et al. Clinical, radiological, pathological features and seizure outcome with surgical management of polymorphous low-grade neuroepithelial tumor of the young associated with epilepsy. *Front Oncol* 2022;12:863373
- Arksey H, O'Malley L. Scoping studies: towards a methodological framework. *Int J Soc Res Methodol* 2005;8:19–32
- Mays N, Roberts E, Popay J. Synthesising research evidence. In: Fulop N, Allen P, Clarke A, Black N, eds. *Studying the Organisation and Delivery of Health Services: Research Methods*. London: Routledge; 2001
- Khalil H, Peters M, Godfrey CM, McInerney P, Soares CB, Parker D. An evidence-based approach to scoping reviews. *Worldviews Evid Based Nurs* 2016;13(02):118–123
- Tricco AC, Lillie E, Zarin W, et al. PRISMA extension for scoping reviews (PRISMA-ScR): checklist and explanation. *Ann Intern Med* 2018;169(07):467–473
- Bale TA, Sait SF, Benhamida J, et al. Malignant transformation of a polymorphous low grade neuroepithelial tumor of the young (PLNTY). *Acta Neuropathol* 2021;141(01):123–125
- Benson JC, Summerfield D, Carr C, et al. Polymorphous low-grade neuroepithelial tumor of the young as a partially calcified intra-axial mass in an adult. *AJNR Am J Neuroradiol* 2020;41(04):573–578
- Bitar M, Danish SF, Rosenblum MK. A newly diagnosed case of polymorphous low-grade neuroepithelial tumor of the young. *Clin Neuropathol* 2018;37(04):178–181
- Broggi G, Certo F, Altieri R, Caltabiano R, Gessi M, Barbagallo GMV. A “polymorphous low-grade neuroepithelial tumor of the young (PLNTY)” diagnosed in an adult. Report of a case and review of the literature. *Surg Neurol Int* 2021;12:470
- Chen Y, Tian T, Guo X, et al. Polymorphous low-grade neuroepithelial tumor of the young: case report and review focus on the radiological features and genetic alterations. *BMC Neurol* 2020;20(01):123
- Danyeli AE, Altinoz MA, Sari R, Elmaci I. Polymorphous low-grade neuroepithelial tumor of the young: a detailed pathomolecular analysis and discussion of a case. *Clin Neuropathol* 2021;40(05):271–278
- Ge R, Fang H, Yin X, Liu C, Chang Y. Case report of low-grade neuroepithelial tumour with oligodendroglioma-like components and CD34 expression. *Pathology* 2021;53(04):547–549
- Gupta R, Lucas CG, Wu J, et al. Low-grade glioneuronal tumors with FGFR2 fusion resolve into a single epigenetic group corresponding to ‘Polymorphous low-grade neuroepithelial tumor of the young’. *Acta Neuropathol* 2021;142(03):595–599
- Gupta VR, Giller C, Kolhe R, Forseen SE, Sharma S. Polymorphous low-grade neuroepithelial tumor of the young: a case report with genomic findings. *World Neurosurg* 2019;132:347–355
- Hendrych M, Hemza J, Kočvarová J, et al. Polymorphous low-grade neuroepithelial tumor of the young. *Ces Slov Neurol Neurochir* 2021;84/117:282–285
- Ida CM, Johnson DR, Nair AA, et al. Polymorphous low-grade neuroepithelial tumor of the young (PLNTY): molecular profiling confirms frequent MAPK pathway activation. *J Neuropathol Exp Neurol* 2021;80(09):821–829
- Johnson DR, Giannini C, Jenkins RB, Kim DK, Kaufmann TJ. Plenty of calcification: imaging characterization of polymorphous low-grade neuroepithelial tumor of the young. *Neuroradiology* 2019;61(11):1327–1332
- Kamalboor H, Dababo A, Alkhateeb M. Polymorphous low-grade neuroepithelial tumor of the young (PLNTY): case report and literature review. *J Neurol Sci* 2019;405:84
- Kikuchi K, Togao O, Yamashita K, et al. Diagnostic accuracy for the epileptogenic zone detection in focal epilepsy could be higher in FDG-PET/MRI than in FDG-PET/CT. *Eur Radiol* 2021;31(05):2915–2922
- Kurokawa M, Kurokawa R, Capizzano AA, et al. Neuroradiological features of the polymorphous low-grade neuroepithelial tumor of the young: five new cases with a systematic review of the literature. *Neuroradiology* 2022;64(06):1255–1264
- Lelotte J, Duprez T, Raftopoulos C, Michotte A. Polymorphous low-grade neuroepithelial tumor of the young: case report of a newly described histopathological entity. *Acta Neurol Belg* 2020;120(03):729–732
- Palejwala AH, O'Neal CM, Quinton MR, Battiste JD, Peterson JEG, Dunn IF. Polymorphous low-grade neuroepithelial tumor of the young: rare tumor and review of the literature. *Rare Tumors* 2022;14:20363613221083360
- Riva G, Cima L, Villanova M, et al. Low-grade neuroepithelial tumor: unusual presentation in an adult without history of seizures. *Neuropathology* 2018;38(05):557–560
- Sumdani H, Shahbuddin Z, Harper G, Hamilton L. Case report of rarely described polymorphous low-grade neuroepithelial tumor of the young and comparison with oligodendroglioma. *World Neurosurg* 2019;127:47–51
- Surrey LF, Jain P, Zhang B, et al. Genomic analysis of dysembryoplastic neuroepithelial tumor spectrum reveals a diversity of molecular alterations dysregulating the MAPK and PI3K/mTOR pathways. *J Neuropathol Exp Neurol* 2019;78(12):1100–1111
- Tateishi K, Ikegaya N, Udaka N, et al. BRAF V600E mutation mediates FDG-methionine uptake mismatch in polymorphous low-grade neuroepithelial tumor of the young. *Acta Neuropathol Commun* 2020;8(01):139
- Zhang K, Sassoan A. Polymorphous low-grade neuroepithelial tumor of the young (PLNTY): two cases of the recently described epileptogenic neoplasm with oligodendroglioma-like components and heavy calcification. *Am J Clin Pathol* 2018;150(suppl 1):S16–S17
- Gilani A, Davies K, Kleinschmidt-DeMasters B. Histological features in pediatric central nervous system tumors with FGFR alterations. *Folia Neuropathol* 2020;58(04):347–356
- Zhao S, Wang J, Li MN, Ding Y, Pan MH, Song K. [Clinicopathological features of polymorphous low-grade neuroepithelial tumor of the young]. *Zhonghua Bing Li Xue Za Zhi* 2022;51(07):640–646
- Ge R, Fang HF, Chang YQ, Li Z, Liu CF. [Clinicopathological features of polymorphous low-grade neuroepithelial tumor of the young]. *Zhonghua Bing Li Xue Za Zhi* 2020;49(11):1131–1135
- Bale TA, Rosenblum MK. The 2021 WHO classification of tumors of the central nervous system: an update on pediatric low-grade gliomas and glioneuronal tumors. *Brain Pathol* 2022;32(04):e13060
- Joshi V, Chougule MV, Mudkanna A, et al. Atypical presentation of polymorphous low-grade neuroepithelial tumor of young (PLNTY): a case report. *Egypt J Neurosurg* 2023;38:7
- Métais A, Appay R, Pagès M, et al. Contributors of the Biopathology RENOCLIP-LOC network. Low-grade epilepsy-associated neuroepithelial tumours with a prominent oligodendroglioma-like component: The diagnostic challenges. *Neuropathol Appl Neurobiol* 2022;48(02):e12769
- Slocum C, Hoffman C, Solomon J, Pisapia D. Abstract 197 – Cerebellar Tumor with FGFR2-KIAA1598 Fusion and Features of

- Polymorphous Low-grade Neuroepithelial Tumor of the Young. American Association of Neuropathologists, Inc. Abstracts of the 98th Annual Meeting June 9–12, 2022 Bonita Springs, Florida. *Journal of Neuropathology & Experimental Neurology* 2022;81(06):494–495
- 36 Cases-Cunillera S, van Loo KMJ, Pitsch J, et al. Heterogeneity and excitability of BRAFV600E-induced tumors is determined by Akt/mTOR-signaling state and Trp53-loss. *Neuro Oncol* 2022;24(05):741–754
- 37 Golub D, Lynch DG, Pan PC, et al. Polymorphous low-grade neuroepithelial tumor of the young with FGFR3-TACC3 fusion mimicking high-grade glioma: case report and series of high-grade correlates. *Front Oncol* 2023;21(13):1307591
- 38 Vandenhevel J, Zinn D. A case of polymorphous low-grade neuroepithelial tumor of the young with polysomy of chromosome 1 and 19 lacking BRAF mutation. Poster presented at Lehigh Valley Health Network, Allentown, PA.
- 39 Majeed M, McMillan C, Jo J, Lee K, Sippey C, Trembath D, Boyer P. Abstract 165 – Polymorphous Low-Grade Neuroepithelial Tumor of the Young in a 47-Year-Old Man Presenting with Headache and Visual Deficits. American Association of Neuropathologists, Inc. Abstracts of the 97th Annual Meeting June 10–13, 2021 St. Louis, Missouri. *Journal of Neuropathology & Experimental Neurology* 2021;80(06):600–601
- 40 Sharma S, Kolhe R, Giller C. Abstract 169 – Polymorphous low-grade neuroepithelial tumor of the young: a case report with genomic findings. American Association of Neuropathologists, Inc. Abstracts of the 94th Annual Meeting June 7–10, 2018 Louisville, Kentucky. *Journal of Neuropathology & Experimental Neurology* 2018;77(06):522
- 41 Vornetti G, Marucci G, Zenesini C, et al. Relationship among clinical, pathological and bio-molecular features in low-grade epilepsy-associated neuroepithelial tumors. *J Clin Neurosci* 2017;44:158–163
- 42 Bale TA. FGFR- gene family alterations in low-grade neuroepithelial tumors. *Acta Neuropathol Commun* 2020;8(01):21
- 43 Blumcke I, Aronica E, Urbach H, Alexopoulos A, Gonzalez-Martinez JA. A neuropathology-based approach to epilepsy surgery in brain tumors and proposal for a new terminology use for long-term epilepsy-associated brain tumors. *Acta Neuropathol* 2014;128(01):39–54
- 44 Blümcke I, Thom M, Aronica E, et al. The clinicopathologic spectrum of focal cortical dysplasias: a consensus classification proposed by an ad hoc Task Force of the ILAE Diagnostic Methods Commission. *Epilepsia* 2011;52(01):158–174