

Computerized Surgical Planning for Mandibular Distraction Osteogenesis

Kevin G. Hu, BA^{1,*} Ali Aral, MD^{1,*} Albert Rancu, BS¹ Michael Alperovich, MD¹

¹Division of Plastic and Reconstructive Surgery, Department of Surgery, Yale School of Medicine, New Haven, Connecticut

Semin Plast Surg

Address for correspondence Michael Alperovich, MD, Division of Plastic Surgery, Department of Surgery, Yale School of Medicine, 330 Cedar Street, Boardman Building, New Haven, CT 06510 (e-mail: Michael.alperovich@yale.edu).

Abstract

Mandibular distraction osteogenesis is a technically challenging procedure due to complex mandibular anatomy, especially in the treatment of Pierre-Robin Sequence due to variable bone thickness in the infant mandible and the presence of tooth buds. Computerized surgical planning (CSP) simplifies the procedure by preoperatively visualizing critical structures, producing cutting guides, and planning distractor placement. This paper describes the process of using CSP to plan mandibular distraction osteogenesis, including discussion of recent advances in the use of custom distractors.

Keywords

- ▶ Pierre Robin Sequence
- ▶ Mandibular Distraction Osteogenesis
- ▶ Computerized Surgical Planning

Computerized Surgical Planning (CSP) has been adopted across a wide range of specialties and procedures, yielding significant improvements in operative times¹⁻³ and complication rates.⁴ In regions with complex anatomy, CSP helps the surgeon protect critical structures. Mandibular distraction osteogenesis (MDO), a common treatment for Pierre Robin sequence (PRS), has incorporated CSP due to limited surface area anatomy in infants. This study describes the use of CSP for MDO in PRS, highlighting recent advances in the use of custom distractors in this patient population and future directions for improving outcomes.

Overview of Pierre Robin Sequence

Pierre Robin sequence (PRS) is a congenital birth defect characterized by micrognathia, glossoptosis, and upper airway obstruction, with up to 95% of PRS patients presenting with cleft palate.^{5,6} Prevalence estimates range from 0.2 to 19.1 per 100,000 patients,⁷⁻¹⁰ with no reported gender bias.⁸ PRS presents as part of a multisystem syndrome in 28%–65.6% of patients, including such syndromes as Stickler syndrome, Treacher Collins syndrome, and *22q11.2* deletion syndrome.^{5-8,10-12}

Functionally, the combination of micrognathia and glossoptosis contributes to a significant risk of airway obstruction and feeding difficulties.¹³ This obstruction can result in obstructive sleep apnea (OSA), even in infants without audible snoring.¹⁴⁻¹⁹ Untreated OSA in the neonate can produce numerous long-term sequelae, such as cognitive and behavioral deficits, metabolic derangements, and blood pressure elevation.²⁰ In severe PRS, the airway obstruction can be so pronounced as to lead to sudden death.²¹

Where conservative measures such as prone positioning or nasopharyngeal tube placement are inadequate to alleviate the airway obstruction, surgical intervention may be required.²² Possible surgical interventions include mandibular distraction osteogenesis (MDO), which incrementally lengthens the mandible to increase airway accessibility, and tongue–lip adhesion (TLA), which affixes the tongue to the lower lip. MDO has been shown to provide superior results compared with TLA with respect to apnea–hypopnea index reduction, elimination of OSA, avoidance of tracheostomy, achieving full oral feeds, and not requiring additional surgical interventions beyond the removal of the distractor device.^{12,23,24} Multiple studies have demonstrated that catch-up growth in early childhood and adolescence is not of sufficient magnitude to obviate the need for MDO.^{5,25-29}

* Both authors contributed equally as co-first authors.

Development of Computerized Surgical Planning for MDO

McCarthy et al in 1992 first described MDO in four cases of hemifacial microsomia.³⁰ Computerized Surgical Planning (CSP) was first utilized for MDO by Gateño et al in 2000, simulating the procedure in animation software with virtual models of facial skeleton scans.³¹ In 2001, Katzen et al developed a soft-tissue algorithm to accurately pinpoint the location of tooth follicles in the developing pediatric mandibles, allowing planning of distractor pin placement to avoid permanent damage to the teeth.³² Furthermore, CSP techniques have been shown to provide accurate and predictable results when comparing preoperative virtual plans and designs to the final measured surgical outcomes.^{33–36}

Creating simulated presurgical plans and customized cutting and drilling guides from CSP is now used in many complex craniofacial conditions including PRS, Treacher Collins syndrome, micrognathia, and craniosynostosis.^{37–40} Advances in virtual reality, artificial intelligence, and integration with robot-assisted surgeries continue to push the frontier of CSP's contribution to patient care.^{41–45}

Computerized Surgical Planning Workflow

Accurate CSP requires high-resolution 3D imaging of the patient's mandible. Ideally, a computed tomography (CT) skull craniofacial protocol with slices no thicker than 1 mm is obtained. Given the pace of growth in the neonatal period, it is important to time imaging as close as possible to surgery. 3D reconstruction and segmentation of the imaging scans

identifies the areas that need to be spared including any visible tooth roots and the course of the inferior alveolar nerve. Damage to the tooth-developing structures occurs in up to 48% of operative sides receiving MDO and may require orthodontic correction in adolescence or adulthood.⁴⁶ One factor complicating management of this risk is that operative damage is often-times not apparent until years after the initial procedure.^{46,47} Damage to the inferior alveolar nerve causes loss of sensation to the lower teeth, their corresponding gingiva, as well as the chin, with loss of cold sensation occurring in up to 2.5% of patients and lower lip motor weakness in up to 15% of half-mouths.⁴⁶ Furthermore, work in animal models also suggests that inferior alveolar nerve injury can impair the quality of healed bone after MDO, possibly through a piezoelectric mechanism.⁴⁸ These structures are segmented by the engineer, given a contrasting color, and made visible by applying a transparency filter to the overlying bone during surgical planning (►Fig. 1).

With a clear view, the osteotomy can be made sparing these critical structures. It is the preference of the authors to use an inverted L-osteotomy starting from the antegonial notch extending superiorly, then proceeding anteriorly to the internal medial border of the mandible inferior to the coronoid process (►Fig. 1). This course avoids the inferior alveolar nerve while also minimizing the proportion of the mandibular ramus that is involved. Any preferred osteotomy direction can be chosen if it can spare the tooth buds and the inferior alveolar nerve.

The vector of distraction is designed to optimize posterior airway volume, the principal goal of MDO. More horizontal distraction vectors have been shown to provide greater post-operative airway volumes compared with oblique/vertical

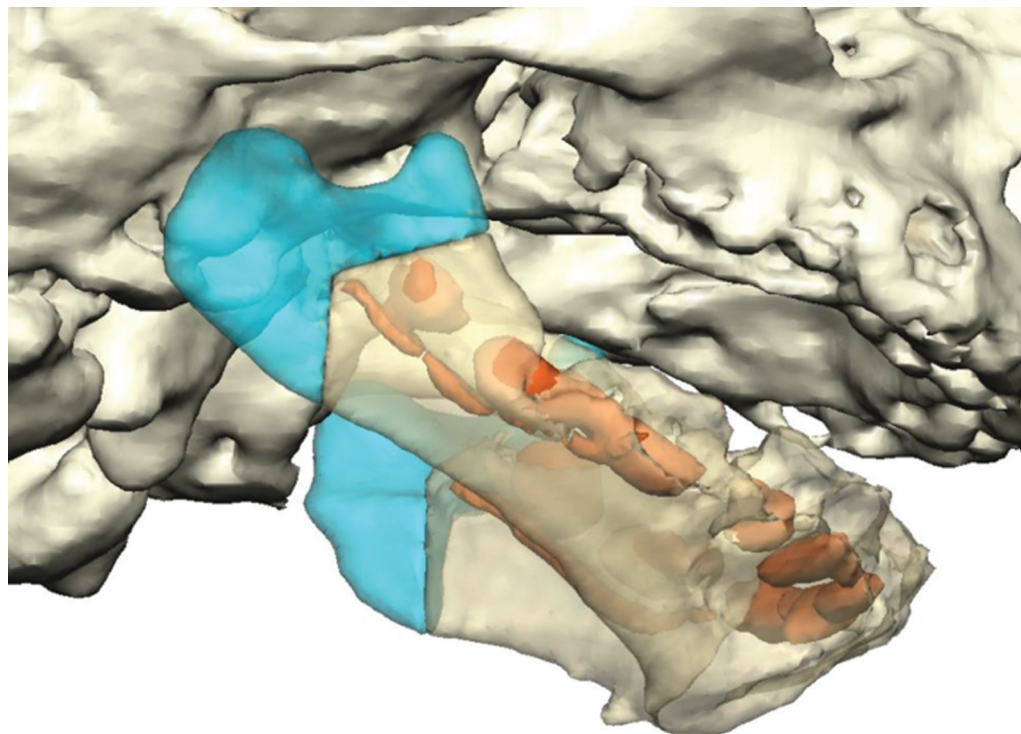


Fig. 1 Segmentation of the mandible reveals the developing tooth buds and inferior alveolar nerve, which are avoided by the planned inverted L-osteotomy.

Bone Thickness Heat Map – Patient Right

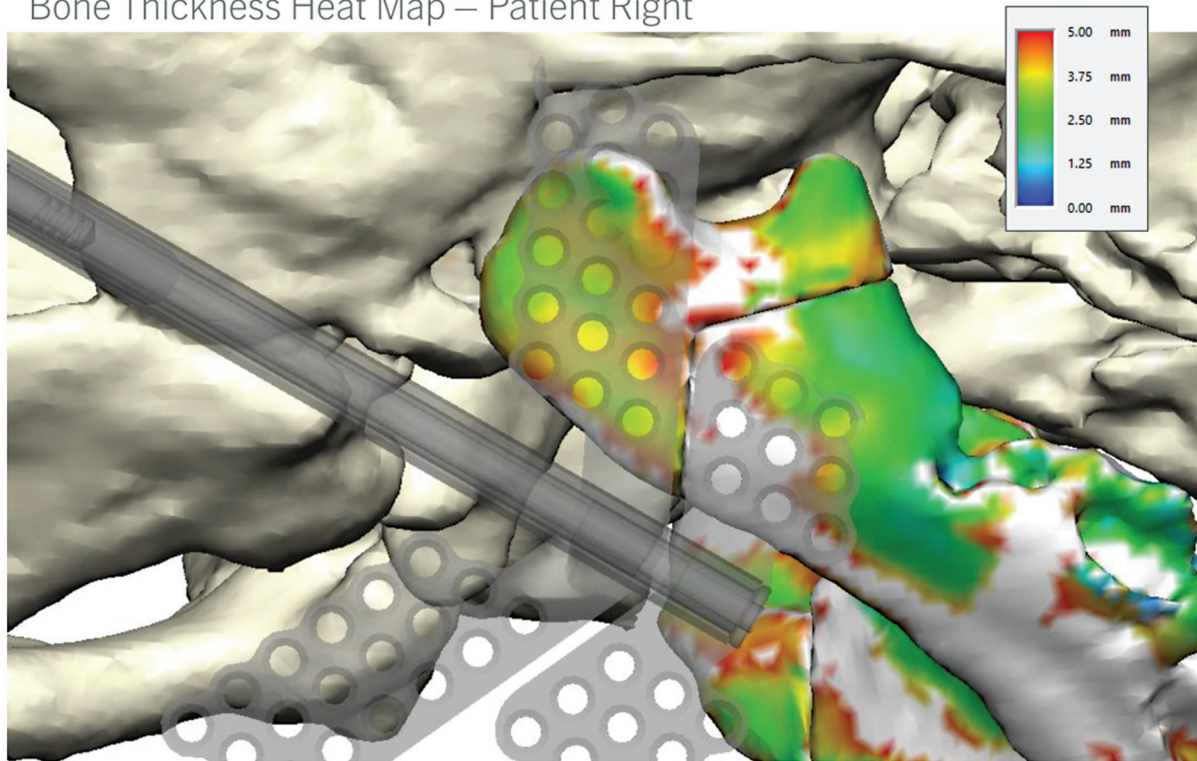


Fig. 2 Example of a heatmap of the osteotomy region. Regions in white are thicker than 5 mm.

distraction vectors.⁴⁹ Vertical vectors also increase the risk of temporomandibular joint ankylosis due to the increased force experienced at the temporomandibular joint.^{50–52} Ultimately, the choice of distraction vector should be made in accordance with the patient's unique anatomy. A patient with insufficient mandibular ramus height or excessive inferior rotation may benefit from a vertical vector of distraction to provide compensatory height and rotation.⁵⁰ While this phenomenon is more common in other diseases, such as Treacher Collins syndrome, it should still be considered for a PRS patient.⁵⁰ One can also choose the distraction vector by first choosing the desired final location for the distracted mandible. It is customary to overproject the mandible given the inevitable decreased growth rate of the distracted mandible.^{53,54}

Next, plate and screw positions are planned. The quality of the bone stock is evaluated for sufficient bone density and thickness, of particular concern in the skeletally immature neonate. A heatmap of the bone allows a holistic visualization of the patient's bone thickness for selecting screw positions (► **Fig. 2**). If possible, at least one 5-mm bicortical screw should be planned on each side of the osteotomy (► **Fig. 3**). Given the preset holes in conventional distractors, this may require adjustment of the osteotomy location. Screws are inserted based on the thickness of the available bone stock. Occasionally, monocortical screws are placed overlying tooth buds and the inferior alveolar nerve, but rarely in infants (► **Fig. 3**).

Cutting guides are printed for planning the osteotomy with pilot holes for each pin (► **Fig. 4**). Additionally, a 3D model of the mandible is printed showing the positions of the inferior

alveolar nerve and the developing tooth buds. If a cutting guide is not available, this model can also serve as a reference for marking out a safe osteotomy. The distractor footplates can be prebent to fit to the model, minimizing time spent modifying the distractor during the procedure itself.

During surgery, a Risdon incision is made in a submandibular crease. Dissection is performed to the level of the platysma, taking care to use a nerve stimulator or other such safeguard to identify and protect the marginal mandibular nerve running deep to the platysma. Once the mandibular periosteum is reached, subperiosteal dissection is performed. The cutting guide is affixed to the mandible and a monocortical osteotomy is performed first. The osteotomy can be bicortical at either end but partial thickness is maintained over the anticipated location of the inferior alveolar nerve. At this point, the distractor is prepared. Footplates are bent to sit flush on either side of the osteotomy. The distractor is fixated and activated for several millimeters. Activation is often sufficient to complete the osteotomy on the lingual side, but can be completed manually at this time if necessary. Finally, the distractor is placed back in a neutral position and the overlying tissue closed in layers.

Custom Distractors

The advent of 3D printing for medical devices has made it possible to create custom implants. While surgical planning has been used to plan the osteotomy direction, there is now capability for printing custom distractors that are bespoke for the patient's mandible. Screw holes are planned within

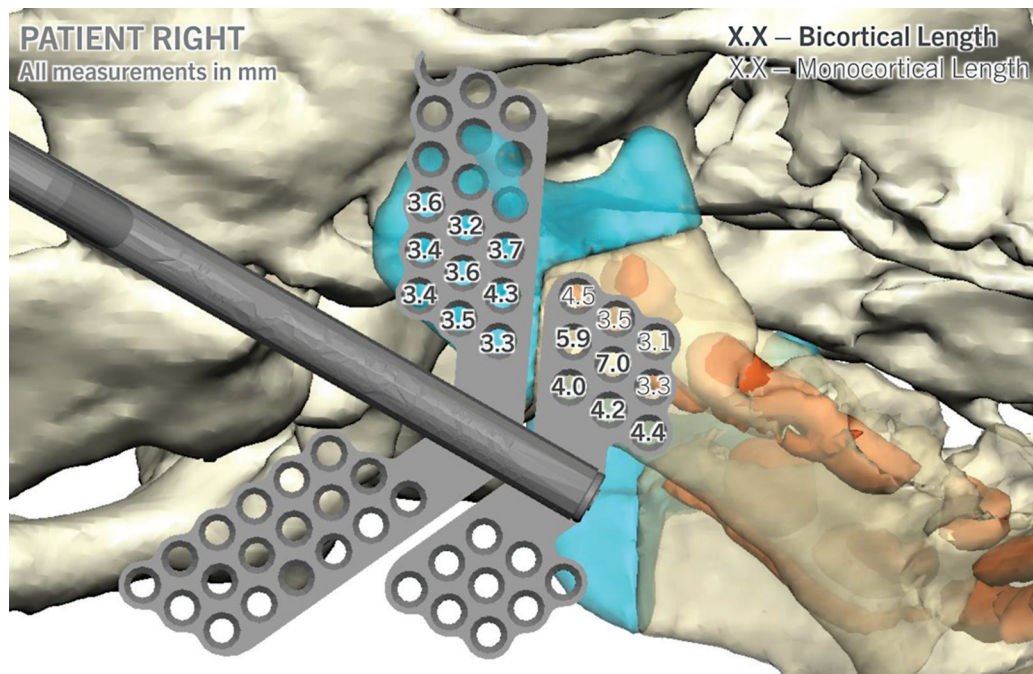
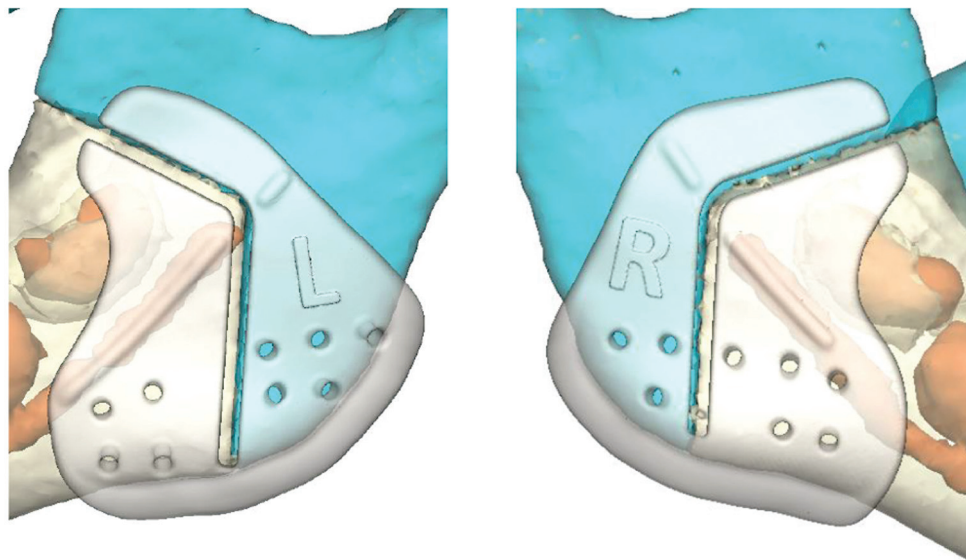



Fig. 3 Example placement of the distractor footplate, with planned screw lengths displayed in millimeters.



 Predictive distractor hole

Guides estimate nerve trajectory with raised bumps

Fig. 4 Placement of the cutting guides. Note the predictive distractor holes and the ridge overlying the course of the inferior alveolar nerve.

the distractor rather than the predetermined grid used in off-the-shelf distractors. In the experience of the authors, use of custom footplate distractors decreases operative time due to less time spent aligning the distractor to the patient's mandible. One disadvantage of using custom distractors is the increased production time needed for printing and shipping the distractor. As custom printing of medical

implants increases in popularity, such wait times are likely to drastically improve.

Postoperative Considerations

Desired postoperative outcomes include a decreased apnea-hypopnea index and improved feeding. Risk factors for complications include age at surgery greater than 30 days,

neurologic anomalies, significant central apnea, gastroesophageal reflux, preoperative intubation, concomitant cardiac comorbidities, and airway obstructions such as laryngomalacia, bronchomalacia, and tracheomalacia.^{55,56} With adequate interdisciplinary preparation between craniofacial surgeons, otolaryngologists, and other airway and medical specialists, PRS patients with mild to moderate forms of these risk factors can still significantly benefit from MDO, although judicious patient selection by the craniofacial surgeon is still recommended.⁵⁷ Extubation prior to postoperative day 5 also significantly increases the risk of respiratory adverse events.⁵⁸ There is also a risk of postoperative airway obstruction due to edema, particularly if cleft palate repair is concurrently performed.⁵⁹ Nonopioid analgesics, such as ketorolac or inferior alveolar nerve blocks, are preferred for pain control given the risk of opioid hypersensitivity due to chronic intermittent hypoxia.^{59,60}

Our protocol is to begin distraction following a 24-hour latency period. No studies have conclusively demonstrated an optimal distraction rate or rhythm for mandibular distraction. Prior to patient discharge, it is important to properly educate the patient caretakers on how to perform the distraction. Speech-language pathology consultation may also be of use to ensure safe feeding technique prior to patient discharge. Distractors are removed 2 to 3 months after completion of activation. At the time of distractor removal, it is important to assess the quality of bone regenerate. Should the regenerate be of insufficient quality, application of a resorbable plate has occasionally been needed for additional stability.

Case

A 4-week-old infant presented to the clinic with cleft palate, microretrognathia, and reported episodes of apnea when sleeping supine and difficulty feeding. Polysomnogram revealed an apnea/hypopnea index of 14.1 events per hour. In consultation with the patient's parents, otolaryngology, and sleep medicine, MDO was planned to address the patient's breathing and feeding difficulty.

High-resolution CT imaging of the skull was obtained with 0.6-mm-thick slices. Surgical planning identified the developing tooth buds and inferior alveolar nerve course (►Fig. 5). The inverted L-osteotomy was planned to avoid the course of the inferior alveolar nerve (►Fig. 5). The final advancement length was chosen as 20 mm (►Fig. 6). Custom footplates were designed with screw holes chosen for ideal bone thickness and safe placement (►Fig. 7).

The patient underwent surgery with the custom cutting guides and distractors at 3 months of age. Upon completion of the surgery, the patient remained intubated and was transferred to the pediatric intensive care unit for continued monitoring. Distraction was initiated on postoperative day 1 with 0.9 mm of distraction twice a day. The patient was extubated on postoperative day 3 and remained stable on room air. The patient was discharged on postoperative day 6 once the patient was feeding well and the parents were turning the distractor independently. The distractors were removed after 3 months without any complications. The patient recovered well with no reported difficulty with breathing or feeding. Cleft palate repair was performed at 12 months.

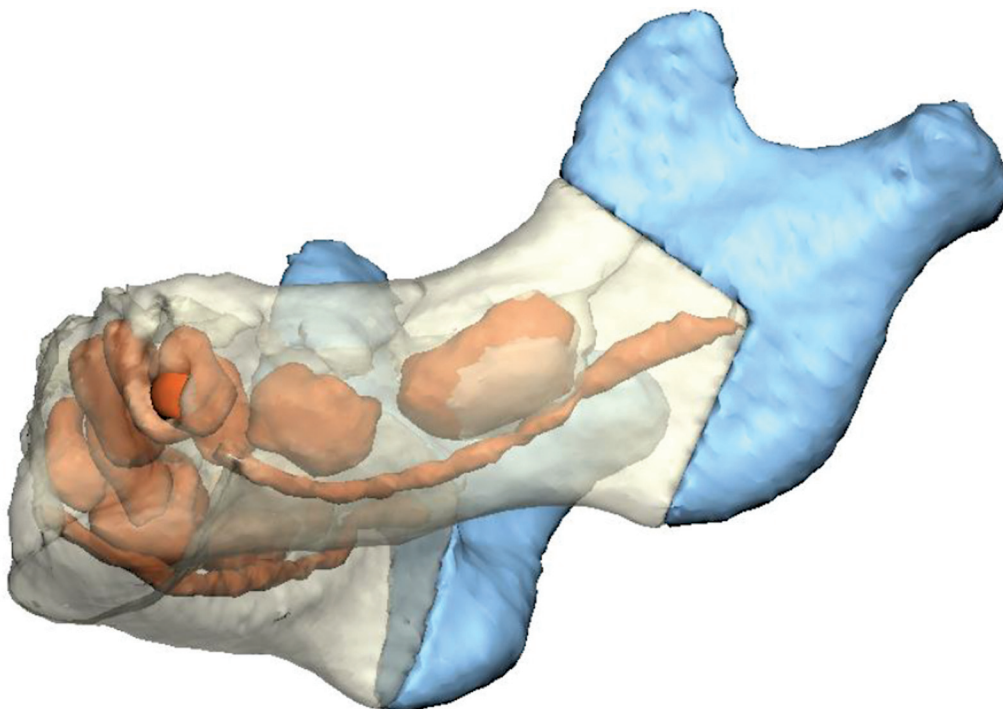


Fig. 5 Segmentation of the mandible for patient 1. *Blue* highlights the posterior mandible fragment after osteotomy and *red* highlights the developing structures to be avoided, such as tooth buds and the inferior alveolar nerve.

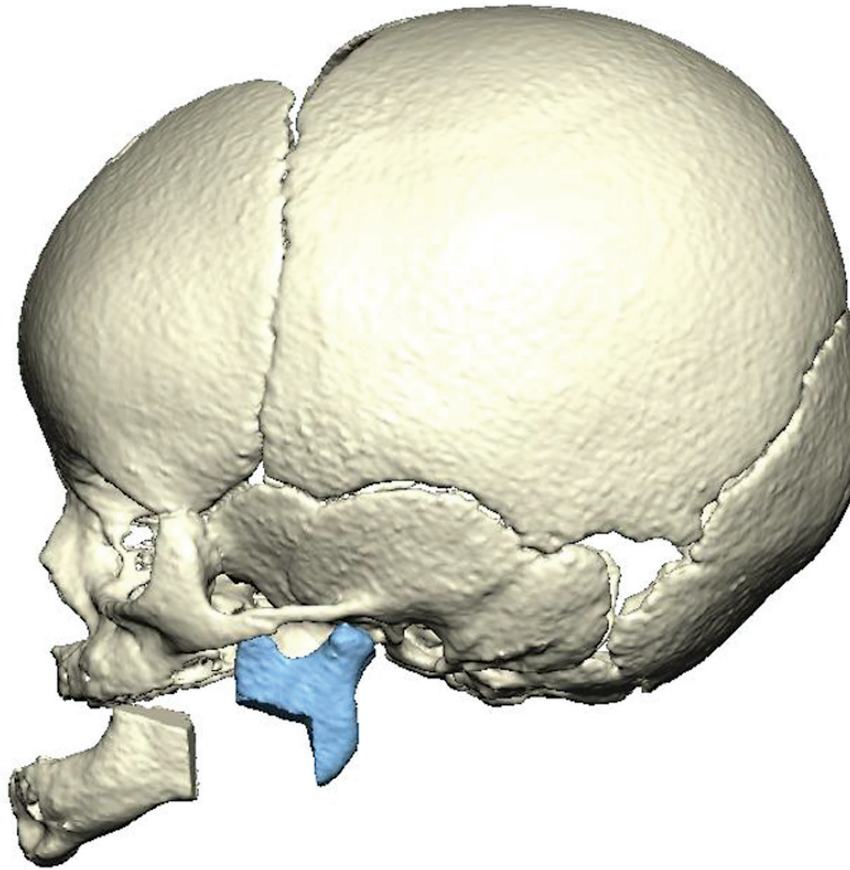


Fig. 6 The final position of the distracted mandible was chosen to be approximately 20 mm anteriorly. The distraction is primarily in the horizontal direction, maximizing the posterior airway volume.

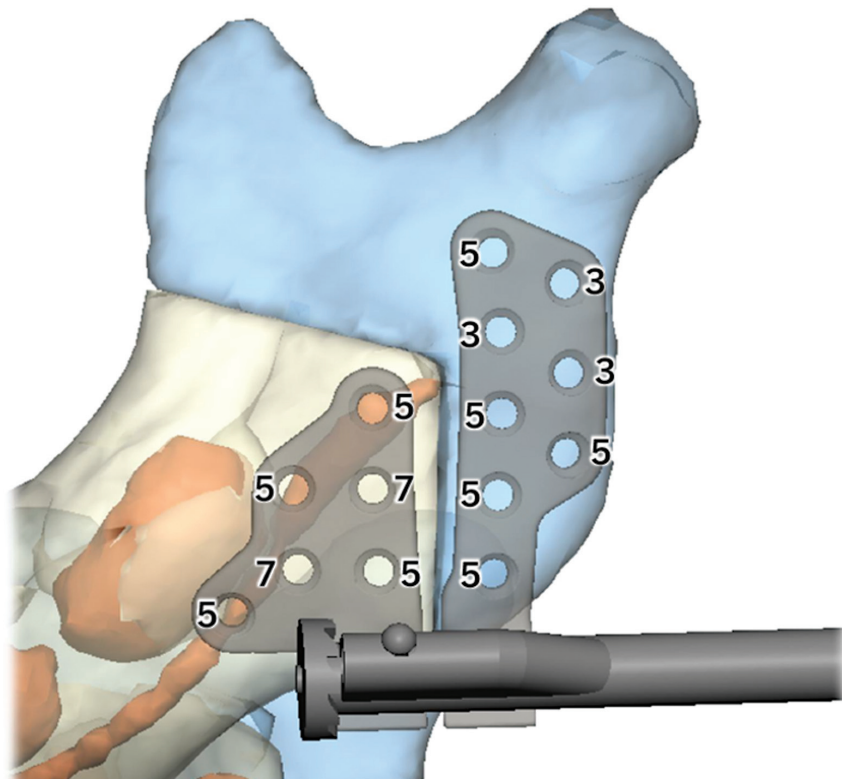


Fig. 7 The design of the custom footplate, along with identified safe pin positions, pin depths, and distraction rod direction.

Future Directions

Future studies are needed to compare operative outcomes with presurgical plans.⁶¹ The questions of cost-effectiveness of CSP for PRS and MDO more broadly also remain open, with existing studies demonstrating equivocal results in the settings of head and neck surgery and mandibular reconstruction.^{3,62}

The option of creating custom distractors is another step toward personalized medicine in the realm of surgery. The recent boom of large-language models has also sparked an interest in applying artificial intelligence and machine learning techniques to every corner of medicine. There is the potential for creating algorithms able to prepopulate optimal osteotomy locations or distraction vectors to maximize posterior airway volume while minimizing the risk of post-operative complications. There already exist multiple modalities to estimate airway volumes from CT imaging, although they currently lack significant between-method agreement.^{37–39} With sufficient cases and data, such musings may become reality.

Conclusion

PRS patients carry a high risk of morbidity due to the severity of their condition as well as a high risk of operative complications due to the immaturity of the mandibular bone and the density of important structures in the region. CSP allows for precise osteotomies and plate fixations while preserving the integrity of these structures. Decreased operative times are also likely to benefit the young infant, for whom extended time under anesthesia is not inconsequential. The development of custom distractors will only continue to advance these improvements in care, with possible developments in the ability to model operative outcomes with respect to airway volume on the horizon.

Funding

Dr. Alperovich receives funding from CTSA (grant number: KL2 TR001862) from the National Center for Advancing Translational Science (NCATS), a component of the National Institutes of Health (NIH), and consults for Johnson & Johnson and LifeNet Health. The manuscript contents are solely the responsibility of the authors and do not necessarily represent the official view of NIH.

Conflict of Interest

None declared.

References

- Almeida MN, Alper DP, Williams MCG, et al. Virtual surgical planning in craniostylosis reduces operative time and length of stay for cranial vault remodeling. *J Craniofac Surg* 2023;34(07):1931–1933
- Andrew TW, Baylan J, Mittermiller PA, et al. Virtual surgical planning decreases operative time for isolated single suture and multi-suture craniostylosis repair. *Plast Reconstr Surg Glob Open* 2018;6(12):e2038
- Mazzola F, Smithers F, Cheng K, et al. Time and cost-analysis of virtual surgical planning for head and neck reconstruction: a matched pair analysis. *Oral Oncol* 2020;100:104491
- May MM, Howe BM, O'Byrne TJ, et al. Short and long-term outcomes of three-dimensional printed surgical guides and virtual surgical planning versus conventional methods for fibula free flap reconstruction of the mandible: decreased nonunion and complication rates. *Head Neck* 2021;43(08):2342–2352
- Pfaff MJ, De Leon F, Le L, et al. Long-term orthognathic considerations in the Pierre Robin sequence patient. *Plast Reconstr Surg* 2020;146(05):599e–606e
- Wenger TL, Perkins J, Parish-Morris J, et al. Cleft palate morphology, genetic etiology, and risk of mortality in infants with Robin sequence. *Am J Med Genet A* 2021;185(12):3694–3700
- Wright MF, Knowles RL, Cortina-Borja M, Javadpour S, Mehendale FV, Urquhart DS. Epidemiology of Robin sequence in the UK and Ireland: an active surveillance study. *Arch Dis Child* 2023;108(09):748–753
- Wright M, Cortina-Borja M, Knowles R, Urquhart DS. Global birth prevalence of Robin sequence in live-born infants: a systematic review and meta-analysis. *Eur Respir Rev* 2023;32(170):230133
- Paes EC, van Nunen DP, Basart H, et al. Birth prevalence of Robin sequence in the Netherlands from 2000–2010: a retrospective population-based study in a large Dutch cohort and review of the literature. *Am J Med Genet A* 2015;167A(09):1972–1982
- Stoll C, Alembick Y, Roth MP. Associated anomalies in Pierre Robin sequence. *Am J Med Genet A* 2023;191(09):2312–2323
- Bakeman AE, Shaffer AD, Tobey ABJ, et al. Prevalence and management of laryngomalacia in patients with Pierre Robin sequence. *Cleft Palate Craniofac J* 2023;60(11):1395–1403
- Resnick CM, Calabrese CE, Sahdev R, Padwa BL. Is tongue-lip adhesion or mandibular distraction more effective in relieving obstructive apnea in infants with Robin sequence? *J Oral Maxillofac Surg* 2019;77(03):591–600
- Zaballa K, Singh J, Waters K. The management of upper airway obstruction in Pierre Robin Sequence. *Paediatr Respir Rev* 2023;45:11–15
- Anderson IC, Sedaghat AR, McGinley BM, Redett RJ, Boss EF, Ishman SL. Prevalence and severity of obstructive sleep apnea and snoring in infants with Pierre Robin sequence. *Cleft Palate Craniofac J* 2011;48(05):614–618
- Lee JJ, Thottam PJ, Ford MD, Jabbour N. Characteristics of sleep apnea in infants with Pierre-Robin sequence: is there improvement with advancing age? *Int J Pediatr Otorhinolaryngol* 2015;79(12):2059–2067
- Semensato MM, Trindade SHK, Marzano-Rodrigues MN, Scomparin L, Trindade-Suedam I. Screening for obstructive sleep apnea and associated risk factors in adolescents and adults with isolated Robin sequence. *Cleft Palate Craniofac J* 2024;61(01):79–86
- Wiechers C, Uhlig S, Poets A, et al. Sleep and neurocognitive outcome in primary school children with Robin Sequence. *Sleep* 2023;46(05):zsac317
- Kukkola HK, Vuola P, Seppä-Moilanen M, Salminen P, Kirjavainen T. Pierre Robin sequence causes position-dependent obstructive sleep apnoea in infants. *Arch Dis Child* 2021;106(10):954–960
- Broucqsaault H, Lamblin MD, Hosana G, Fayoux P. Evaluation of the efficacy of tongue-lip adhesion in Pierre Robin sequence. *Eur Ann Otorhinolaryngol Head Neck Dis* 2018;135(03):155–158
- Spicuzza L, Leonardi S, La Rosa M. Pediatric sleep apnea: early onset of the “syndrome”? *Sleep Med Rev* 2009;13(02):111–122
- Randall P. The Robin anomalad: micrognathia and glossoptosis with air way obstruction. In: Converse JM, ed. *Reconstructive Plastic Surgery*. Philadelphia: WB Saunders; 1977:2235–2245
- Freitas RDS, do Prado D, Guarezi Nasser IJ, Peressutti C, Ogawa VS. Pierre Robin sequence and respiratory distress: long-term evolution in patients submitted to the conservative treatment. *J Craniofac Surg* 2023;34(04):1267–1270

- 23 Khansa I, Hall C, Madhoun LL, et al. Airway and feeding outcomes of mandibular distraction, tongue-lip adhesion, and conservative management in Pierre Robin sequence: a prospective study. *Plast Reconstr Surg* 2017;139(04):975e–983e
- 24 Zhang RS, Hoppe IC, Taylor JA, Bartlett SP. Surgical management and outcomes of Pierre Robin sequence: a comparison of mandibular distraction osteogenesis and tongue-lip adhesion. *Plast Reconstr Surg* 2018;142(02):480–509
- 25 Suri S, Ross RB, Tompson BD. Craniofacial morphology and adolescent facial growth in Pierre Robin sequence. *Am J Orthod Dentofacial Orthop* 2010;137(06):763–774
- 26 Ozawa TO, Lorenzoni DC, de Oliveira LG, da Silva Filho OG. Facial profile evaluation of isolated Pierre Robin sequence. *Cleft Palate Craniofac J* 2012;49(05):546–552
- 27 Daskalogiannakis J, Ross RB, Tompson BD. The mandibular catch-up growth controversy in Pierre Robin sequence. *Am J Orthod Dentofacial Orthop* 2001;120(03):280–285
- 28 Purnell CA, Janes LE, Klosowiak JL, Gosain AK. Mandibular catch-up growth in Pierre Robin sequence: a systematic review. *Cleft Palate Craniofac J* 2019;56(02):168–176
- 29 Krimmel M, Kluba S, Breidt M, et al. Three-dimensional assessment of facial development in children with Pierre Robin sequence. *J Craniofac Surg* 2009;20(06):2055–2060
- 30 McCarthy JG, Schreiber J, Karp N, Thorne CH, Grayson BH. Lengthening the human mandible by gradual distraction. *Plast Reconstr Surg* 1992;89(01):1–8, discussion 9–10
- 31 Gateño J, Teichgraeber JF, Aguilar E. Distraction osteogenesis: a new surgical technique for use with the multiplanar mandibular distractor. *Plast Reconstr Surg* 2000;105(03):883–888
- 32 Katzen JT, Holliday RA, McCarthy JG. Imaging the neonatal mandible for accurate distraction osteogenesis. *J Craniofac Surg* 2001;12(01):26–30
- 33 Li B, Sun H, Zeng F, Zhang T, Wang X. Accuracy of a CAD/CAM surgical template for mandibular distraction: a preliminary study. *Br J Oral Maxillofac Surg* 2018;56(09):814–819
- 34 Chen K, Xiao D, Abotaleb B, Chen H, Li Y, Zhu S. Accuracy of virtual surgical planning in treatment of temporomandibular joint ankylosis using distraction osteogenesis: comparison of planned and actual results. *J Oral Maxillofac Surg* 2018;76(11):2422.e1–2422.e20
- 35 Vanesa V, Irene MP, Marta AS, et al. Accuracy of virtually planned mandibular distraction in a pediatric case series. *J Craniomaxillofac Surg* 2021;49(02):154–165
- 36 Tan A, Chai Y, Mooi W, et al. Computer-assisted surgery in therapeutic strategy distraction osteogenesis of hemifacial microsomia: accuracy and predictability. *J Craniomaxillofac Surg* 2019;47(02):204–218
- 37 Resnick CM. Precise osteotomies for mandibular distraction in infants with Robin sequence using virtual surgical planning. *Int J Oral Maxillofac Implants* 2018;47(01):35–43
- 38 Doscher ME, Garfein ES, Bent J, Tepper OM. Neonatal mandibular distraction osteogenesis: converting virtual surgical planning into an operative reality. *Int J Pediatr Otorhinolaryngol* 2014;78(02):381–384
- 39 Day KM, Gabrick KS, Sargent LA. Applications of computer technology in complex craniofacial reconstruction. *Plast Reconstr Surg Glob Open* 2018;6(03):e1655
- 40 Yu H, Wang B, Wang M, Wang X, Shen SG. Computer-assisted distraction osteogenesis in the treatment of hemifacial microsomia. *J Craniofac Surg* 2016;27(06):1539–1542
- 41 Robiony M, Salvo I, Costa F, et al. Virtual reality surgical planning for maxillofacial distraction osteogenesis: the role of reverse engineering rapid prototyping and cooperative work. *J Oral Maxillofac Surg* 2007;65(06):1198–1208
- 42 Yang WF, Su YX. Artificial intelligence-enabled automatic segmentation of skull CT facilitates computer-assisted craniomaxillofacial surgery. *Oral Oncol* 2021;118:105360
- 43 Kim BS, Zhang Z, Sun M, et al. Feasibility of a robot-assisted surgical navigation system for mandibular distraction osteogenesis in hemifacial microsomia: a model experiment. *J Craniofac Surg* 2023;34(02):525–531
- 44 Zhang Z, Kim BS, Han W, et al. Preliminary study of the accuracy and safety of robot-assisted mandibular distraction osteogenesis with electromagnetic navigation in hemifacial microsomia using rabbit models. *Sci Rep* 2022;12(01):19572
- 45 Qiu X, Han W, Dai L, et al. Assessment of an artificial intelligence mandibular osteotomy design system: a retrospective study. *Aesthetic Plast Surg* 2022;46(03):1303–1313
- 46 Steinberg JP, Brady CM, Waters BR, et al. Mid-term dental and nerve-related complications of infant distraction for Robin sequence. *Plast Reconstr Surg* 2016;138(01):82e–90e
- 47 Kleine-Hakala M, Hukka J, Hurmerinta K. Effect of mandibular distraction osteogenesis on developing molars. *Orthod Craniofac Res* 2007;10(04):196–202
- 48 Cao J, Zhang S, Gupta A, et al. Sensory nerves affect bone regeneration in rabbit mandibular distraction osteogenesis. *Int J Med Sci* 2019;16(06):831–837
- 49 Zellner EG, Mhlaba JM, Reid RR, Steinbacher DM. Does mandibular distraction vector influence airway volumes and outcome? *J Oral Maxillofac Surg* 2017;75(01):167–177
- 50 Flores RL. Neonatal mandibular distraction osteogenesis. *Semin Plast Surg* 2014;28(04):199–206
- 51 Andrews BT, Fan KL, Roostaeian J, Federico C, Bradley JP. Incidence of concomitant airway anomalies when using the university of California, Los Angeles, protocol for neonatal mandibular distraction. *Plast Reconstr Surg* 2013;131(05):1116–1123
- 52 Ramly EP, Yu JW, Eisemann BS, et al. Temporomandibular joint ankylosis in pediatric patients with craniofacial differences: causes, recurrence and clinical outcomes. *J Craniofac Surg* 2020;31(05):1343–1347
- 53 Avinoam S, Shetye PR. Craniofacial distraction: orthodontic considerations. *Clin Plast Surg* 2021;48(03):531–541
- 54 Weichman KE, Jacobs J, Patel P, et al. Early distraction for mild to moderate unilateral craniofacial microsomia: long-term follow-up, outcomes, and recommendations. *Plast Reconstr Surg* 2017;139(04):941e–953e
- 55 Flores RL, Greathouse ST, Costa M, Tahiri Y, Soleimani T, Tholpady SS. Defining failure and its predictors in mandibular distraction for Robin sequence. *J Craniomaxillofac Surg* 2015;43(08):1614–1619
- 56 Breik O, Umaphysivam K, Tivey D, Anderson P. Feeding and reflux in children after mandibular distraction osteogenesis for micrognathia: a systematic review. *Int J Pediatr Otorhinolaryngol* 2016;85:128–135
- 57 Shen C, Wang MM, Eisemann BT, Rodriguez AJ, Rickert SM, Flores RL. The surgical treatment of Robin sequence: neonatal mandibular distraction osteogenesis in the unfavorable patient. *J Craniofac Surg* 2021;32(07):2326–2329
- 58 Zhang RS, Lin LO, Hoppe IC, Bartlett SP, Taylor JA, Swanson JW. Risk factors for perioperative respiratory failure following mandibular distraction osteogenesis for micrognathia: a retrospective cohort study. *Plast Reconstr Surg* 2019;143(06):1725–1736
- 59 Cladis F, Kumar A, Grunwaldt L, Otteson T, Ford M, Losee JE. Pierre Robin Sequence: a perioperative review. *Anesth Analg* 2014;119(02):400–412
- 60 Krodel DJ, Belvis D, Suresh S. Inferior alveolar nerve blocks for postoperative pain control after mandibular distraction with osteotomies in a neonate. *Paediatr Anaesth* 2014;24(06):635–637
- 61 Ortranto de Britto Teixeira A, Almeida MAO, Almeida RDC, et al. Three-dimensional accuracy of virtual planning in orthognathic surgery. *Am J Orthod Dentofacial Orthop* 2020;158(05):674–683
- 62 Fatima A, Hackman TG, Wood JS. Cost-effectiveness analysis of virtual surgical planning in mandibular reconstruction. *Plast Reconstr Surg* 2019;143(04):1185–1194