



# Spinal Accessory Nerve to Suprascapular Nerve Transfer by Dorsal Approach for Shoulder Reanimation in Cases of Brachial Plexus Injuries: Surgical Technique

Vinita Puri<sup>1</sup>, Raghav Shrotriya<sup>1</sup>, Venkateshwaran N.<sup>1</sup>

<sup>1</sup>Department of Plastic Surgery, Seth GS Medical College and KEM Hospital, Mumbai, Maharashtra, India

**Address for correspondence** Raghav Shrotriya, MS, MCh Plastic Surgery, Department of Plastic Surgery, 2<sup>nd</sup> floor, Gynaec Block, Seth GS Medical College and KEM Hospital, Mumbai, Maharashtra, India (e-mail: dr.raghav.s@gmail.com).

Indian J Plast Surg

## Abstract

Distal nerve transfers are frequently used for the treatment of patients having brachial plexus injuries. Spinal accessory nerve to suprascapular nerve transfer by dorsal approach is advantageous since it brings the site of neurotization closer to the neuromuscular end plate and minimizes donor muscle weakness. This surgery is found to be challenging owing to the small and deep operative field. In this article, the authors describe the surgical technique for this procedure.

## Keywords

- ▶ Brachial plexus injury
- ▶ suprascapular nerve
- ▶ spinal accessory nerve
- ▶ nerve transfer
- ▶ shoulder reanimation

## Introduction

In case of brachial plexus injuries, the neurotization of injured nerves distally has been shown to have various advantages. It brings the site of neurotization close to the motor end plates of the muscles, thereby minimizing the downtime for the axons to travel and function to be achieved. Additionally, it allows us to bypass any proximal injuries to the nerve. In case of traumatic adult brachial plexus injuries, spinal accessory nerve (SAN) to suprascapular nerve (SSN) neurotization is done through dorsal approach for shoulder abduction and external rotation. This technique was first described by Guan et al in 2006<sup>1</sup> and since then it has been popularized by Bhandari et al in multiple publications (2010,<sup>2</sup> 2011,<sup>3</sup> 2013,<sup>4</sup> 2014, 2016, 2017). This neurotization is generally done by anterior approach combined along with the exploration of the plexus. In very late cases (between 9 and 12 months post-injury), neurotization by posterior approach is preferred as it ensures shorter time for neurotization. Though it is a well-established technique, it has been

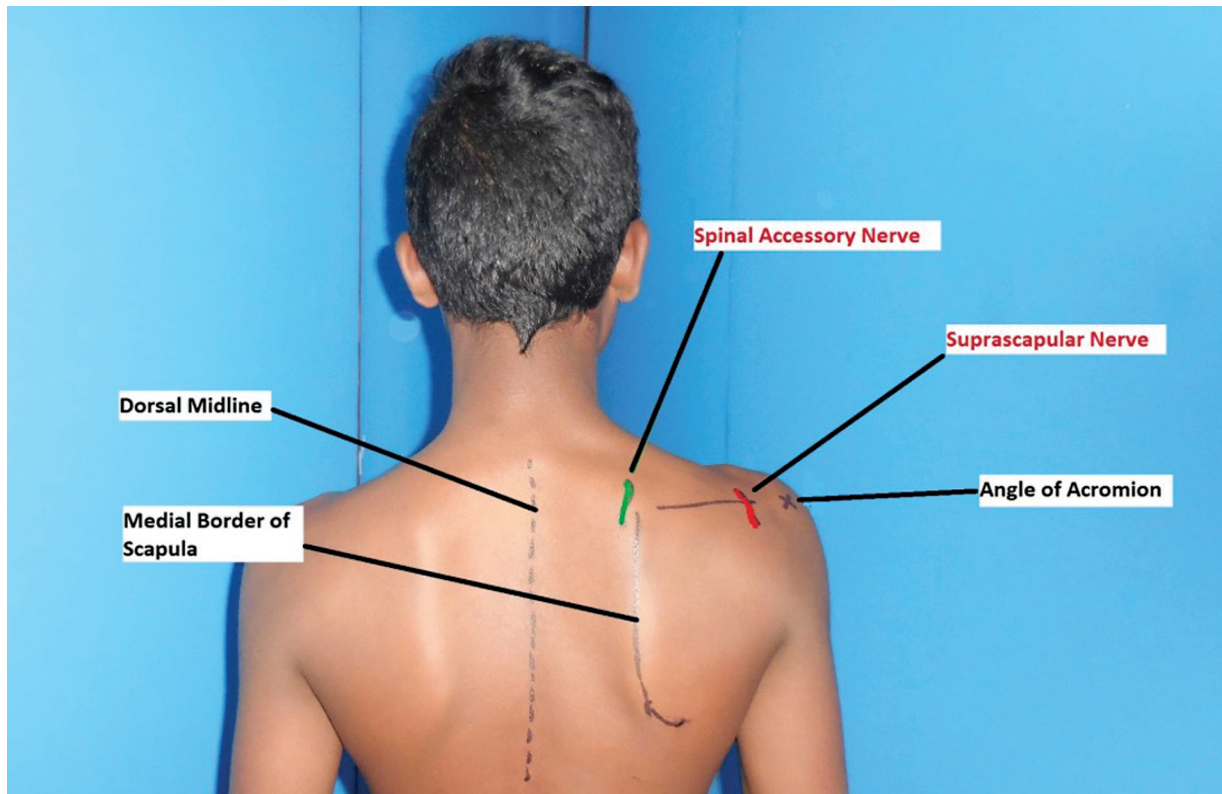
found to be used sparingly by many surgeons owing to the technical difficulties. This surgery is found to be specially challenging owing to the small and deep operative field. In this article, the authors describe the surgical technique for this procedure along with few tips and tricks that have helped the authors in making the procedure easier.

## Surgical Technique

Approximate position of nerves should be marked in standing position preoperatively as follows<sup>1</sup>- as measured from the acromion: SAN at 70% of the line joining acromion and midline of back (approximately 14–14.5 cm in most adults) and SSN: At 30% of the line joining acromion and medial border of scapula (approximately 4–4.5 cm in most adults; ▶ **Fig. 1**). This marking may be done using indelible ink or henna as used by the authors.<sup>5</sup> Place the patient in lateral position with the affected hand up. The patient is placed on the table such that the back and the head are both near the edge of the table. The preferred position is as shown in the

DOI <https://doi.org/10.1055/s-0044-1786767>.  
ISSN 0970-0358.

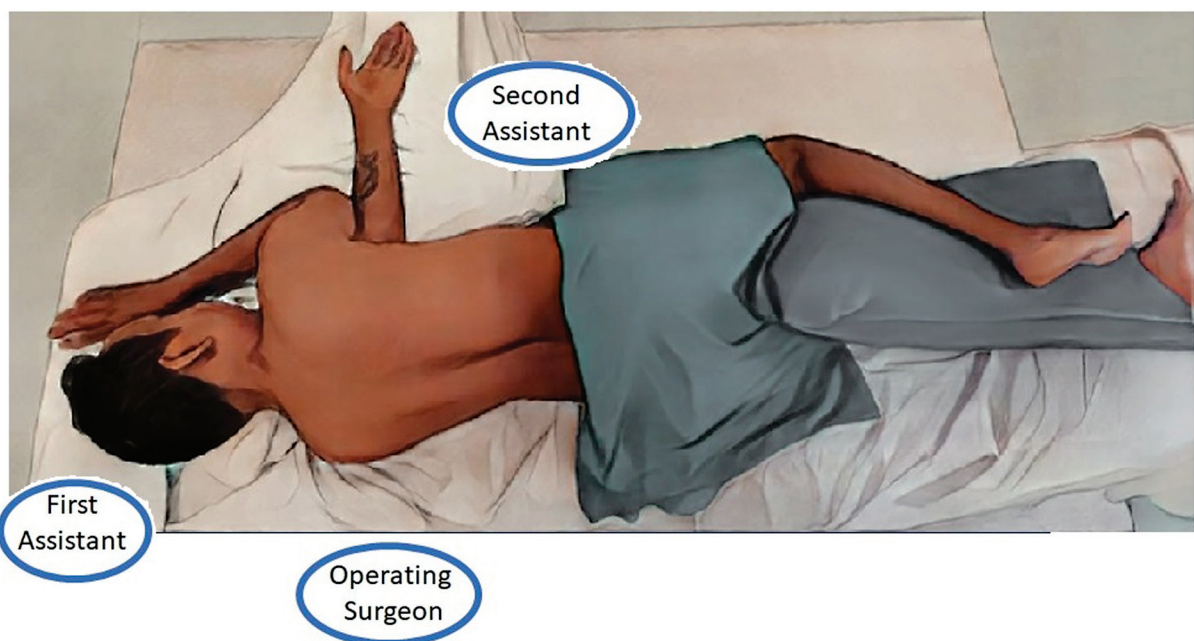
© 2024. Association of Plastic Surgeons of India. All rights reserved. This is an open access article published by Thieme under the terms of the Creative Commons Attribution-NonDerivative-NonCommercial-License, permitting copying and reproduction so long as the original work is given appropriate credit. Contents may not be used for commercial purposes, or adapted, remixed, transformed or built upon. (<https://creativecommons.org/licenses/by-nc-nd/4.0/>)  
Thieme Medical and Scientific Publishers Pvt. Ltd., A-12, 2nd Floor, Sector 2, Noida-201301 UP, India



**Fig. 1** Preoperative markings.

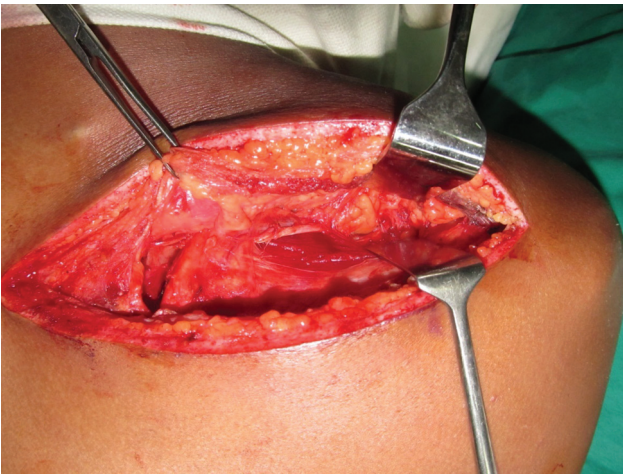
schematic (→ **Fig. 2**). The first assistant may be replaced by a self-retaining retractor, but the second assistant is essential. Whole of the upper limb and ipsilateral back is draped into the sterile field. Intravenous access may be taken in the leg. For marking the landmark tip of acromion, spine of scapula,

medial border of scapula, and midline of back are marked. Incision is marked over the spine of scapula extending medially up to 2 cm beyond the approximate marking of SAN. 1:500,000 adrenaline saline solution is infiltrated in the incision both in subcutaneous and periosteal plane.



**Fig. 2** Schematic for position of the patient on table, top view.

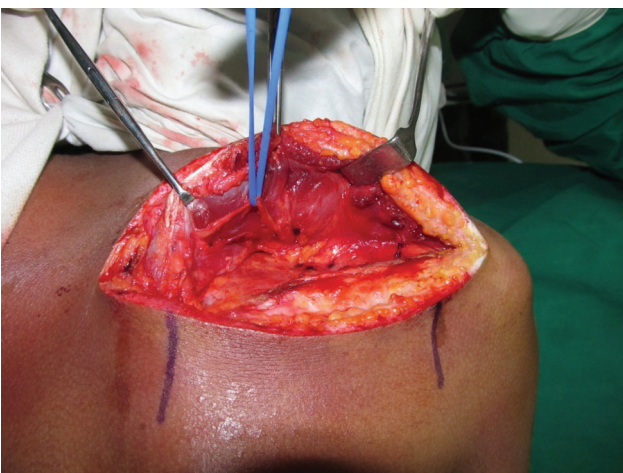




**Fig. 3** Trapezius retracted.

### Dissection of SAN

Incision is taken and deepened to reach the spine of scapula using a blade or monopolar cautery. With catspaw retractor on both edges spine of scapula is incised over and the insertion of trapezius visualized. Using the artery forceps, space is created between trapezius and supraspinatus, and trapezius is detached from its insertion on the spine. There is a well-defined plane between the trapezius and supraspinatus and if it is not developed right, we may enter the wrong plane and go deep to the supraspinatus muscle. Babcock forceps is now used to hold the free edge of the trapezius and trapezius is retracted to expose its undersurface (►Fig. 3). The incision is taken beyond the medial border of scapula. The SAN travels transversely in a lateral to medial direction and turns caudally once it crosses the scapula medially. It may thus be injured in the medial dissection if we are not careful. As the trapezius is carefully dissected just beyond the medial border of scapula, SAN is found running perpendicular to the direction of fibers of trapezius. It is looped and traced distally and proximally along its length (►Fig. 4). Some of the nerve branches need to be divided so as to allow



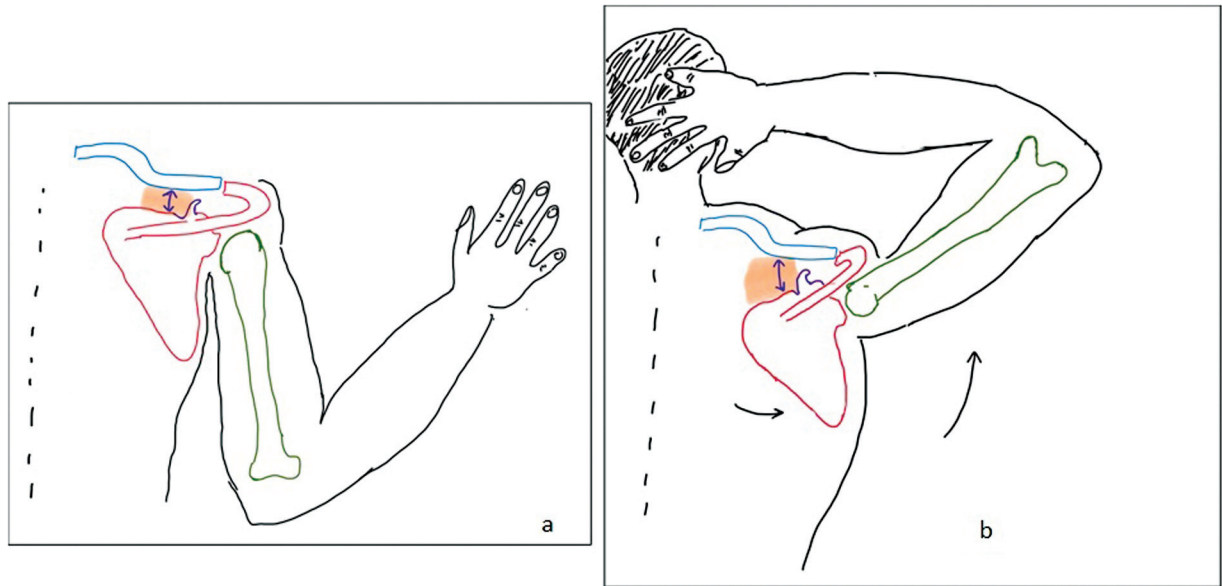
**Fig. 4** Spinal accessory nerve on the undersurface of trapezius.

the SAN to reach the suprascapular notch laterally and get a long length of donor distally. As we move laterally, the proximal part of SAN disappears into a dense fat and this marks the end point of SAN dissection. If fibrin glue is planned for use in the surgery, at this point it may be reconstituted.

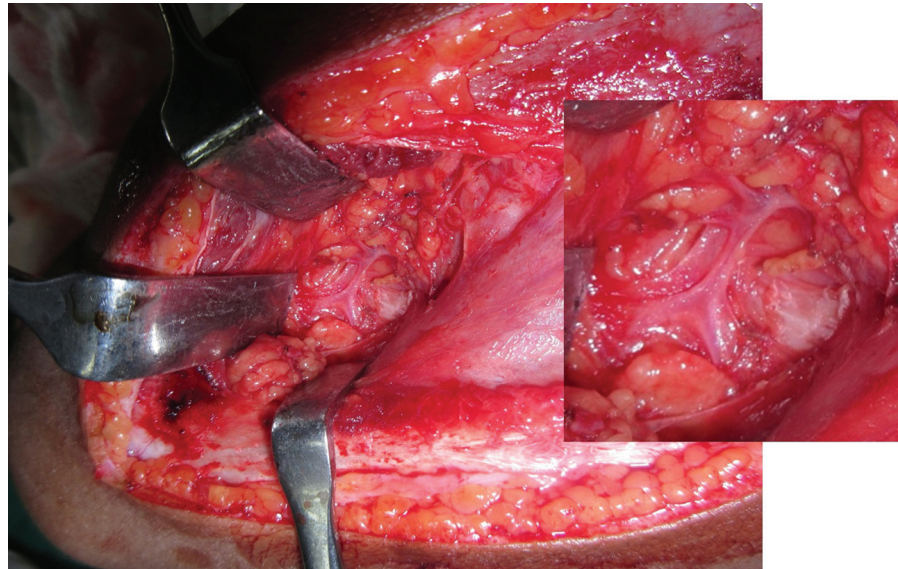
### Dissection of SSN

Once the adequate length of SAN has been dissected, the attention is turned laterally for the dissection of SSN. In the angle formed between the spine of scapula posteriorly and clavicle anteriorly, there exists a pad of fat that needs to be excised/retracted. The anterior/cranial edge of the dorsal surface of scapula is palpated using the index finger, along the supraspinatus origin and is traced laterally to reach the point where the bone turns upwards. This is the starting point of the coracoid process and the suprascapular notch lies just medial to it. Next the patient's arm is rotated upwards such that the hand is placed over the head (►Fig. 5). This simple maneuver rotates the scapula anteriorly over the chest wall, thereby opening the angle between the spine of the scapula and the clavicle. The above-mentioned maneuver can almost double the width of the working space laterally. This advantage is all the more pronounced in bulky patients. Without this maneuver, the ligament is covered by the over-hanging bulk of supraspinatus that requires more effort on the part of the assistant to retract. The step of finding suprascapular nerve has been found to be so difficult that some authors have even tried using fluoroscopic imaging for localization for the same.<sup>6</sup> By using this technique, the authors have found dissection of suprascapular nerve to be easier in more than 75 patients operated over 10 years.

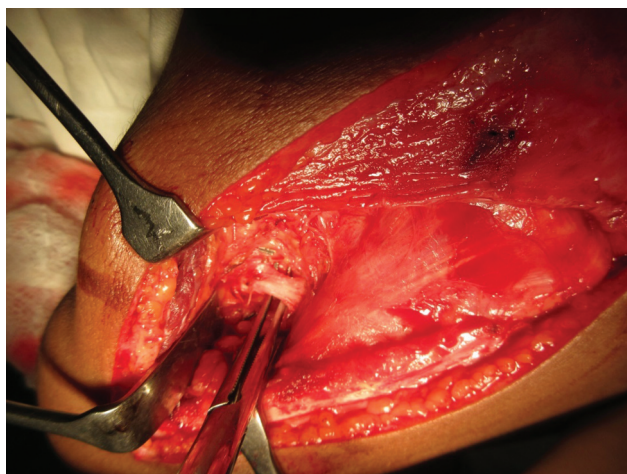
The suprascapular vessels are now identified (►Fig. 6) and clipped. Using peanut gauze pledgets, the cranial/anterior edge of the bone is exposed by multiple sweeping movements. At the starting of the coracoid process, the suprascapular ligament is identified (►Fig. 7) and divided to reveal the notch. The ligament may be "band shaped," "fan shaped,"<sup>7</sup> bipartite,<sup>8</sup> or rarely tripartite. The ligament has been occasionally found to be ossified.<sup>9</sup> A right angled Mixer forceps is put beneath the ligament and it is then divided using a fresh blade. This is done to protect the SSN that travels below the ligament. After cutting the ligament, the SSN is sometimes found to lie in the depths of the notch and the Mixer forceps is used to scoop out the fatty tissue from the depths of the notch. All the fatty tissue is then looped and gradually the fat may be dissected off to reveal the suprascapular nerve running craniocaudally (►Fig. 8). The nerve should be examined for signs of fibrosis or neuroma (►Fig. 9) that may occur due to distal traction injury. Around 1 to 1.5 cm of additional length may be achieved by dissecting toward the infraclavicular fossa. This is in conjunction with Dr. Susan Mackinnon's mantra "*Donor distal, Recipient proximal.*"<sup>10</sup> Difficulties in this part of dissection are that the working space is very small and the nerve is 6 to 7 cm from the surface. Supraspinatus muscle constantly falls over the



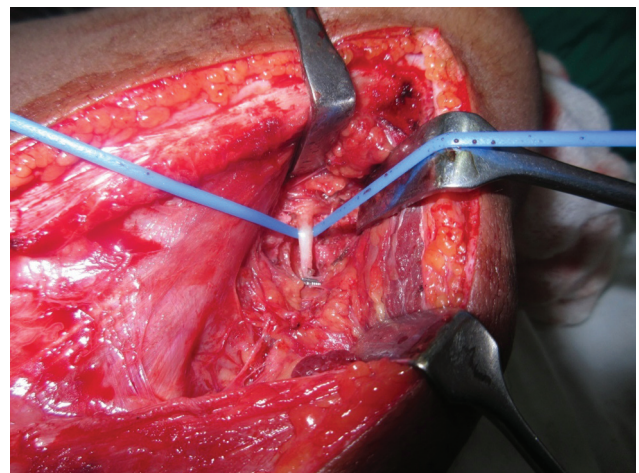
**Fig. 5** Schematic diagram showing increased ease of access to the suprascapular notch by rotating the elbow cranially.



**Fig. 6** Suprascapular artery.

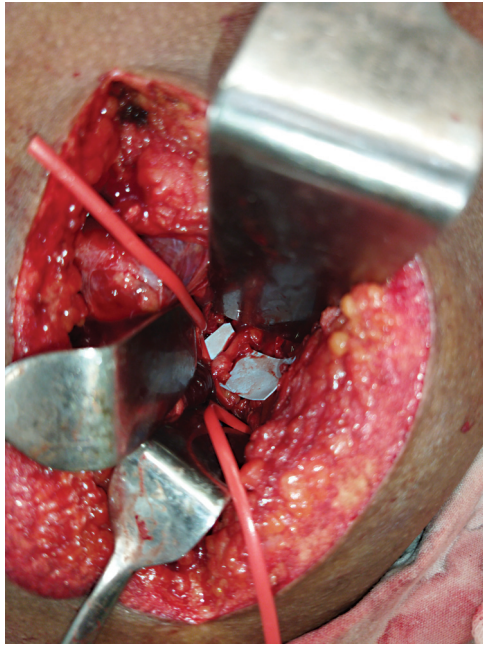

**Fig. 7** Suprascapular ligament identified.



**Fig. 8** Suprascapular nerve identified and looped.



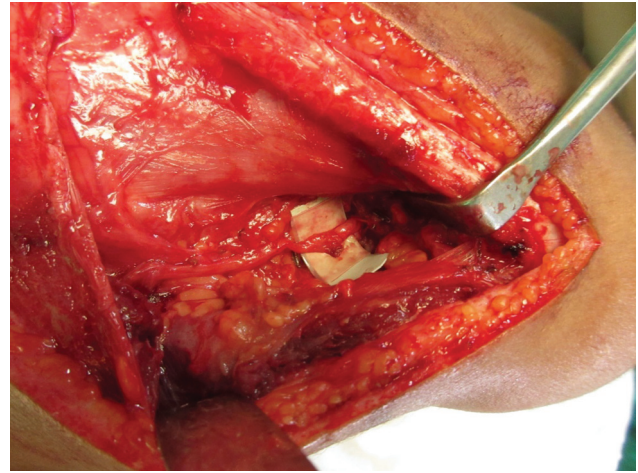


**Fig. 9** Biopsy proven suprascapular nerve neuroma identified at the suprascapular notch.

notch blocking its visualization and needs to be retracted using a long right-angled retractor placed in a slight cranial angulation by the second assistant.

## Neurotization

Now the adequacy of length of the SAN may be confirmed by mock movement using a vascular loop. The SAN is now divided distally and turned laterally to reach near the notch. Appropriate background material is now placed near the suprascapular notch and the SAN is placed over it running towards the notch. Sometimes the dissection of SSN leads to formation of dead space anteriorly so that a small tape gauze may be placed under the background for support. All preparations are made for micro-suturing or fibrin glue application prior to cutting the SSN as the SSN has a very small length available in a very small space, it is preferably not let out of the surgeon's sight. SSN is now clipped proximally and divided. The vasa nervorum of the SSN is big in size and the proximal end may retract and give rise to troublesome bleeding after division of the nerve, if it is not clipped adequately. The authors have faced severe bleeding in a patient after cutting the nerve, which was controlled with much difficulty. The SSN is larger in caliber as compared to the donor, SAN and to achieve good size match, few of the branches may be added for neurotization (►**Fig. 10**). The excess length of the SAN should only be cut after ascertaining the final length of SSN lest the donor falls short of the recipient. Nerve coaptation is now performed in a tension free manner. After that the background and gauze pieces are all removed gently, hemostasis is checked, counts are confirmed, and closure is done by suturing back the free border of trapezius first and then the skin is closed in layers. This



**Fig. 10** Spinal accessory nerve to suprascapular nerve neurotization.

surgical steps have been demonstrated in the accompanying video (►**Video 1**).

### Video 1

SAN to SSN transfer for shoulder reanimation by dorsal approach- Surgical steps. Online content including video sequences viewable at: <https://www.thieme-connect.com/products/ejournals/html/10.1055/s-0044-1786767>.

## Discussion

### Why SAN to SSN?

Suprascapular neurotization also restores external rotation that maximizes abduction by preventing the impingement of the greater tuberosity of humerus against the coracoacromial arch. In the context of a meta-analysis, Merrell et al<sup>11</sup> reported that the best nerve transfer for restoration of shoulder abduction was the spinal accessory to suprascapular nerve. Also, adequate number of fascicles are available in SSN for neurotization.<sup>12</sup>

### Why Dorsal Approach?

The major advantage is that the site of neurotization is closer to the target neuromuscular junctions and thereby shortens the time required for return of function. This is of great importance in the patients presenting very late (10–12 months). The SSN may suffer traction injury at multiple levels that is known as “double injury.”<sup>3</sup> Visualization of SSN by dorsal approach may allow identification of injury at the level of the suprascapular notch as can be ascertained by presence of a neuroma (►**Fig. 9**) or even the absence of the nerve in cases of distal avulsion injury. In such cases, neurotization done from anterior approach would have only led to wastage of a donor nerve. Post-surgery, the nerve anastomosis is stable unlike anterior approach where the anastomosis lies in the mobile neck. Distal transection of the SAN spares the important branches to trapezius and preserves its function of shoulder stabilization

and elevation, thereby minimizing the donor site morbidity.<sup>4</sup> Some authors have demonstrated slightly better results after neurotization with posterior approach as compared to the anterior approach.<sup>13,14</sup>

### Few Challenges

It requires a learning curve; especially finding SSN sometimes is a challenge. There is a need for change of position of the patient from supine to floppy lateral. The authors start with dorsal approach SAN to SSN neurotization in all cases with the loss of shoulder abduction and then the patient is made supine for brachial plexus exploration and further nerve transfers. There are scars at two sites, one anteriorly and one posteriorly. Supraspinatus muscle is little bulky and tends to fall right over the suprascapular notch. Retraction of supraspinatus by an assistant is of paramount importance to expose the ligament and thereafter, the notch. If hemostatic clip slips, the proximal part of the SSN may retract into the neck leading to troublesome bleeding from the large-sized vasa nervorum.

### Conclusion

SAN to SSN neurotization by dorsal approach is a very useful technique for shoulder reanimation in patients having nerve root avulsion injury causing loss of shoulder function. The absolute indication for this technique is the patient presenting late for surgery for shoulder reanimation (9–12 months post-injury) and relative indication is every patient who requires shoulder reanimation by SAN to SSN neurotization. In spite of all the challenges discussed above, we have seen this transfer has its specific indications and this is a useful surgery to have in the surgical armamentarium for every brachial plexus surgeon.

### Conflict of Interest

None declared.

### References

- 1 Guan SB, Hou CL, Chen DS, Gu YD. Restoration of shoulder abduction by transfer of the spinal accessory nerve to supra-

- scapular nerve through dorsal approach: a clinical study. *Chin Med J (Engl)* 2006;119(09):707–712
- 2 Bhandari PS, Sadhotra LP, Bhargava P, Singh M, et al. Dorsal approach in spinal accessory to suprascapular nerve transfer in brachial plexus injuries: technique details. *Ind J Neurotr* 2010;7(01):71–74
- 3 Bhandari PS, Deb P. Dorsal approach in transfer of the distal spinal accessory nerve into the suprascapular nerve: histomorphometric analysis and clinical results in 14 cases of upper brachial plexus injuries. *J Hand Surg Am* 2011;36(07):1182–1190
- 4 Bhandari PS, Deb P. Posterior approach for both spinal accessory nerve to suprascapular nerve and triceps branch to axillary nerve for upper plexus injuries. *J Hand Surg Am* 2013;38(01):168–172
- 5 Puri VA, Mahendru S, Rana RE. Use of henna as a skin marker. *J Plast Reconstr Aesthet Surg* 2006;59(10):1123–1124
- 6 Cabbad NC, Nuland KS, Pothula A. Intraoperative fluoroscopic imaging for suprascapular nerve localization during spinal accessory nerve to suprascapular nerve transfer. *J Hand Surg Am* 2017;42(08):668.e1–668.e5
- 7 Ticker JB, Djurasovic M, Strauch RJ, et al. The incidence of ganglion cysts and other variations in anatomy along the course of the suprascapular nerve. *J Shoulder Elbow Surg* 1998;7(05):472–478
- 8 Alon M, Weiss S, Fishel B, Dekel S. Bilateral suprascapular nerve entrapment syndrome due to an anomalous transverse scapular ligament. *Clin Orthop Relat Res* 1988;(234):31–33
- 9 Polgaj M, Sibiński M, Grzegorzewski A, Waszczykowski M, Majos A, Topol M. Morphological and radiological study of ossified superior transverse scapular ligament as potential risk factor of suprascapular nerve entrapment. *BioMed Res Int* 2014;2014:613601
- 10 Colbert SH, Mackinnon S. Posterior approach for double nerve transfer for restoration of shoulder function in upper brachial plexus palsy. *Hand (N Y)* 2006;1(02):71–77
- 11 Merrell GA, Barrie KA, Katz DL, Wolfe SW. Results of nerve transfer techniques for restoration of shoulder and elbow function in the context of a meta-analysis of the English literature. *J Hand Surg Am* 2001;26(02):303–314
- 12 Chuang DC, Lee GW, Hashem F, Wei FC. Restoration of shoulder abduction by nerve transfer in avulsed brachial plexus injury: evaluation of 99 patients with various nerve transfers. *Plast Reconstr Surg* 1995;96(01):122–128
- 13 Tahir H, Osama M, Beg MSA, Ahmed M. Comparison of anterior vs. dorsal approach for spinal accessory to suprascapular nerve transfer in patients with a brachial plexus injury and its outcome on shoulder function. *Cureus* 2022;14(07):e26543
- 14 Jimulia DT, Duraku LS, Parekh JN, George S, Chaudhry T, Power DM. The clinical outcomes of spinal accessory to suprascapular nerve transfer through a posterior approach. *Hand (N Y)* 2023;0(00):15589447231199797