



Ewing Sarcoma of Kidney: A Rare Entity

Vibha Aithal A.¹ Sajitha K.¹ Michelle Mathias¹

¹Department of Pathology, K S Hegde Medical Academy, Mangaluru, Karnataka, India

Address for correspondence Vibha Aithal A., MBBS, MD (Pathology), Assistant Professor, Department of Pathology, K S Hegde Medical Academy, Deralakatte, Mangaluru, Karnataka 575018, India (e-mail: vibha2aithal@gmail.com).

J Health Allied Sci^{NU} 2024;14(Suppl S1):S144–S146.

Abstract

Primary renal origin of Ewing sarcoma/PNET (primitive neuroectodermal tumor) is a rare entity in the adult population and has an aggressive outcome. The entity was first coined by Arthur Purdy stout in 1918 and recognized under family of small round cell tumor. Radiologically it is difficult to distinguish from primary clear cell carcinoma of kidney from Ewing/PNET. Diagnosis of this requires histopathology, immunohistochemistry (IHC), and cytogenetics studies.

A 40-year-old female presented with hematuria and radiology found a mass lower pole of left kidney with extension into renal hilum. Nephrectomy was done for the case and the histopathology diagnosis of small round cell tumor of left kidney was given. Followed by IHC, diagnosis of malignant round cell tumor was suggestive of Ewing sarcoma.

Microscopy showed cells with small, round, hyperchromatic nuclei, scant cytoplasm, and inconspicuous nucleoli. Increased mitosis was noted (15/10 high power field). Multiple foci of pseudorosettes, areas of hemorrhage, and necrosis lymphovascular emboli were seen.

IHC done outside showed NKX 2-2, synaptophysin positivity, CD99 diffuse membranous positivity, cytokeratin perinuclear dot like positivity, and negative for CD20, CD3, desmin, CD34, S100, and Pax8. Impression of malignant round cell tumor was suggestive of Ewing sarcoma.

Keywords

- ▶ Ewing sarcoma
- ▶ small round blue cell tumor
- ▶ hematuria

Ewing sarcoma is one of the rare yet highly aggressive tumors. This should be kept as differential diagnosis in young adults with renal mass, as on radiologically it cannot be differentiated from renal cell carcinoma. Diagnosis of Ewing sarcoma is done using histopathology, IHC, and cytogenetic study. Early diagnosis helps in initiation of surgery, chemotherapy, and radiotherapy and helps in increasing the survival rate.

Introduction

Ewing sarcoma is highly malignant tumor of bone mostly seen in children and young adults.¹

Nearly 6% of cases are extraosseous. Trunk, extremities, head and neck, and retroperitoneum are the most common extraosseous site.²

Primary renal origin of Ewing sarcoma is a rare entity in the adult population and has an aggressive outcome. It arises from neural and neural crest cells. Now Ewing sarcoma and primitive neuroectodermal tumor (PNET) are considered same as they have similar chromosomal translocation and immunohistochemical (IHC) characteristics.^{3,4}

article published online
June 7, 2024

DOI <https://doi.org/10.1055/s-0044-1786993>.
ISSN 2582-4287.

© 2024. The Author(s).

This is an open access article published by Thieme under the terms of the Creative Commons Attribution License, permitting unrestricted use, distribution, and reproduction so long as the original work is properly cited. (<https://creativecommons.org/licenses/by/4.0/>)

Thieme Medical and Scientific Publishers Pvt. Ltd., A-12, 2nd Floor, Sector 2, Noida-201301 UP, India

Radiologically, it is indistinguishable from renal cell carcinoma. Definitive diagnosis depends on histopathology, IHC and cytogenetic studies.⁵

Case Report

A 40-year-old female presented with a history of painless hematuria of 1 month duration.

The complete blood count showed mild anemia. Urine analysis was positive for red blood cells. Blood urea was 21 mg/dL, creatinine was 1.1 mg/dL, and uric acid was 2.0 mg/dL.

Radiological image (magnetic resonance imaging abdomen and pelvis) showed an enhancing lesion in the lower pole of left kidney with extension into renal hilum, showing diffusion restriction and left renal vein thrombosis. Imaging features were highly suggestive of malignant neoplasm, probably renal cell carcinoma.

Contrast-enhanced computed tomography abdomen showed heterogenous enhancing partially exophytic lesion noted in mid and lower pole of left kidney, few necrotic areas seen in the inferior portion of the lesion. 2 × 1.1 cm and 1.1 × 1 cm filling defect in left renal vein noted that was consistent with tumor thrombosis.

Left radical nephrectomy was done and grossly outer surface of kidney capsule can be stripped, and a mass was noted in the middle and lower pole of which was lobulated, soft in consistency with areas of hemorrhage. Tumor was seen infiltrating into the proximal part of renal vein. Cut surface of the kidney showed pale, white, fleshy, infiltrating mass noted in the middle and lower pole measuring 7 × 5.5 × 5 cm, and cystic, hemorrhagic, and necrotic areas were noted (→ Fig. 1).

Microscopy showed tumor cells arranged in sheets and at places lobular pattern. These tumor cells are small, round, hyperchromatic nuclei, scant cytoplasm, and inconspicuous nucleoli. Increased mitosis was noted (15/10 high-power field). Multiple foci of pseudorosettes was noted. Areas of hemorrhage and necrosis (30%) were noted. Lymphovascular

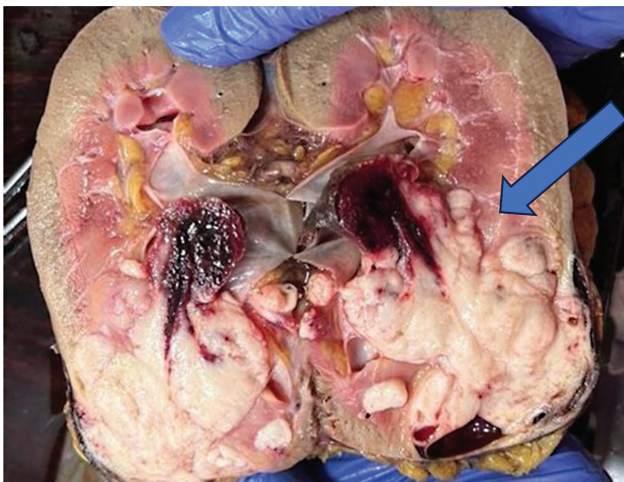


Fig. 1 Cut surface of the kidney showing pale, white, fleshy, infiltrating mass (blue arrow) noted in the middle and lower pole with cystic, hemorrhagic and necrotic areas.

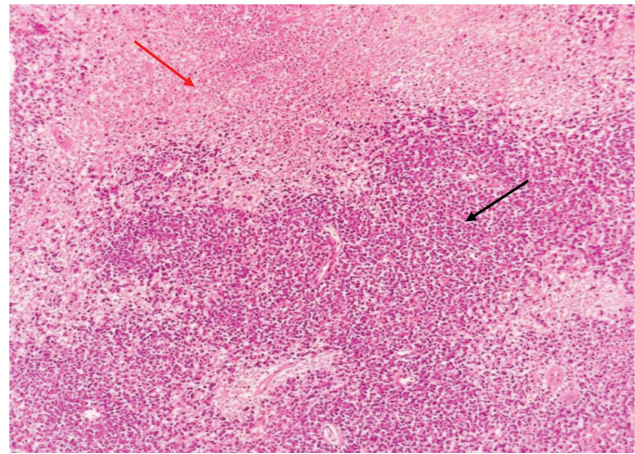


Fig. 2 (Hematoxylin and eosin, 10X) Areas of necrosis (red arrow) along with tumor cells (black arrow).

emboli was seen. These tumor cells were seen infiltrating into the renal sinus fat, perinephric fat and proximal end of renal vein (→ Figs. 2 and 3).

And the diagnosis of small round cell tumor of left kidney was given.

IHC done outside showed NKX 2-2 positivity (→ Fig. 4), synaptophysin positivity, CD99 diffuse membranous positivity (→ Fig. 5), cytokeratin (CK) perinuclear dot like positivity, and negative for CD20, CD3, desmin, CD34, S100, and Pax8. Impression of Ewing sarcoma (malignant round cell tumor) was given. And EWSR1 rearrangement studies has been advised.

Discussion

Ewing sarcoma (PNET) of kidney is extremely rare and highly aggressive tumor in adolescents and young adults and has an aggressive behavior. The entity was first coined by Arthur Purdy Stout in 1918 and recognized under family of small round cell tumor.⁶

Average age at diagnosis was 24.9 years.⁷ Our case was diagnosed at an age of 40 years.

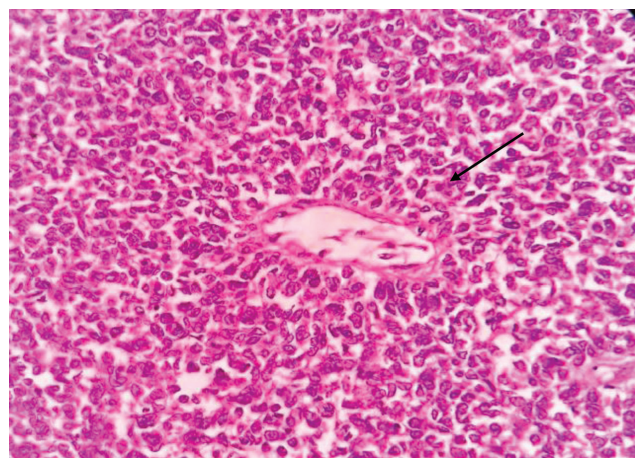


Fig. 3 (Hematoxylin and eosin, 40X) Homer Wright rosettes (black arrow) with small round monomorphic tumor cells.

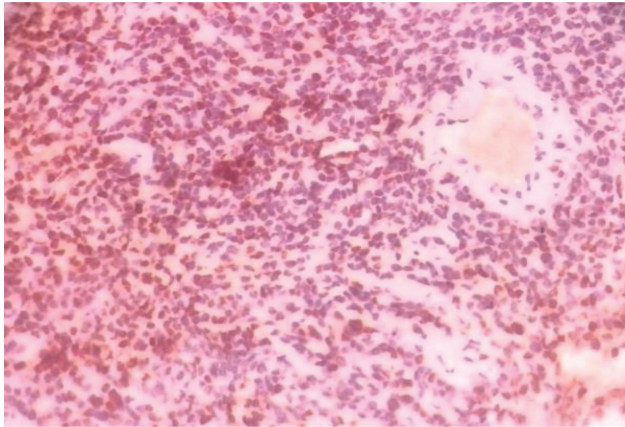


Fig. 4 (NKX2-2, 40X) Immunohistochemistry for NKX2-2 tumor cells showing strong nuclear staining.

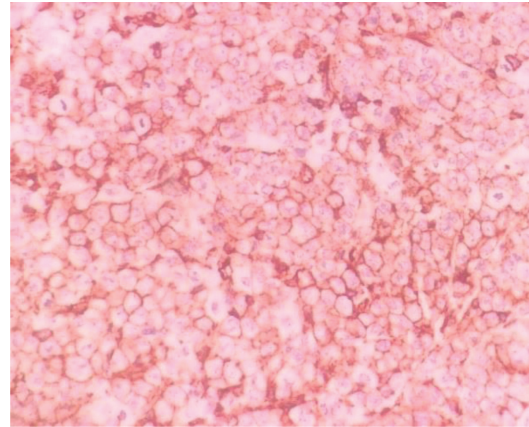


Fig. 5 (CD99, 40X) Immunohistochemistry for CD99 tumor cells showing strong diffuse membranous staining.

Patients usually present with flank pain, hematuria, and urinary tract infections-related symptoms. In this case, patient presented with hematuria only.^{7,8} These highly aggressive tumor invades into the renal collecting system leading to hematuria. About 66% of patients presents with distant metastasis at the time of presentation and the most common site of metastasis are lungs followed by liver and bone.

There are no specific findings on radiological imaging for primary Ewing sarcoma.

Histopathology, IHC and cytogenetic study are necessary for the diagnosis. Wilms tumor, neuroblastoma, clear cell sarcoma of kidney, lymphoma and Ewing sarcoma, rhabdomyosarcoma, small cell variant of osteosarcoma, desmoplastic small round cell tumor, small cell anaplastic neuroendocrine carcinoma, and nephroblastoma are included in differential diagnosis of small round blue cell tumor.⁹

However, histopathological findings along with IHC give definitive diagnosis.

Histopathological findings show small round monomorphic cells with Homer Wright rosettes and IHC is strongly positive for CD99 and FLI-1. IHC panel of CK, epithelial membrane antigen, WT1, synaptophysin, muscle-specific antigen, desmin, myogenin, CD45, and Leukocyte common antigen (LCA) are needed to rule out other small round cell tumors.

Fusion of EWS/FLI-1 gene causes translocation of t(11:22)(q24;q12) that is the gold standard for diagnosis.¹⁰

Our case was given first cycle of chemotherapy with vincristine, Adriamycin, filgrastim, and cyclophosphamide.

Nephrectomy is considered principal line of management for Ewing sarcoma/PNET, followed by effective chemotherapy with vincristine, doxorubicin, ifosfamide, etoposide, actinomycin D, and cyclophosphamide.

Combination of surgical excision, chemotherapy and radiotherapy is used for treatment.

The prognosis remains poor and overall 5 years survival rates have been reported due to aggressive nature of tumor.¹⁰

Conclusion

Ewing sarcoma is one of the rare yet highly aggressive tumor. This should be kept as differential diagnosis in young adults with renal mass, as on radiologically it cannot be differentiated from renal cell carcinoma. Diagnosis of Ewing sarcoma is done using histopathology, IHC, and cytogenetic study. Early diagnosis helps in initiation of surgery, chemotherapy, and radiotherapy and helps in increasing the survival rate. However, the prognosis remains poor.

Conflict of Interest

None declared.

References

- 1 Choubey SK, Pipara G, Kumar A. Ewings sarcoma of the kidney: a rare entity. *World J Nephrol Urol* 2017;6(1-2):18-20
- 2 Mukkunda R, Venkitaraman R, Thway K, et al. Primary adult renal Ewing's sarcoma: a rare entity. *Sarcoma* 2009;2009:504654
- 3 Saikawa S, Taga M, Matsuda Y, et al. Primary Ewing's sarcoma/primitive neuroectodermal tumor of the kidney and its clinical features. *IJU Case Rep* 2022;5(05):330-333
- 4 Chatterjee S, Kumar K, Mondal S, Maiti K, Pal DK. Primary Ewing's sarcoma of the kidney: a diagnostic and therapeutic challenge. *Ind J Case Reports* 2020;6:62-63
- 5 Choudhury AR, Jain SG, Reghunath A, Ghasi RG, Kaur N, Kolte S. Primary Ewing's sarcoma of the kidney: a rare masquerader of renal cell carcinoma on imaging. *Egypt J Radiol Nucl Med* 2022;53(01):1-6
- 6 Patel SS, Patel K, Bandi A. Primary Ewing sarcoma of the kidney: case report and review of the literature. *J Oncol* 2022;2(02):1047
- 7 Zöllner S, Dirksen U, Jürgens H, Ranft A. Renal Ewing tumors. *Ann Oncol* 2013;24(09):2455-2461
- 8 Sadiq M, Ahmad I, Shuja J, Ahmad K. Primary Ewing sarcoma of the kidney: a case report and treatment review. *CEN Case Rep* 2017;6(02):132-135
- 9 Doroudinia A, Ahmadi S, Mehrian P, Pourabdollah M. Primary Ewing sarcoma of the kidney. *BMJ Case Rep* 2019;12(01):bcr-2018
- 10 Saxena R, Sait S, Mhaweck-Fauceglia P. Ewing sarcoma/primitive neuroectodermal tumor of the kidney: a case report. Diagnosed by immunohistochemistry and molecular analysis. *Ann Diagn Pathol* 2006;10(06):363-366