



Successful Reablation Hemostasis for Needle Tract Bleeding Following Colorectal Liver Metastasis Percutaneous Microwave Ablation: A Case Report

Thanakorn Phothong^{1,2} Phurich Janjindamai¹ Keerati Hongsakul¹
Supparerk Laohawiriyakamol³

¹ Division of Body Interventional Radiology, Department of Radiology, Faculty of Medicine, Prince of Songkla University, Hat Yai, Songkhla, Thailand

² Department of Radiology, Sunpasitthiprasong Hospital, Ubon Ratchathani, Thailand

³ Department of Surgery, Faculty of Medicine, Prince of Songkla University, Hat Yat, Songkhla, Thailand

Address for correspondence Thanakorn Phothong, MD, Division of Body Interventional Radiology, Department of Radiology, Faculty of Medicine, Prince of Songkla University, Hat Yai, Songkhla 90110, Thailand (e-mail: Thanakornphothong@gmail.com).

J Clin Interv Radiol ISVIR

Abstract

Percutaneous ablation is a well-established alternative treatment for colorectal liver metastasis. Major complications after percutaneous ablation are less common but can occur. Few intervention options for immediate hemostasis after percutaneous ablation have been described, with most involving embolization or surgery. Recently, a few reports have shown good results of percutaneous heat ablation for hemostasis in needle tract bleeding. We report a case involving a 78-year-old woman who developed needle tract bleeding immediately after percutaneous microwave ablation for colorectal liver metastasis. The bleeding was successfully controlled using a reablation technique.

Keyword

- ▶ needle tract bleeding
- ▶ colorectal liver metastasis
- ▶ reablation hemostasis

Introduction

Colorectal cancer is the fourth most common cancer globally, often leading to liver metastasis.¹ Surgery is the gold standard for treating colorectal liver metastasis (CRLM), yet only one-third of patients are candidates.¹ Percutaneous ablation is an alternative for treating unresectable CRLM, providing comparable outcomes for treating small lesions.¹ In 0.5 to 1.5% of cases, intra-abdominal bleeding may occur during liver tumor ablation, controllable through several options.² Heat ablation needles are increasingly used to control bleeding, including needle tract bleeding after percutaneous ablation.²

Case Report

We report a 78-year-old woman, postright hemicolectomy for colonic carcinoma (TNM stage pT3N1aM0) with free surgical margins. She had multiple comorbidities: hypertension, dyslipidemia, chronic pulmonary embolism on enoxaparin, ischemic heart disease managed with aspirin, nonvalvular atrial fibrillation, postsurgery pituitary macroadenoma, chronic cholecystitis, and a history of passing a bile duct stone. Postoperatively, serum carcinoembryonic antigen level was elevated and magnetic resonance imaging (MRI) revealed four liver metastases (segment 8/5 junction: 2.2 cm, segment 5: 1.6 cm, segment 7: 1.0 cm, segment 8:

DOI <https://doi.org/10.1055/s-0044-1787004>.
ISSN 2457-0214.

© 2024. The Author(s).

This is an open access article published by Thieme under the terms of the Creative Commons Attribution License, permitting unrestricted use, distribution, and reproduction so long as the original work is properly cited. (<https://creativecommons.org/licenses/by/4.0/>)
Thieme Medical and Scientific Publishers Pvt. Ltd., A-12, 2nd Floor, Sector 2, Noida-201301 UP, India

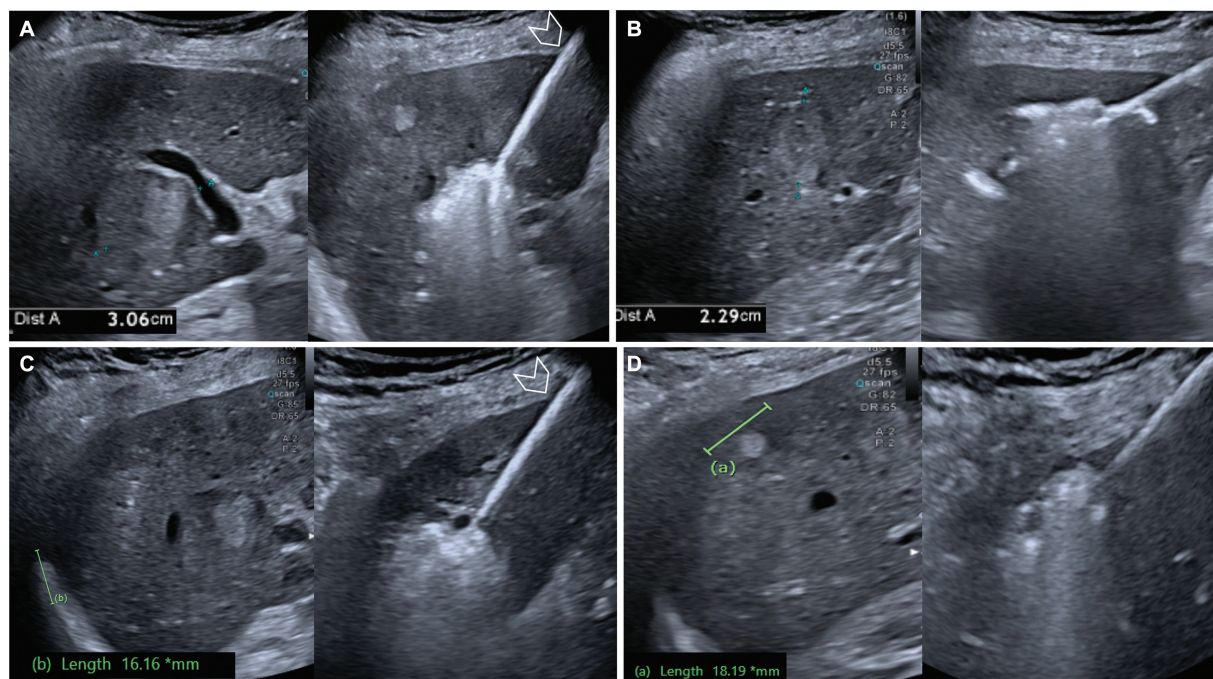


Fig. 1 Intraprocedural ultrasound images and subsequent ablation: (A) the segment 8/5 junction lesion and first liver capsular puncture site (arrowhead), (B) the segment 5 lesion, (C) the segment 7 lesion and second liver capsular puncture site (arrowhead), and (D) the segment 8 lesion.

1.5 cm). Surgical resection was unfeasible due to comorbidities, leading to scheduled percutaneous liver ablation. Pre-procedure laboratory tests were within normal limits, including platelet count and coagulation function. Aspirin and enoxaparin were withheld appropriately.

Periprocedure liver ultrasound revealed a slight enlargement in the size of four masses up to 3.1 cm (►Fig. 1). Using a 13G × 15 cm microwave ablation (MWA) needle (The Emprint Ablation System, Covidien, Boulder, Colorado, United States), lesions were targeted via two capsular punctures under local anesthesia. Sedation drugs were administered after placing the ablation needle in the first lesion. Sequential ablation included segment 8/5 (75W × 5 minutes and 100W × 3.5 minutes overlapping), segment 5 (100W × 3.5 minutes), segment 7 (75W × 4 minutes), and segment 8 (75W × 3.5 minutes) (►Fig. 1). Tract cauterization was performed on the first puncture tract before introducing the needle into the second puncture tract. Another tract cauterization was performed at the second puncture tract at the end of the procedure. Immediately postprocedure (just after removing the ablative needle), ultrasound showed rapid development of fluid in the hepatorenal and right perihepatic region. Active Doppler color extravasation from the second puncture tract was found, with pulsations on spectral waveform analysis. At that time, the patient remained sedated with stable vital signs. The same ablation needle was reinserted 1.5 cm beyond the liver capsular outline into the bleeding tract. Reablation was initiated with 70W for 5 minutes. Subsequent ultrasound no longer showed any active bleeding (►Fig. 2). Additional external

compression was applied for 5 minutes, followed by placement of a sandbag over the puncture site for 6 hours. Post-procedure computed tomography angiography abdomen on the same day showed a good ablation zone and no evidence of active contrast extravasation or gross major vascular injury either on arterial or portal phase (►Fig. 3).

The patient was admitted for 3 days due to a postprocedure drop in hematocrit from 31.5 to 25.5%, requiring a blood transfusion. Despite this, the overall clinical condition remained stable, allowing for discharge. The follow-up MRI at 1 month later showed a well-covered ablation zone over the target tumors with complete resolution of the perihepatic hematoma.

Discussion

Intra-abdominal hemorrhage after liver tumor ablation is rare.^{2,3} Limited reports exist on using percutaneous heat ablation for needle tract bleeding.^{2,4,5} Options for immediate bleeding management include external compression for 5 minutes (54% success) and transvascular embolization (100% effective with a median waiting time to angiogram of 22 hours).^{2,3} Few reports show 100% effective control of tract bleeding with heat ablation, despite abnormal coagulation function, mostly performed under ultrasound guidance.^{2,4} The target site is active bleeding that can be seen on color Doppler or contrast-enhanced ultrasound.^{2,4} The ablative needle is inserted into the outer parts of the bleeding tract to stop bleeding and minimize parenchymal injury.² Although no standard ablative protocol exists, the principle

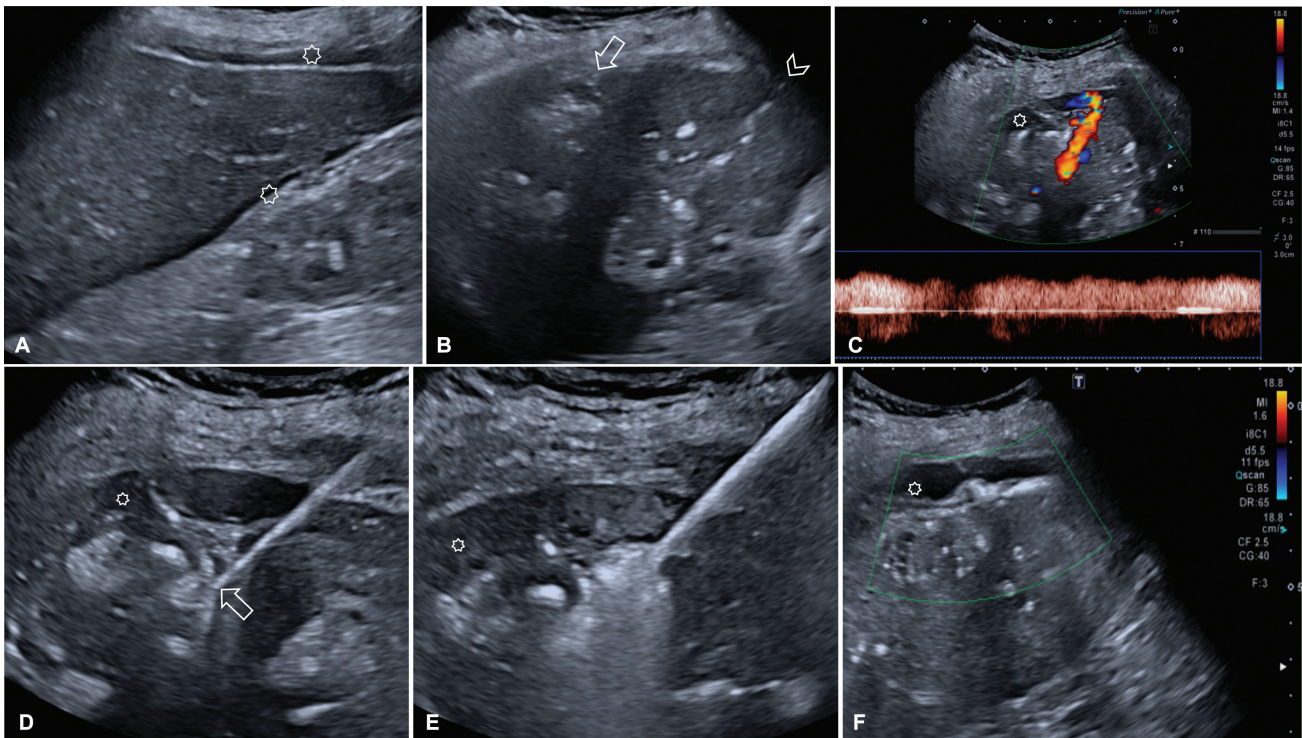


Fig. 2 Images during ablation of bleeding needle tract. (A) Newly detected hepatorenal and perihepatic fluid (asterisk) after the removal of the microwave ablation (MWA) needle from the second puncture liver tract. (B) First (arrowhead) and second (arrow) sites of puncture of the liver capsule. (C) Color Doppler shows active extravasation from the second puncture liver tract with pulsation on spectral analysis. (D) Reinsertion of the MWA needle was done into the bleeding site and the needle tip is visualized (arrow). (E) After starting reablation of the bleeding tract. (F) No extravasation was detected on color Doppler after complete bleeding tract ablation.

involves delivering sufficient energy to overcome the heat sink effect at the active bleeding site and stop the bleeding. Suggested settings for radiofrequency ablation include using power at 100W or higher for 3 to 5 minutes while maintaining continuous cooling pump operation.² For MWA, the reported protocol uses 50 to 100W for 5 to 8 minutes.^{4,5} The endpoint is the disappearance of active bleeding.^{2,5} Reevaluation should be conducted after an additional 5 to 10 minutes wait to avoid gas obscuration.⁵ Further contrast

media study may be needed to confirm successful hemostasis. No major complications after tract reablation have been reported such as new intraperitoneal bleeding, bile duct injury, liver abscess, or nearby organ injury.^{2,4,5}

Conclusion

Reablation under ultrasound promptly stops active needle tract bleeding without extra tool preparation, proving effective.

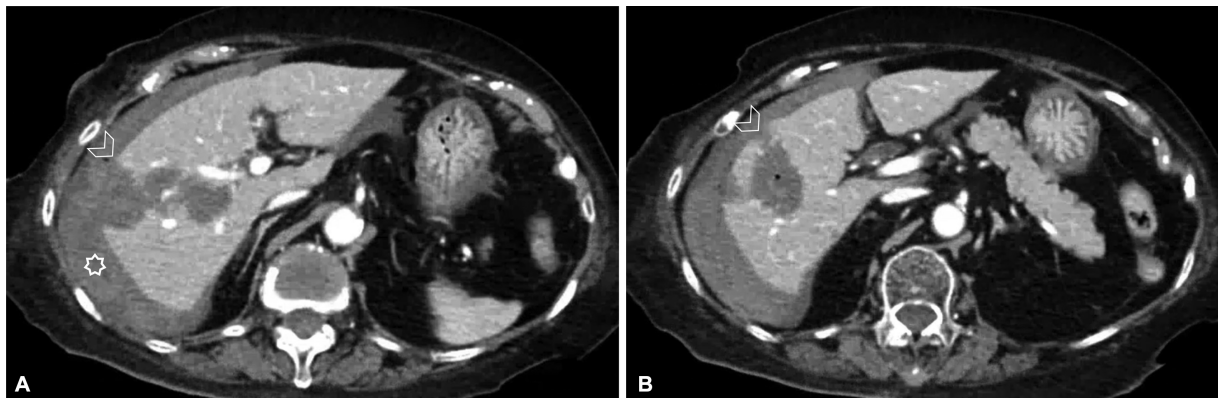


Fig. 3 Computed tomography angiography (CTA) abdomen immediately after completing the procedure shows perihepatic hematoma and post-liver ablation changes. (A) Second liver capsule puncture site (arrowhead) after reablation without residual active bleeding with perihepatic hematoma (asterisk) and (B) first liver capsule puncture site (arrowhead).

Conflict of interest

None declared.

References

- 1 Lin YM, Paolucci I, Brock KK, Odisio BC. Image-guided ablation for colorectal liver metastasis: principles, current evidence, and the path forward. *Cancers (Basel)* 2021;13(16):3926
- 2 Song KD, Lee MW, Rhim H, Kang TW. Hemostasis using re-radiofrequency ablation for hepatic tract bleeding after ultrasound-guided percutaneous radiofrequency ablation of hepatic tumors. *Br J Radiol* 2021;94(1128):20210353
- 3 Kim JW, Shin JH, Kim PN, et al. Embolization for bleeding after hepatic radiofrequency ablation. *J Vasc Interv Radiol* 2017;28(03):356–365.e2
- 4 Guo J, Tian G, Zhao Q, Jiang T. Fast hemostasis: a win-win strategy for ultrasound and microwave ablation. *OncoTargets Ther* 2018; 11:1395–1402
- 5 Jiang T, Kelekis A, Zhao Q, et al. Safety and efficacy of percutaneous microwave ablation for post-procedural haemostasis: a bi-central retrospective study focusing on safety and efficacy. *Br J Radiol* 2020;93(1106):20190615