




A Case of Cerebral Infarction due to Internal Carotid Artery Occlusion Accompanied by Persistent Primitive Trigeminal Artery

Hiroyuki Abe^{1,3} Kentaro Mori¹ Issei Fukui¹ Akira Tamase¹ Ryotaro Yamashita² Mutsuki Takeda²
Tatsu Nakano² Motohiro Nomura¹  Tetsuya Yamamoto³

¹Department of Neurosurgery, Yokohama Sakae Kyosai Hospital, Yokohama, Kanagawa, Japan

²Department of Neurology, Yokohama Sakae Kyosai Hospital, Yokohama, Kanagawa, Japan

³Department of Neurosurgery, Yokohama City University School of Medicine, Yokohama, Kanagawa, Japan

Address for correspondence Motohiro Nomura, MD, PhD, Department of Neurosurgery, Yokohama Sakae Kyosai Hospital, 132 Katsura-cho, Sakae-ku, Yokohama 247-8581, Japan (e-mail: nomura413jp@yahoo.co.jp).

Asian J Neurosurg 2024;19:174–178.

Abstract

An 85-year-old woman with a history of diabetes mellitus became aware of motor weakness of the left lower extremity. Magnetic resonance imaging showed multiple small cerebral infarctions in the right corona radiata. Angiography revealed persistent primitive trigeminal artery (PPTA) originating from the right internal carotid artery (ICA) and connecting to basilar artery, and the right ICA occluded distal to PPTA. Collateral blood circulation had developed, and sufficient collateral blood flow was expected. From these findings, the right ICA was considered to show stenosis due to atherosclerotic changes before occlusion. Conservative treatment was conducted with the transoral administration of rivaroxaban. It is important to correctly diagnose the anatomy and existence of an anomalous vessel in a stroke patient, not only when endovascular treatment is planned, but also for conservative medical treatment. Rapid and accurate radiological examinations facilitate safe and effective treatment.

Keywords

- ▶ persistent primitive trigeminal artery
- ▶ internal carotid artery
- ▶ occlusion
- ▶ cerebral infarction

Introduction

Primitive vascular anastomoses exist early in embryonic development between the primitive internal carotid artery (ICA), and dorsal aorta and future vertebrobasilar artery. At the 4-mm embryonic stage, the primitive trigeminal artery branches from the primitive ICA and anastomoses with the longitudinal neural artery.¹ The primitive vascular anastomosis regresses in about 1 week with the development of the posterior communicating artery and vertebral artery, but remnants are occasionally found in adults. The persistent primitive trigeminal

artery (PPTA) is the most common residual primitive vessel anastomosis, occurring in 0.5 to 0.7%.^{2,3} It has been reported that PPTA originates from the cavernous or precavernous portion of ICA and anastomoses to the distal one-third of the basilar artery (BA) between the superior cerebellar artery and anterior inferior cerebellar artery.^{4–6}

Cases with cerebral infarction due to ICA occlusion accompanied by PPTA are rare. It is important to recognize the exact vascular anatomy including an anomalous vessel in a stroke patient, not only when endovascular treatment is planned, but also for conservative medical treatment. In this report, we

article published online
June 5, 2024

DOI <https://doi.org/10.1055/s-0044-1787085>.
ISSN 2248-9614.

© 2024. Asian Congress of Neurological Surgeons. All rights reserved.

This is an open access article published by Thieme under the terms of the Creative Commons Attribution-NonDerivative-NonCommercial-License, permitting copying and reproduction so long as the original work is given appropriate credit. Contents may not be used for commercial purposes, or adapted, remixed, transformed or built upon. (<https://creativecommons.org/licenses/by-nc-nd/4.0/>)

Thieme Medical and Scientific Publishers Pvt. Ltd., A-12, 2nd Floor, Sector 2, Noida-201301 UP, India

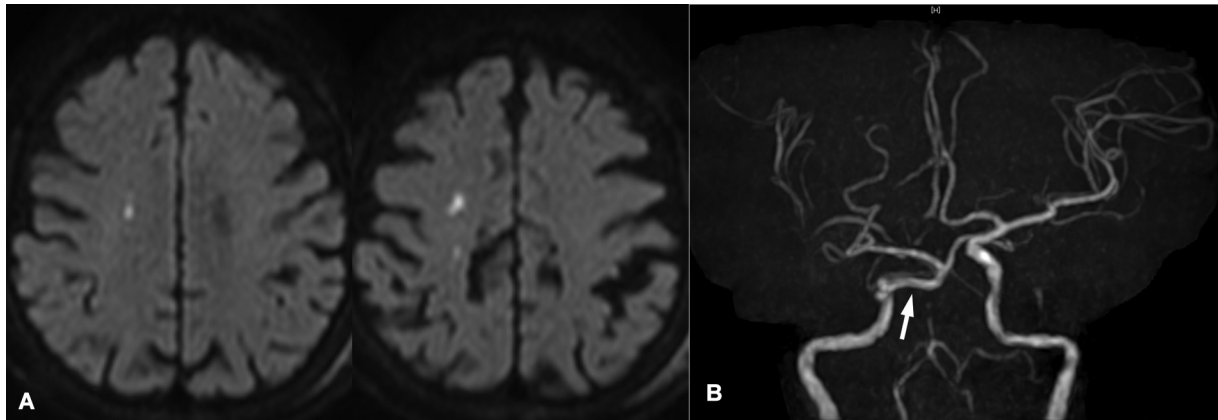


Fig. 1 (A) Diffusion-weighted imaging of magnetic resonance imaging showing multiple cerebral infarctions in the right corona radiata. (B) Magnetic resonance angiography showing persistent primitive trigeminal artery (PPTA; arrow) and internal carotid artery occlusion distal to PPTA on the right side.

present a patient with PPTA who showed cerebral infarction due to ICA occlusion distal to the PPTA origin, and discuss the anatomy, etiology, and management of such cases.

Case Presentation

An 85-year-old woman with a history of diabetes mellitus became aware of motor weakness of the left lower extremity. Three days later, she became unable to walk. Six days after onset, she developed left hemiparesis, and was transported to our hospital. The National Institutes of Health Stroke Scale was 8/42. An electrocardiogram showed atrial fibrillation (AF). Diffusion-weighted imaging of magnetic resonance imaging (MRI) showed multiple small high-intensity spots in the right corona radiata, suggesting cerebral infarctions due to hemodynamic insufficiency (→ **Fig. 1A**). Magnetic resonance angiography (MRA) revealed right PPTA originating from ICA and connecting to BA, and right ICA occlusion distal to PPTA (→ **Fig. 1B**). MRA also showed opacification of the right middle cerebral artery (MCA). Emergency cerebral angiography showed that the right ICA was occluded about 3 mm distal to the PPTA orifice. There was no stenotic change in PPTA itself and ICA proximal to PPTA origin. Collateral blood flow via the

anterior communicating artery (AComA) to right MCA was revealed (→ **Fig. 2**). The occluded end of ICA was not characteristic of acute embolization, such as showing a meniscus sign. Additionally, there was an anastomosis from the right maxillary artery to ICA via the ophthalmic artery. Collateral blood circulation was considered to have developed, and sufficient collateral blood flow was expected. Blood flow of the right cerebral hemisphere had not significantly decreased compared with the contralateral side on single-photon emission computed tomography (→ **Fig. 3**). From these findings, right ICA was considered to show stenosis due to atherosclerotic changes, although there was a possibility that an embolus had formed due to AF, finally occluding the stenosed atherosclerotic ICA. In our case, BA was thin and blood flow to the vertebrobasilar system was supplied via PPTA. Conservative treatment was conducted in the acute phase with transoral administration of 10 mg of rivaroxaban. Symptoms such as left hemiparesis gradually improved. She was transferred to another hospital for rehabilitation on the 27th day with a modified Rankin Scale of 3. Blood flow and ICA occlusion remained unchanged during the follow-up period. MRI obtained 9 months after onset showed ICA occlusion, patency of PPTA, and no new cerebral infarction (→ **Fig. 4**).

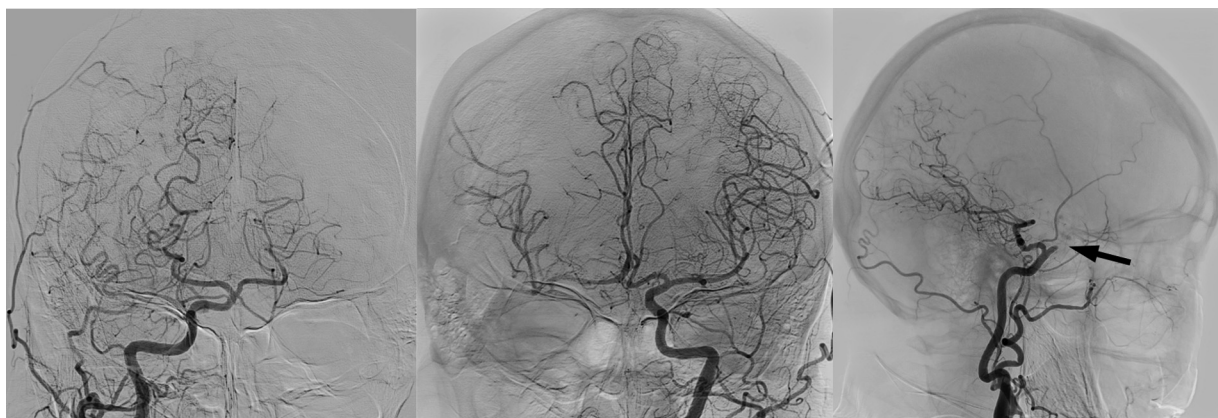

Fig. 2 Angiography revealing right internal carotid artery (ICA) occlusion distal to persistent primitive trigeminal artery and collateral blood flow via anterior communicating artery. The distal end of the occluded ICA is round (arrow).

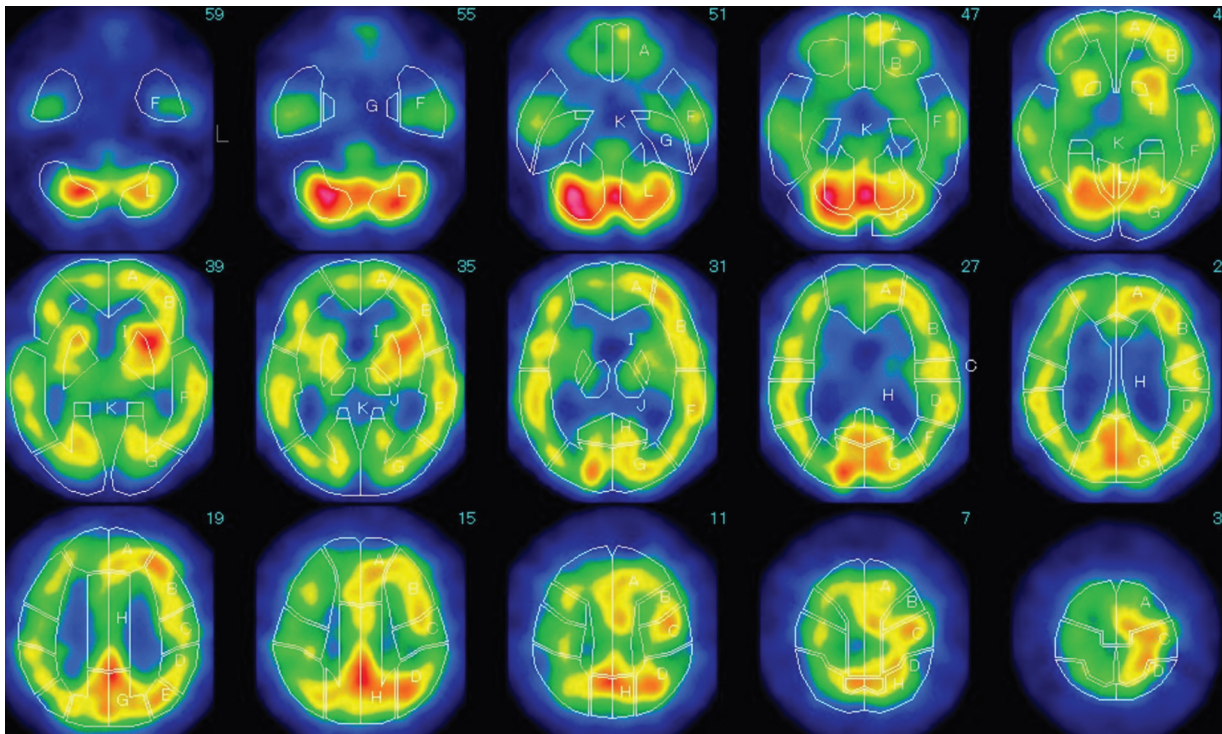


Fig. 3 Single-photon emission computed tomography showing that cerebral blood flow in the right cerebrum has slightly decreased.

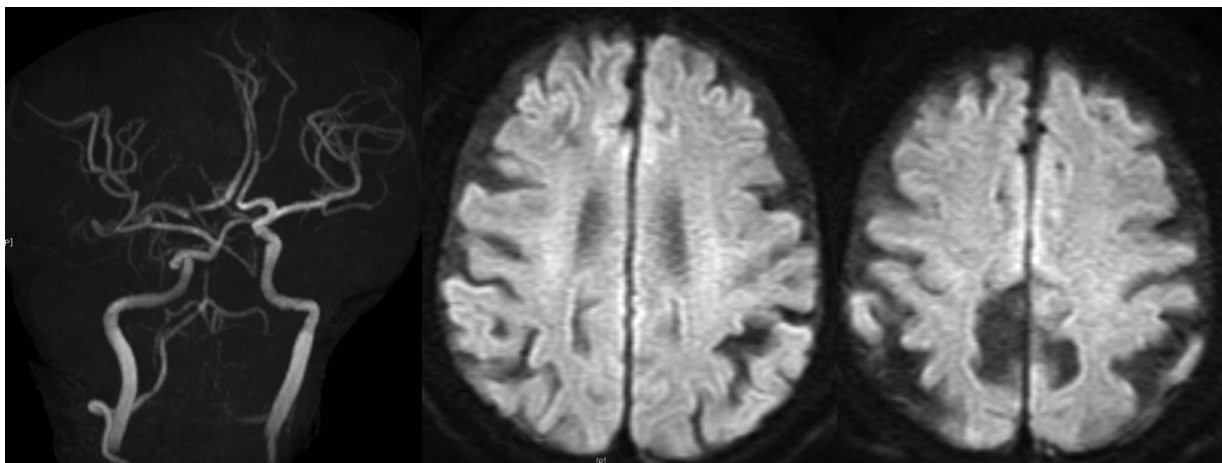


Fig. 4 Magnetic resonance imaging and magnetic resonance angiography obtained 9 months after onset showing persistent primitive trigeminal artery (PPTA), internal carotid artery occlusion distal to PPTA, and no new infarctions.

Discussion

Persistent Primitive Trigeminal Artery

PPTA is the most common persistent artery connecting between ICA and BA.⁷ PPTAs are classified into two subtypes: lateral and media.⁸ Suttner et al⁹ hypothesized that the developmental primordium differs between lateral and medial types. A recent study revealed that the lateral type is 11 times more common than the medial one.^{2,3} In our case, PPTA originated from the posterolateral wall of ICA, and penetrated the dura mater inside the trigeminal ganglion. Therefore, PPTA in our case was considered to be of the lateral type. PPTA generally contributes to normal cerebral blood flow and shows no pathology. However, it occasionally accompanies some anomalies, such as aneurysm, arteriovenous malformation,

and moyamoya disease.⁸ It is necessary to pay attention to PPTA during transphenoidal surgery or microvascular decompression for trigeminal neuralgia.¹⁰ In such cases, diagnosis and treatment are compromised. In our case, ICA distal to PPTA was occluded probably due to atherosclerosis. Atherosclerotic change followed by occlusion of ICA coincidentally occurred in our case. Although emergency endovascular treatment was not required in our case, recognition of the exact anatomy was mandatory.

Etiology

There are some reports describing cerebral infarction in cases of PPTA.¹¹ In our case, the right ICA was considered chronically stenosed or occluded due to atherosclerosis, not

simple embolization, because of the gradual worsening of neurological symptoms and relatively good neurological status. In addition, radiological examinations also revealed abundant collateral blood circulation and a small area of cerebral infarction. These findings are typically observed in cases of atherosclerotic cerebral infarction, although the possibility that a thrombus formed due to AF, contributing to occlusion of the atherosclerotic ICA at the final stage, cannot be excluded. PPTA is occasionally associated with stenosis, occlusion, dissection, and congenital absence of ICA.¹² Lyu et al reported a case of PPTA and ipsilateral hypoplasia of ICA distal to PPTA.⁸ Their patient developed cerebral infarction in the territory of ICA circulation. Cerebral infarction in their case may have been induced by hemodynamic insufficiency. Although their case was accompanied by congenital hypoplasia of distal ICA, the vascular anatomy was similar to that of our case with ICA occlusion. Foerch et al⁷ reported a case of cerebral infarction in the brain stem. In it, cervical ICA proximal to PPTA was severely stenotic, and PPTA contributed retrograde collateral blood supply to the distal ICA. In their case, the stenosis was treated by carotid artery stenting. Hiramatsu et al¹² reported a case of occlusion of ICA proximal to PPTA origin, which was treated by thrombectomy. On the other hand, ICA distal to PPTA was occluded in our case, and blood flow to the territory of the right distal ICA was supplied via AComA. Thus, in cases of cerebral infarction with PPTA, the pathology might be different in each case according to the location of the affected vessel. Therefore, close evaluation of anatomy and cerebral blood flow is essential. Prompt recognition of the vascular anatomy and selection of an appropriate treatment strategy are necessary in an emergency situation.

Treatment

For our case, conservative treatment was performed. We considered that ICA was gradually stenosed due to atherosclerosis, and sufficient collateral blood circulation had developed at the time of ICA occlusion. For such cases of atherosclerosis, an antiplatelet agent is commonly used as medical treatment. However, our patient had AF, and this may contribute to the final stage of occlusion of a stenotic ICA. Medical treatment with both anticoagulant and antiplatelet agents might increase the bleeding tendency in elderly patients. Therefore, only an anticoagulant drug was introduced. If cerebral blood flow is decreased, extracranial–intracranial bypass may be an option for cases of ICA occlusion with PPTA in the chronic stage. For cases with large vessel occlusion due to atherosclerosis in an acute stage, endovascular treatment may be necessary. Percutaneous transluminal angioplasty (PTA) or PTA with stenting might be an option, regardless of with or without PPTA. For these treatments, advancements of a guiding catheter to the common carotid artery or proximal ICA and microcatheter to ICA close to the PPTA orifice are necessary. In such situations, recognition of the existence of an anomalous artery is essential.

On the other hand, for cases of acute embolic stroke, mechanical thrombectomy (MT) should be considered in the same way as in cases without PPTA.^{12,13} Our case showed

collateral blood circulation; therefore, MT or acute endovascular treatment was not necessary. There are reports of patients with PPTA treated by MT in an acute stage.^{12,13} For such cases, advancement of a guiding catheter, microguide-wire, microcatheter, and stent is necessary. Regardless of PPTA being affected or not, emergency treatment of the vascular lesion is essential for cases with large-vessel occlusion in an emergency situation.

During angiography, catheterization into PPTA was not done, because PPTA itself was not affected in our case. There are some reports of cases in which PPTA itself was affected and manipulated.^{14–18} Among them, two cases underwent thrombectomy through PPTA.^{14,15} The diameter of PPTA is reported to be 1.7–9 mm.^{19–21} The media of PPTA has been reported to be congenitally vulnerable¹⁷; therefore, it is necessary to pay close attention not to damage the vessel wall of PPTA. It is important to recognize the vascular anatomy correctly, not only in cases treated by the endovascular technique, but also in conservatively treated cases. Even in emergency situations, it is necessary to thoroughly confirm the vascular anatomy and diameter of PPTA on radiological examinations. By checking these anatomical characteristics, safe and reliable treatment will be possible without damage of PPTA, such as arterial perforation and dissection.

Conclusion

Although cases with cerebral infarction due to ICA occlusion accompanied with PPTA are rare, the frequency of encountering such cases might increase as the radiological modalities develop and indication of MT expands. Care should be taken to correctly diagnose the anatomy, including the existence of an anomalous vessel. Rapid and accurate radiological examination facilitates safe and effective treatment.

Authors' Contributions

H.A. and K.M. were involved in drafting of manuscript, critical revision, and treatment of patient. I.F., A.T., R.Y., M.T., and T.N. drafted and critically revised the manuscript. M.N. contributed to study conception and design, drafting of manuscript, critical revision, and treatment of patient.

Ethical Approval and Patients' Consent

This study was approved by the Ethics Committee of Yokohama Sakae Kyosai Hospital. Need for written patient consent form was waved by the Ethics Committee because data were deidentified.

Conflict of Interest

None declared.

References

- 1 Namba K. Carotid-vertebrobasilar anastomoses with reference to their segmental property. *Neurol Med Chir (Tokyo)* 2017;57(06): 267–277
- 2 O'uchi E, O'uchi T. Persistent primitive trigeminal arteries (PTA) and its variant (PTAV): analysis of 103 cases detected in 16,415

- cases of MRA over 3 years. *Neuroradiology* 2010;52(12):1111–1119
- 3 Uchino A, Saito N, Okada Y, et al. Persistent trigeminal artery and its variants on MR angiography. *Surg Radiol Anat* 2012;34(03):271–276
 - 4 Parkinson D, Shields CB. Persistent trigeminal artery: its relationship to the normal branches of the cavernous carotid. *J Neurosurg* 1974;40(02):244–248
 - 5 Schmid AH. Persistent trigeminal artery. An autopsy report. *Neuroradiology* 1974;7(03):173–175
 - 6 Willinsky R, Lasjaunias P, Berenstein A. Intracavernous branches of the internal carotid artery (ICA). Comprehensive review of their variations. *Surg Radiol Anat* 1987;9(03):201–215
 - 7 Foerch C, Berkefeld J, Halbsguth A, Ziemann U, Neumann-Haefelin T. Brain stem infarction caused by proximal internal carotid artery stenosis in a patient with a persisting primitive trigeminal artery. *Cerebrovasc Dis* 2006;22(2-3):200–202
 - 8 Lyu DP, Wang Y, Wang K, Yao M, Wu YF, Zhou ZH. Acute cerebral infarction in a patient with persistent trigeminal artery and homolateral hypoplasia of internal carotid artery distal anastomosis: a case report and a mini review of the literature. *J Stroke Cerebrovasc Dis* 2019;28(12):104388
 - 9 Suttner N, Mura J, Tedeschi H, et al. Persistent trigeminal artery: a unique anatomic specimen—analysis and therapeutic implications. *Neurosurgery* 2000;47(02):428–433
 - 10 Tyagi G, Sadashiva N, Konar S, et al. Persistent trigeminal artery: neuroanatomic and clinical relevance. *World Neurosurg* 2020;134:e214–e223
 - 11 Liu YB, Feng PY, Zhang TZ, Sun J, Yang HX. A study on the persistent trigeminal artery and its classification based on magnetic resonance angiograph images. *J Comput Assist Tomogr* 2022;46(04):645–650
 - 12 Hiramatsu R, Ohnishi H, Kawabata S, Miyachi S, Kuroiwa T. Successful recanalization for internal carotid artery occlusion with persistent primitive trigeminal artery manifesting only as ischemia of the posterior circulation. *BMC Neurol* 2016;16:41
 - 13 Horio Y, Fukuda K, Yoshinaga T, et al. Successful mechanical thrombectomy using a combined technique for internal carotid artery occlusion with persistent primitive trigeminal artery. *Surg Neurol Int* 2020;11:345
 - 14 Imahori T, Fujita A, Hosoda K, Kohmura E. Acute ischemic stroke involving both anterior and posterior circulation treated by endovascular revascularization for acute basilar artery occlusion via persistent primitive trigeminal artery. *J Korean Neurosurg Soc* 2016;59(04):400–404
 - 15 Mulder MJHL, Lycklama à Nijeholt GJ, Dinkelaar W, et al. Thrombectomy in posterior circulation stroke through persistent primitive trigeminal artery: a case report. *Interv Neuroradiol* 2015;21(06):715–718
 - 16 Schlamann M, Doerfler A, Schoch B, Forsting M, Wanke I. Balloon-assisted coil embolization of a posterior cerebral artery aneurysm via a persistent primitive trigeminal artery: technical note. *Neuroradiology* 2006;48(12):931–934
 - 17 Shiomi K, Yamao Y, Ishii A, et al. Carotid-cavernous fistula associated with a ruptured persistent primitive trigeminal artery aneurysm: a case report and review of literature. *NMC Case Rep J* 2021;8(01):691–696
 - 18 Zenteno M, Lee A, Moscote-Salazar LR. Rupture of persistent primitive trigeminal artery-basilar artery aneurysm managed with stent-assisted coiling. *Asian J Neurosurg* 2018;13(03):817–821
 - 19 Tubbs RS, Shoja MM, Salter EG, Oakes WJ. Cadaveric findings of persistent fetal trigeminal arteries. *Clin Anat* 2007;20(04):367–370
 - 20 Pötin M, Miralbé S, Cattin F, et al. MRI and MR angiography of persistent trigeminal artery. *Neuroradiology* 1996;38(08):730–733
 - 21 Vasović L, Jovanović I, Ugrenović S, Vlajković S, Jovanović P, Stojanović V. Trigeminal artery: a review of normal and pathological features. *Childs Nerv Syst* 2012;28(01):33–46