




# Advancements in Cholangioscopy: A Case Report with a New Cholangioscope System and Review of Literature

Priscilla Lopez<sup>1,2</sup>  Mohan Ramchandani<sup>3</sup> Sundeep Lakhtakia<sup>3</sup> Pradev Inavolu<sup>3</sup> D. Nageshwar Reddy<sup>3</sup>

<sup>1</sup> Department of Surgery Clínica Las Condes, Santiago, Chile

<sup>2</sup> Department of Therapeutic, Instituto Chileno Japonés, Santiago, Chile

<sup>3</sup> Department of Gastroenterology, Asian Institute of Gastroenterology, Hyderabad, Telangana, India

**Address for correspondence** D. Nageshwar Reddy, MD, DM, FRCP, Department of Gastroenterology, Asian Institute of Gastroenterology, Hyderabad, Telangana 500082, India (e-mail: aigindia@yahoo.co.in).

J Digest Endosc 2024;15:125–130.

## Abstract

The field of cholangioscopy is undergoing rapid evolution, marked by continuous innovation. The advent of SpyGlass cholangioscopy has initiated a new chapter, transforming the practice with advancements that include single-operator procedures and the introduction of disposable cholangioscopes. Despite these strides, significant needs remain, including enhancement of optical imaging, improving maneuverability, and expansion of therapeutic channels. This article delves into the recent progress within cholangioscopy, with a particular focus on the clinical applications of the Leinzett Lan-EP-3516 cholangioscope for the management of portal biliopathy. We present a detailed case study demonstrating how this cutting-edge cholangioscope—distinguished by its various sizing options and compatibility with portable devices for immediate imaging—played an important role in the successful treatment of a distal common biliary duct stricture and choledocholithiasis. The device's cost-effectiveness and superior imaging quality signify a notable advancement in cholangioscopic technology, facilitating enhanced treatment pathways for patients with complex biliary disorders. This case exemplifies the dynamic and expanding utility of cholangioscopy in therapeutic interventions and underscores its escalating significance in clinical settings.

## Keywords

- ▶ portal biliopathy
- ▶ single-operator cholangioscopy
- ▶ ERCP
- ▶ stricture

## Introduction

Direct endoscopic views of the bile duct have been described in literature since the 1970s.<sup>1</sup> Over the decades, remarkable progress has been achieved, driven by technologically advanced systems that offer improved image quality and enhanced maneuverability. Cholangioscopy, initially employed primarily for characterizing indeterminate strictures and managing large bile duct stones, has expanded its scope to include a broader range of therapeutic procedures, elevating its clinical significance.

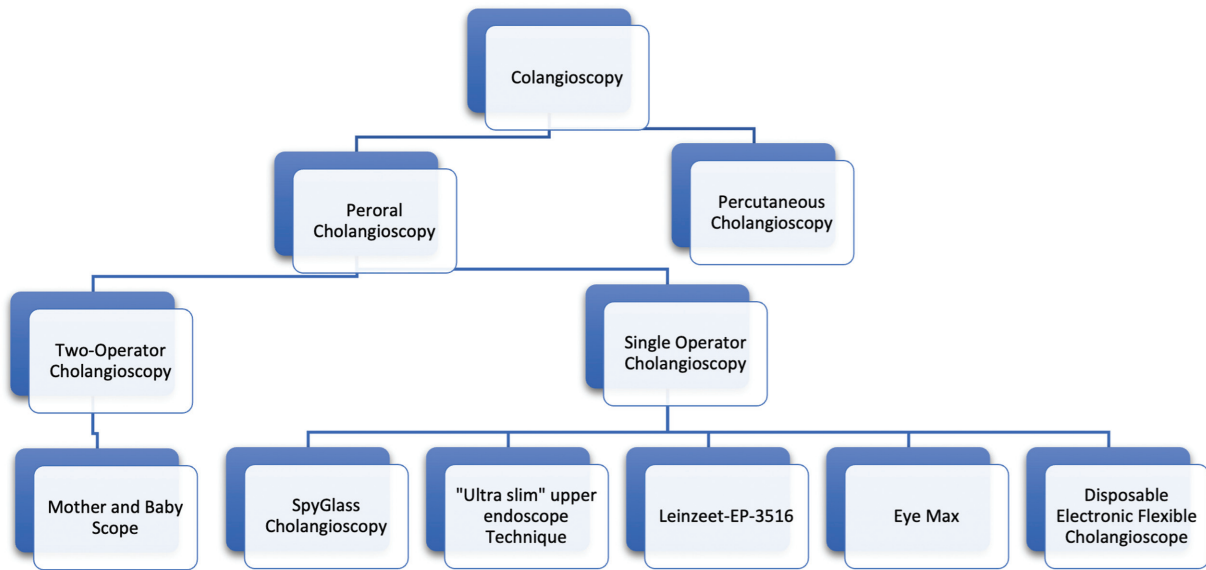
While three distinct cholangioscopy techniques have been described, encompassing “dual-operator”,<sup>2</sup> “single-operator”,<sup>3,4</sup> and the “direct” technique using gastroscopes, it is the single-operator cholangioscopy that has garnered widespread acceptance as the gold standard for biliary system interventions.<sup>5,6</sup> Its user-friendly design and widespread availability have contributed to its prominence in clinical practice.

However, the field of cholangioscopy faces several unmet needs, such as the demand for larger therapeutic channels, improved irrigation capabilities, and thinner scopes to

DOI <https://doi.org/10.1055/s-0044-1787125>.  
ISSN 0976-5042.

© 2024. The Author(s).

This is an open access article published by Thieme under the terms of the Creative Commons Attribution License, permitting unrestricted use, distribution, and reproduction so long as the original work is properly cited. (<https://creativecommons.org/licenses/by/4.0/>)  
Thieme Medical and Scientific Publishers Pvt. Ltd., A-12, 2nd Floor, Sector 2, Noida-201301 UP, India



**Fig. 1** Types of cholangioscopy.

navigate tight strictures. Additionally, there is a pressing need for more cost-effective cholangioscope options, especially in resource-limited settings.

The first single-operator cholangioscope system developed was the legacy SpyGlass Direct Visualization System (Boston Scientific, Marlborough, Massachusetts, United States).<sup>3</sup> Since then, continuous advancements in cholangiopancreatography have persisted, leading to the development of newer cholangioscope systems. One such innovative cholangioscope is the Leinzeet Lan-EP-3516 (→Fig. 1, →Tables 1 and 2). This single-operator cholangioscope is available in three different sizes, offering versatility to medical practitioners.

We describe the usefulness of this novel cholangioscope in a case of obstructive jaundice in the setting of portal hypertension, the condition commonly known as portal biliopathy (PB) or portal hypertensive cholangiopathy. The currently available imaging modalities include abdominal ultrasound,

computed tomography (CT), magnetic resonance imaging,<sup>7</sup> and endoscopic ultrasound.<sup>8,9</sup> These are all suggestive but not diagnostic of the actual biliary pathology in these patients. The introduction of cholangioscopy makes it possible to assess the biliary lesions more efficiently.<sup>10,11</sup> This provides essential information that directs patient management in this disease. Most patients with PB-related ductal abnormalities are asymptomatic<sup>12</sup> and do not require any treatment. Those who are symptomatic require treatment in the form of repeated endoscopic interventions or surgery.<sup>13</sup> Choice of therapy depends on various factors, such as type and number of biliary strictures, presence or absence of veins for shunt surgery, and biliary stones. In this context, we present a case report that demonstrates the successful management of distal common biliary duct (CBD) stricture and choledocolithiasis in patients with PB using the Leinzeet Lan-EP-3516 cholangioscope.

**Table 1** General characteristics of cholangioscopes

	DOC CHF-BP30	DOC CHF-B290	"Ultra Slim" upper endoscope technique	Digital SOC	Leinzeet-EP-3516	Eye Max	Disposable electronic flexible choledoscope
Image	++	+++	+++	++	++	++	++
Therapeutic channel	++	+++	+++	++	+++	+++	++
Separate irrigation channel	No	Yes	No	Yes	Yes	Yes	Yes
Maneuverability	++	++	+++	+++	+++	+++	++
Cost	+++	+++	+++	++	+	+	+
Disposable	No	No	No	Yes	Yes	Yes	Yes
Operator	2	2	1	1	1	1	1

Abbreviations: DOC, dual-operator cholangioscopy; SOC, single-operator cholangioscopy.

Note: + poor; ++ fair; +++ good.

**Table 2** Characteristics of cholangioscopes

	DOC CHF-BP30	DOC CHF-B290	“Ultra Slim” upper endoscope	Digital SOC	Leinzett	Eye Max	Disposable electronic flexible choledoscope
Insertion diameter (mm)	Distal diameter 3.1	3.4	5.9-5	3.6	3.8/3.52/2.6	3.7/3.07	3.4/3.3
Working channel (mm)	1.2	1.3	2.2	1.2	2/1.6/1.2	2/1.2	1.2
Working length (mm)	1,870	1,920	1,100-1,700	2,140	2,140	2,200	1,870
Steering	2-way (up-down)	2-way (up-down) 70 grades	4-way (up-down-right-left) Up to 210 grades	4-way (up-down-right-left) 30 grades	4/2-way (up-down) (up-down)	4-way (up-down-right-left) 30 grades	4-way/2 way (up-down-right-left) (up-down)
Quality images	High definition	Enhanced near-point image quality	High-resolution definition	High-resolution definition	High-resolution definition	High-resolution definition	High-resolution definition
Image-enhanced function system	Not available	Available	Available	Not available	Not available	Not available	Not available
Compatible with phone-tablet	No	No	No	No	Yes	No	No

Abbreviations: DOC, dual-operator cholangioscopy; SOC, single-operator cholangioscopy.

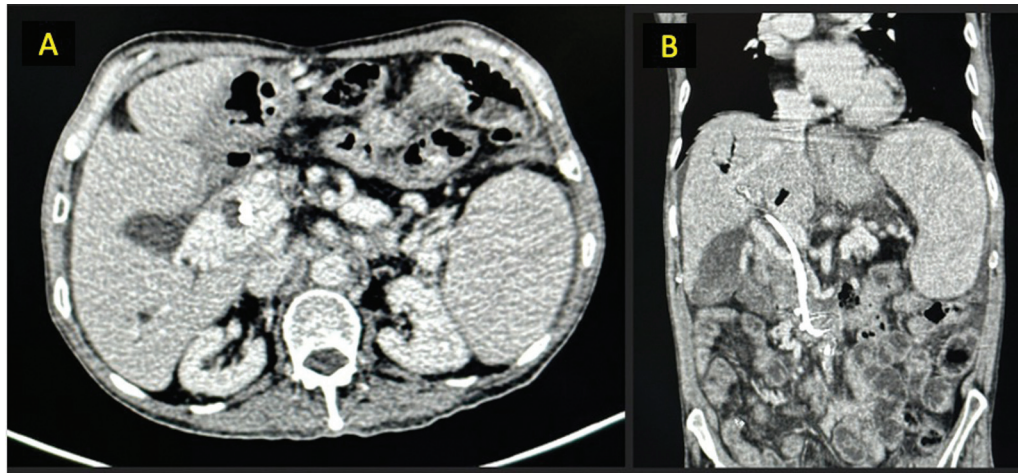
### Case

A 70-year-old male patient presented with a medical history characterized by diabetes mellitus type II, chronic calcific pancreatitis, and portal hypertension due to portal vein thrombosis and liver disease secondary to nonalcoholic steatohepatitis. This patient had previously experienced obstructive jaundice due to a benign distal common bile stricture and large and numerous bile duct stones in the year 2021; endoscopic retrograde cholangiopancreatography (ERCP) was done. The stricture was treated with covered self-expanding metal stents, which was removed 10 months later. Multiple ERCPs with balloon sphincteroplasty and plastics stent exchanges were done between 2021 and 2023. The patient consulted due to abdominal pain, and laboratory data showed elevated bilirubin and mild elevation of transaminases and alkaline phosphatase. Positron emission tomography-CT study showed a CBD stent in situ, without avid mass lesion noted in distal CBD to suggest neoplastic pathology. The liver shows heterogeneous parenchymal attenuation, surface nodularity with volume distribution, concordant with chronic liver disease. The portal vein is replaced by multiple collaterals in porto-hepatis (portal cavernoma with multiple paracholedochal collaterals). Dilated biliary intrahepatic bilateral radicular ducts were noted (→Fig. 2). The procedure was performed using deep sedation (general anesthesia without endotracheal intubation), following the patient’s informed and documented consent. After the duodenoscope was introduced, two plastic stents were removed using rat tooth forceps. Then, selective CBD cannulation was performed, and a guidewire (0.025-inch, Visiglide Guidewire, Olympus Corp, Tokyo, Japan) was passed into the common bile duct. Cholangioscopy was planned. The introduction of the cholangioscope Leinzett Lan-EP-3516 (Hangzhou Leinzett Medical Technology Co Ltd, Hangzhou, Zhejiang, China) was done with wire-guided technique and the maneuverability was easy. Cholangioscopy revealed the presence of a smooth stricture with sharp edges with no evidence of any neovascularization, nodularity, or extrinsic compression in distal CBD.

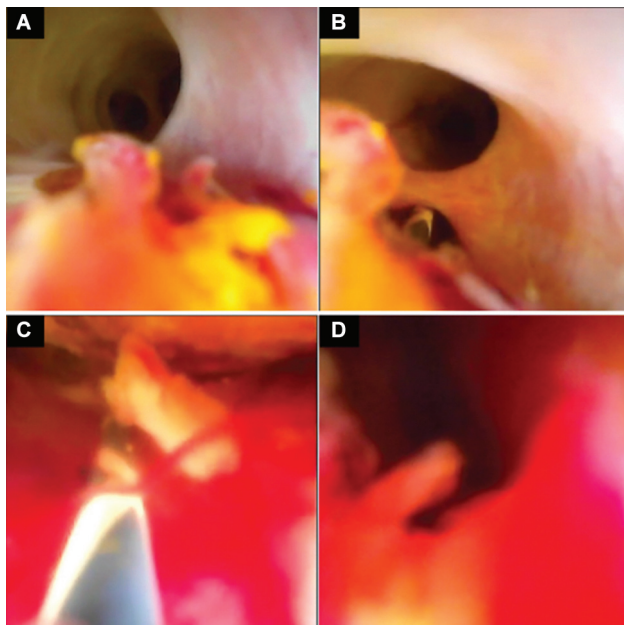
Additionally, multiple hard and soft biliary stones were found above the stricture, and multiple longitudinal protrusions on the CBD wall were suggestive of intraductal varices (→Fig. 3). The cholangioscope could be negotiated easily through this stricture. Biliary endotherapy was deferred because of the high risk of bleeding in the presence of intraductal varices. Given the benign stricture and the multiple stones, two 7-F, 10-cm double-pigtail plastic stents (Zimmon, Cook Medical LLC, Bloomington, Indiana, United States) were placed. The patient was comfortable after the procedure, and no bleeding or complications were observed. The proximal splenorenal shunt (PRSS) could not be done as there was no shuntable splenic vein.

### Discussion

The field of cholangioscopy is dynamic and continually advancing, with its applications expanding, particularly in therapeutic



**Fig. 2** Positron emission tomography-computed tomography (PET-CT): (A, B) Portal cavernomatosis with multiple paracholedochal collaterals.



**Fig. 3** Leinzett-EP-3516 images: (A and B) Mucosal nodularity with subepithelial bulge suggestive of biliary varices. (C) Secondary biliary stones. (D) Benign biliary stricture.

procedures, thus heightening its clinical significance. Cholangioscopy, a technique with a history spanning several decades, has come to the forefront of routine medical practice following refinements in device design for single-operator use and substantial enhancements in endoscopic imaging. Nevertheless, despite these notable strides, several challenges persist, impeding its widespread adoption. Over time, various alternative cholangioscope devices have been developed, each with distinct features and specifications, the general characteristics of some of them we explained in ►Tables 1 and 2.

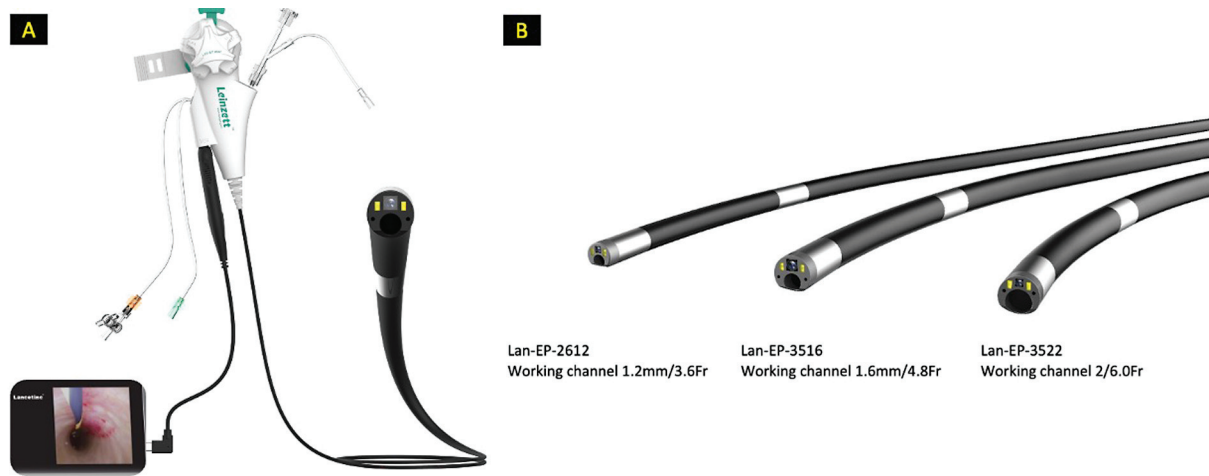In this case study, we exemplify the application of the Leinzett Lan-EP-3516 cholangioscope (as demonstrated in ►Fig. 4), an innovative device that obtained Food and Drug Administration approval in October 2023. Importantly,

this advanced cholangioscope is offered in three external diameter versions: 11.4, 10.5, and 7.8 Fr, each accompanied by corresponding working channels of 6, 4.8, and 3.6 Fr (as depicted in ►Fig. 4).

An exceptional feature of the Leinzett Lan-EP-3516 is its flexible connection option to portable devices such as tablets and smartphones via an image processor, which enables direct procedure recording (as illustrated in ►Fig. 4). Furthermore, an online application can be downloaded to a phone, tablet, or personal computer (PC) for real-time recording and capturing screenshots. Notably, this system operates without needing for a separate power source, drawing power from the connected device, whether a tablet, phone, PC, or monitor.

Another notable advantage is the cost-effectiveness of the Leinzett Lan-EP-3516 in comparison to other cholangioscopes, addressing a common critique associated with cholangioscopy devices. It is essential to emphasize that cholangioscopy is typically employed in complex cases where patients have undergone various biliopancreatic endoscopic procedures. The early application of cholangioscopy may reduce the overall procedural cost in these cases.<sup>14</sup>

In this case, cholangioscopy showed that the stricture was caused by ischemia because it had smooth margins with no nodularity and neovascularization or compression by collaterals.<sup>15</sup> Furthermore, the cholangioscopy confirmed the presence of intraluminal varices, which may be an intraductal manifestation of PB. Additionally, detection of multiple hard and soft choledocholithiasis was critical to determining the appropriate treatment strategy. PB refers to biliary adverse events as a result of portal hypertension. The prevalence of PB in portal hypertension due to cirrhosis is 25 to 40%.<sup>16</sup> Clinical presentation of PB varies from biliary varices to strictures that lead to adverse events of obstructive jaundice, cholangitis, choledocholithiasis, and secondary biliary cirrhosis. It has been postulated that during the early phase of the disease, the biliary obstruction is caused by the pressure of collaterals on the bile ducts. As the disease progresses, there is scarring, leading to angulations or stricture formation. Identifying



**Fig. 4** (A) Connection option to portable device. (B) Different working channels diameters.

the cause of stricture is imperative to decide the management. In these cases, blind biliary endotherapies like stricture dilation, biliary sweep using a stone retrieval balloon, or Dormia basket may cause severe bleeding and be avoided in this case. For that, the treatment was the insertion of two plastic double-pigtail stents.<sup>10</sup> Curative treatment in this clinical situation is surgery, commonly PRSS followed by bilioenteric anastomosis but in this patient, there was no shuntable vein available.<sup>17–19</sup>

## Conclusion

We report using a new cholangioscope, Leinzett Lan-EP-3516, in patients with PB. Valuable information was obtained by this imaging modality, which is essential to managing these patients. Cholangioscopy is advancing rapidly, finding expanding applications in therapeutic procedures and solidifying its role in modern medicine. This recent addition to the armamentarium of cholangioscopy devices showcases the ongoing progress in the field, further improving patient care and expanding the utility of cholangioscopy in clinical practice. As technology continues to drive cholangioscopy forward, it is set to become an indispensable tool for endoscopy, providing clinicians with enhanced options for precise diagnostics and optimized therapeutic interventions in a wide range of clinical scenarios.

### Funding

None.

### Conflict of Interest

None declared.

## References

- 1 Urakami Y, Seifert E, Butke H. Peroral direct cholangioscopy (PDCS) using routine straight-view endoscope: first report. *Endoscopy* 1977;9(01):27–30
- 2 Nakajima M, Akasaka Y, Yamaguchi K, Fujimoto S, Kawai K. Direct endoscopic visualization of the bile and pancreatic duct systems by peroral cholangiopancreatography (PCPS). *Gastrointest Endosc* 1978;24(04):141–145
- 3 Chen YK. Preclinical characterization of the Spyglass peroral cholangiopancreatography system for direct access, visualization, and biopsy. *Gastrointest Endosc* 2007;65(02):303–311
- 4 Chen YK, Pleskow DK. SpyGlass single-operator peroral cholangiopancreatography system for the diagnosis and therapy of bile-duct disorders: a clinical feasibility study (with video). *Gastrointest Endosc* 2007;65(06):832–841
- 5 Mauro A, Mazza S, Scalvini D, et al. The role of cholangioscopy in biliary diseases. *Diagnostics (Basel)* 2023;13(18):13
- 6 Navaneethan U, Hasan MK, Kommaraju K, et al. Digital, single-operator cholangiopancreatography in the diagnosis and management of pancreatobiliary disorders: a multicenter clinical experience (with video). *Gastrointest Endosc* 2016;84(04):649–655
- 7 Aguirre DA, Farhadi FA, Rattansingh A, Jhaveri KS. Portal biliopathy: imaging manifestations on multidetector computed tomography and magnetic resonance imaging. *Clin Imaging* 2012;36(02):126–134
- 8 Mangla V, Singla V, Pal S. Portal biliopathy: diagnosis by endosonography. *Clin Gastroenterol Hepatol* 2012;10(01):A34
- 9 Chavan R, Nabi Z, Lakhtakia S, et al. Linear endoscopic ultrasound examination of portal biliopathy. *Endoscopy* 2020;52(04):E136–E137
- 10 Ramchandani M, Nageshwar Reddy D, Lakhtakia S, Gupta R, Tandan M, Rao GV. Role of single-operator per-oral cholangioscopy and intraductal US in assessment of portal biliopathy (with videos). *Gastrointest Endosc* 2014;79(06):1015–1019
- 11 Phan VA, Abu-Assi R, Nguyen N. Gastrointestinal: utility of per-oral cholangioscopy in the diagnosis of portal hypertension associated biliopathy. *J Gastroenterol Hepatol* 2016;31(11):1798
- 12 Llop E, de Juan C, Seijo S, et al. Portal cholangiopathy: radiological classification and natural history. *Gut* 2011;60(06):853–860
- 13 Cellich PP, Crawford M, Kaffes AJ, Sandroussi C. Portal biliopathy: multidisciplinary management and outcomes of treatment. *ANZ J Surg* 2015;85(7-8):561–566
- 14 Angsuwatcharakon P, Kulpatcharapong S, Moon JH, et al. Consensus guidelines on the role of cholangioscopy to diagnose

- indeterminate biliary stricture. *HPB (Oxford)* 2022;24(01):17–29
- 15 Dhiman RK, Puri P, Chawla Y, et al. Biliary changes in extrahepatic portal venous obstruction: compression by collaterals or ischemic? *Gastrointest Endosc* 1999;50(05):646–652
- 16 Agarwal AK, Sharma D, Singh S, Agarwal S, Girish SP. Portal biliopathy: a study of 39 surgically treated patients. *HPB (Oxford)* 2011;13(01):33–39
- 17 Bhavsar R, Yadav A, Nundy S. Portal cavernoma cholangiopathy: update and recommendations on diagnosis and management. *Ann Hepatobiliary Pancreat Surg* 2022;26(04):298–307
- 18 Khuroo MS, Rather AA, Khuroo NS, Khuroo MS. Portal biliopathy. *World J Gastroenterol* 2016;22(35):7973–7982
- 19 Machicado JD, Rajjman I, Shah RJ. Future of cholangioscopy. *Gastrointest Endosc Clin N Am* 2022;32(03):583–596