


# Use of Ambient Light Compatible Fluorescence-Guided Surgical Technology for Objective Assessment of Flap Perfusion in Autologous Breast Reconstruction

Ellen C. Shaffrey, MD<sup>1</sup>  Steven P. Moura, MA<sup>1,2</sup> Allison J. Seitz, MD<sup>1</sup> Sydney Jupitz, PhD<sup>3</sup>  
Trevor Seets, MS<sup>3</sup> Tisha Kawahara, MS<sup>3</sup> Adam Uselmann, PhD<sup>3</sup> Christie Lin, PhD<sup>3</sup>  
Samuel O. Poore, MD, PhD<sup>1</sup>

<sup>1</sup> Division of Plastic Surgery, University of Wisconsin School of Medicine and Public Health, Madison, Wisconsin

<sup>2</sup> Boston University Chobanian and Avedisian School of Medicine, Division of Plastic and Reconstructive Surgery, Boston, Massachusetts

<sup>3</sup> OnLume Surgical, Research Division, Madison, Wisconsin

**Address for correspondence** Samuel O. Poore, MD, PhD, Division of Plastic and Reconstructive Surgery, University of Wisconsin School of Medicine, 600 Highland Avenue, CSC G5/347, Madison, WI (e-mail: poore@surgery.wisc.edu).

J Reconstr Microsurg

## Abstract

**Background** Decreased autologous flap vascular perfusion can lead to secondary procedures. Fluorescence angiography during surgery reduces the probability of repeat surgery but suffers from interpretation variability. Recently, the OnLume Avata System was developed, which evaluates real-time vascular perfusion in ambient light. This study aims to predict complications in autologous breast reconstruction using measures of relative intensity (RI) and relative area (RA).

**Methods** Patients undergoing autologous breast reconstruction underwent intraoperative tissue perfusion assessment using the OnLume Avata System. Post-hoc image annotation was completed by labeling areas of the flap interpreted to be “Well Perfused,” “Questionably Perfused,” and “Under Perfused.” RIs and RAs were calculated for the marked areas. Primary complications of interest were overall complication rate, fat and mastectomy skin flap necrosis, and surgical revision. Logistic regression was applied to determine the odds of developing a complication based on RI and RA for each image.

**Results** A total of 25 patients (45 flaps) were included. In total, 17 patients (68%) developed at least one complication. Patients who developed any complication ( $p = 0.02$ ) or underwent a surgical revision for complications ( $p = 0.02$ ) had statistically lower RI of under-perfused portions of the flap. Patients with greater areas of under-perfused flap had a significantly higher risk of developing fat necrosis (odds ratio [OR]: 5.71,  $p = 0.03$ ) and required a revision operation (OR: 1.10,  $p = 0.01$ ).

**Conclusion** Image-based interpretation using the OnLume Avata System correlated with the risk of developing postoperative complications that standard fluorescence imaging systems may not appreciate. This information can benefit surgeons to improve perfusion assessment and intraoperative decision-making.

## Keywords

- ▶ fluorescence imaging
- ▶ microsurgical anastomosis
- ▶ indocyanine green
- ▶ ambient light compatible
- ▶ autologous breast reconstruction

received  
February 5, 2024  
accepted after revision  
April 15, 2024

© 2024, Thieme. All rights reserved.  
Thieme Medical Publishers, Inc.,  
333 Seventh Avenue, 18th Floor,  
New York, NY 10001, USA

DOI <https://doi.org/10.1055/s-0044-1787267>  
ISSN 0743-684X.

Breast cancer is the most common cancer among women globally, with more than 2 million new cases diagnosed each year. As patients' survival continues to increase due to improved, multidisciplinary treatment, they must live longer with any morbidity resulting from surgical treatment. Notably, after cancer resection, approximately 19% of breast reconstruction patients pursue autologous reconstruction.<sup>1,2</sup> Post-mastectomy breast reconstruction improves the quality of life in breast cancer survivors but can be associated with high complication rates due to tissue ischemia.<sup>2</sup> In 15 to 25% of cases, patients undergo secondary surgery to correct tissue necrosis which can cost up to \$14,000 per procedure.<sup>3</sup>

Traditional approaches to identifying flap necrosis rely on a surgeon's subjective assessment, an unreliable predictor of postoperative complications.<sup>4-6</sup> Accurate and reliable intraoperative methods for assessment of the quality and viability of the mastectomy skin flaps and the abdominal tissue used for reconstruction are critical to mitigate early complications following reconstruction. Therefore, fluorescence imaging with the Food and Drug Administration (FDA)-approved dye indocyanine green (ICG) has been used to visualize flow through vessels and enable a more accurate assessment of anastomotic patency. Compared with other perfusion-imaging modalities such as computed tomography angiography (CTA), it allows for real-time evaluation of vascularity with additional radiation exposure.<sup>7</sup>

Intraoperative implementation of ICG angiography imaging has been demonstrated to predict the risk of tissue necrosis and reduce the probability of repeat procedures in autologous breast reconstruction.<sup>8-14</sup> It has also been implemented in secondary procedure to confirm adequate removal of ischemic tissues.<sup>15</sup> However, there continues to be difficulty with the interpretation of perfusion and standardization of fluorescence assessment techniques, as variables such as system performance, display settings, and patient factors can affect surgical perception. Furthermore, little investigation has been done on identifying objective variables within ICG angiography imaging that may influence the prediction of postoperative complications.

The OnLume Avata System (OnLume Surgical, Madison, WI), an FDA-cleared wide-field fluorescence-guided surgery (FGS) imaging system, can perform relative quantification to assess vascular perfusion in ambient light consistently. A recent study by Seets et al demonstrated this technology's ability to distinguish between well and under-perfused areas of an autologous free flap following anastomosis with a 97.8% sensitivity and 97.4% specificity.<sup>16</sup> This study aims to identify areas of vascular compromise and predict complications in autologous breast reconstruction using objective measures of relative intensity (RI) and relative area (RA) determined with OnLume imaging technology.

## Methods

A prospective clinical study was designed to evaluate the intraoperative perfusion of abdominally based autologous flaps and mastectomy skin in female patients who had

mastectomies followed by immediate or delayed deep inferior epigastric artery (DIEP) flap reconstruction. Patient enrollment began after institutional review board approval (ID #: 2020-0906) at the University of Wisconsin-Madison (Madison, WI). Patients over 18 years old presenting for either uni- or bilaterally based autologous reconstruction to be performed by the senior author (S.O.P.) between October 2021 and September 2022 were considered for participation. Patients were excluded if they had known allergies to ICG, a history of lymphedema of either upper extremity, or were pregnant, may become pregnant or, actively breastfeeding. Verbal and written consent was obtained from each patient preoperatively.

Patient demographics, comorbidities, breast cancer history, and intraoperative variables were recorded. The primary complications of interest were overall complication rate, development of fat or mastectomy skin flap necrosis, and complication-related surgical revision. Secondary complications of interest included incisional dehiscence, epidermolysis, infection, seroma, hematoma, and partial or total flap loss.

## Intraoperative Surgical Technique and Image Capture Protocol

All patients underwent simple skin-sparing or nipple-sparing mastectomy performed by one of four breast surgeons, followed by DIEP flap breast reconstruction by the senior author, a fellowship-trained microsurgeon (S.O.P.). Preoperative abdominal CTA was obtained for all patients to assist in perforator selection. Flaps were elevated based on perforators of DIEP, sparing any muscle harvest. After the mastectomies were completed, the recipient internal mammary artery and veins were prepared at the level of the third intercostal space. In bilateral cases, the flaps were sequentially ligated and transferred to the chest for microsurgical anastomosis. The lateral aspect of each flap, consistent with Zone 4, was removed in all cases before microsurgical anastomosis. All venous anastomoses were performed using a venous coupler, and arterial anastomoses were hand-sewn using 8-0 nylon in a simple, interrupted fashion.

After completion of the microsurgical anastomosis, each patient underwent visualization of the reconstructed DIEP flap and mastectomy skin flaps using the OnLume Avata System. An injection of 6.25 mg of fluorescent ICG dye was prepared according to instructions for use and administered centrally or peripherally as a bolus, immediately followed by a bolus injection of 10 mL of normal saline. The OnLume Avata System was then used to concurrently capture white light, fluorescence, and overlay (fluorescence on white light) vascular ingress videos into the reconstructed DIEP and mastectomy skin flaps under ambient light conditions with room lights kept on (**–Video S1**). Images were captured between the working distances of 20 to 45 cm. Bilateral cases were recorded with a single administration of ICG dye. Areas of concern were noted for research purposes using the OnLume Avata System; however, the final decisions for flap excision were based purely on standard-of-care fluorescence imaging using the SPY (Stryker, Kalamazoo, MI) and

clinical evaluation, in accordance with the clinical study protocol.

#### Video S1

Intraoperative video demonstrating continuous recording with simultaneous display of multiple image modalities (overlay, fluorescence, and standard white light) allowing for real-time identification of areas of decreased perfusion in ambient light. Online content including video sequences viewable at: <https://www.thieme-connect.com/products/ejournals/html/10.1055/s-0044-1787267>.

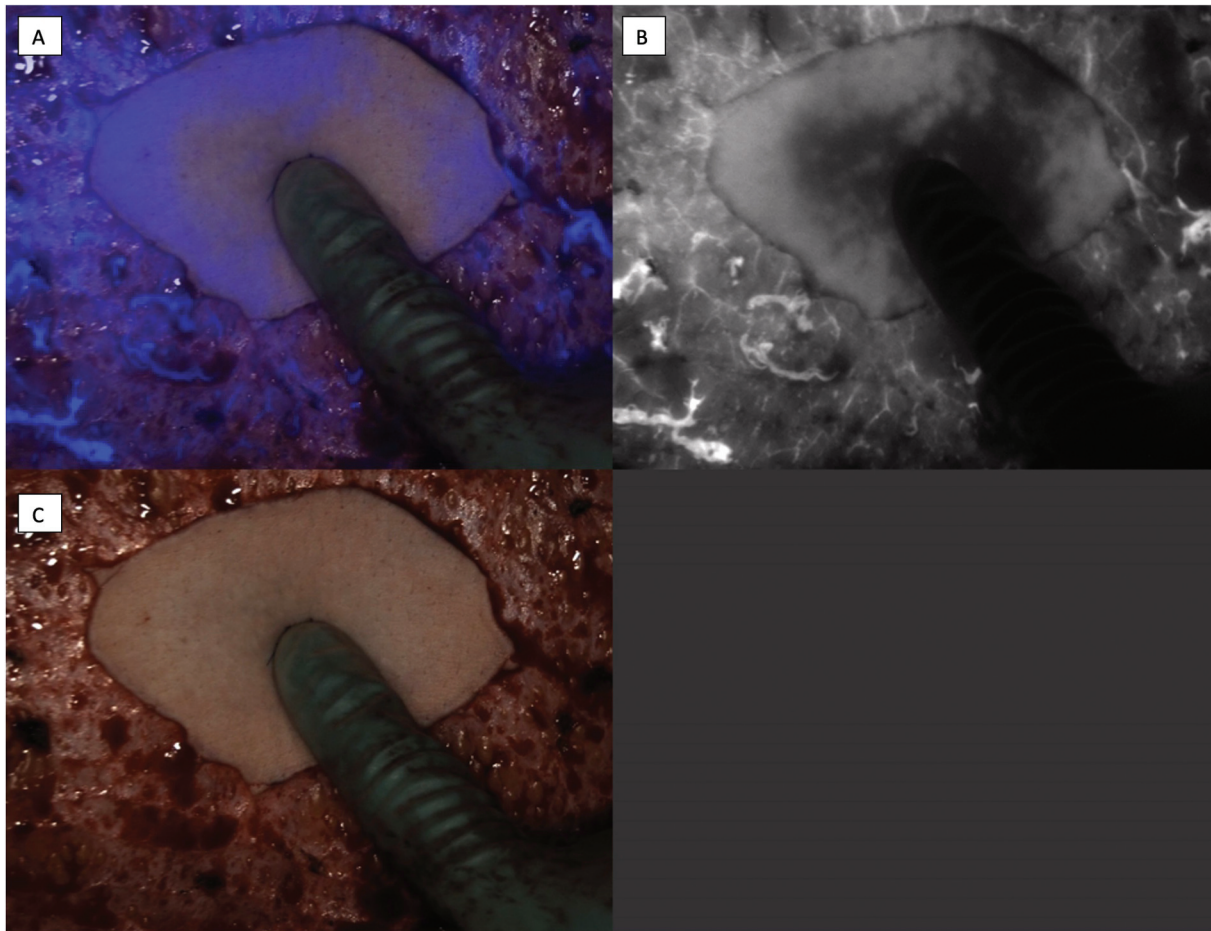
#### Postoperative Analysis of Flap Images

From the collected ingress videos, images were captured for post-hoc analysis of mastectomy skin flap and reconstructed DIEP flap vascularity (→Fig. 1). Images were selected once flaps had reached peak perfusion, which was determined using quantitative imaging metric software. The dataset of intraoperatively captured images was filtered, ensuring clear

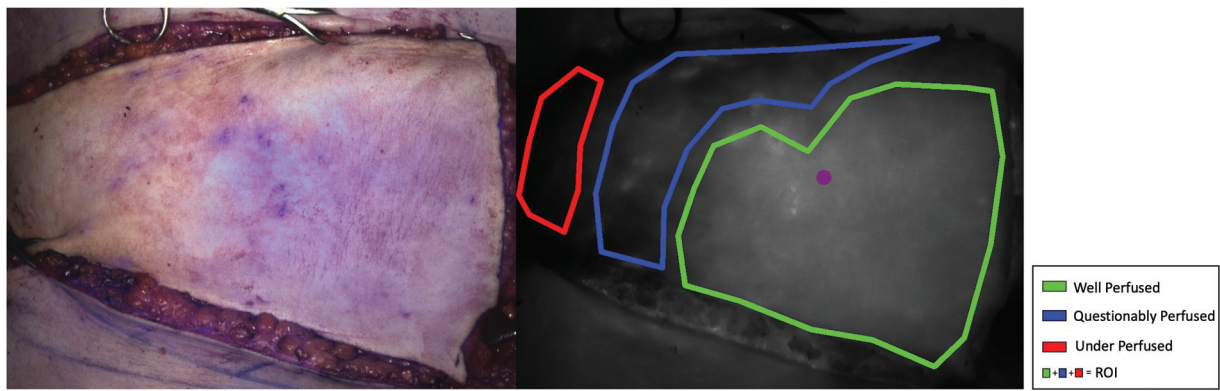
images of the majority of the flap surface and the removal of redundant images.

Post-hoc analysis of OnLume Avata images for all patients was performed by a blinded plastic surgeon (E.C.S.) not involved in the patient's initial operation to allow for unbiased analysis of the images. This surgeon had significant clinical experience reviewing fluorescence images for vascular perfusion. Areas of the mastectomy skin and reconstructed DIEP flap were subjectively assessed and outlined as either "Well Perfused," "Questionably Perfused," or "Under Perfused" using imaging software (→Fig. 2). "Well Perfused" areas were considered an area of the flap with obvious and uniform fluorescence and white light signal. "Questionably Perfused" areas were defined as regions of the flap where there was inconsistent or diminished signal. "Under Perfused" areas were defined as regions of the flap where there was no appreciable fluorescence or white light signal. Relative fluorescence intensity values were normalized between images by selecting a  $20 \times 20$ -pixel region in each image identified as the brightest area that was not an artifact.

On the final filtered dataset, the relative quantitation of all labeled regions was performed on a per-image basis to



**Fig. 1** Simultaneous display of multiple image modalities: (A) overlay, (B) fluorescence, and (C) standard white light. Surgeon performing palpation in ambient light of the region within DIEP flap that exhibits dimmer relative fluorescence consistent with decreased flap perfusion. DIEP, deep inferior epigastric artery.



**Fig. 2** Representative image of annotated reconstructed deep inferior epigastric artery (DIEP) flap at the point of maximal indocyanine green ingress. Areas of the flap that were thought to be “Well Perfused,” “Questionably Perfused,” and “Under Perfused” were marked to allow for calculation of relative intensity (RI) and relative area (RA). RI was normalized to  $20 \times 20$ -pixel selection of “bright” reference region (purple circle).

generate an relative overall intensity (ROI) for all marked areas and RI and RA values for the areas labeled “Well Perfused,” “Questionably Perfused,” or “Under Perfused.” Relative values were selected to allow linear scaling of images despite potential variation in working distances, laser power, or patient-specific factors, allowing for between-patient comparisons.<sup>17</sup> The ROI, RI, and RA values were evaluated for association with complication outcomes of interest for all annotated flap images.

### Statistical Analysis

Study data were collected and managed using REDCap electronic data capture tools hosted at the University of Wisconsin-Madison. All statistical analyses were performed using IBM SPSS Statistics Version 28 (IBM Corp., Armonk, NY). The statistical significance level was defined as  $p < 0.05$ . Categorical data were described as frequencies and percentages. Normally distributed data were reported as means and standard deviations, while nonnormally distributed data were reported as medians and interquartile ranges. Patient and operative variables were compared with collected OnLume Avata image values (ROI, RI, and RA) for all labeled areas between patients who did and did not experience a complication. This was performed using Chi-squared testing for comparison of proportions and independent sample  $t$ -test for continuous measures. Univariable logistic regression was performed to examine the association of RI and RA with primary outcomes of interest. No statistical corrections for multiple comparisons were used.

## Results

### Patient Characteristics

A total of 25 patients were recruited for this prospective study. The average age was  $49.4 (\pm 9.7)$  years, with a mean body mass index of  $31.3 (\pm 3.4)$  at the time of surgery. Most patients were never smokers ( $n = 20, 80.0\%$ ), followed by former smokers ( $n = 3, 12.0\%$ ) and current smokers ( $n = 2, 8.0\%$ ). Five (20.0%) patients had a prior history of breast cancer, and 17 (68.0%) patients had a current diagnosis of

breast cancer, with ductal carcinoma in situ and invasive ductal carcinoma being the most common diagnosis ( $n = 7, 41.2\%$  and  $n = 7, 41.2\%$ , respectively). Hormone therapy was the most common medical therapy received by patients ( $n = 10, 40\%$ ) (► **Table 1**).

### Operative Details

The majority of patients underwent immediate ( $n = 16, 64.0\%$ ), bilateral breast reconstruction ( $n = 20, 80\%$ ), with a total of 45 DIEP flaps (right-sided flap:  $n = 21$ , left-sided flap,  $n = 24$ ) being performed. The average mastectomy weights were  $958.8 (\pm 349.2)$  grams from the right breast and  $898.0 (\pm 278.6)$  grams from the left breast. During surgery, the average number of perforators harvested per flap was  $2.35 (\pm 0.75)$  on the right flap and  $2.04 (\pm 0.56)$  on the left flap. One right flap (4.8%) and one left flap (4.2%) required arterial anastomosis revision before fluorescence imaging was performed. The average operative time was  $543.3 (\pm 85.5)$  minutes. The mean length of follow-up was  $6.8 (\pm 2.7)$  months (► **Table 2**).

### Postoperative Complication and Revision Rates

Seventeen patients (68.0%) developed postoperative complications, with the most common complication being fat necrosis for both the right and left reconstructed breasts (right:  $n = 9, 37.5\%$ , left:  $n = 5, 23.8\%$ ). Eleven patients (44.0%) required complication-related surgical revision (► **Table 3**). There was no significant difference in patient or operative characteristics between patients who developed complications and those who did not (► **Tables 4** and **5**).

### Reconstructed DIEP Flap—Comparison of Relative Intensities and Areas to Complications

Regarding primary outcomes of interest, patients who developed any complication ( $RI = 0.20 \pm 0.01$  vs.  $0.32 \pm 0.04$ ,  $p = 0.02$ ) or underwent complication-related surgical revision ( $RI = 0.20 \pm 0.01$  vs.  $0.32 \pm 0.04$ ,  $p = 0.02$ ) demonstrated a significantly lower RI for areas of the reconstructed DIEP flap considered to be “Under Perfused.” No significant

**Table 1** Patient characteristics

Variable	( <i>n</i> <sub>total</sub> = 25)
Age, y (SD)	49.4 (9.7)
BMI at surgery, kg/m <sup>2</sup> (SD)	31.3 (3.4)
History of smoking, <i>n</i> (%)	
Never	20 (80.0)
Former	3 (12.0)
Current	2 (8.0)
Past medical history, <i>n</i> (%)	
Hypertension	0 (0)
Diabetes mellitus	0 (0)
Cardiovascular disease	2 (8.0)
Respiratory disease	1 (4.0)
Bleeding or clotting coagulopathy	0 (0) 0 (0)
History of prior breast surgery, <i>n</i> (%)	
Yes	13 (52.0)
No	12 (48.0)
Prior history of breast cancer, <i>n</i> (%)	
Yes	5 (20.0)
No	20 (80.0)
Current cancer diagnosis, <i>n</i> (%)	
Yes	17 (68.0)
DCIS	7 (41.2)
LCIS	1 (5.9)
IDC	7 (41.2)
ILC	0 (0)
TNBC	1 (5.9)
IBC	0 (0)
Not reported	1 (5.9)
No	8 (32.0)
Medical therapy, <i>n</i> (%)	
Neoadjuvant chemotherapy	6 (24.0)
Neoadjuvant radiation	3 (12.0)
Adjuvant chemotherapy	4 (16.0)
Adjuvant radiation	2 (8.0)
Hormone therapy	10 (40.0)

Abbreviations: DCIS, ductal carcinoma in situ; IBC, inflammatory breast cancer; IDC, invasive ductal carcinoma; ILC, invasive lobular carcinoma; LCIS, lobular carcinoma in situ; SD, standard deviation; TNBC, triple negative breast cancer.

difference was appreciated between RIs and the development of fat necrosis in any of the labeled areas. Regarding secondary complication outcomes, patients who developed epidermolysis had a significantly lower ROI ( $0.51 \pm 0.21$  vs.  $0.69 \pm 0.14$ ,  $p = 0.02$ ) of all labeled areas. Patients who developed incisional dehiscence demonstrated both a significantly lower ROI of all labeled areas ( $0.44 \pm 0.09$

**Table 2** Operative characteristics

Variable	( <i>n</i> <sub>total</sub> = 25)
Timing of reconstruction, <i>n</i> (%)	
Immediate	16 (64.0)
Delayed	9 (36.0)
Laterality of reconstruction, <i>n</i> (%)	
Unilateral	5 (20.0)
Right	4 (16.0)
Left	1 (4.0)
Bilateral	20 (80.0)
Mastectomy weight, mean (SD)	
Right, g ( <i>n</i> = 24)	958.8 (349.2)
Left, g ( <i>n</i> = 21)	898.0 (278.6)
Number of perforators harvested per flap, mean (SD)	
Right flap ( <i>n</i> = 21)	2.35 (0.75)
Left flap ( <i>n</i> = 24)	2.04 (0.56)
Immediate revision of artery, <i>n</i> (%)	
Right flap ( <i>n</i> = 21)	1 (4.8)
Left flap ( <i>n</i> = 24)	1 (4.2)
Immediate revision of vein, <i>n</i> (%)	
Right flap ( <i>n</i> = 21)	0 (0)
Left flap ( <i>n</i> = 24)	0 (0)
Operative time (min), mean (SD)	543.3 (85.5)
Follow-up duration (m), mean (SD)	6.8 (2.7)

Abbreviations: min, minute; m, month.

vs.  $0.69 \pm 0.12$ ,  $p = 0.009$ ) and RI ( $0.58 \pm 0.04$  vs.  $0.75 \pm 0.10$ ,  $p = 0.02$ ) of “Well Perfused” areas (► **Table 6**).

No significant differences in RA were appreciated for the primary outcomes of interest; however, patients who experienced epidermolysis had a significantly smaller area considered to be “Well Perfused” ( $0.24 \pm 0.33$  vs.  $0.78 \pm 0.33$ ,  $p = 0.002$ ) and a larger area of “Questionably Perfused” ( $0.66 \pm 0.46$  vs.  $0.19 \pm 0.30$ ,  $p = 0.005$ ) reconstructed DIEP flap (► **Table 7**).

### Mastectomy Skin—Comparison of Relative Intensities and Areas to Complications

Patients with a lower RI within areas of the mastectomy skin flap considered to be “Questionably Perfused” ( $0.47 \pm 0.15$  vs.  $0.65 \pm 0.01$ ,  $p < 0.001$ ) or “Under Perfused” ( $0.29 \pm 0.07$  vs.  $0.36 \pm 0.04$ ,  $p < 0.001$ ) were more likely to require complication-related surgical revision. No significant difference between RIs and the development of mastectomy flap necrosis or overall complications in any labeled areas was appreciated. Patients with a lower RI of “Well Perfused” mastectomy skin had a greater likelihood of developing epidermolysis ( $0.67 \pm 0.04$  vs.  $0.76 \pm 0.12$ ,  $p = 0.02$ ) (► **Table 8**). No significant differences in RA were appreciated for the primary or secondary outcomes of interest (► **Table 9**).

**Table 3** Postoperative complication and revision rates

Variable	n (%)
Overall complication rate ( $n_{\text{total}} = 25$ )	17 (68.0)
Right breast complications ( $n_{\text{total}} = 24$ )	
Overall complication rate	13 (54.2)
Fat necrosis	9 (37.5)
Incisional dehiscence	2 (8.3)
Epidermolysis	3 (12.5)
Infection	0 (0)
Seroma	0 (0)
Hematoma	0 (0)
Partial flap loss	1 (4.2)
Total flap loss	0 (0)
Mastectomy skin necrosis	5 (20.8)
Left breast complications ( $n_{\text{total}} = 21$ )	
Overall complication rate	10 (47.6)
Fat necrosis	5 (23.8)
Incisional dehiscence	2 (9.5)
Epidermolysis	3 (14.3)
Infection	2 (9.5)
Seroma	1 (4.8)
Hematoma	1 (4.8)
Partial flap loss	0 (0)
Total flap loss	0 (0)
Mastectomy skin necrosis	1 (4.8)
Surgical revisions ( $n_{\text{total}} = 25$ )	
Overall revision rate	21 (84.0)
Complication-related revision	11 (44.0)
Fat necrosis	9 (36.0)
Incisional dehiscence	1 (4.0)
Partial flap loss	1 (4.0)
Mastectomy skin flap debridement	4 (16.0)
Cosmetic-related revision	10 (40.0)
Number of revisions, mean (SD)	1.29 (0.64)

Abbreviation: SD, standard deviation.

### Risk of Complications Based on Perfusion of Reconstructed DIEP and Mastectomy Skin Flaps

Univariable regression analysis revealed that increasing RAs of “Under Perfused” reconstructed DIEP flaps were significantly associated with the development of postoperative fat necrosis (odds ratio [OR]: 5.71, 95% confidence interval [CI]: 0.02–1347.6,  $p = 0.03$ ) and needing a complication-related surgical revision (OR: 1.10, 95% CI: 0.01–3.5,  $p = 0.01$ ). There was no significant association between the RIs of the reconstructed DIEP flap and our outcomes of interest (► **Tables 10** and **11**). Additionally, no significant associations were demonstrated for RIs or RAs of mastectomy skin flap and outcomes of interest (► **Tables 12** and **13**).

## Discussion

In this pilot study, we performed a prospective clinical trial utilizing the novel, ambient light-compatible OnLume Avata System to collect objective tissue perfusion values in cases of autologous breast reconstruction to assist in predicting postoperative complications. We demonstrated that patients who developed complications ( $p = 0.02$ ) or required complication-related revision surgery ( $p = 0.02$ ) had a lower average RI of their reconstructed DIEP flap in areas concerning for hypoperfusion or ischemia. Those with larger areas of “Under Perfused” flap had a significantly higher risk of developing fat necrosis (OR: 5.71, 95% CI: 0.02–1347.6,  $p = 0.03$ ) and needing a revision operation ( $p = 1.10$ , 95% CI: 0.01–3.5,  $p = 0.01$ ). Furthermore, the development of complications was not associated with any other patient or operative variables. These findings emphasize that objective fluorescence values could be utilized to improve perfusion assessment and intraoperative clinical decision-making if developed into a real-time tool available for surgeons.

While historically, clinical examination was utilized to predict mastectomy skin and autologous flap viability, implementation of ICG angiography has been found to be highly sensitive and specific in evaluating vascular patency and tissue ischemia in breast reconstruction.<sup>2,4,6,18–22</sup> In a study of 20 skin-sparing mastectomy flaps comparing ICG angiography and clinical judgment to predict skin necrosis, ICG was found to be 100% sensitive and 91% specific at identification of necrosis, with nine breasts developing wound-healing complications.<sup>23</sup>

These correlations between intraoperative findings and clinical outcomes have ultimately led to the use of ICG technology to aid in reducing the rates of postoperative complications and revision operations and to improve patient satisfaction.<sup>24,25</sup> A recent analysis of ICG angiography usage in breast reconstruction by Chattha et al, utilizing the Healthcare Cost and Utilization Project National Inpatient Sample database, identified a significant increase in its implementation ( $p < 0.001$ ) in the last decade, particularly in high-risk patients undergoing autologous breast reconstruction.<sup>26</sup> Regarding ischemic complications in reconstructed DIEP flaps, Komorowska-Timek and Gurtner used ICG angiography in 24 breast reconstruction cases. They found a significant reduction in complication rates compared with a similar cohort of patients on whom ICG was not used (4% from 15%,  $p < 0.01$ ).<sup>6</sup> Similarly, intraoperative use of ICG angiography has been shown to reduce partial flap loss and necrosis rates.<sup>27,28</sup>

Recently, investigation has turned to intraoperative fluorescence-guided flap excision, as perfusion-related complications, such as fat necrosis, can dramatically compromise the ultimate result of autologous breast reconstruction.<sup>29,30</sup> While Hembd et al demonstrated a significant reduction in postoperative fat necrosis ( $p = 0.004$ ), the risk of fat necrosis was not eliminated. Any patient who developed fat necrosis, with or without ICG angiography, required, on average, 0.69 additional procedures, 1.22 imaging studies, and 1.7 additional oncologic office visits.<sup>31</sup>

**Table 4** Patient characteristics associated with complications

Variable	Complications ( $n_{\text{total}} = 17$ )	No complications ( $n_{\text{total}} = 8$ )	<i>p</i> -Value
Age, y (SD)	49.1 (9.9)	50.0 (9.9)	0.83
BMI at surgery, kg/m <sup>2</sup> (SD)	31.4 (3.9)	30.9 (2.4)	0.73
History of smoking, <i>n</i> (%)			
Never	13 (76.5)	7 (87.5)	0.60
Former	2 (11.8)	1 (12.5)	
Current	2 (11.8)	0	
Past medical history, <i>n</i> (%)			
Hypertension	–	–	–
Diabetes mellitus	–	–	–
Cardiovascular disease	1 (5.9)	1 (12.5)	0.55
Respiratory disease	1 (5.9)	0 (0.0)	0.68
Bleeding or clotting	–	–	–
Coagulopathy	–	–	–
History of prior breast surgery, <i>n</i> (%)	8 (47.1)	5 (62.5)	0.67
Prior history of breast cancer, <i>n</i> (%)	3 (17.6)	2 (25.0)	0.53
Current cancer diagnosis, <i>n</i> (%)	12 (70.5)	5 (62.5)	0.51
Medical therapy, <i>n</i> (%)			
Neoadjuvant chemotherapy	5 (29.4)	1 (12.5)	0.35
Neoadjuvant radiation	3 (17.6)	0 (0.0)	0.30
Adjuvant chemotherapy	3 (17.6)	1 (12.5)	0.62
Adjuvant radiation	2 (11.8)	0 (0.0)	0.45
Hormone therapy	8 (47.1)	2 (25.0)	0.27

Abbreviations: BMI, body mass index; SD, standard deviation.

Note: Statistically significant:  $p < 0.05$ .

**Table 5** Operative characteristics associated with complications

Variable	Complications ( $n_{\text{total}} = 17$ )	No complications ( $n_{\text{total}} = 8$ )	<i>p</i> -Value
Timing of reconstruction, <i>n</i> (%)			
Immediate	10 (58.8)	6 (75.0)	0.37
Delayed	7 (41.2)	2 (25.0)	0.66
Laterality of reconstruction, <i>n</i> (%)			
Unilateral	2 (11.8)	3 (37.5)	0.17
Bilateral	15 (88.2)	5 (62.5)	0.28
Mastectomy weight, mean (SD)			
Right	992.6 (381.5)	864.2 (245.7)	0.49
Left	937.6 (295.3)	795.0 (223.6)	0.35
Number of perforators harvested per flap, mean (SD)			
Right flap ( $n = 21$ )	2.4 (0.76)	2.2 (0.75)	0.49
Left flap ( $n = 24$ )	2.0 (0.52)	2.14 (0.69)	0.59
Operative time (min), mean (SD)	549.5 (76.2)	530.1 (107.2)	0.61

Abbreviations: min, minute; SD, standard deviation.

Note: Statistically significant:  $p < 0.05$ .

**Table 6** Comparison of average relative intensities between complication and no complication groups (reconstructed DIEP flap)

Complication	Complication (mean ± SD)	No complication (mean ± SD)	p-Value
Overall complications			
Relative overall intensity	0.65 (0.18)	0.70 (0.15)	0.36
Well perfused	0.74 (0.12)	0.73 (0.09)	0.79
Questionably perfused	0.44 (0.23)	0.54 (0.20)	0.32
<b>Under perfused</b>	<b>0.20 (0.01)</b>	<b>0.32 (0.04)</b>	<b>0.02<sup>a</sup></b>
Fat necrosis			
Relative overall intensity	0.62 (0.15)	0.70 (0.15)	0.19
Well perfused	0.71 (0.08)	0.75 (0.11)	0.32
Questionably perfused	0.41 (0.22)	0.55 (0.21)	0.13
Under perfused	0.32 (0.05)	0.25 (0.08)	0.27
Incisional dehiscence			
<b>Relative overall intensity</b>	<b>0.44 (0.09)</b>	<b>0.69 (0.12)</b>	<b>0.009<sup>a</sup></b>
<b>Well perfused</b>	<b>0.58 (0.04)</b>	<b>0.75 (0.10)</b>	<b>0.02<sup>a</sup></b>
Questionably perfused	0.27 (0.07)	0.51 (0.22)	0.17
Under perfused	–	0.29 (0.07)	–
Epidermolysis			
<b>Relative overall intensity</b>	<b>0.51 (0.21)</b>	<b>0.69 (0.14)</b>	<b>0.02<sup>a</sup></b>
Well perfused	0.74 (0.01)	0.74 (0.11)	0.92
Questionably perfused	0.44 (0.26)	0.50 (0.22)	0.67
Under perfused	0.33 (0.02)	0.26 (0.08)	0.37
Infection			
Relative overall intensity	0.60 (0.01)	0.67 (0.17)	0.56
Well perfused	0.62 (0.02)	0.74 (0.10)	0.10
Questionably perfused	0.29 (0.0)	0.50 (0.22)	0.36
Under perfused	–	0.29 (0.07)	–
Seroma			
Relative overall intensity	0.61 (0.0)	0.67 (0.17)	0.69
Well perfused	0.61 (0.0)	0.74 (0.10)	0.20
Questionably perfused	–	0.48 (0.22)	–
Under perfused	–	0.29 (0.07)	–
Hematoma			
Relative overall intensity	–	0.67 (0.16)	–
Well perfused	–	0.74 (0.10)	–
Questionably perfused	–	0.49 (0.22)	–
Under perfused	–	0.29 (0.07)	–
Partial flap loss			
Relative overall intensity	0.59 (0.0)	0.67 (0.17)	0.63
Well perfused	0.78 (0.0)	0.74 (0.10)	0.63
Questionably perfused	0.60 (0.0)	0.36 (0.22)	0.60
Under perfused	0.27 (0.0)	0.33 (0.08)	0.86
Total flap loss			
Relative overall intensity	–	0.67 (0.16)	–
Well perfused	–	0.74 (0.10)	–



**Table 6** (Continued)

Complication	Complication (mean ± SD)	No complication (mean ± SD)	p-Value
Questionably perfused	–	0.49 (0.22)	–
Under perfused	–	0.29 (0.07)	–
Complication-related surgical revision			
Relative overall intensity	0.69 (0.16)	0.57 (0.17)	0.13
Well perfused	0.73 (0.10)	0.70 (0.06)	0.57
Questionably perfused	0.49 (0.24)	0.43 (0.12)	0.62
<b>Under perfused</b>	<b>0.20 (0.01)</b>	<b>0.32 (0.04)</b>	<b>0.02<sup>a</sup></b>

Abbreviation: DIEP, deep inferior epigastric artery; SD, standard deviation.

<sup>a</sup>Statistically significant ( $p < 0.05$ ) values are indicated in bold.

**Table 7** Comparison of average relative area between complication and no complication groups (reconstructed DIEP flap)

Complication	Complication (mean ± SD)	No complication (mean ± SD)	p-Value
Overall complications			
Well perfused	0.62 (0.41)	0.81 (0.32)	0.12
Questionably perfused	0.34 (0.40)	0.16 (0.26)	0.10
Under perfused	0.04 (0.10)	0.03 (0.40)	0.90
Fat necrosis			
Well perfused	0.65 (0.35)	0.74 (0.39)	0.44
Questionably perfused	0.30 (0.35)	0.23 (0.36)	0.53
Under perfused	0.05 (0.13)	0.03 (0.11)	0.53
Incisional dehiscence			
Well perfused	0.50 (0.50)	0.73 (0.37)	0.32
Questionably perfused	0.50 (0.50)	0.23 (0.34)	0.21
Under perfused	0.0 (0.0)	0.04 (0.12)	0.60
Epidermolysis			
<b>Well perfused</b>	<b>0.24 (0.33)</b>	<b>0.78 (0.33)</b>	<b>0.002<sup>a</sup></b>
<b>Questionably perfused</b>	<b>0.66 (0.46)</b>	<b>0.19 (0.30)</b>	<b>0.005<sup>a</sup></b>
Under perfused	0.10 (0.19)	0.03 (0.10)	0.18
Infection			
Well perfused	0.95 (0.07)	0.69 (0.38)	0.36
Questionably perfused	0.05 (0.07)	0.27 (0.36)	0.40
Under perfused	–	0.04 (0.12)	–
Seroma			
Well perfused	1.00 (0.0)	0.70 (0.38)	0.44
Questionably perfused	–	0.26 (0.35)	–
Under perfused	–	0.04 (0.12)	–
Hematoma			
Well perfused	–	0.71 (0.37)	–
Questionably perfused	–	0.25 (0.35)	–
Under perfused	–	0.03 (0.11)	–
Partial flap loss			
Well perfused	0.36 (0.0)	0.72 (0.37)	0.35
Questionably perfused	0.41 (0.0)	0.25 (0.36)	0.65

(Continued)

**Table 7** (Continued)

Complication	Complication (mean ± SD)	No complication (mean ± SD)	p-Value
Under perfused	0.23 (0.0)	0.03 (0.11)	0.09
Total flap loss			
Well perfused	–	0.71 (0.37)	–
Questionably perfused	–	0.25 (0.35)	–
Under perfused	–	0.03 (0.11)	–
Complication-related surgical revision			
Well perfused	0.74 (0.35)	0.51 (0.49)	0.21
Questionably perfused	0.23 (0.35)	0.37 (0.41)	0.23
Under perfused	0.02 (0.08)	0.12 (0.25)	0.07

Abbreviations: DIEP, deep inferior epigastric artery; SD, standard deviation.

<sup>a</sup>Statistically significant ( $p < 0.05$ ) values are indicated in bold.

**Table 8** Comparison of average relative intensities between complication and no complication groups (mastectomy skin)

Complication	Complication (mean ± SD)	No complication (mean ± SD)	p-Value
Overall complications			
Relative overall intensity	0.59 (0.15)	0.59 (0.14)	0.98
Well perfused	0.75 (0.12)	0.73 (0.12)	0.68
Questionably perfused	0.47 (0.12)	0.51 (0.19)	0.88
Under perfused	0.30 (0.06)	0.31 (0.08)	0.59
Incisional dehiscence			
Relative overall intensity	–	0.59 (0.14)	–
Well perfused	–	0.73 (0.11)	–
Questionably perfused	–	0.49 (0.07)	–
Under perfused	–	0.31 (0.16)	–
Epidermolysis			
Relative overall intensity	0.56 (0.02)	0.60 (0.15)	0.26
Well perfused	<b>0.67 (0.04)</b>	<b>0.76 (0.12)</b>	<b>0.02<sup>a</sup></b>
Questionably perfused	0.48 (0.08)	0.49 (0.17)	0.92
Under perfused	0.27 (0.01)	0.32 (0.08)	0.36
Infection			
Relative overall intensity	–	0.59 (0.14)	–
Well perfused	–	0.74 (0.12)	–
Questionably perfused	–	0.49 (0.16)	–
Under perfused	–	0.31 (0.07)	–
Seroma			
Relative overall intensity	–	0.59 (0.14)	–
Well perfused	–	0.74 (0.12)	–
Questionably perfused	–	0.49 (0.16)	–
Under perfused	–	0.31 (0.07)	–
Hematoma			
Relative overall intensity	–	0.59 (0.14)	–
Well perfused	–	0.74 (0.12)	–

**Table 8** (Continued)

Complication	Complication (mean ± SD)	No complication (mean ± SD)	p-Value
Questionably perfused	–	0.49 (0.16)	–
Under perfused	–	0.31 (0.07)	–
Mastectomy flap necrosis			
Relative overall intensity	0.55 (0.20)	0.60 (0.13)	0.49
Well perfused	0.85 (0.11)	0.73 (0.11)	0.08
Questionably perfused	0.49 (0.12)	0.49 (0.17)	0.98
Under perfused	0.35 (0.06)	0.29 (0.07)	0.28
Complication-related surgical revision			
Relative overall intensity	0.59 (0.15)	0.62 (0.03)	0.36
Well perfused	0.74 (0.12)	0.70 (0.0)	0.77
<b>Questionably perfused</b>	<b>0.47 (0.15)</b>	<b>0.65 (0.01)</b>	<b>&lt;0.001<sup>a</sup></b>
<b>Under perfused</b>	<b>0.29 (0.07)</b>	<b>0.36 (0.04)</b>	<b>&lt;0.001<sup>a</sup></b>

Abbreviation: SD, standard deviation.

<sup>a</sup>Statistically significant ( $p < 0.05$ ) values are indicated in bold.**Table 9** Comparison of average relative area between complication and no complication groups (mastectomy skin)

Complication	Complication (mean ± SD)	No complication (mean ± SD)	p-Value
Overall complications			
Well perfused	0.41 (0.36)	0.37 (0.30)	0.77
Questionably perfused	0.53 (0.38)	0.51 (0.39)	0.84
Under perfused	0.05 (0.11)	0.11 (0.22)	0.30
Incisional dehiscence			
Well perfused	–	0.39 (0.33)	–
Questionably perfused	–	0.53 (0.38)	–
Under perfused	–	0.08 (0.17)	–
Epidermolysis			
Well perfused	0.52 (0.31)	0.37 (0.33)	0.43
Questionably perfused	0.36 (0.42)	0.55 (0.18)	0.35
Under perfused	0.12 (0.18)	0.07 (0.16)	0.60
Infection			
Well perfused	–	0.39 (0.33)	–
Questionably perfused	–	0.53 (0.38)	–
Under perfused	–	0.08 (0.17)	–
Seroma			
Well perfused	–	0.39 (0.33)	–
Questionably perfused	–	0.53 (0.38)	–
Under perfused	–	0.08 (0.17)	–
Hematoma			
Well perfused	–	0.39 (0.33)	–
Questionably perfused	–	0.53 (0.38)	–
Under perfused	–	0.08 (0.17)	–
Mastectomy fat necrosis			

(Continued)

**Table 9** (Continued)

Complication	Complication (mean ± SD)	No complication (mean ± SD)	p-Value
Well perfused	0.17 (0.33)	0.44 (0.31)	0.09
Questionably perfused	0.79 (0.32)	0.47 (0.37)	0.08
Under perfused	0.04 (0.08)	0.09 (0.18)	0.55
Complication-related surgical revision			
Well perfused	0.41 (0.33)	0.14 (0.21)	0.28
Questionably perfused	0.51 (0.39)	0.72 (0.15)	0.47
Under perfused	0.08 (0.17)	0.14 (0.06)	0.65

Abbreviation: SD, standard deviation.

Note: Statistically significant:  $p < 0.05$ .

**Table 10** Univariable logistic regression examining risk of complications based on relative intensity (reconstructed DIEP flap)

	OR	95% CI	p-Value
Overall complications			
Relative overall intensity	0.15	0.003–8.2	0.35
Well perfused	2.6	0.003–2,392.3	0.78
Questionably perfused	0.12	0.002–6.8	0.31
Under perfused	–	–	–
Fat necrosis			
Relative overall intensity	0.06	0.001–4.0	0.19
Well perfused	0.02	0.0–42.4	0.31
Questionably perfused	0.03	0.0–3.2	0.14
Under perfused	45.0	0.0–62.1	0.23
Complication-related surgical revision			
Relative overall intensity	67.6	0.26–17,571.0	0.14
Well perfused	53.1	0.0–3,347.5	0.56
Questionably perfused	4.4	0.02–1,120.2	0.60
Under perfused	–	–	–

Abbreviations: CI, confidence interval; DIEP, deep inferior epigastric artery; OR, odds ratio.

Note: Statistically significant:  $p < 0.05$ .

The persistent development of fat necrosis and other ischemic complications despite intraoperative ICG angiography highlights the need for continued investigation into fluorescence technology. Our results highlight this, where 31.1% of flaps developed fat necrosis despite resection based on standard-of-care fluorescence imaging and clinical evaluation. A significant challenge surgeons face is the consistent interpretation of perfusion, given that standardization in current fluorescence imaging systems is lacking. As a result, most studies evaluating the efficacy of ICG imaging in autologous breast reconstruction fail to provide objective perfusion values that can assist surgeons in understanding fluorescence images.<sup>4,5</sup> We demonstrate that by utilizing fluorescence technology that employs reproducible image quantitation, the collection and measurement of RI and RA values provide critical information on “Under Perfused” areas of the reconstructed flap that are at a higher likelihood

of developing fat necrosis and subsequently require a revision operation. Furthermore, given that this technology is performed under ambient light, spatial information in the flaps allows for precise localization during excision.

We acknowledge the necessity for a more detailed comparative analysis of the OnLume Avata System against existing technologies such as SPY Elite and the Mitaka PDE Gen3 system, which is an anticipated future investigation. The SPY Elite system was the first FGS to be approved by the FDA in 2005 and has revolutionized fluorescence-guided imaging, but nevertheless, suffers from the disadvantage of having an “always-on” probe, which emits signal regardless of proximity or interaction with target tissues, leading to impaired usability.<sup>32</sup> Alternatively, the Mitaka PDE Gen3 is recognized for its ergonomic, handheld design and significantly lower cost, with a total cost of \$76,805 compared with SPY Elites cost of \$275,275, but does not allow for real-time image

**Table 11** Univariable logistic regression examining risk of complications based on relative area (reconstructed DIEP flap)

	OR	95% CI	p-Value
Overall complications			
Well perfused	0.23	0.04–1.5	0.12
Questionably perfused	5.33	0.67–42.3	0.11
Under perfused	1.46	0.006–337.6	0.89
Fat necrosis			
Well perfused	0.50	0.09–2.79	0.43
Questionably perfused	1.81	0.29–11.3	0.52
<b>Under perfused</b>	<b>5.71</b>	<b>0.02–1,347.6</b>	<b>0.03<sup>a</sup></b>
Complication-related surgical revision			
Well perfused	4.20	0.43–41.5	0.21
Questionably perfused	0.40	0.04–4.4	0.45
<b>Under perfused</b>	<b>1.10</b>	<b>0.01–3.5</b>	<b>0.01<sup>a</sup></b>

Abbreviations: CI, confidence interval; DIEP, deep inferior epigastric artery; OR, odds ratio.

<sup>a</sup>Statistically significant ( $p < 0.05$ ) values are indicated in bold.

**Table 12** Univariable logistic regression examining risk of complications based on relative intensity (mastectomy skin)

	OR	95% CI	p-Value
Overall complications			
Relative overall intensity	1.07	0.006–186.9	0.98
Well perfused	5.1	0.004–7,307.4	0.66
Questionably perfused	0.20	0.001–37.5	0.55
Under perfused	0.23	0.0–3,425.30	0.86
Mastectomy flap necrosis			
Relative overall intensity	0.05	0.0–175.3	0.48
Well perfused	16.2	0.13–1,969.2	0.10
Questionably perfused	1.07	0.002–636.8	0.98
Under perfused	51.2	0.0–4,610.2	0.26
Complication-related surgical revision			
Relative overall intensity	0.22	0.0–2,731.0	0.75
Well perfused	23.0	0.0–1,135.1	0.76
Questionably perfused	0.001	0.0–13.8	0.15
Under perfused	–	–	–

Abbreviations: CI, confidence interval; OR, odds ratio.

Note: Statistically significant:  $p < 0.05$ .

overlay.<sup>32,33</sup> Alternatively, the OnLume Avata System is able to produce high-resolution, real-time imaging without the need for environmental modifications. Its unique features significantly enhance its clinical utility, eliminating the need for special lighting conditions, which can disrupt surgical procedures and extend operation times. Moreover, it offers advanced imaging capabilities that enable more precise visualization of tissue perfusion, a crucial factor in high-stakes surgical procedures. As a result, it has the potential to

lead to improved patient outcomes by empowering surgeons to make more informed decisions regarding tissue viability and surgical margins. Future investigation is anticipated, with plans to analyze outcome differences in those who undergo standard-of-care ICG angiography versus the OnLume Avata System with the implementation of RI fluorescence thresholds.

We recognize the limitations of our current study, the foremost being the small sample size; however, the proposed

**Table 13** Univariable logistic regression examining risk of complications based on relative area (mastectomy skin)

	OR	95% CI	p-Value
Overall complications			
Well perfused	1.42	0.15–13.8	0.76
Questionably perfused	1.24	0.17–8.8	0.83
Under perfused	0.07	0.0–12.6	0.32
Mastectomy flap necrosis			
Well perfused	0.40	0.001–2.2	0.12
Questionably perfused	15.8	0.54–464.4	0.10
Under perfused	0.06	0.0–668.7	0.55
Complication-related surgical revision			
Well perfused	28.1	0.04–1,817.3	0.31
Questionably perfused	0.20	0.002–15.7	0.47
Under perfused	0.20	0.0–169.9	0.64

Abbreviations: CI, confidence interval; OR, odds ratio.  
Note: Statistically significant:  $p < 0.05$ .

sample number was calculated using power analyses. Additionally, our findings are not compared with other noninvasive ICG imaging techniques, as this pilot study aimed to determine if objective relative values demonstrated any meaningful difference in patients who did and did not develop complications. Another study limitation is that one surgeon operated and captured the intraoperative images, whereas a different blinded surgeon completed postoperative annotations. Although this study design ensures the interpretation is unbiased between capture and analysis, the visualization settings are subject to surgeon preference in the operating room despite trying to standardize image capture between subjects. We also recognize that not all complications are attributable to ischemia. With future optimization and validation in large populations with comparison to a control group, implementation of RI and RA measurements utilizing ambient-light compatible technology may ultimately be used for perioperative assessment of autologous breast reconstruction vascular perfusion to prevent tissue necrosis and subsequent complications.

## Conclusions

The real-time qualitative assessment of tissue perfusion during autologous breast reconstruction further augmented by quantitative assessment with RI and RA utilizing the ambient-light compatible OnLume Avata System can help predict the risk of developing postoperative complications that standard fluorescence imaging systems may not appreciate due to the variability of interpretation. Patients who demonstrate a larger area of under-perfused flap are at higher risk of developing fat necrosis and needing a revision operation. This information can benefit surgeons and patients in assisting with postoperative management and counseling.

## IRB Approval

This study was approved by the Institutional Review Board under protocol number 2020–0906.

## Funding

This study received National Institutes of Health (NIH) grant funding (Project ID: IDAAI6254, Reference number: K20–001). The research reported was supported by the National Cancer Institute of the NIH under award numbers R43CA206754 and R44CA206754.

Authors Dr. Shaffrey, Mr. Moura, Dr. Seitz, and Dr. Poore have nothing to disclose. Authors Sydney Jupitz, Ph.D., Trevor Seets, MS, Tisha Kawahara, MS, Adam Uselmann, Ph.D., and Christie Lin, Ph.D. are employed by OnLume Surgical.

OnLume Inc. is located in Madison, Wisconsin, however, is not directly affiliated with the University of Wisconsin-Madison.

## References

- Saldanha JJ, Broyles JM, Adam GP, et al. Autologous breast reconstruction after mastectomy for breast cancer: a systematic review. *Plast Reconstr Surg Glob Open* 2022;10(03):E4181
- Phillips BT, Lanier ST, Conkling N, et al. Intraoperative perfusion techniques can accurately predict mastectomy skin flap necrosis in breast reconstruction: results of a prospective trial. *Plast Reconstr Surg* 2012;129(05):778e–788e
- Matsen CB, Mehrara B, Eaton A, et al. Skin flap necrosis after mastectomy with reconstruction: a prospective study. *Ann Surg Oncol* 2016;23(01):257–264
- Moyer HR, Losken A. Predicting mastectomy skin flap necrosis with indocyanine green angiography: the gray area defined. *Plast Reconstr Surg* 2012;129(05):1043–1048
- Munabi NCO, Olorunnipa OB, Goltsman D, Rohde CH, Ascherman JA. The ability of intra-operative perfusion mapping with laser-assisted indocyanine green angiography to predict mastectomy flap necrosis in breast reconstruction: a prospective trial. *J Plast Reconstr Aesthet Surg* 2014;67(04):449–455

- 6 Komorowska-Timek E, Gurtner GC. Intraoperative perfusion mapping with laser-assisted indocyanine green imaging can predict and prevent complications in immediate breast reconstruction. *Plast Reconstr Surg* 2010;125(04):1065–1073
- 7 Nassar AH, Maselli AM, Manstein S, et al. Comparison of various modalities utilized for preoperative planning in microsurgical reconstructive surgery. *J Reconstr Microsurg* 2022;38(03):170–180
- 8 Francisco BS, Kerr-Valentic MA, Agarwal JP. Laser-assisted indocyanine green angiography and DIEP breast reconstruction. *Plast Reconstr Surg* 2010;125(03):116e–118e
- 9 Gorai K, Inoue K, Saegusa N, et al. Prediction of skin necrosis after mastectomy for breast cancer using indocyanine green angiography imaging. *Plast Reconstr Surg Glob Open* 2017;5(04):e1321
- 10 Mazdeyasna S, Huang C, Paranzino AB, et al. Intraoperative optical and fluorescence imaging of blood flow distributions in mastectomy skin flaps for identifying ischemic tissues. *Plast Reconstr Surg* 2022;150(02):282–287
- 11 Mattison GL, Lewis PG, Gupta SC, Kim HY. SPY imaging use in postmastectomy breast reconstruction patients: preventative or overly conservative? *Plast Reconstr Surg* 2016;138(01):15e–21e
- 12 Parmeshwar N, Sultan SM, Kim EA, Piper ML. A systematic review of the utility of indocyanine angiography in autologous breast reconstruction. *Ann Plast Surg* 2021;86(05):601–606
- 13 Lauritzen E, Damsgaard TE. Use of Indocyanine Green Angiography decreases the risk of complications in autologous- and implant-based breast reconstruction: a systematic review and meta-analysis. *J Plast Reconstr Aesthet Surg* 2021;74(08):1703–1717
- 14 Bigdeli AK, Thomas B, Falkner F, Gazyakan E, Hirche C, Kneser U. The impact of indocyanine-green fluorescence angiography on intraoperative decision-making and postoperative outcome in free flap surgery. *J Reconstr Microsurg* 2020;36(08):556–566
- 15 Geeroms M, Lu YJ, Hsu CC, Huang RW, Lin CH, Lin CH. Perfusion Dynamics during Secondary Flap Debulking with Liposuction. *J Reconstr Microsurg* 2023 (e-pub ahead of print). Doi: 10.1055/s-0043-1777325. PMID: 38092022
- 16 Seets T, Shaffrey EC, Kawahara T, Singh S, Seitz A, Poore SO, Uselmann A, Lin C. An ambient light-compatible, fluorescence-guided surgery imaging platform for real-time clinical assessment of vascular perfusion and flap viability in breast reconstruction. *Proc. SPIE 12361, Molecular-Guided Surgery: Molecules, Devices, and Applications IX*, 1236103 (14 March 2023); <https://doi.org/10.1117/12.2649353>
- 17 Driessen C, Arnardottir TH, Lorenzo AR, Mani MR. How should indocyanine green dye angiography be assessed to best predict mastectomy skin flap necrosis? A systematic review. *J Plast Reconstr Aesthet Surg* 2020;73(06):1031–1042
- 18 Sood M, Glat P. Potential of the SPY intraoperative perfusion assessment system to reduce ischemic complications in immediate postmastectomy breast reconstruction. *Ann Surg Innov Res* 2013;7(01):9
- 19 Newman MI, Samson MC. The application of laser-assisted indocyanine green fluorescent dye angiography in microsurgical breast reconstruction. *J Reconstr Microsurg* 2009;25(01):21–26
- 20 Mothes H, Dönicke T, Friedel R, Simon M, Markgraf E, Bach O. Indocyanine-green fluorescence video angiography used clinically to evaluate tissue perfusion in microsurgery. *J Trauma* 2004;57(05):1018–1024
- 21 Holm C, Dornseifer U, Sturtz G, Ninkovic M. Sensitivity and specificity of ICG angiography in free flap reexploration. *J Reconstr Microsurg* 2010;26(05):311–316
- 22 Pestana IA, Coan B, Erdmann D, Marcus J, Levin LS, Zenn MR. Early experience with fluorescent angiography in free-tissue transfer reconstruction. *Plast Reconstr Surg* 2009;123(04):1239–1244
- 23 Newman MI, Samson MC, Tamburrino JF, Swartz KA. Intraoperative laser-assisted indocyanine green angiography for the evaluation of mastectomy flaps in immediate breast reconstruction. *J Reconstr Microsurg* 2010;26(07):487–492
- 24 Holm C, Tegeler J, Mayr M, Becker A, Pfeiffer UJ, Mühlbauer W. Monitoring free flaps using laser-induced fluorescence of indocyanine green: a preliminary experience. *Microsurgery* 2002;22(07):278–287
- 25 Gurtner GC, Jones GE, Neligan PC, et al. Intraoperative laser angiography using the SPY system: review of the literature and recommendations for use. *Ann Surg Innov Res* 2013;7(01):1–14
- 26 Chattha A, Bucknor A, Chen AD, Lee BT, Lin SJ. Indocyanine green angiography use in breast reconstruction: a national analysis of outcomes and cost in 110,320 patients. *Plast Reconstr Surg* 2018;141(04):825–832
- 27 Casey WJ III, Connolly KA, Nanda A, Rebecca AM, Perdakis G, Smith AA. Indocyanine green laser angiography improves deep inferior epigastric perforator flap outcomes following abdominal suction lipectomy. *Plast Reconstr Surg* 2015;135(03):491e–497e
- 28 Duggal CS, Madni T, Losken A. An outcome analysis of intraoperative angiography for postmastectomy breast reconstruction. *Aesthet Surg J* 2014;34(01):61–65
- 29 Varela R, Casado-Sanchez C, Zarbakhsh S, Diez J, Hernandez-Godoy J, Landin L. Outcomes of DIEP flap and fluorescent angiography: a randomized controlled clinical trial. *Plast Reconstr Surg* 2020;145(01):1–10
- 30 Momeni A, Sheckter C. Intraoperative laser-assisted indocyanine green imaging can reduce the rate of fat necrosis in microsurgical breast reconstruction. *Plast Reconstr Surg* 2020;145(03):507e–513e
- 31 Hembd AS, Yan J, Zhu H, Haddock NT, Teotia SS. Intraoperative assessment of DIEP flap breast reconstruction using indocyanine green angiography: reduction of fat necrosis, resection volumes, and postoperative surveillance. *Plast Reconstr Surg* 2020;146(01):1e–10e
- 32 Nagaya T, Nakamura YA, Choyke PL, Kobayashi H. Fluorescence-guided surgery. *Front Oncol* 2017;7(DEC):314
- 33 McGregor A, Pavri SN, Tsay C, Kim S, Narayan D. Use of indocyanine green for sentinel lymph node biopsy: case series and methods comparison. *Plast Reconstr Surg Glob Open* 2017;5(11):e1566