



A Modified Wedge Resection Technique to Achieve Natural Results in Labia Minora Reduction

Neha Chauhan¹

¹ Department of Plastic Surgery, Fortis Hospital, Richmond Road

Indian J Plast Surg

Address for correspondence Neha Chauhan, MS, MCh, Fortis Hospital, Richmond Road, Bangalore, Karnataka 560025, India (e-mail: drnehac@gmail.com; drnehaplasticsurgeon@gmail.com).

Abstract

Aesthetic genital surgeries are on the rise globally. Labia minora reduction, the most common aesthetic genital surgery, can be done either by the edge resection or by the wedge resection techniques. The edge resection technique trims the edge of the labia minora and leads to unnatural results as it does not maintain the color gradation that is naturally present on the inner surface of the labia minora or the minor irregularities that are naturally present in the labia besides posing problems like scar pain at edges during intercourse and chances of overresection. Wedge resection has the advantage of retaining the color gradation and the minor natural irregularities on the edge of the labia minora and is considered to be a better technique than the edge resection technique. However, the classical central wedge reduction technique suffers from a deformity in long term in the form of a visible notch at margins of the labia minora at the site of suturing. The author suggests a modification of this technique to overcome this problem to give better natural long-term results.

Keywords

- ▶ genitalia
- ▶ female
- ▶ cosmetic surgery
- ▶ esthetic surgery

Introduction

Labia minora are cutaneous-mucosal folds of tissue present between labia majora separated by interlabial cleft. The free border of the labia minora extends from the clitoris to the posterior commissure of the vulva. The external surface of the labia minora comprises of skin and is pigmented like rest of the surrounding skin. However, the inner surface shows color gradation from dark brown at the margin to pinkish toward the vaginal introitus (▶ **Figs. 1** and **2**). While there are innumerable variations in the size, shape, and color of labia minora, literature considers an aesthetically and functionally pleasing labia minora as one that is present within the confines of the labia majora in standing position.¹ With increasing exposure to media with models in sheer clothing with no labial show, popularity of tight-fitting

leggings/swimwear and widespread prevalence of Brazilian waxing, genital aesthetic surgeries are on a rise globally.² Labia minora reduction surgery is the most common cosmetic genital surgery procedure.^{3,4} The two most common techniques used for labia minora reduction are edge resection and the wedge resection. Edge resection suffers from pitfalls that the natural color gradation of the inner surface of the mucosa is lost resulting in unnatural appearance and the entire edge of the neo-labia gets scarred often leading to painful intercourse. The wedge resections (central,³⁻⁵ inferior, and posterior⁶) are preferred over the edge resection but suffer from long-term deformity of visible notching at the free margin of the labia due to straight line closure rendering them aesthetically displeasing. The author here suggests a modification of the wedge technique to achieve more natural results.

DOI <https://doi.org/10.1055/s-0044-1787277>.
ISSN 0970-0358.

© 2024. Association of Plastic Surgeons of India. All rights reserved. This is an open access article published by Thieme under the terms of the Creative Commons Attribution-NonDerivative-NonCommercial-License, permitting copying and reproduction so long as the original work is given appropriate credit. Contents may not be used for commercial purposes, or adapted, remixed, transformed or built upon. (<https://creativecommons.org/licenses/by-nc-nd/4.0/>)
Thieme Medical and Scientific Publishers Pvt. Ltd., A-12, 2nd Floor, Sector 2, Noida-201301 UP, India

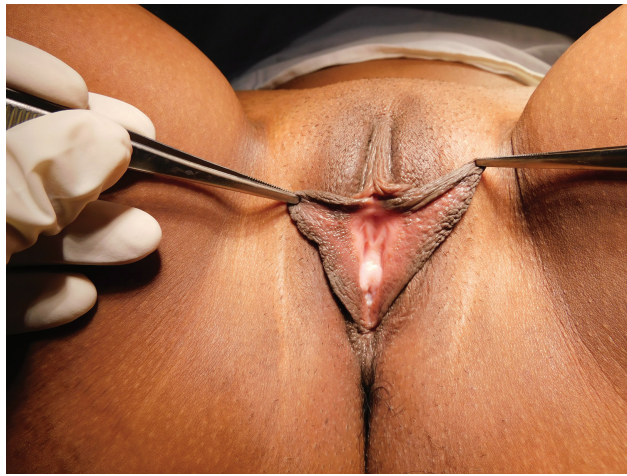

Fig. 1 Preoperative enlarged labia minora of patient 1.

Materials and Methods

After long-term follow-up visits of author's initial three patients operated using the central wedge technique³ with all three of them complaining of a visible notch at the edge of the labia minora (► **Figs. 1** and **3**), the author has modified the wedge technique and has used it for 14 patients between January 2018 and December 2023. The women presenting were aged 25 to 47 years with most common complaints being large sized labia minora causing discomfort during walking, constant rubbing on the undergarment/sanitary pads causing discomfort, itching, infections, and invagination of the labia minora during sexual intercourse.

The Modification

The regular central wedge technique involves straight line closure of the excised wedge as seen on the left labia minora of ► **Figs. 4** and **5** with the two lengths of wedge "x" being equal. However, due to straight line closure, a prominent notch develops on the edge of the labia minora giving it an operated appearance.

The markings of the modified technique are as shown on the right labia minora of ► **Fig. 4** and **5**. The incision line instead of being marked as a straight line is broken down to include a small triangle of tissue at the free edge of the labia minora.

The lines "c" and "d" are equal in size. A small triangular flap "a" is marked close to the free edge of the labia minora. Corresponding to "a," an area to receive the flap is marked as "b" (► **Fig. 5**). While designing, care is taken that the color gradation of flap "a" matches the recipient area "b" and also that the limbs "c" and "d" of the wedge have similar color gradation. In author's technique, the base of the flap "a" accounts for no more than approximately 15 to 20% of the total length of "x" of simple wedge excision. Bigger flaps than this could disturb the color gradation on inner surface of labia minora making scars conspicuous. This consideration is important while planning this modification to achieve natural results. The author plans only as much excision as can be approximated without any tension at suture sites with mono-

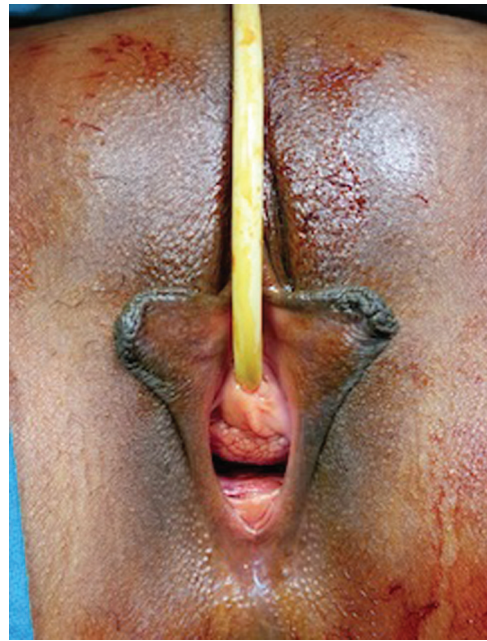


Fig. 2 Preoperative appearance of labia minora of patient 2 operated by modified technique.

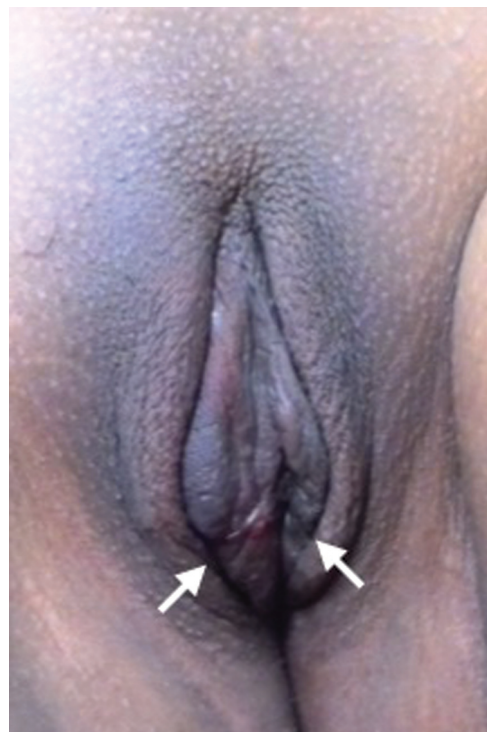

Fig. 3 Postoperative appearance of patient 1 with visible notching at 6 months.

cryl 5–0 cutting needle to avoid early wound healing complications like dehiscence and stretched out scars and late complications like narrowing of the introitus and dyspareunia.

The author reverses this pattern on the opposite labia with positions of flap "a" and recipient "b" being reversed to create an asymmetry between left and right surgical sites and to allow the final scars to resemble the natural fine undulations present on the free border of the labia minora. A comparison

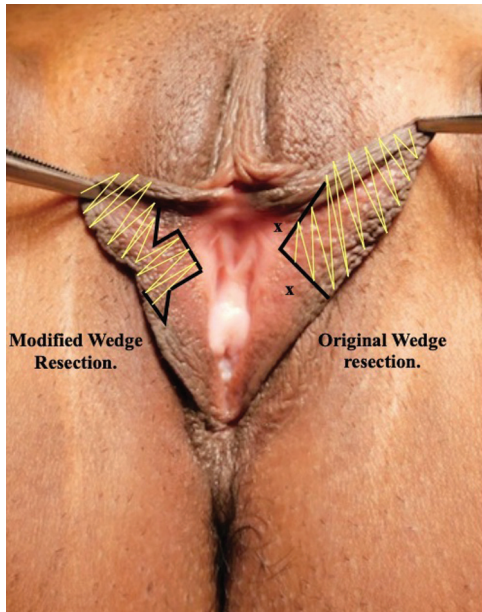


Fig. 4 Comparison of presurgical markings of modified wedge resection (right labia) with the wedge resection (left labia) on patient photograph.

of markings and end scars of both techniques is illustrated in ►Figs. 5 and 6.

The surgery is done on daycare basis and the patient is discharged with Foley’s urine catheter in situ for 2 to 3 days and a dressing over suture sites with 2% mupirocin ointment. After Foley’s catheter removal by third postoperative day, the patient is advised to maintain local hygiene with mild soap and clean water and to continue applying 2% mupirocin ointment after each cycle of micturition for 2 weeks by when the suture lines heal. Follow-up is advised at 2 weeks, 1 month, 3 months, 6 months, and 1 year.

Results

There was no wound dehiscence, pain during intercourse, or any other significant complaint after the procedure by any patient. Preoperative appearance and 6 months postsurgery

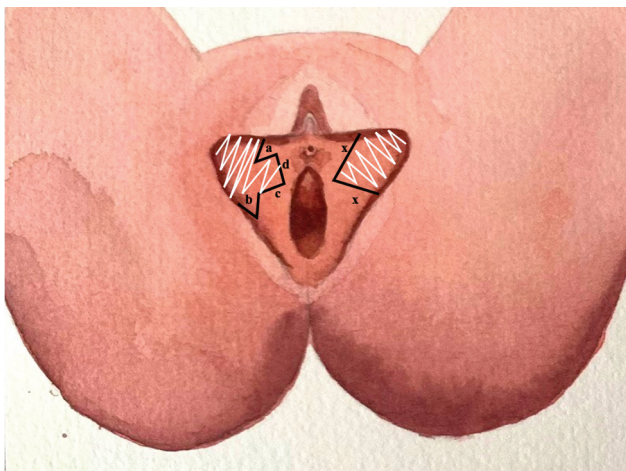


Fig. 5 Comparison of presurgical markings of author’s technique (right labia) with the wedge resection (left labia) (not up to scale).

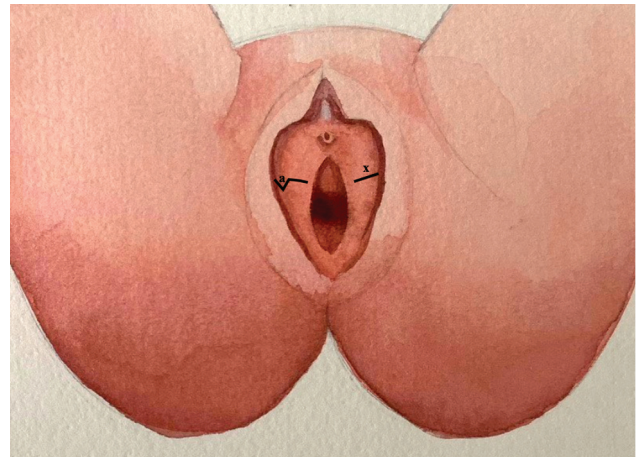


Fig. 6 Illustration showing the sutured incision lines of author’s technique (right labia) compared with the wedge resection (left labia) (not up to scale).

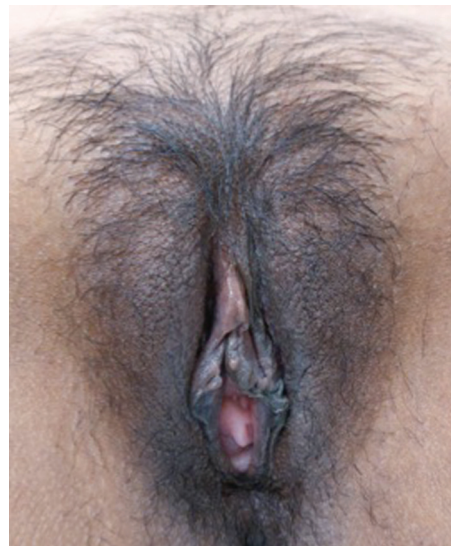

Fig. 7 Six months’ follow-up of patient 2 showing natural results.

appearance of a patient operated using the modified technique are shown in ►Figs. 2 and 7, respectively.

Discussion

Straight line closure of labia minora in the central wedge resection technique of Alter³ results in a visible notch at the free edge of the labia at the operated site.⁵ This notch can be aesthetically displeasing to many patients. Giraldo et al in 2004 published a paper where he used 90-degree Z-plasty to overcome the scar contraction problem and notching inherent to Alter’s procedure. However, Giraldo et al’s technique may result in the mismatch of color gradation⁵ that may be aesthetically displeasing to many patients.

Inner surface of the labia minora is unique in the color gradation that it presents making it difficult to employ a regular Z-plasty to lengthen the scar to avoid notch without disturbing the color gradation. These problems are overcome by planning excision using the modified wedge technique

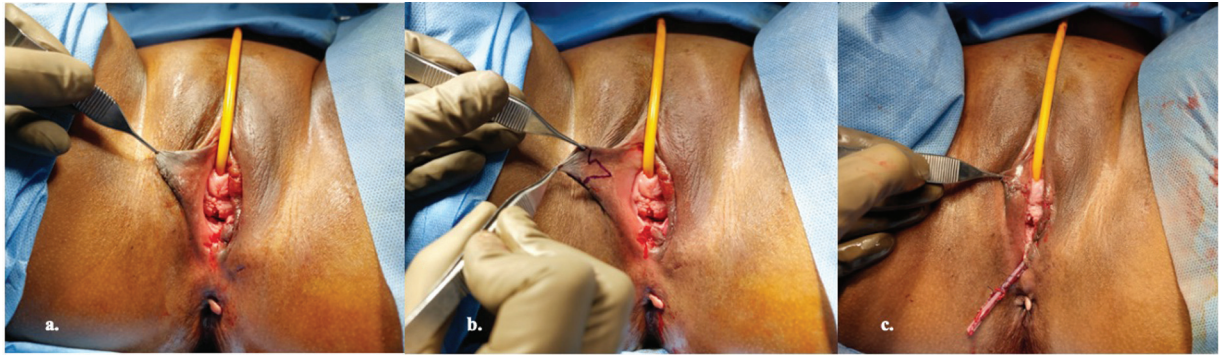


Fig. 8 Preop appearance (A), markings (B), and immediate postoperative results (C) of patient 3 that underwent right labiaplasty by the author and left-sided vaginal cyst excision by the gynecology team.

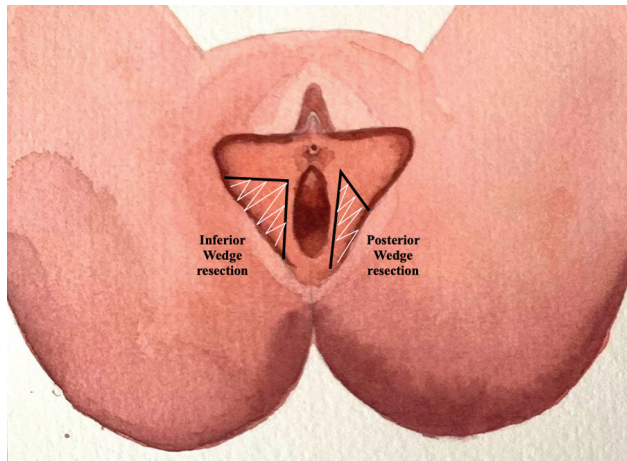


Fig. 9 The inferior and posterior wedge techniques⁶ are also straight line closures and may benefit by adding the modification suggested by the author.

described by the author. By including a V-shaped wedge of tissue as a flap in the closure line instead of closing the wedge as a straight line, the linear direction of force of wound contraction is broken down (►Fig. 8). This results in a much smaller and inconspicuous notch at the edge of the labia minora than the original technique. Beginners may benefit by remembering that careful analysis of color gradation of inner surface of the labia minora while marking is the key to success of this procedure in terms of aesthetics.

In a comprehensive study published by Oranges et al in 2015 where he discusses 11 types of labia minora reductions, none of the techniques has proven superior to others. His article describes two novel wedge resections, namely, inferior and posterior wedge resections (►Fig. 9). However, they are also straight line closures and the author's modification can be beneficial even in those wedge resections.

In author's series, patients did not have any wound healing complications, flap failure, or scar-related complications. However, the major shortcoming of this study remains a small sample size.

Conclusion

The modified wedge technique may offer aesthetically superior results to the central/inferior/posterior wedge excision and Giraldo et al's 90-degree Z-plasty, both in terms of the scar having minimal notching on the free edge of the labia minora, as well as with maintaining the natural color gradation on the inner surface of the labia minora.

Note

This research was previously presented at AESURG 2023 in Lonavala, Maharashtra, India.

Conflict of Interest

None declared.

Acknowledgment

The author acknowledges the contribution of Dr Richa Tomar, Gurugram, India for making the watercolour illustrations ►Figs. 5–6 and 9.

References

- Hodgkinson DJ, Hait G. Aesthetic vaginal labiaplasty. *Plast Reconstr Surg* 1984;74(03):414–416
- Banwell PE. Anatomy and classification of the female genitalia: implications for surgical management. In: Hamori CA, Banwell PE, Alinsod R, eds. *Female Cosmetic Genital Surgery: Concepts, Classification and Techniques*. 1st ed. New York: Thieme Publishers; 2017:3–21
- Alter GJ. A new technique for aesthetic labia minora reduction. *Ann Plast Surg* 1998;40(03):287–290
- Alter GJ. Aesthetic labia minora and clitoral hood reduction using extended central wedge resection. *Plast Reconstr Surg* 2008;122(06):1780–1789
- Giraldo F, González C, de Haro F. Central wedge nymphectomy with a 90-degree Z-plasty for aesthetic reduction of the labia minora. *Plast Reconstr Surg* 2004;113(06):1820–1825, discussion 1826–1827
- Oranges CM, Sisti A, Sisti G. Labia minora reduction techniques: a comprehensive literature review. *Aesthet Surg J* 2015;35(04):419–431