





Fish Arrow Injuries to the Extremities: A Case Series

P Umar Farooq Baba¹  Raheeb Ahmad Shah² Mir Yasir¹ Eknath J.¹ Sheikh Adil Bashir¹ 
Adil Hafeez Wani¹

¹ Department of Plastic and Reconstructive Surgery, Sher-i-Kashmir Institute of Medical Sciences (SKIMS), Soura, Srinagar, Jammu and Kashmir, India

² JK Health Services, Srinagar, Jammu and Kashmir, India

Address for correspondence P. Umar Farooq Baba, MS, MCh, Department of Plastic and Reconstructive Surgery, Sher-i-Kashmir Institute of Medical Sciences (SKIMS), Soura, Srinagar 190011, Jammu and Kashmir, India (e-mail: drumar397@gmail.com).

Indian J Plast Surg

Abstract

Fishing as a hobby is fairly popular among youth in hilly and mountainous areas of the world. Hence, injuries to extremities are also common by fishing equipment, especially in untrained people using indigenous equipment. The mechanism of injury is that of penetrating trauma. There is a paucity of literature regarding fishing equipment injury to extremities. In this article, we have presented a case series of fishing arrow injuries presented to us in the Department of Plastic and Reconstructive Surgery, Sher-i-Kashmir Institute of Medical Sciences (SKIMS), Srinagar, Jammu and Kashmir, India. Most of these injuries were treated under the wide-awake local anesthesia no tourniquet technique which has revolutionized the management of extremity injuries. Also, special precautions regarding the prevention of further tissue injury by arrow hooks while retrieving the arrows have been highlighted.

Keywords

- ▶ fish arrow injuries
- ▶ extremities
- ▶ arrow hook
- ▶ WALANT

Introduction

The valley of Kashmir is blessed with mountains, meadows, and freshwater bodies. These water bodies are rich in aquatic fauna and flora; a large variety of fish is found in abundance there. Consequently, a large section of young adults is attracted to these water bodies for fishing, swimming, boating, etc. Especially in Srinagar, the main city of Kashmir, the shallow wetlands and small streams are so rich in fish that “arrow hunting” is a more popular method of fishing than anglers or fishing nets.

In this case series, we present peculiar and unique reports of fish arrow injury to young men. All of them sustained these injuries to their extremities while fishing. Although fishing equipment injuries are common worldwide¹ and can sometimes be fatal² or debilitating,³ they usually are trivial. However, in the case of extremities, even trivial injuries might prove to be debilitating because of the relative superficial disposition of major vessels and nerves which makes

them prone to trauma.⁴ Furthermore, fish hook or arrow injuries to extremities are uncommonly reported in literature worldwide.⁵ There are multiple arrowheads in an indigenous fish arrow so the simple removal of this foreign body may cause entanglement of vital structures in these arrowheads upon removal, and hence, cause more injury than the initial penetrating trauma itself.⁶ Hence, knowledge of anatomy, planning of incisions, and radiological guidance is vital in such injuries.⁷

Case Descriptions

Case 1 (→ Figs. 1 and 2)

A 42-year-old man sustained an accidental fishing arrow injury to his left hand when his friend shot an arrow in the shallow waters and instead, it hit his palm. The person was taken to our hospital where after the initial history taking and local examination, an X-ray and high-resolution ultrasonography (HR-USG) scan was performed. Local

DOI <https://doi.org/10.1055/s-0044-1787279>.
ISSN 0970-0358.

© 2024. Association of Plastic Surgeons of India. All rights reserved. This is an open access article published by Thieme under the terms of the Creative Commons Attribution-NonDerivative-NonCommercial-License, permitting copying and reproduction so long as the original work is given appropriate credit. Contents may not be used for commercial purposes, or adapted, remixed, transformed or built upon. (<https://creativecommons.org/licenses/by-nc-nd/4.0/>)
Thieme Medical and Scientific Publishers Pvt. Ltd., A-12, 2nd Floor, Sector 2, Noida-201301 UP, India




Fig. 1 The fish hook injury on the left hand, the arrow being removed in an antegrade direction.

examination revealed no neurovascular (NV) deficit in any digit with normally functioning both flexors and extensors. X-ray (→**Fig. 1**) showed a foreign body entering the third web space almost abutting the skin on the dorsal surface of the hand. HR-USG showed the distal arrowhead just abutting the common palmar digital nerve of the third web space. There

was a challenge in retrieving this foreign body through the wound of entry as there was a high chance that the arrowhead would damage the common digital nerve to the third web space due to its proximity to it.

Hence, it was decided to remove it by following the path of trajectory through the dorsal skin taking care not to rotate the arrow head while removing it (→**Fig. 1**). The surgery was performed under the wide-awake local anesthesia no tourniquet (WALANT) technique of anesthesia. In this technique, the WALANT solution (consisting of Xylocaine 1%, adrenaline 1:100,000, and sodium bicarbonate 8.4%) is infiltrated into the area of interest with a thin 27-G needle, and there is a waiting time of approximately 24 minutes to achieve a fully bloodless field with good local anesthesia with preservation of motor function so that all the tendon movements can be demonstrated during the procedure. Regarding sterility of the whole of the fish arrow, these were washed multiple times, first with Savlon and then twice with Betadine (till dry) before antegrade withdrawal was contemplated. After removal of the foreign body, the wound was again flushed with Betadine 10% solution. The entry wound was enlarged to facilitate smooth movement of the foreign body by freeing it from fibrous strands of palmar fascia. The make and the architecture of the foreign body is such that its side hooks are directed in such a way if we try to pull it out, all the tissues in the tract will be tethered by its sharp side hooks (which are directed in the opposite direction), and thereby do a lot of collateral damage to the uninjured tissues. So just by making a small incision in the skin just above the tip, we can get the

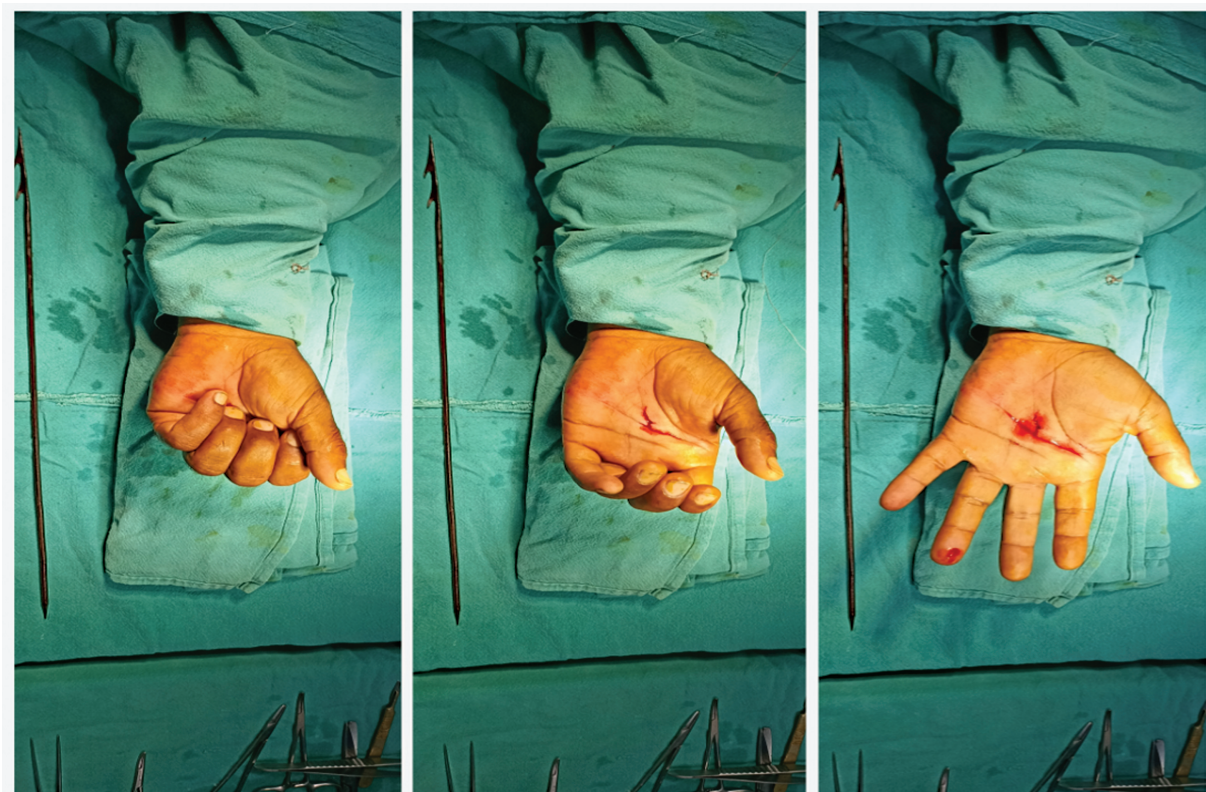

Fig. 2 After the removal of the foreign body, demonstrating the full range of movements (ROMs) under the wide-awake local anesthesia no tourniquet (WALANT) technique of anesthesia.

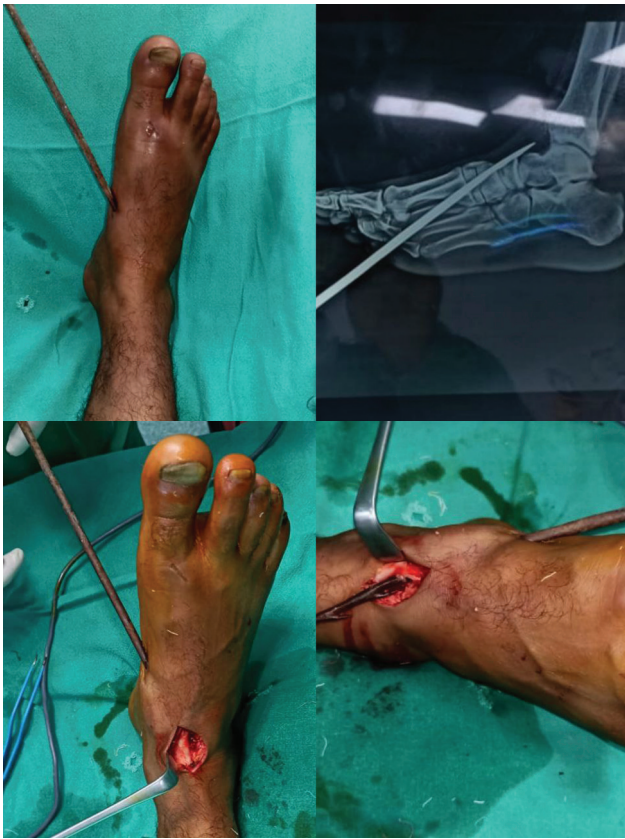

Fig. 3 Fish arrow injury on the right foot. Incision made, neurovascular (NV) bundle and extensor hallucis longus (EHL) identified, and the tip of arrow located.

front part with multiple side hooks safely out without any trauma to the surrounding tissues.

Postoperatively, there was no neurodeficit in any digit (**►Fig. 2**). The follow-up was also unremarkable.

Case 2 (►Figs. 3 and 4)

A 28-year-old man was accidentally hit with a fish arrow on the medial aspect of his right foot when his friend tried to strike a trout fish in a freshwater stream when he (patient)

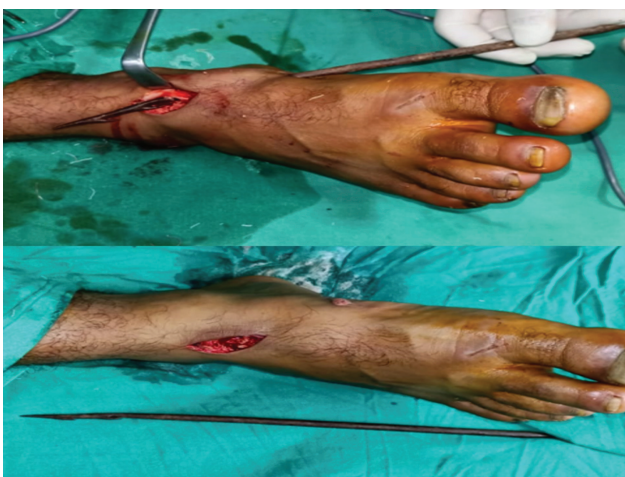

Fig. 4 Foreign body removed after proper identification of anatomy.

was sitting with both his feet underwater. He was shifted to our hospital within 1 hour of trauma and admitted to the accident and emergency department. Initial examination showed normal extension of the great toe and normal inversion of the foot with intact sensation of first web space. Tetanus toxoid (TT) and intravenous antibiotics were administered, and an X-ray (**►Fig. 3**) and HR-USG were done. HR-USG showed a fish hook penetrating the medial aspect of the foot going under the tibialis anterior (TA) tendon, and just ending near the extensor hallucis longus (EHL) tendon under the superior slip of inferior extensor retinaculum. The tip of the arrow was abutting the dorsalis pedis artery and deep peroneal nerve (**►Fig. 3**).

In this case, the demanding part was to preserve the integrity of the NV bundle as well as to prevent injury to the TA and EHL tendons. The patient was operated on the same day—an incision was made at the dorsal aspect of the ankle over the EHL tendon, blunt and controlled subcutaneous dissection was done, NV bundles were identified, safeguarded, and the tip of fish arrow retrieved from under the EHL tendon. Care was taken not to rotate the arrow while being removed to prevent injury to NV bundles from the proximal “arrow hook.” At the end of the surgery, the normal extension of the great toe and foot inversion were confirmed (**►Fig. 4**). The patient was discharged 6 hours after surgery on the same day. Postoperative follow-up was uneventful with a normal range of motion and sensation.

Case 3 (►Figs. 5)

A 40-year-old left-handed man while fishing alone at a stream accidentally hit his right hand. He was shifted to a local health care facility where first aid, TT, and intravenous antibiotic doses were administered. He was referred to our hospital. On examination, he had a fish arrow injury at the base of the right thenar eminence just at the distal margin of the flexor retinaculum (**►Fig. 5**). Clinically, the sensation in the median nerve territory was normal. All the intrinsic movements of the thumb and fingers were normal. HR-USG was performed which confirmed sparing of the recurrent branch of the median nerve and common palmar digital branches of the median nerve. The foreign body was removed under the WALANT technique of anesthesia. The patient was discharged the same day after evaluating for distal NV status, which of course was normal.

Discussion

Fishing as a means of recreation is very common among young individuals in mountainous regions of the world. It does not require any special equipment and local variations of fishing equipment are always available. However, with such equipment, penetrating injuries can occur.⁸ There is a paucity of literature dealing with fish hook injuries in the extremities.⁵ Unlike other means of penetrating trauma, fish hook injury to extremities is uncommonly associated with injury to vital structures.⁹ However, when a vital structure

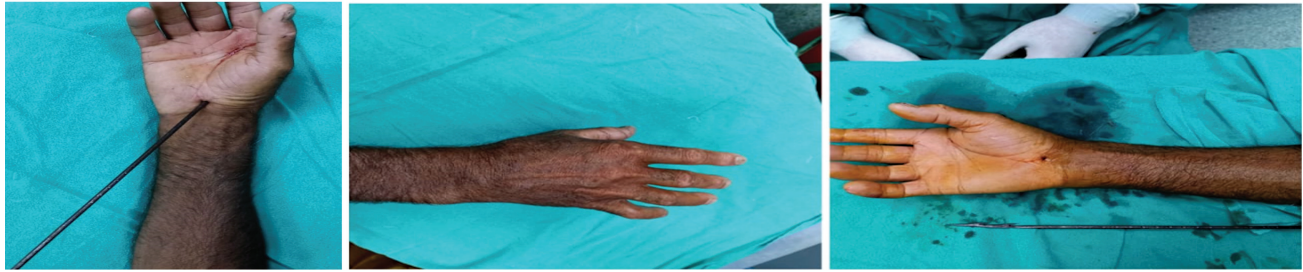

Fig. 5 Fish hook injury on the right hand, and removal of the arrow under wide-awake local anesthesia without a tourniquet (WALANT).

injury is suspected, it should be considered that such tools act in a way resembling gunshot wounds.¹⁰ Hence, they must be dealt with keeping in view the principles of firearm injury management, that is, debridement and excision of necrotic tissue, all accessible bone pieces, and removal of the projectile followed by repair of nerves and vessels.¹¹ Since the fish arrow projectiles found in our cases have multiple arrowheads, they are commonly removed in the anterograde direction, to avoid further injury to vital structures due to these multiple arrowheads. This principle is true for all such weapons which have multiple notches or “anchor hooks” at the tip.¹²

The utilization of the WALANT technique of anesthesia has revolutionized as well as eased the removal of such foreign bodies in clinical practice. Also, simple investigations like HR-USG and an X-ray are enough preoperatively. However, knowledge of surface anatomy is critical to rule out injury to vital structures. It has been our practice to operate these patients within 6 hours to alleviate psychological stress. We strongly emphasize that such foreign bodies should not be removed by inexperienced practitioners as they may do more harm than good.

Conflict of Interest

None declared.

References

- 1 Aiello LP, Iwamoto M, Guyer DR. Penetrating ocular fish-hook injuries. Surgical management and long-term visual outcome. *Ophthalmology* 1992;99(06):862–866
- 2 Yoshida N, Iwamoto M, Mukae H, et al. A case of fatal sepsis due to *Vibrio vulnificus* [in Japanese]. *Kansenshogaku Zasshi* 1990;64(02):236–242
- 3 Gutierrez A, Gil L, Sahuquillo J, Rubio E. Unusual penetrating craniocerebral injury. *Surg Neurol* 1983;19(06):541–543
- 4 Banerjee B, Das RK. Sonographic detection of foreign bodies of the extremities. *Br J Radiol* 1991;64(758):107–112
- 5 McCallum WG, Fromm RE Jr. Fish scale: an unusual foreign body. *Am J Emerg Med* 1995;13(04):419–420
- 6 Lammers RL, Magill T. Detection and management of foreign bodies in soft tissue. *Emerg Med Clin North Am* 1992;10(04):767–781
- 7 López F, Martínez-Lage JF, Herrera A, et al. Penetrating craniocerebral injury from an underwater fishing harpoon. *Childs Nerv Syst* 2000;16(02):117–119
- 8 Ciulla TA, Mukai S, Miller JW. Severe penetrating eye trauma caused by fish pick accidents. *Retina* 1996;16(03):219–221
- 9 vanGurp G, Hutchison TJ, Alto WA. Arrow wound management in Papua New Guinea. *J Trauma* 1990;30(02):183–188
- 10 Hain JR. Fatal arrow wounds. *J Forensic Sci* 1989;34(03):691–693
- 11 Eren B, Cetin S, Türkmen N, Akan O, Gürses MS, Gündoğmuş UN. An unusual case of penetrating intracranial injury due to scissors. *Soud Lek* 2013;58(02):29–30
- 12 Taylor AG, Peter JC. Patients with retained transcranial knife blades: a high-risk group. *J Neurosurg* 1997;87(04):512–515