



Intracranial Pressure Monitoring Location: A Pilot Study on the Validation of Subdural Site with the Intraventricular Site

Suparna Bharadwaj¹ Mouleeswaran Sundaram¹ Dhritiman Chakrabarti¹
Radhakrishnan Muthuchellappan¹

¹Department of Neuro Anaesthesia and Neuro Critical Care, National Institute of Mental Health and Neurosciences, Bangalore, Karnataka, India

Asian J Neurosurg 2024;19:402–407.

Address for correspondence Radhakrishnan Muthuchellappan, MD, DM, Department of Neuro Anaesthesia and Neuro Critical Care, National Institute of Mental Health and Neurosciences, Bangalore, Karnataka 560029, India
(e-mail: nimhansarticlesubmission@gmail.com).

Abstract

Introduction Knowledge of preoperative and intraoperative intracranial pressure (ICP) enables the neuroanesthesiologist to optimize cerebral perfusion pressure. However, ICP is rarely monitored during the intraoperative period. In this report, subdural site ICP measurement is validated with intraventricular ICP measurement, and the feasibility of subdural ICP monitoring during the intraoperative period is discussed.

Materials and Methods In this prospective pilot study, ICP measurement at the subdural site was achieved with an intravenous cannula and the ventricular site with a ventricular cannula. Both were transduced using a fluid-filled pressure transducer and connected to the monitor for display of the number and the waveforms. Monitoring of intraoperative ICP using both the techniques was done in all patients recruited into the study. The correlation between the two modalities of measurement was studied by the Spearman correlation test and their limits of agreement were studied using the Bland–Altman plot. A case series describing the perioperative management based on the subdural ICP values are also described.

Results Subdural ICP showed a strong correlation with intraventricular ICP ($r_s = 0.93$, $p = 0.01$). Agreement analysis using the Bland–Altman plot showed that the mean difference of ICP between the modalities was 1.44 mm Hg (95% confidence interval, -0.6 to 3.49 , $p = 0.122$).

Discussion This study validates the ICP values measured at the subdural site with the intraventricular site. Subdural site ICP monitoring can be achieved rapidly with readily available systems and helps in making intraoperative clinical decisions.

Conclusion Cannula-based subdural ICP is a satisfactory alternative to intraventricular ICP monitoring in the intraoperative period.

Keywords

- ▶ intraoperative intracranial pressure monitoring
- ▶ intraventricular catheter
- ▶ subdural catheter
- ▶ perioperative management

article published online
June 18, 2024

DOI <https://doi.org/10.1055/s-0044-1787536>.
ISSN 2248-9614.

© 2024. Asian Congress of Neurological Surgeons. All rights reserved.

This is an open access article published by Thieme under the terms of the Creative Commons Attribution-NonDerivative-NonCommercial-License, permitting copying and reproduction so long as the original work is given appropriate credit. Contents may not be used for commercial purposes, or adapted, remixed, transformed or built upon. (<https://creativecommons.org/licenses/by-nc-nd/4.0/>)

Thieme Medical and Scientific Publishers Pvt. Ltd., A-12, 2nd Floor, Sector 2, Noida-201301 UP, India

Introduction

In 1783, Alexander Monro proposed that the skull is a rigid box with a fixed internal volume of 1,400 to 1,700 mL.¹ The contents include 80% brain parenchyma, 10% cerebrospinal fluid (CSF), and 10% blood.² As per the Monro–Kellie doctrine, an increase in one component will cause a decrease in one or both of the other components, mostly CSF and blood.² Such a compensatory reserve is called spatial compensation, and the failure of compensatory reserve results in severe brain damage. Normal intracranial pressure (ICP) values change with age and posture. It is 5 to 15 mm Hg in healthy supine adults, 3 to 7 mm Hg in children, and 1.5 to 6 mm Hg in infants.³ Several monitors and transducers are available for monitoring ICP.⁴

Intraventricular ICP monitoring is the gold standard and comprises a ventricular catheter attached to an external fluid-filled pressure transducer.⁴ Other advantages of the intraventricular ICP monitoring system are that it allows the drainage of CSF, and ICP waveforms are distinct and readily analyzed.⁴ Monitors which measure ICP from extraventricular sites display the absolute ICP values and neither allow CSF drainage nor permit ICP waveform analysis.⁵ These monitors have transducers either at the tip of the catheter or externally, and they can be placed in the brain parenchyma, subdural/subarachnoid, or extradural space. The main advantages of extraventricular ICP monitors are less invasiveness, less infection rate, and easy maintenance.¹ However, these monitors are primarily used in the intensive care unit, and their utility during the intraoperative period is not frequently explored. Knowledge of preoperative and intraoperative ICP will enable the neuroanesthesiologist to target optimal cerebral perfusion pressure (CPP). Intraventricular ICP monitoring may not be feasible in cases where cerebral ventricles are compressed. Extraventricular ICP monitoring is an alternative in such cases. Presently validated extraventricular ICP monitors are expensive, and the sensors are not reusable.

We hypothesize in this pilot study that the subdural ICP measurement using an intravenous cannula is a reliable surrogate for the gold standard technique of intraventricular ICP measurement. The primary objective of this study was to correlate the subdural ICP values with the gold standard intraventricular ICP values.

Materials and Methods

This is a prospective validation and feasibility study of neurosurgical patients whose ICP was monitored intraoperatively. Patients were studied for 4 months, from July 2021 to October 2021. Institutional ethics committee approval was not obtained for this study as ICP monitoring is standard of care at our institution. Informed consent from patients was obtained for scientific publication of the data with patient anonymity. Intraventricular ICP and/or subdural ICP were monitored in patients recruited into the study.

For the intraventricular monitoring, the lateral ventricle was hit using a ventricular cannula through the Kocher's

point, 3 cm lateral to the midline, and 1 cm in front of the coronal suture.⁶ On confirming the CSF flow, the cannula was immediately connected to a de-aired system of an external fluid-filled pressure transducer (IpeX pressure monitoring kit, BL Lifesciences, Uttar Pradesh, India) to record the opening pressure (→ Fig. 1A and B). Both values and waveform get displayed on the monitor (Intellivue MX850, Philips, GmbH, Germany and Carescape B850, Wipro GE Healthcare, Karnataka, India). After noting the opening pressure, the ventricular cannula was replaced with a ventricular catheter, connected to the same transducer, and retained for further intraoperative monitoring. If the patient was scheduled for ventriculoperitoneal shunt procedure, the intraventricular cannula was internalized into a shunt after recording the opening CSF pressure.

For subdural ICP monitoring, an intravenous cannula connected to a fluid-filled pressure transducer was used. The de-aired system was placed subdurally once the first burr hole was made by the neurosurgeon (→ Fig. 1C and D), and the value gets displayed on the monitor.

The transducer was zeroed at the level of the tragus of the patient on all occasions. The system was not pressurized. When deemed necessary, the CSF was drained from the proximal three-way stopcock of the transducer in the intraventricular ICP monitoring system. ICP waveforms were distinct with intraventricular monitoring and were not appreciable during subdural ICP monitoring (→ Fig. 2A and B).

Statistical Analysis

Data were analyzed using R software, version 3.5.2. A correlation was conducted using Spearman's correlation coefficient and data graphed as a scatter plot. Agreement analysis was conducted using the Bland–Altman plot, and a single-sample *t*-test was performed on the mean difference of ICP between the modalities. Null hypothesis (H₀) was that the difference between the techniques was considered as 0 mm Hg.

Results

Twelve patients were recruited into this study. Both subdural and intraventricular ICP were monitored in nine patients and were included for analysis of the agreement. The remaining three patients were included for assessing the feasibility of intraoperative ICP monitoring using the subdural technique. Seven patients included in the agreement analysis underwent insertion of a ventriculoperitoneal shunt, one underwent intracranial aneurysm clipping, and one patient underwent strip craniectomy for craniosynostosis. The subdural ICP and intraventricular ICP measured in each of the nine study subjects are given in → Table 1. There was a strong positive correlation between the two ICP monitoring techniques with $r_s = 0.93$ ($p = 0.01$) (→ Fig. 3A). The mean difference of ICP between modalities was found to be 1.44 mm Hg (95% confidence interval, -0.6 to 3.49 , $p = 0.122$) (→ Fig. 3B).

From the ICP values, it is apparent that the subdural ICP had consistently higher values than intraventricular ICP. However, the mean difference was found to be 1.44 mm Hg,

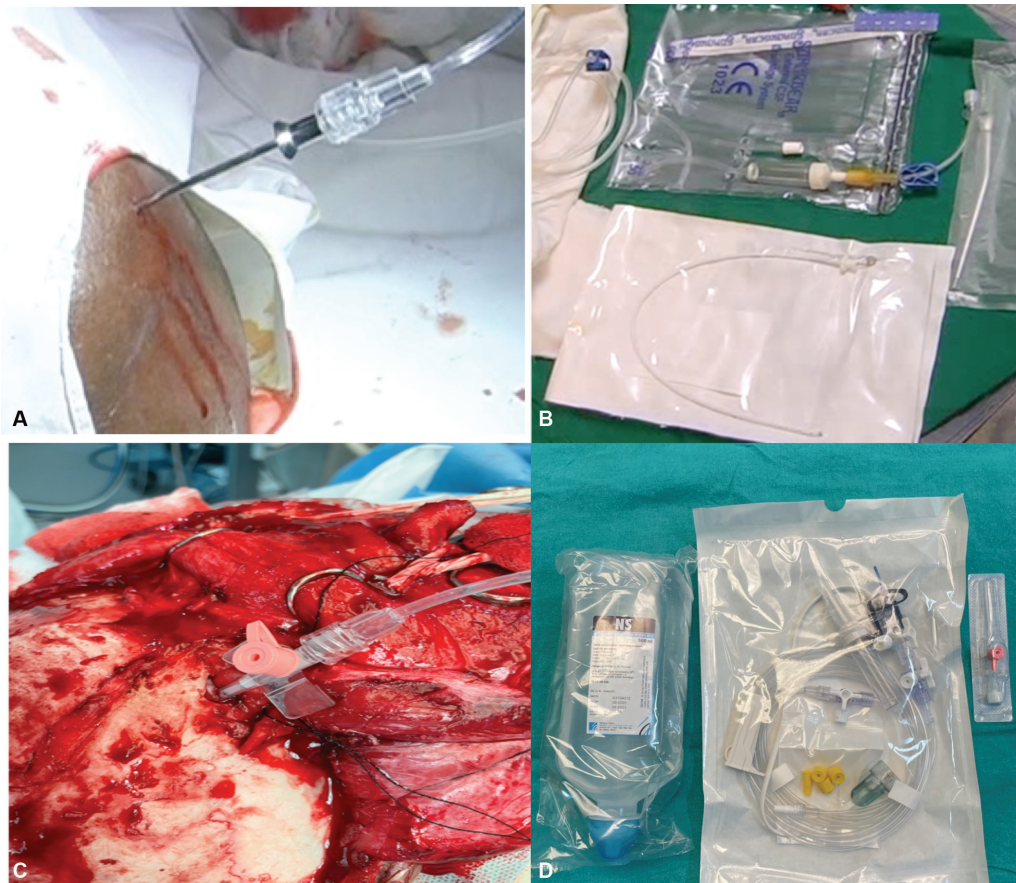


Fig. 1 (A and B) Intraventricular cannula and pressure transducer system. (C and D) Subdural cannula and pressure transducer system.

and the difference from zero is not statistically significant ($p=0.12$). The 95% confidence levels were also found to be large, which may be interpreted as imprecise estimates. Both the points are probably related to the small sample size of the study.

To explore the feasibility of continuous intraoperative ICP monitoring, subdural ICP was measured in three patients using an intravenous cannula connected to the pressure transducer. Subdural ICP monitoring in these patients helped to make critical intraoperative clinical decisions based on the

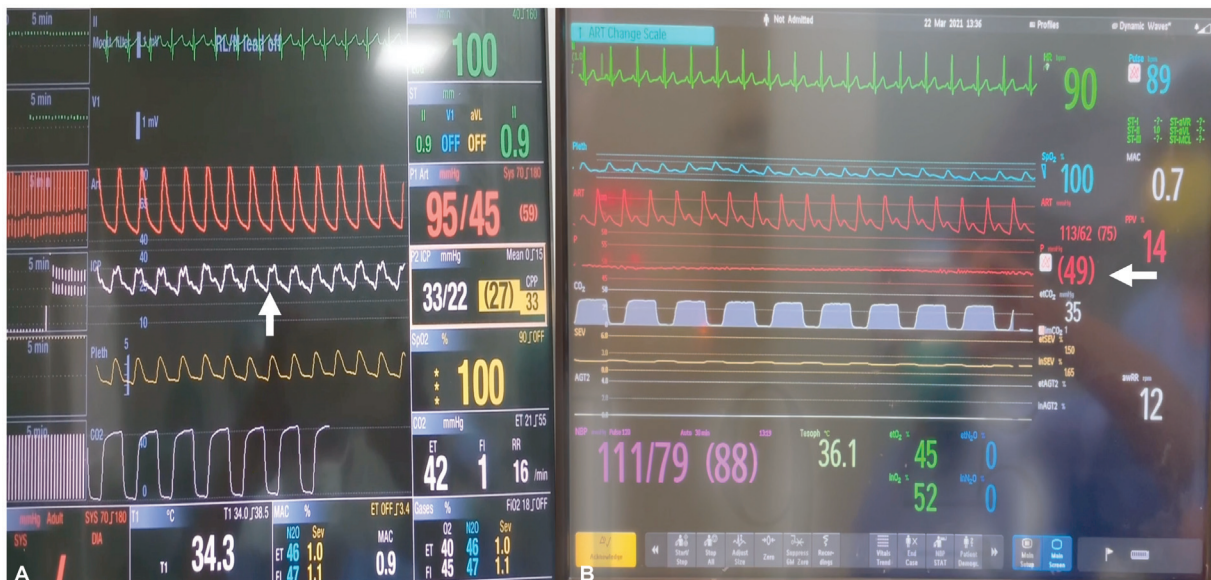

Fig. 2 (A) Appreciable intraventricular pressure (ICP No) waveform and value (white arrow). (B) Absolute ICP value without appreciable ICP waveform (white arrow).

Table 1 Subdural ICP and Intraventricular ICP values in study subjects

Sl. no.	Diagnosis	Subdural ICP (mm Hg)	Opening pressure of CSF (mm Hg)	GCS (immediate postop)
1	Left CP angle lesion	28	25	E4V5M6
2	GH secreting pituitary macroadenoma	27	23	E4V5M6
3	Thalamic lesion	33	35	E4V5M6
4	Sellar lesion	21	24	E4V5M6
5	Cerebellar hematoma	37	34	E3M4VT
6	Right CP angle lesion	31	31	E4V5M6
7	Pineal gland tumor	29	26	E3V3M6
8	Subarachnoid hemorrhage	24	21	E3VTM5
9	Craniosynostosis	16	14	E4V5M6

Abbreviations: CP, cerebellopontine; CSF, cerebrospinal fluid; E, eye opening; GCS, Glasgow Coma Scale; GH, growth hormone; ICP, intraventricular pressure; M, motor response; V, verbal response; VT, patient on tracheal tube.

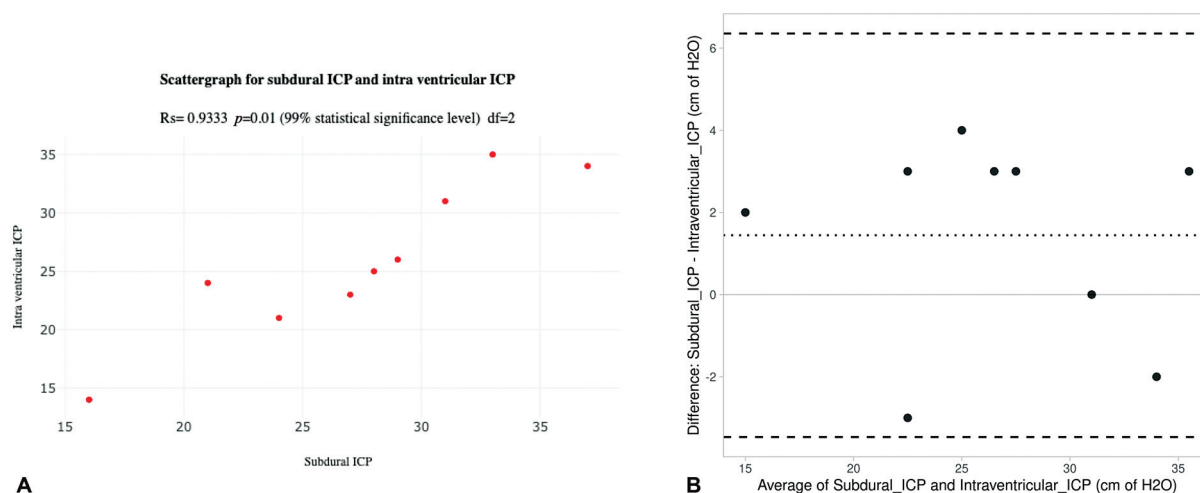


Fig. 3 (A) Spearman's correlation coefficient scatter plot. (B) Bland–Altman agreement plot (mentioned as cm of H₂O in the x-axis. It should be mm Hg. To be verified).

ICP values. Details of cases and the intraoperative course are shown in ► **Table 2**.

Discussion

Preoperative and postoperative ICP monitoring has been utilized for patient management, particularly in patients with traumatic brain injury.⁶ However, intraoperative ICP monitoring is seldom practiced. In neurosurgical patients with other intracranial pathologies, perioperative ICP monitoring is limited to research and not a routine practice. Through this feasibility and pilot validation study, the utility of intraoperative ICP monitoring for clinical decision-making has been highlighted. This study also proposes that subdural ICP is a satisfactory alternative to intraventricular ICP monitoring in the intraoperative period. There are limited studies in the literature comparing intraventricular ICP with subdural ICP. Olson et al, in their

meta-analysis, argued that intraventricular and intraparenchymal ICP values are not interchangeable and there exists significant differences.⁷ No such comparative studies exist for subdural ICP monitoring.

Use of intravenous cannula for subdural ICP monitoring is safe considering the short length and narrow lumen of the catheter. In this study, subdural ICP was monitored intermittently at various surgical points by inserting intravenous cannula in the subdural location. Hence, chance of infection is rare. Hemorrhage is a possibility as the insertion of cannula is a blind procedure. However, craniotomy would be relatively large in patients with traumatic brain injury and bleeding could be well controlled. Seizures are rare again as patients are operated for traumatic brain injury under cover of antiseizure medication. While use of intraoperative subdural ICP monitoring is an invasive technique, intraoperative ultrasonography can be a noninvasive technique to detect mass effects and midline shift.

Table 2 Intraoperative course of patients in whom intraoperative subdural ICP was measured

Sl. no	Case details	ICP monitoring	ICP mm Hg (baseline)	Interventions	Final ICP (mm Hg)	Target CPP in mm Hg	Patient outcome at discharge
1	20 year/male/right temporal contusion/admission GCS: E4V5M6/8 hours after admission, GCS deteriorated to E3V2M4 with midline shift of 7 mm on CT brain Initial surgical plan: Right frontotemporal craniotomy and evacuation of contusion and replacement of bone flap	Subdural	49	Head end elevation from 30 to 60 degrees Brief hyperventilation (ETCO2 28 mm Hg)	39 25	60–70	Decompressive craniectomy performed based on baseline ICP GCS E4V5M6, moving all four limbs
2	38 y/F/headache for 8 months, vomiting for 4 months. Headache is relieved by vomiting suggesting poor cerebral compliance/admission GCS E4V5M6 Diagnosis: Supratentorial space-occupying lesion	Subdural	25 (with head end elevation, Mannitol)	Change over from inhalational anesthesia to total intravenous anesthesia	8	60–70	GCS E4V5M6, moving all four limbs
3	6 months/M/craniosynostosis	Subdural	22	Strip craniectomy	9	Maintain ward MAP	Conscious, alert, playful and moving all four limbs

Abbreviations: CPP, cerebral perfusion pressure; CT, computed tomography; GCS, Glasgow Coma Scale; ICP, intracranial pressure; MAP, mean arterial pressure.

Monitoring subdural ICP in three patients demonstrated the feasibility of intraoperative ICP monitoring and helped clinicians for the goal-directed management of patients (► **Table 2**).

Case 1: Indications for ICP monitoring as per the Brain Trauma Foundation guidelines include severe head injury with abnormal computed tomography (CT) scan. This patient presented with Glasgow Coma Scale of 15 and normal CT; hence, ICP monitoring was not initiated. However, he deteriorated during observation and was taken up for surgery. The decision for decompressive craniectomy (DC) was based on the baseline intraoperative subdural ICP (= 49 mm Hg). Demetriades studied ICP in patients after DC to understand the effectiveness of DC for ICP reduction.⁸ Nevertheless, literature is lacking for decisions on DC based on intraoperative ICP values.

Case 2: In this case, the choice of total intravenous anesthesia (TIVA) was made based on the subdural ICP values before the craniotomy was completed. A subdural ICP of 25 mm Hg following the first burr hole with controlled intraoperative hemodynamics and ventilation is deemed high. Thus, an objective criterion (ICP) was used to decide on the choice of anesthetics. The use of TIVA versus inhalational agents for intraoperative management of neurosurgical patients with raised ICP is a dilemma for most neuroanesthesiologists. This case illustrates that decisions can be made based on intraoperative ICP values. However, Petersen et al observed in their study that subdural ICP was comparable in patients of supratentorial tumors with either inhalational agents or TIVA.⁹

Case 3: In this case, ICP was monitored before and after strip craniectomy. Incidence of hydrocephalus in patients with craniosynostosis and syndromic association is anywhere between 30 and 100%.^{10,11} Whenever the ICP is higher after strip craniectomy, close patient observation in the postoperative period becomes crucial. One should look for either symptoms suggestive of raised ICP or objective ICP value to decide the need for CSF diversion.

Limitations

This study had several limitations. First, small sample size of the study is a major limitation. More studies on the clinical outcome of patients with a larger sample size are needed to stress the importance of intraoperative ICP monitoring. Second, ICP waveform was not elicitable on the monitor during subdural monitoring. This could be due to the rigid nature of the intravenous catheter. However, kinking and blockage was ruled out at each instance of ICP monitoring by flushing the cannula. The ICP values were reliable as the ICP changed with clinical scenarios in each patient.

Conclusion

Intraoperative subdural ICP monitoring is feasible using an inexpensive intravenous cannula. Simple external pressure transducers may be used to monitor ICP values. Intraoperative ICP can guide the neuroanesthesiologist and the

neurosurgeon regarding optimal CPP, the need for DC, and insertion of external ventricular drain as appropriate for efficient clinical management. More studies on the clinical outcome of patients with a larger sample size are needed to stress the importance of intraoperative ICP monitoring.

Authors' Contributions

S.B. was responsible for the conceptualization, methodology, and manuscript preparation. M.S. handled data collection, while D.C. focused on data analysis. R.M. provided supervision and was involved in manuscript preparation, reviewing, and editing. All authors reviewed the results and approved the final version of the manuscript.

Conflict of Interest

None declared.

Acknowledgments

We would like to acknowledge the neurosurgeons, Dr. Abhay and Dr. Rana who contributed to intraoperative ICP monitoring.

References

- 1 Raboel PH, Bartek J Jr, Andresen M, Bellander BM, Romner B. Intracranial pressure monitoring: invasive versus non-invasive methods-a review. *Crit Care Res Pract* 2012;2012:950393
- 2 Neff S, Subramaniam RP. Monro-Kellie doctrine. *J Neurosurg* 1996;85(06):1195
- 3 Rangel-Castilla L, Gopinath S, Robertson CS. Management of intracranial hypertension. *Neurol Clin* 2008;26(02):521-541, x
- 4 Nag DS, Sahu S, Swain A, Kant S. Intracranial pressure monitoring: gold standard and recent innovations. *World J Clin Cases* 2019;7(13):1535-1553
- 5 Lavinio A, Menon DK. Intracranial pressure: why we monitor it, how to monitor it, what to do with the number and what's the future? *Curr Opin Anaesthesiol* 2011;24(02):117-123
- 6 Munakomi S, Das JM. Ventriculostomy. [Updated August 9, 2021]. In: *StatPearls*. Treasure Island, FL: StatPearls Publishing January 2021. Accessed May 17, 2024 at: <https://www.ncbi.nlm.nih.gov/books/NBK545317/>
- 7 Olson DM, Ortega Pérez S, Ramsay J, et al. Differentiate the source and site of intracranial pressure measurements using more precise nomenclature. *Neurocrit Care* 2019;30(02):239-243
- 8 Demetriades AK. Intracranial pressure monitoring after primary decompressive craniectomy: is it useful? *Acta Neurochir (Wien)* 2017;159(04):623-624
- 9 Petersen KD, Landsfeldt U, Cold GE, et al. Intracranial pressure and cerebral hemodynamic in patients with cerebral tumors: a randomized prospective study of patients subjected to craniotomy in propofol-fentanyl, isoflurane-fentanyl, or sevoflurane-fentanyl anesthesia. *Anesthesiology* 2003;98(02):329-336
- 10 Choi JW, Lim SY, Shin HJ. Craniosynostosis in growing children : pathophysiological changes and neurosurgical problems. *J Korean Neurosurg Soc* 2016;59(03):197-203
- 11 Derderian C, Seaward J. Syndromic craniosynostosis. *Semin Plast Surg* 2012;26(02):64-75