



A Report of a Rare Case of Bi-Rooted Bimaxillary Deciduous Canines

Mohamed Shaji¹ Srikala Bhandary² Simna Abhilash¹ Dhvani Abhijit Tanna²

¹Department of Pediatric and Preventive Dentistry, Primary Health Care Corporation, Doha, Qatar

²Department of Pediatric and Preventive Dentistry, A.B. Shetty Memorial Institute of Dental Sciences, Nitte (Deemed-to-be University), Mangalore, Karnataka, India

Address for correspondence Srikala Bhandary, MDS, Department of Pediatric and Preventive Dentistry, A.B. Shetty Memorial Institute of Dental Sciences, Nitte (Deemed-to-be University), Mangalore 575018, Karnataka, India (e-mail: drsrikalabhandary@nitte.edu.in; docsrikala@gmail.com).

J Health Allied Sci^{NU} 2025;15:136–138.

Abstract

Keywords

- dental anomalies
- dilaceration
- radiographic examination
- bi-rooted deciduous canines

Primary teeth have considerably fewer anomalies than permanent teeth. Rarely does a primary canine have two roots. This kind of strange abnormality could cause issues with exfoliation or extraction. The significance of anomalies must be emphasized to make a proper diagnosis and ensure a successful course of therapy. As far as we are aware, Dakshina Kannada district has never previously reported a maxillary deciduous canine with two roots. The objective of this case study was to raise awareness of the potential morphological changes in deciduous canines and to emphasize the implications of precise diagnosis and radiographic imaging from various viewpoints. To allow a better treatment outcome and prevent unintended problems, clinicians should take into account all potential tooth abnormalities or anomalies, following a periodic intraoral and radiographic evaluations.

Introduction

The shape, size, number, and dental tissue composition of both primary and permanent teeth can vary significantly. Primary teeth have far fewer abnormalities in tooth morphology than do permanent teeth.^{1,2} It has been determined that the single root type of primary canines is both regular and the most common type of root morphology.³ The deciduous canines typically have a single, long, and tapered root and exit in a single canal.^{4–6} Bi-rooted primary canines have only been documented a few times, are extremely uncommon, and have only been identified through radiographic analysis.

Only a few instances of a bi-rooted primary canine have been documented, with the first being in 1941.² Cases among children of Japanese, African American, Caucasian, and Pueblo Indian descent have been documented rarely.^{7–11} The primary canines with two roots have been observed to be more common in the upper jaw rather than the lower jaw and to occur bilaterally.³

The causative component is believed to be developmental problems that altered morphodifferentiation and differential growth of Hertwig's epithelial root sheath, resulting in an ingrowth of this tissue in the first stage of root formation.¹⁰ Due to the fact that bi-rooted canines do not cause any issues for the patients, there may be many cases that go unnoticed. Usually, a dentist will notice these root anomalies while doing a standard radiographic examination. It could cause issues with the eruption of permanent teeth, as well as during extraction and root canal therapy. Therefore, it will be beneficial to always keep this peculiarity in mind when inspecting and treating primary teeth.¹²

In the present case, a 4-year-old Indian boy's major maxillary canines displayed radicular bifurcation and root dilacerations of the mesial root, which is a morphological aberration. The article's objectives are to raise awareness of the morphological changes that can occur in deciduous canines and also highlight the significance of accurate diagnosis and radiographic imaging taken from various perspectives.

article published online
June 7, 2024

DOI <https://doi.org/10.1055/s-0044-1787555>.
ISSN 2582-4287.

© 2024. The Author(s).

This is an open access article published by Thieme under the terms of the Creative Commons Attribution License, permitting unrestricted use, distribution, and reproduction so long as the original work is properly cited. (<https://creativecommons.org/licenses/by/4.0/>)
Thieme Medical and Scientific Publishers Pvt. Ltd., A-12, 2nd Floor, Sector 2, Noida-201301 UP, India

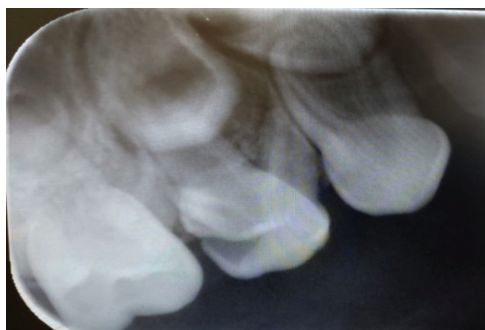


Fig. 1 Showing bi-rooted maxillary 53.

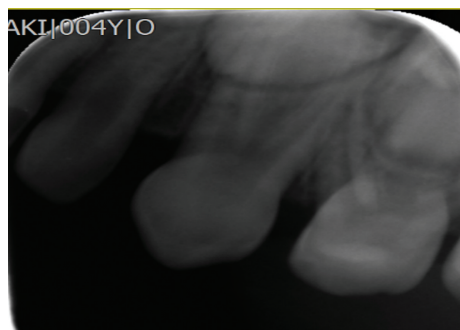

Fig. 2 Showing bi-rooted maxillary 63.

Case Presentation

The primary complaint of a 4-year-old kid who visited a pediatric dentist at a private dental office in Mangalore, Karnataka, India was pain and swelling in the upper right cheek. Patient was alert, afebrile, and had a normal gait. There were no additional medical issues. Upon doing an intraoral examination, it was discovered that there was gingival inflammation and disseminated swelling on the connected gingiva in relation to tooth 54 that had partially penetrated the mucogingival junction of tooth 54. Additionally, the patient had cavities in teeth at 84, 85, 74, and 64.

After the intraoral examination, an intraoral periapical radiograph (IOPA) was done as part of the treatment process, and it indicated extensive dentinal caries involving the pulp of 54 with interradicular radiolucency and lamina dura loss (► **Fig. 1**). In relation to 53, an unintentional discovery of a bi-rooted canine was made. Root dilaceration with respect to the 53's distal root was discovered during a second IOPA that used a different cone angulation to clarify and corroborate the initial discovery.

Following IOPA, it was determined that both major maxillary canines were bi-rooted with root tip dilacerations on the side that was contralateral to 63 (► **Fig. 2**). After that, an orthopantomogram (OPG) was done to confirm any other irregularities over the complete dentition (► **Fig. 3**).

Pulpectomies were done on 54, followed by glass ionomer cement restorations, composite restorations on 74, 84, and 85, and pit and fissure sealants on 75, 65, and 55. Five percent sodium fluoride varnish was used for topical fluoride treatment.

To monitor the eruption of the patient's normal permanent dentition and rule out any eruption anomalies connected to the maxillary anterior segment, the child's parents were told of the root abnormality.

Discussion

An uncommon dental abnormality is a main maxillary canine with two roots. Bi-rooted deciduous canines are more common in the maxilla rather than the mandible, and they are frequently seen on either arch.⁸ Additionally, children who are black and who are male are more likely to

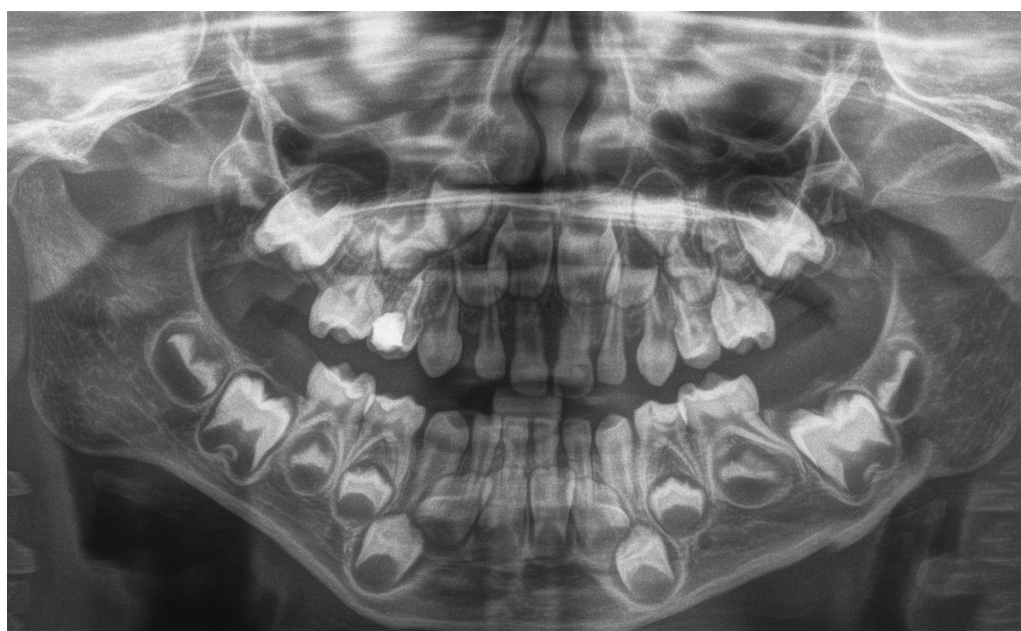

Fig. 3 Orthopantomogram (OPG) showing entire dentition (bi-rooted 53 and 63).

exhibit an increased prevalence.¹³ More boys than girls are observed to have the prevalence.¹⁴

In such situations, where a proper tooth morphology identification and diagnosis of the anomaly are required, a well-structured treatment plan is mandatory. Diagnostic radiographs are always an added benefit in spotting these asymptomatic, minor defects that a clinician frequently misses. Furthermore, multiangle periapical radiographs will be beneficial in locating the root dilacerations.

A routine intraoral examination cannot identify bi-rooted deciduous canines; however, they can be easily found during a routine dental radiograph examination. In the current instance, IOPA has determined that the major maxillary canine is bi-rooted, with a dilatation of the roots on both canines and a mesial and distal root. The right primary maxillary canine, on the other hand, showed a normal morphology with a slightly enlarged cervical third. The OPG, however, does not provide a clear-cut portrayal of bi-rooted morphology. Therefore, radiographic pictures must be carefully examined to deduce and identify details that could suggest the presence of bifurcations.^{15,16}

Bi-rooted tooth development, in contrast to single-rooted teeth, starts between 9 and 10 months after birth. While the gene that starts the differential growth of Hertwig's epithelial root sheath is usually thought to be more highly expressed in double-rooted teeth,¹² it has been seen that trauma or other abnormalities during morpho differentiation may impact root form and size in later stages.^{14,17} However, no history of direct or indirect trauma was mentioned in the present cases, and because the child was an only child, no reference of the same anomaly in siblings was made. Therefore, it seemed doubtful that any pertinent underlying causes for the bi-rooted primary maxillary canines would be discovered.

This atypical root structure may cause issues with endodontic treatment, difficult extractions, and delayed eruption of permanent teeth. When receiving endodontic treatment, it is important to keep in mind that there may be more root canals than there are roots. The dentist should take care during exodontic operations to avoid trapping the crown of the permanent tooth in the interradiaculal space of the primary tooth, as this could result in the unintentional extraction of the permanent tooth bud.

Conclusion

Specialists should explore all potential tooth polymorphisms during regular intraoral and radiological evaluations to

improve therapeutic efficacies and avoid unwanted consequences.

The existence of two roots in deciduous canines bilaterally cannot be attributed to a single etiology in the current study, hence additional research is needed for the proper management of this aberration.

Conflict of Interest

None declared.

References

- 1 Nelson SJ, Ash JR. Wheeler's Dental Anatomy, Physiology and Occlusion. 9th ed. St. Louis:: Saunders Elsevier;; 2010:48–67
- 2 Winkler MP, Ahmad R. Multirrooted anomalies in the primary dentition of Native Americans. *J Am Dent Assoc* 1997;128(07): 1009–1011
- 3 Uehara S. A practical guide for treating children [in Japanese]. *Nihon Shika Ishikai Zasshi* 1966;19(02):125–131
- 4 Burns RC, Buchanan LS. Tooth morphology and access openings. In: Cohen S, Burns RC, eds. *Pathways of the Pulp*. 6th. Boston, MA: Mosby; 1994:128–178
- 5 Ravi SV, Simon E, Thomas K, Ravi A. Maxillary canine with two root canals: a case report. *Indian J Dent Res* 2012;(06):69–71
- 6 Ten Cate AR. *Oral Histology: Development, Structure and Function*. 2nd ed. St. Louis:: CV Mosby Co.; 1985:69–72
- 7 Takano H. Supernumerary rooted primary mandibular right canine. *Shika Geppo* 1941;21:48–50
- 8 Mochizuki K, Ohtawa Y, Kubo S, Machida Y, Yakushiji M. Bifurcation, birooted primary canines: a case report. *Int J Paediatr Dent* 2001;11(05):380–385
- 9 Atac AS, Cetinguc A. Primary maxillary bi-lateral birooted canines: report of two cases. *Hacettepe Dishekimligi Fakultesi Dergisi* 2005;29:24–28
- 10 Orhan AI, Sari S. Double-rooted primary canines: a report of three cases. *J Indian Soc Pedod Prev Dent* 2006;24(04):204–208
- 11 Dhanpal PK, King NM. Bilateral bimaxillary bi-rooted primary canines: report of a case. *J Clin Pediatr Dent* 2009;34(02): 113–116
- 12 Ott NW, Ball RN. Birooted primary canines: report of three cases. *Pediatr Dent* 1996;18(04):328–330
- 13 Talebi M, Parisay I, Khorakian F, Bagherian M. Bi-rooted primary maxillary canines: a case report. *J Dent Res Dent Clin Dent Prospect* 2010;4(03):101–103
- 14 Assiry A. Bi-rooted primary maxillary canines: a case report. *J Med Case Rep* 2019;13(01):261
- 15 Ott NW, Ball RN. Birooted primary canines: report of three cases. *Pediatr Dent* 1996;18(04):328–330
- 16 Victorino FR, Bernardes RA, Baldi JV, et al. Bilateral mandibular canines with two roots and two separate canals: case report. *Braz Dent J* 2009;20(01):84–86
- 17 Sicher H. *Orban's Oral Histology and Embryology*. 5th ed. St. Louis:: Mosby; 1962:48–51