




Patient-Based Ratio Method for Permanent Zone Donor Area Calculation in Hair Transplant

Sudhanshu Punia¹ Aakanksha Goel¹  Amit Gupta¹

¹ Aesthetic and Cosmetic Plastic Surgery, Divine Aesthetic Surgery, Greater Kailash, New Delhi, India

Indian J Plast Surg

Address for correspondence Sudhanshu Punia, MBBS, DNB, MCh, Consultant, Divine Aesthetic Surgery, Greater Kailash, New Delhi 110048, India (e-mail: sudhanshupunia@gmail.com).

Abstract

Introduction Most common type of hair loss is androgenetic alopecia. Orentreich's donor dominance theory and the definition of safe donor area are the theoretical foundation of modern hair transplantation. In safe donor area no progression of permanent hair loss occurs. Its knowledge is important to prevent loss of transplanted hair. Estimation is not tailored to every patient, also in early stages, the margins are assumed to be free from future hair loss. Our study is an attempt to find and establish a relationship between safe zone dimensions and other standard scalp dimensions, and effectively predict the complete safe zone in early stages of hair loss.

Materials and Methods From July to December 2022, the first 100 patients with Norwood IV onwards of hair loss were included. Then, the distance between the vertex and the point of change in occipital hair quality and density was measured, and from this point till occipital protuberance were taken. The ratio between the two was taken. In the next 100 patients of Norwood II to IVa, the applicability of the new ratio to assess the permanent zone was used.

Results Ratio method takes into account the patient's measurements, that is, permanent zone and total distance from vertex occiput. The ratio range we got is: Permanent zone: total distance from vertex to occiput: 0.43–0.53

Therefore, the permanent zone would be equal to = total distance from vertex to occiput \times 0.43–0.53. With the lower limit being the occiput. Over 90% of the patients did not have significant reduction in density of transplanted hair.

Conclusion The authors suggest the use of this ratio method to determine the dimensions of the permanent zone especially in patients with early grades of hair loss as per the Norwood scale. It is a simple, effective, and easily applicable concept that can ensure long-lasting results in patients undergoing hair transplants.

Keywords

- ▶ ratio method in hair transplant
- ▶ divine permanent zone
- ▶ permanent donor zone

DOI <https://doi.org/10.1055/s-0044-1787655>.
ISSN 0970-0358.

© 2024. Association of Plastic Surgeons of India. All rights reserved. This is an open access article published by Thieme under the terms of the Creative Commons Attribution-NonDerivative-NonCommercial-License, permitting copying and reproduction so long as the original work is given appropriate credit. Contents may not be used for commercial purposes, or adapted, remixed, transformed or built upon. (<https://creativecommons.org/licenses/by-nc-nd/4.0/>)
Thieme Medical and Scientific Publishers Pvt. Ltd., A-12, 2nd Floor, Sector 2, Noida-201301 UP, India

Introduction

Hair loss is a common problem with androgenetic alopecia being the most common type. It is characterized by progressive thinning of the scalp hair and a reduction in hair density and diameter.¹

Most patients experiencing hair loss, lose hair from the hairline, bitemporal regions, and the frontal region, or if from the vertex, the anterior margin is first.²

The first hair transplant was performed by Orentreich³ who suggested the theory of “donor dominance,” which stated that the transplanted hair keeps the original nature of the donor site even after being transplanted. Donor dominance theory of Orentreich and the definition of a safe donor area are the theoretical foundation of modern hair transplantation.

The safe donor area is defined as an area in which no progression of permanent androgenic hair loss occurs.⁴

Knowledge of safe area is important so that the hair harvested for transplantation does not fall off and the harvest remains in the permanent zone. A number of authors have reported how to estimate the safe area, but we feel that the estimation is not tailored to every patient. In patients who do not have advanced stages of hair loss, the margins of the safe area are assumed to be free from future hair loss at the vertex.

In other words, there is no way to predict the exact dimensions of the safe zone for every individual.

Our study is an attempt to find and establish a relationship between the safe zone dimensions and other standard dimensions of the scalp, and to be able to predict the complete safe zone effectively in patients with early stages of hair loss.

Materials and Methods

The study was conducted in 200 patients presenting for hair restoration in a private center in India, from July 2022 to December 2022.

Patients with diffuse, unpatterned hair loss, and miniaturization in occipital scalp were excluded.

In the first 100 patients, patients with Norwood IV (► **Fig. 1**) onwards of hair loss were included. The permanent zone was drawn by marking a 2-inch area over the occiput, and in between two vertical lines drawn from the ears cranially (axis of pinna). This is the method we currently use. A line is drawn at the level of occiput, and then the cranial marking is made 2 inches above this line.

Then, the distance between the vertex (point A) and the point of change in occipital hair quality and density was measured (point B), and from this point till occipital protuberance (point C) were taken. The total distance (points A to point C) was measured (► **Figs. 2,3,4**). The ratio between the two (BC/AC) was taken and data was tabularized (► **Supplementary Table 1**, online in the online version).

Vertex is the superior most point of the skull, and occipital protuberance is defined as the highest point of the posterior part of the skull.

Hence, the vertex was the starting/cranial most point and occiput was the ending/caudal most point.

In the next 100 patients of Norwood II to IVa grade of hair loss were selected and the applicability of the new ratio to assess the permanent zone was used. The ratio was implemented to estimate the permanent zone in patients without a clear cut demarcation of the permanent zone (► **Supplementary Table 2**, available in the online version).

The zone was designed with the caudocranial direction calculated from the ratio, the marking of the zone curving toward the ears, 2 cm above the ears.

These patients were followed up closely for 10 months to see the longevity of the hair and final results. The study is an ongoing study to see the long-term results for hair transplant; the 10-month period is taken as it is the time when patients are told to see their final results.

Results

The ratio method takes into account the patient's measurements, that is, permanent zone and total distance from vertex occiput.

The ratio range we got is:

Permanent zone (BC): total distance from vertex to occiput (AC): 0.43–0.53

Therefore, the permanent zone would be equal to
= total distance from vertex to occiput \times 0.43–0.53.
With the lower limit being the occiput.

The dimensions received after using this formula were used to predict the craniocaudal dimension of the permanent zone. Note that 0.43 was used for patients with family history of advanced hair loss and 0.53 was used for those who did not have the same.

Ratios have been fixed at two values for ease of applicability, the highest and lowest values received were used as the average was not representative of the entire group, the higher value was used for patients with weaker family history of progressive baldness and lower value was for patient with stronger family history. This was done to avoid accidental erroneous use of a higher value (like mean) in patients with an actual low ratio value.

Note that the ratio 0.43 was used for a total of 41 patients and 0.53 for 59 patients.

All of our patients receive only platelet-rich plasma and no adjuvant medications like minoxidil or finasteride were given.

These results are tabulated (► **Table 1**). The presence of hair was checked by the density in 1 \times 1 cm area, by trichoscopic assessment in two separate areas, a pictorial comparison, and patients' input, after 10 months of the procedure. Any reduction greater than 10% was noteworthy and results were deemed inadequate in terms of hair longevity. It was seen that 90.24% of patients with 0.43 ratio and 94.92% of patients with 0.53 ratio did not have any noteworthy reduction of transplanted hair.

Therefore, overall 92.58% of patients recruited in the study did not have any noteworthy loss of transplanted hair.

The patients themselves reported that the transplanted hair were thicker than the existing ones.

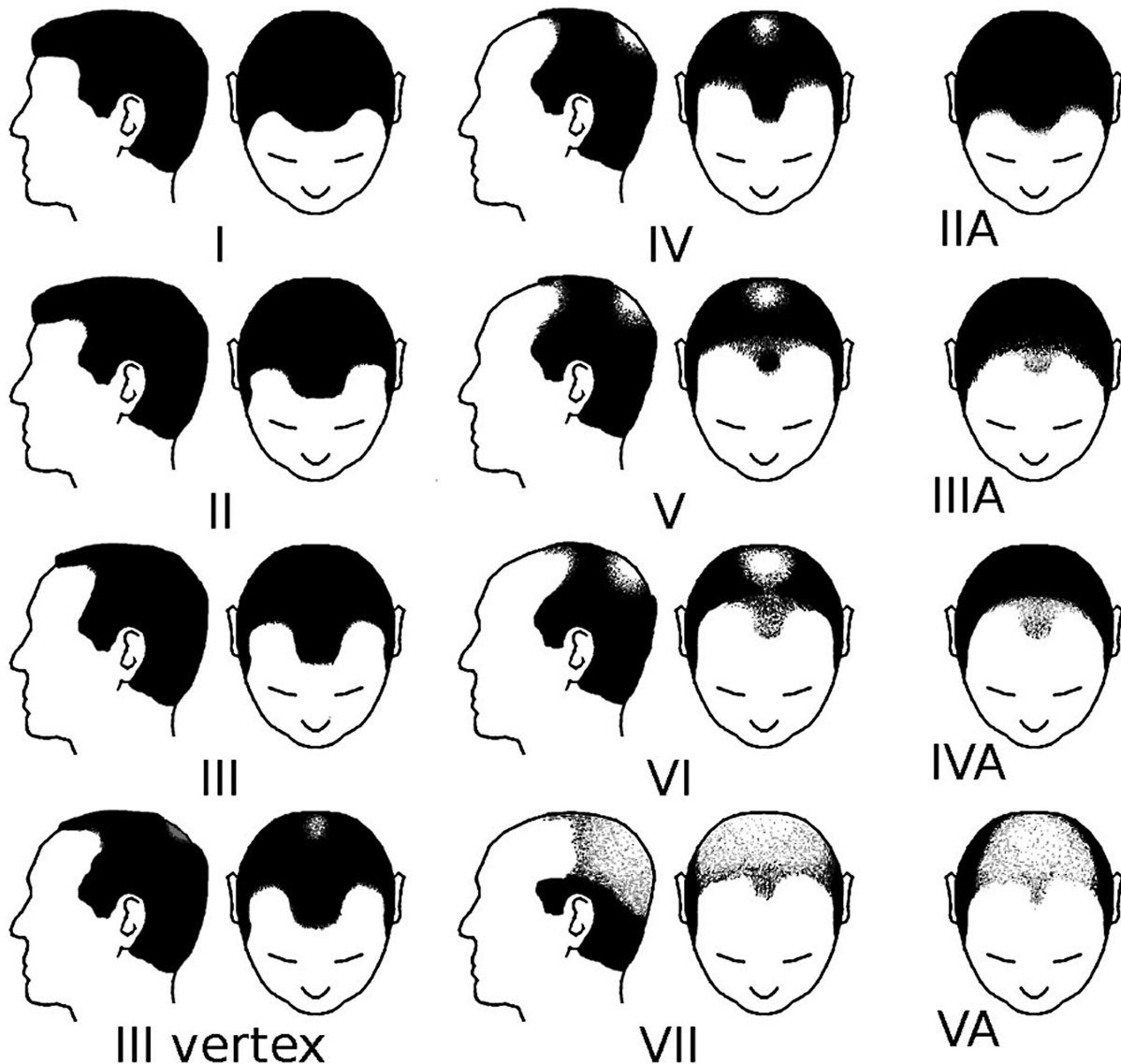


Fig. 1 Pictorial representation of Norwood classification.

Discussion

The androgen-sensitive miniaturization of the hair follicles is a pathognomonic symptom of hair loss, dihydrotestosterone (DHT) binds to specific androgen receptors resulting in changes in the hair follicles eventually resulting in hair loss.⁵

DHT can stimulate the growth of the hair follicles on the face, chest, and genital area, while inhibiting the growth of hair in the skin of the scalp. The safe area of the scalp is anticipated to have no invasion of alopecia even in high grades of hair loss, as this area is resistant to the effects of DHT.⁵

This is the basis of selecting this area for harvesting the hair grafts.

Various descriptions of safe zone are present.

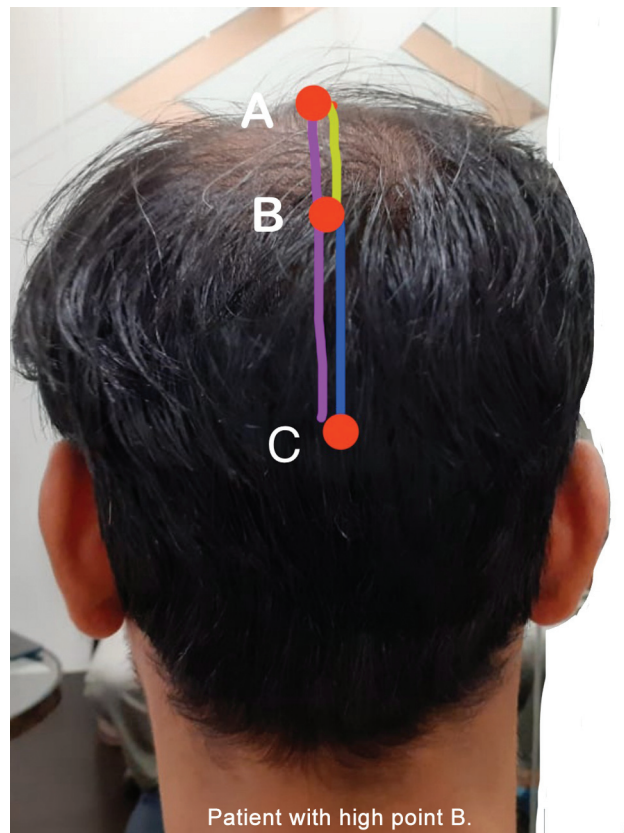
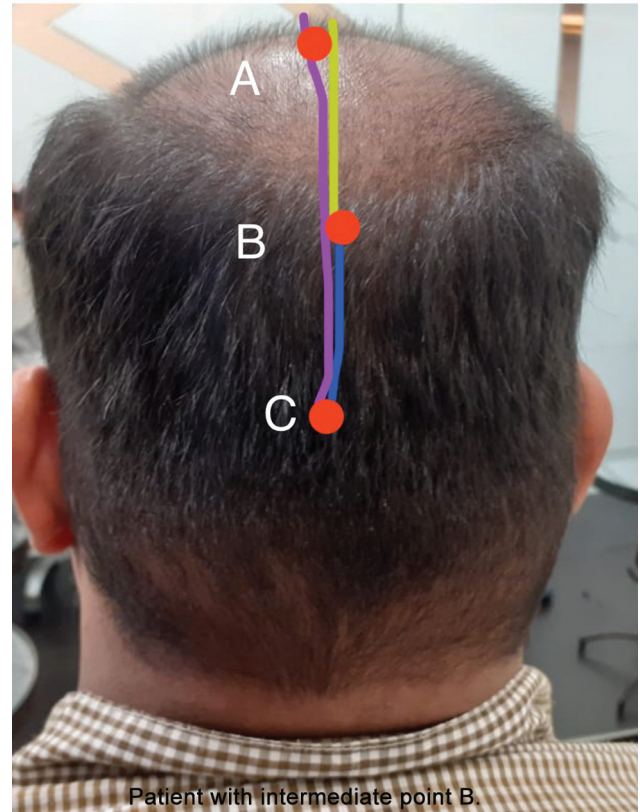
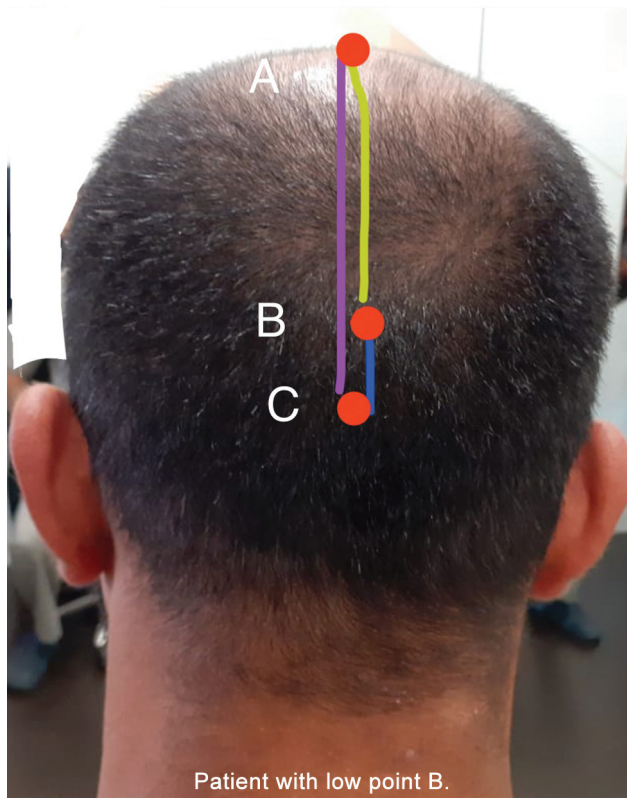
Unger's⁶ definition was in accordance with the facts that the global mean life expectancy was ≤ 80 years and $> 80\%$ of men aged between 70 and 79 years manifested baldness that is less than Norwood type VII. Unger described the dimen-

sions of the permanent zone as a line drawn upwards from tragus and another line 2 cm above the auricle which intersects with the occipital midline. The zone is 7 cm inferior from here.⁷

Cole and Devroye⁸ defined the total permanent donor area as 203 cm², which ranges 62 to 66 mm in the occipital region.

Bernstein and Rassman⁹ reported that the safe donor area accounted for approximately 25% of the entire scalp present in the occipital region. Rassman and Carson¹⁰ described three significant boundaries, anterior boundary, vertically superior to that of the external acoustic meatus, superiorly 2 cm above the upper border of the helical rim of the horizontal plane, and inferior border of the donor area is slightly controversial as it may move upward with the passage of time.

The most crucial and clinically critical standard for determining a safe donor area is the superior border, which is profoundly related to the maximum extent of vertex



Figs. 2, 3, 4 – figures showing. Point A- Vertex, Point B- point where density and quality of hair in occipital region change, Point C – Occipital protuberance. These figures show variability in dimension of permanent zone and this is why one design does not suit every patient.

Table 1 Outcome

	Patients with 0.43	Patients with 0.53
No noteworthy hair loss (< 10%)	37	56
Noteworthy hair loss (> 10%)	4	3
Percentage (%)	90.24	94.92

Note: Average percentage = 92.5%. Noteworthy hair loss: reduction greater than 10% of total number transplanted, results deemed inadequate in terms of hair longevity.

alopecia.¹¹ It is suggested to leave an area of 1 cm² under the line of miniaturization to avoid DHT-sensitive hair.

Also, there is no universally acceptable definition for the safe donor zone.^{12,13}

Occipital scalp has been used as the donor area, the hairs here are naturally androgen resistant and hence thought to be permanent.¹⁴

Hence, it is prudent that the hair absolutely be harvested from the exact permanent zone to achieve long-lasting results.

The area calculated from the ratio method was well within the estimated donor zone. As it took into account the dimensions of the patient's head, and the fear of accidentally taking DHT-sensitive hair was minimal.

On examination of the results at the end of 10 months, all transplanted hair were found to be growing well. For confirmation the density was checked in two separate 1 × 1 cm² areas.

Note that 90.24% of patients in whom 0.43 was used had no noteworthy hair loss; similarly, 94.92% patients retained the transplanted hair when 0.53 was used.

Overall, 92.58% patients had positive results. This showed that the transplanted hair were harvested from the permanent zone and estimation of permanent zone using the ratio method was correct.

Therefore, in our study we were able to establish that the calculated area was fully within the permanent donor zone and the hair can be harvested safely without the fear of future loss.

Conclusion

The authors suggest the use of this ratio method to determine the dimensions of the permanent zone especially in patients with early grades of hair loss as per the Norwood scale. It is a simple, effective, and easily applicable concept that can ensure long-lasting results in patients undergoing hair transplants.

Conflict of Interest

None declared.

References

- 1 Khumalo NP, Jessop S, Gumedze F, Ehrlich R. Hairdressing and the prevalence of scalp disease in African adults. *Br J Dermatol* 2007; 157(05):981–988
- 2 Hamilton JB. Patterned loss of hair in man; types and incidence. *Ann N Y Acad Sci* 1951;53(03):708–728
- 3 Orentreich N. Autografts in alopecias and other selected dermatological conditions. *Ann N Y Acad Sci* 1959;83:463–479
- 4 Knudsen RG. The donor area. *Facial Plast Surg Clin North Am* 2004;12(02):233–240
- 5 Hoffmann R, Happle R. Current understanding of androgenetic alopecia. Part II: clinical aspects and treatment. *Eur J Dermatol* 2000;10(05):410–417
- 6 Unger W. Delineating the safe donor area for hair transplanting. *J Am Acad Cosmet Surg* 1994;4:239–243
- 7 Goldsmith LA, Katz SI, Gilchrist BA, Paller AS, Leffell DJ, Wolff K. *Fitzpatrick's Dermatology in General Medicine*. 8th ed. New York, NY: McGraw-Hill Medical; 2012
- 8 Cole J, Devroye J. A calculated look at the donor area. *Hair Transplant Forum Intl* 2001;11:150–154
- 9 Bernstein RM, Rassman WR. Follicular transplantation. Patient evaluation and surgical planning. *Dermatol Surg* 1997;23(09): 771–784, discussion 801–805
- 10 Rassman WR, Carson S. Micrografting in extensive quantities. The ideal hair restoration procedure. *Dermatol Surg* 1995;21(04): 306–311
- 11 Park JH, Na YC, Moh JS, Lee SY, You SH. Predicting the permanent safe donor area for hair transplantation in Koreans with male pattern baldness according to the position of the parietal whorl. *Arch Plast Surg* 2014;41(03):277–284
- 12 Chouhan K, Kota RS, Kumar A, Gupta J. Assessment of safe donor zone of scalp and beard for follicular unit extraction in Indian men: a study of 580 cases. *J Cutan Aesthet Surg* 2019;12(01): 31–35
- 13 Kumaresan M, Mysore V. Controversies in hair transplantation. *J Cutan Aesthet Surg* 2018;11(04):173–181
- 14 Yepuri V, Mysore V. Effects of hormones on hair. In: Mysore V, ed. *Hair Transplantation*. 1st ed. New Delhi, India: Jaypee; 2016:21–23