



Versatility and Outcomes of ‘Mumbai Technique’ of Stacked Cartilage Grafts in Indian Rhinoplasty

Uday B. Bhat¹ Mangesh K. Pawar¹ Ishita Katyal² Amit Peswani¹ Sabyasachi Basu²
Sahil Abhay Waghmare¹ Abhishek Uday Dhakad¹ Udit Dalmia³

¹Department of Plastic Surgery, Topiwala National Medical College and Bai Yamunabai Laxman Nair Charitable Hospital, Mumbai, Maharashtra, India

²Department of Plastic Surgery, Tata Memorial Hospital, Mumbai, Maharashtra, India

³Department of Plastic Surgery, Breach Candy Hospital, Mumbai, Maharashtra, India

Address for correspondence Ishita Katyal, MCh, Department of Plastic Surgery, Tata Memorial Hospital, Mumbai 400012, Maharashtra, India (e-mail: drishitakatyal@yahoo.com).

Indian J Plast Surg

Abstract

Background Augmentation rhinoplasty requires graft with substantial volume. In cases where patient is reluctant to use costal cartilage, this can be done using septum and conchal cartilage graft. Using the technique of “stacked cartilage graft” an assembly is made using septum and conchal cartilage for nasal augmentation and contour defects. Although multilayered grafts have been described before, we propose an elaborate and effective method named after our city, Mumbai, to shape these grafts and highlight economical use of conchal and septal cartilage to overcome its limited volume. It also describes its clinical and aesthetic outcome of this technique in Indian patients.

Methods A retrospective study from 2005 to 2020 was done in our institute. Data was collected from medical and hospital records. Preoperative and postoperative photographs were obtained for preoperative planning and outcome analysis. Rhinoplasty Outcome Evaluation score was used for outcome analysis. Minimum follow-up was 1 year in our study.

Results A total of 210 patients were included in our study. In all cases, the stacked cartilage graft technique produced a natural appearing dorsum. Complications of cartilage such as resorption, extrusion, and warping were minimum. All the patients were satisfied with their results.

Conclusion Although the limited volume of conchal cartilage is criticized, in reality it can be used effectively for larger requirement with “economy of use” using our technique. The curvatures and convolutions of conchal cartilage can be effectively neutralized by using this technique to obtain a smooth surface.

However, this technique requires incorporation of every bit of cartilage and meticulous stacking of the pieces to get the desired shape. Thus, the stacked cartilage grafts have excellent versatility and produce natural and long-lasting results and minimal complications.

Keywords

- ▶ cartilage graft
- ▶ augmentation
- ▶ rhinoplasty

DOI <https://doi.org/10.1055/s-0044-1787658>.
ISSN 0970-0358.

© 2024. Association of Plastic Surgeons of India. All rights reserved.
This is an open access article published by Thieme under the terms of the Creative Commons Attribution-NonDerivative-NonCommercial-License, permitting copying and reproduction so long as the original work is given appropriate credit. Contents may not be used for commercial purposes, or adapted, remixed, transformed or built upon. (<https://creativecommons.org/licenses/by-nc-nd/4.0/>)
Thieme Medical and Scientific Publishers Pvt. Ltd., A-12, 2nd Floor, Sector 2, Noida-201301 UP, India

Introduction

The most common Indian nose encountered in our clinical practices lacks projection, therefore most of the patients require augmentation rather than a reduction¹ (►Fig. 1). This augmentation needs a graft material with substantial volume. For this purpose autologous cartilage grafts, for example, costal cartilage, are the best source. But when patient is reluctant for its use, we have conchal and septal grafts. The disadvantage with the use of conchal and septal grafts is that, it is limited in volume. However, using the Gillies principle of "economy of use,"² conchal and septal grafts can be used for augmentation. Every bit and piece of available conchal and septum cartilage graft can be combined to obtain a substantial volume. They can be assembled into single compact graft using the technique of "stacked cartilage graft." We describe the Mumbai technique of "stacked cartilage graft" for making an assembly for nasal augmentation and contour defects in Indian rhinoplasty patients. Our study highlights economical use of conchal and septal cartilage to overcome its limited volume. It also describes its clinical and aesthetic outcome of this technique in Indian patients.

Materials and Methods

This is a retrospective observational study from year 2005 to 2020. Pre- and postoperative photographs were used for preoperative planning and result analysis. Pre- and postoperative "Rhinoplasty Outcome Evaluation (ROE) score" was used for outcome analysis.³ Primary rhinoplasty patients who underwent cartilage grafting for dorsum augmentation, tip augmentation, and contour deformities were included.

Patients requiring structural reconstruction (excluding columellar strut), reconstruction and support for nasal ala, lateral wall, patients requiring spreader grafts, patients with past history of septal surgery or positive tip touch sign indicating loss of septal volume, and cleft lip nose patients were excluded.⁴

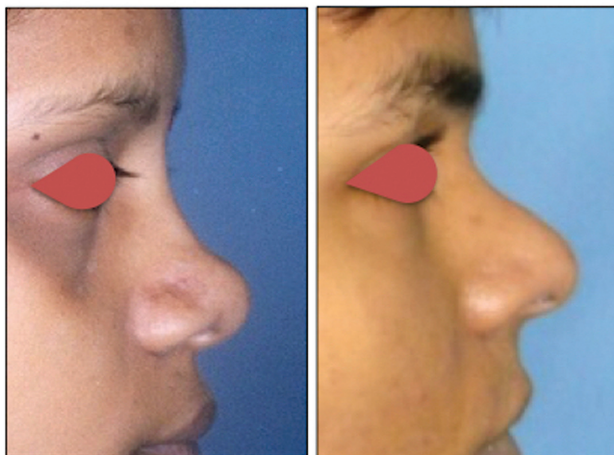

Fig. 1 Profile view of most common Indian noses showing "lack of projection."

A preoperative soap template to fill the deficiency was made. This was used as a guide tool for estimating the volume of the graft.

All procedures complied with the ethical standards of the institutional guidelines on human experimentation and with the Helsinki Declaration of 1975 revised in 2008.

Operative Technique

All the operations were performed under general anesthesia. Open approach was used in patients requiring additional maneuvers for nasal lengthening or shortening, correction of severe crooked nose, and domal sutures. Closed approach was used in patients requiring only tip graft, dorsal augmentation, and columellar strut. In closed approach, separate incision at the caudal septal margin was required for septal cartilage graft harvest. In either approach, the septal cartilage was harvested first, followed by harvest of unilateral or bilateral conchal cartilage as required.

The septum and conchal cartilage graft were assembled for augmentation as described below.

Stacked Cartilage Graft Technique Description

(1) Preparation of stacked cartilage graft using septum only (►Fig. 2)

Septal cartilage is naturally straight. Its edges are made smooth. The harvested piece is cut into long strips. Among these a long strip is used for columellar strut if required. And the rest of the strips are stacked on each other and sutured

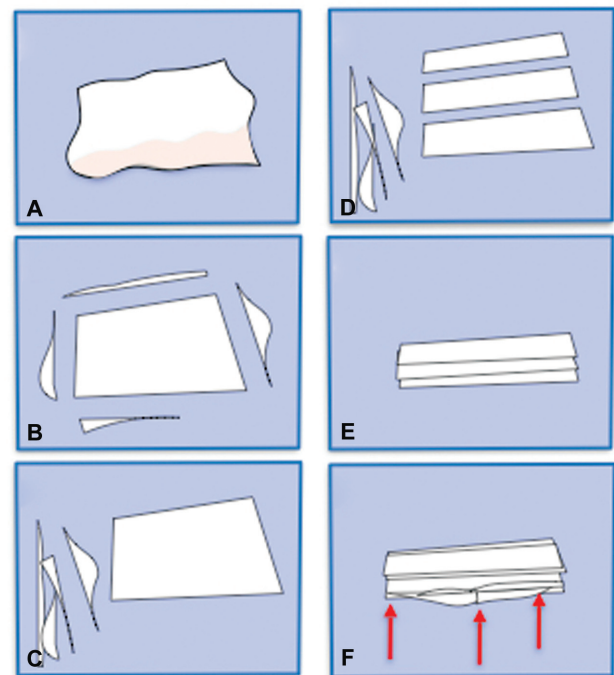


Fig. 2 Preparation of stack cartilage graft using septum only. (A) Septum cartilage, (B) edges are made smooth, (C) bits and pieces are not discarded and kept till the end for use, (D) broad piece cut into long strips, (E) strips are then stacked and sutured with 6-0 absorbable suture, (F) bits and pieces if needed are used on lateral and bottom side of assembly (red arrows).



Fig. 3 Final assembly of stack cartilage graft using septum cartilage only.

using absorbable 6-0 sutures. Remaining small pieces are not discarded but used to fill the irregularities of the stack. **►Fig. 3** shows final assembly prepared using septum cartilage.

(2) Preparation of stacked cartilage graft using conchal and septum cartilage (**►Fig. 4**)

As conchal cartilage is curved, its concavity is flattened by making crosshatches over the cup side. This opens the cup to make it flat. Sharp edges are then made smooth and the entire piece is cut into strips which are then stacked and sutured using absorbable 6-0 sutures. The top layer of this

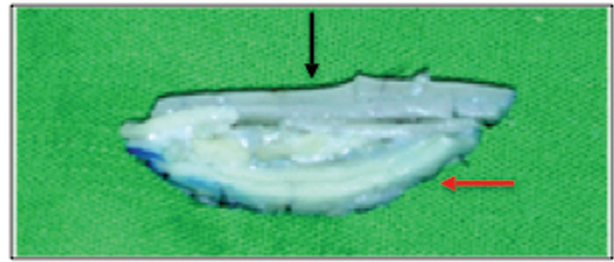


Fig. 5 Final assembly of stack cartilage graft using conchal and septum cartilage (red arrow is conchal cartilage and black arrow is septum cartilage).

assembly is then made using septal cartilage as it is naturally straight and holds the assembly together. Remaining small pieces if needed are used either on the lateral side or bottom side of the construct. **►Fig. 5** shows the final assembly prepared using conchal and septum cartilage.

This whole assembly is shaped according to the soap template made preoperatively. Grafts of different volumes and various shapes and sizes can be made using this technique (**►Figs. 6–8**).

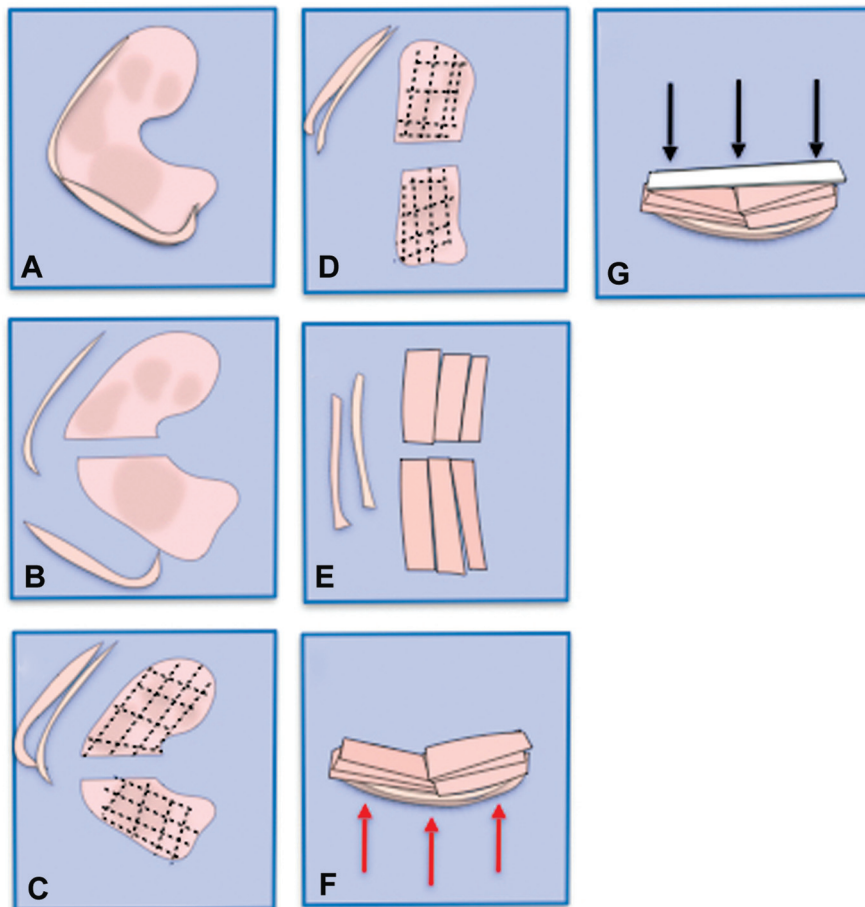


Fig. 4 Preparation of stack cartilage graft using conchal and septum cartilage. (A) Conchal cartilage is naturally concave/cup shaped, (B) edges are made smooth, (C) bits and pieces are not discarded and kept till the end for use, crosshatches made on concave/cup side, (D) warping leads to flattening of concave/cup side, (E) broad piece cut into long strips, (F) strips are then stacked and sutured with 6-0 absorbable, bits and pieces if needed are used on the lateral and bottom side of assembly (red arrows), (G) top layer is made by septum cartilage as it is naturally flat (black arrows).

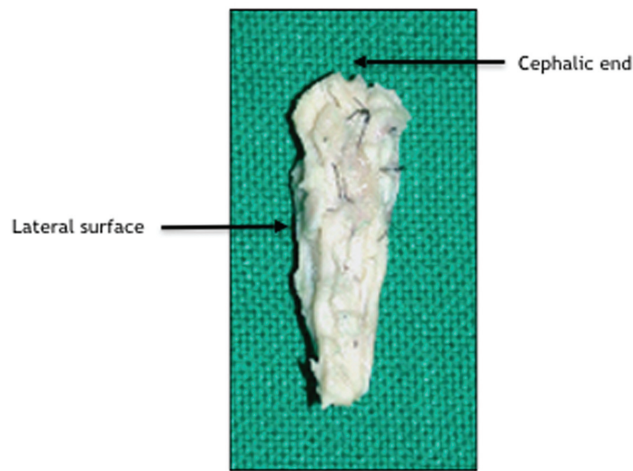


Fig. 6 Assembly of 25 pieces of cartilage graft.

The assembly is then inserted into the pocket and held in place with pullout sutures of nylon 6-0. Other maneuvers like domal sutures, columellar strut, osteotomies, alar wedge resection, etc. can be incorporated in the procedure. The shape of the newly draped envelope is maintained with porous adhesive tape and plaster of Paris. After 48 hours the plaster is removed to look for any displacement of the graft. The displacement, if any, is corrected by digital manipulation and the pullout sutures. The plaster is reapplied and kept for a week.

After surgery, patients were followed on outpatient basis to look for any complications. Minimum follow-up was 1 year in our study. Patients with less than 1 year of follow-up were not included in the study.

ROE score at the last visit was taken into account.

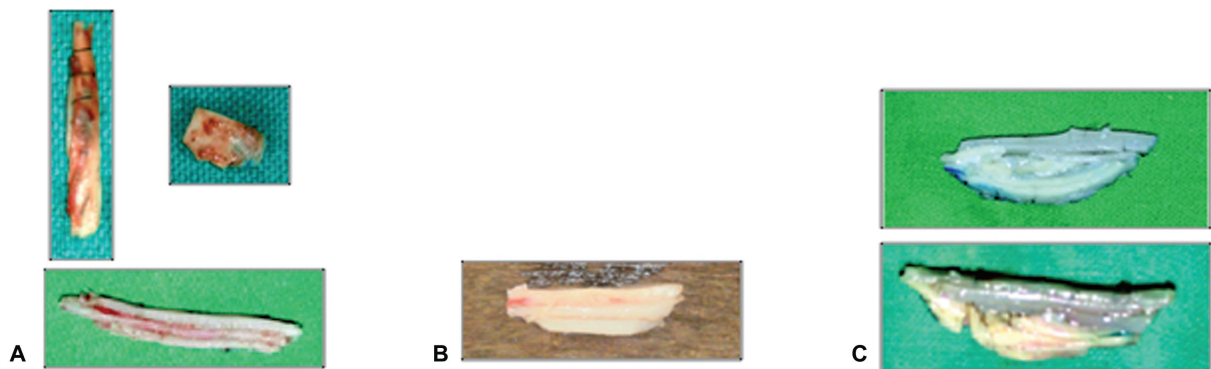


Fig. 7 Assembly of different volume made using the stack cartilage graft technique. (A) Small volume using either septal or conchal, (B) medium volume using septal and unilateral conchal graft, (C) large volume using septal and bilateral conchal graft.

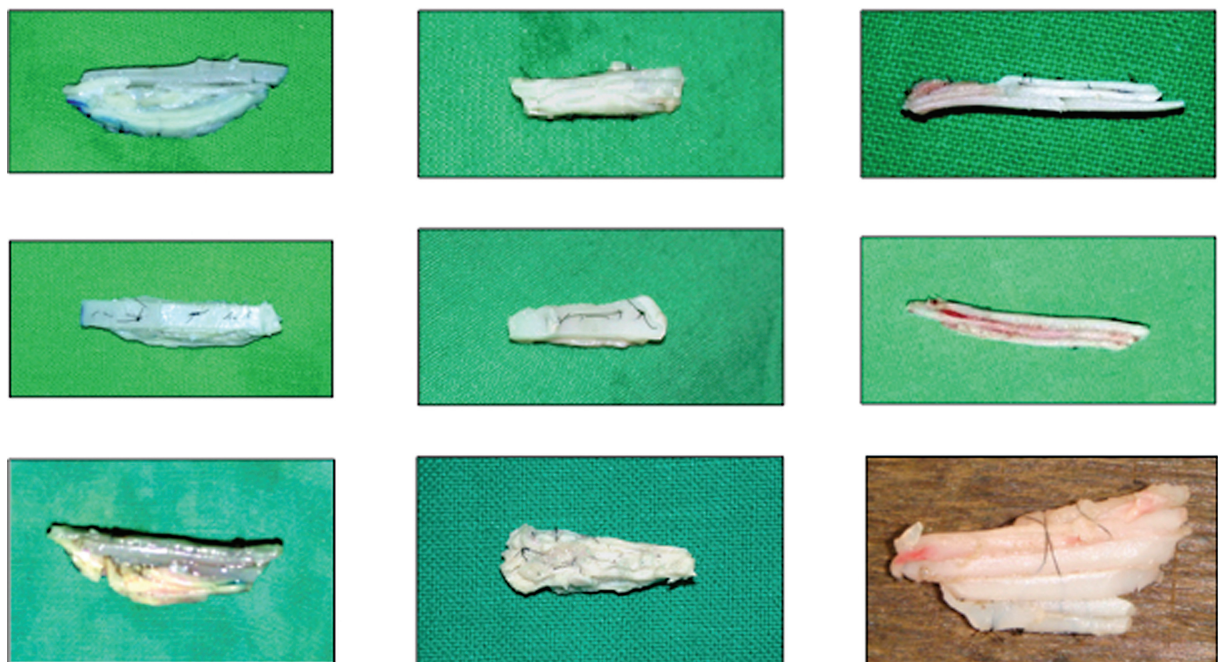


Fig. 8 Assembly of different sizes and shapes using the stack cartilage graft technique.

Table 1 Variety of indications where stack cartilage graft was used in our study

Dorsal augmentation	84
Tip augmentation	51
Contour fill	13
Dorsal + tip	62

Table 2 Complications following use of stack cartilage graft use

Displacement	21
Infection	1
Warping	0
Partial resorption	2

Results

Total 210 patients underwent augmentation rhinoplasty using cartilage graft assembly made by "stacked cartilage graft" technique. The largest graft was a 10-layered graft of conchal (bilateral) and septal cartilages; measuring 10 mm in thickness and 25 mm in length. There were 91 males and 119 females. The follow-up of the patient after surgery varied from 1 to 10 years. The assembly was used for various rhinoplasty indications, including dorsal augmentation, tip augmentation, combined dorsal and tip augmentation, and contour fill (► **Table 1**). Some complications such as infection, displacement, and partial resorption were noted (► **Table 2**). Resorption was seen in 2 patients with posttraumatic scarred bed. The displacement and infection were managed by manipulation and stepping up the antibiotics. There was no donor site morbidity. There was increase in postoperative ROE score in all patients excluding the 2 patients who had partial resorption. All the patients were satisfied with their results. In all cases, the stacked cartilage grafts produced a natural dorsum. Using this technique, warping and lack of volume were not found to be a problem.

Representative Cases

Patient 1 (► **Fig. 9**):

This lady underwent subtle augmentation of nasal dorsum. Using two-layered assembly graft (small volume) as onlay graft, good dorsal augmentation was achieved in this case.

Patient 2 (► **Fig. 10**):

A female with lack of projection, dorsum augmentation using a medium volume onlay graft assembly with additional maneuvers were performed—tip correction, osteotomies, and alar wedge resection.

Patient 3 (► **Fig. 11**):

Ill-defined nose was corrected using medium volume onlay graft assembly, osteotomies, tip correction, and alar wedge resection.

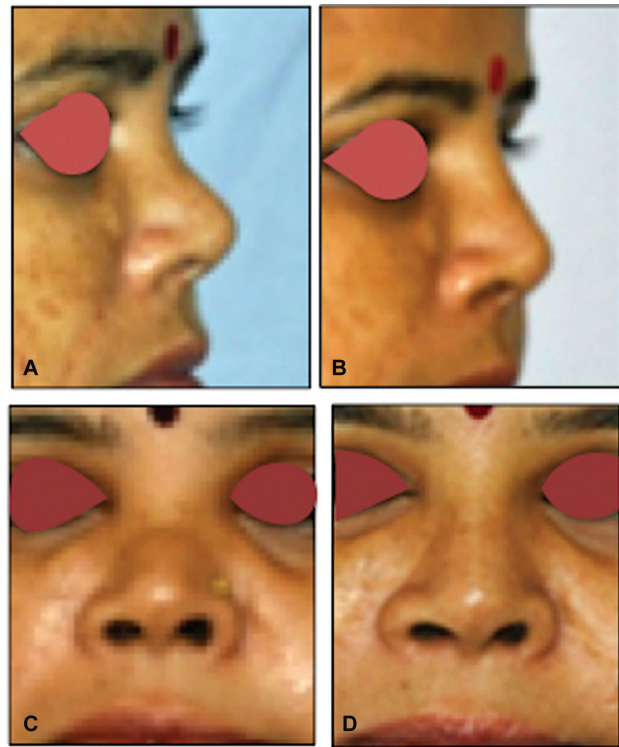


Fig. 9 Subtle dorsum augmentation using small volume assembly. (A) Lack of projection, (B) ill-defined nose, (C) good augmentation, (D) well-defined dorsal aesthetic lines.

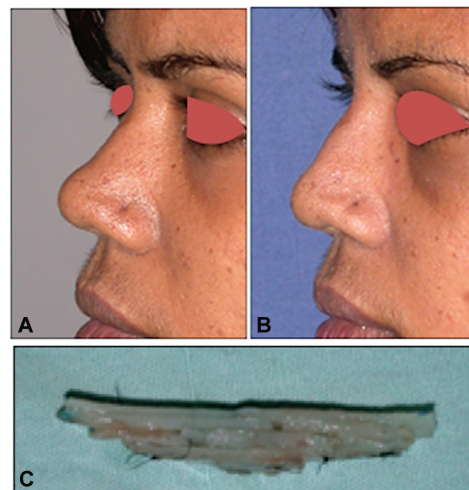


Fig. 10 Dorsum augmentation using medium volume assembly in female. (A) Dorsum deficient, (B) generous nasal augmentation, (C) graft assembly used in this case.

Patient 4 (► **Fig. 12**):

Posttraumatic nose deformity, onlay graft assembly used was 6 layered, osteotomies and tip correction were also performed in him.

Patient 5 (► **Fig. 13**):

A 10-year follow-up of patient who underwent correction of ill-defined nose. Ten-layered large volume assembly was used as an onlay graft measuring 10 mm wide and 25 mm in length.

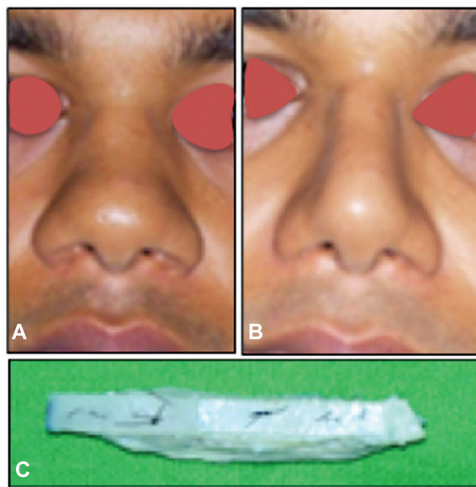


Fig. 11 Ill-defined nose, dorsum augmentation by medium volume assembly, osteotomies, and tip correction. (A) Preoperative, (B) postoperative, (C) graft assembly used in this case.

Patient 6 (→ Fig. 14):

A case of Parakeet nose, correction done by excision of overprojecting septum and lateral cartilages and the assembly used as onlay graft giving good dorsal augmentation.

Discussion

Out of the numerous options available for nasal augmentation, autologous cartilage graft is a better option.⁵

Among the various donor sites, the auricular cartilage provides a fair amount of graft when harvested from both the upper (cymba concha) and lower part (cavum concha). Moreover, the harvest can be done in the same operative field. Using stacked cartilage graft technique, one concha can usually provide up to a 4-mm thick assembly volume. Any additional amount of cartilage required can be obtained from the contralateral ear. Stacked together with a septal cartilage graft, one can obtain an almost 1-cm thick assembly for onlay in cases where large volume is required.

Although conchal cartilage is criticized for its convolutions and its curved nature, this can be overcome by cross-hatching, flattening, shaving of tubercle, and cutting it into multiple pieces followed by rearranging it to make a smooth surface (→ Fig. 4).

The costal cartilage is the largest source of autologous graft material and the donor of choice whenever a large amount of cartilage graft is required for augmentation. However, the harvest of costal cartilage is a relatively invasive and morbid procedure.⁶ Rib cartilage harvest involves the risk of pleural injury.^{6,7} Although comparatively well hidden, many people especially females disapprove a chest wall scar.⁸ Whereas conchal cartilage graft has no donor site deformity, also its scar is well hidden. However, in cases where abundant volume is needed, like in cases of cleft lip nose or total septal reconstruction, lateral wall grafts, and valve reconstruction, costal cartilage graft remains the option of choice. Other methods described with cartilage grafts are diced cartilage, crushed cartilage, and tandem

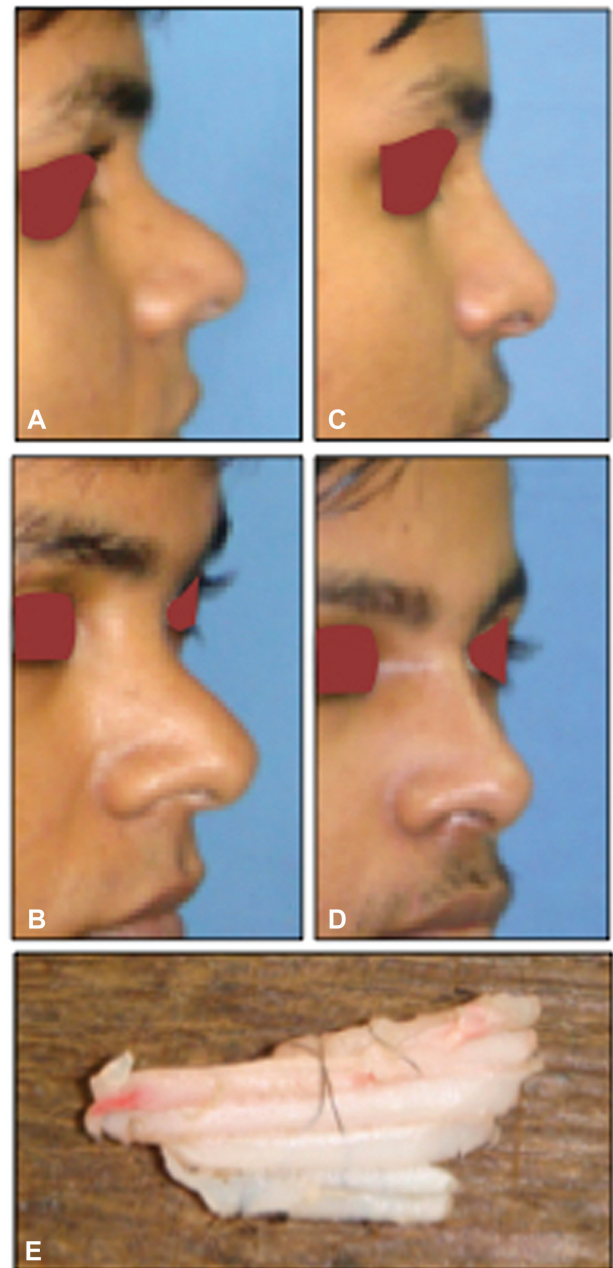


Fig. 12 Posttraumatic nose, correction by onlay graft, osteotomies, and tip plasty. (A, B) Dorsum deficient and lack of projection, (C, D) good dorsum augmentation, (E) 6-layered assembly onlay graft.

grafts. Diced cartilage is frequently used for dorsal augmentation and various variations of the technique have been described in literature. However, it has its own set of limitations including visible pebbling of the surface if not diced into sufficiently small pieces or in thin skin individuals.^{9,10} It is malleable and may yield to pressure.⁸ It can also lead to contour irregularities due to displacement of graft in the sleeve.^{9,11,12} Moreover, a separate incision is required to harvest the fascia unless one harvests the rectus abdominis fascia along with costal cartilage.¹³

The crushed cartilage grafts may have decreased survival of cartilage.¹⁴⁻¹⁷ It is generally used for small volumes.

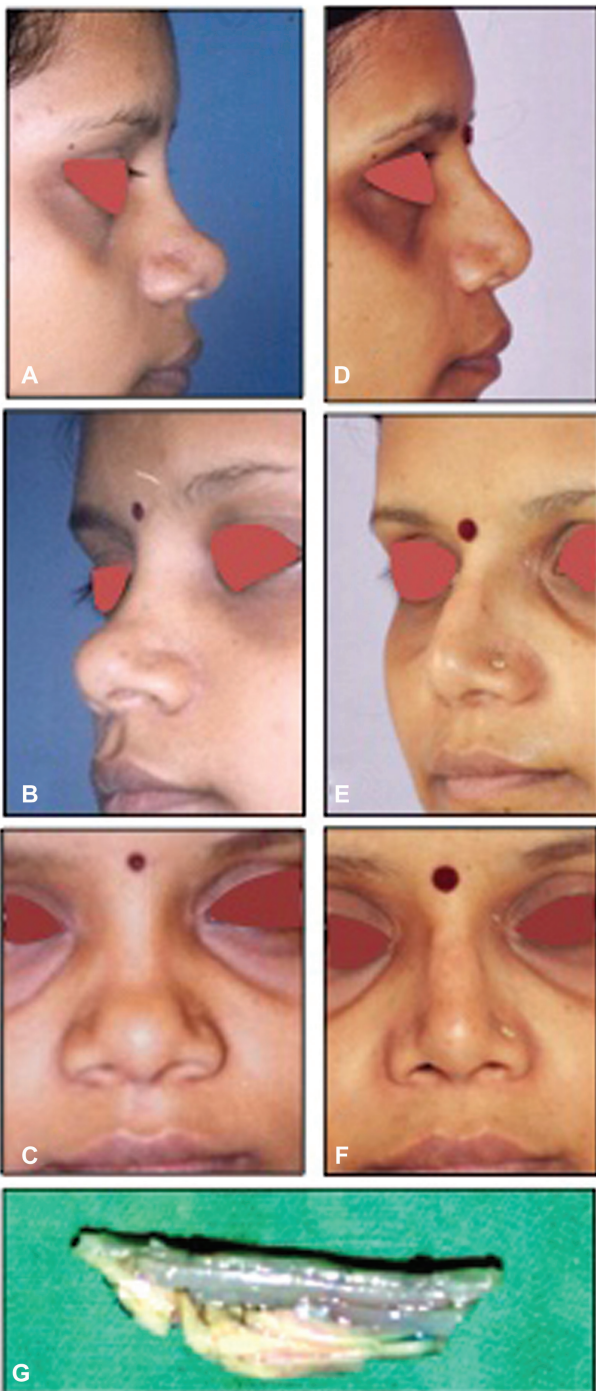

Fig. 13 Ill-defined nose onlay graft, osteotomies, and tip plasty. (A–C) Ill-defined nose, (D–F) result at 10 years, (G) largest volume graft assembly used: 10 layers, 10 mm thick and 25 mm in length.

Another technique called tandem graft employs two grafts, with one lying in front of the other like two riders on a bike.¹⁷ The cyma conchae graft is used as the upper tandem while the cavum conchae is split into two halves. Either one half is used as second tandem and the other as third tandem, or the other half can be used to increase the thickness of the lower tandem. This technique gives a very natural result. However, it is also limited by its use for limited augmentation. The complications include step deformity at

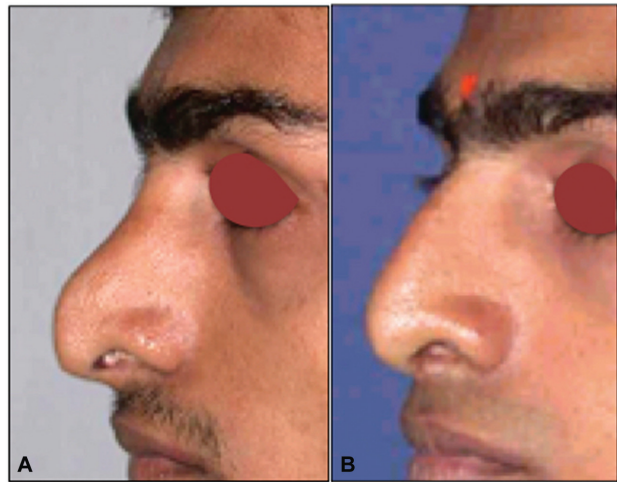


Fig. 14 (A) Case of "Parakeet nose," (B) correction done by assembled cartilage graft over dorsum and excision of projecting dorsal border of septum and lateral cartilages.

the junction of two tandem grafts, dorsal convexity, and contour irregularities.¹⁸

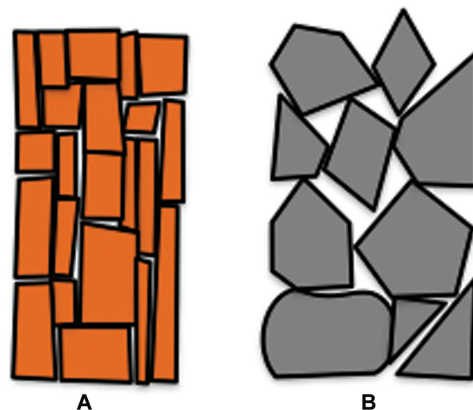


Fig. 15 (A) Stable assembly created by Mumbai technique, (B) "random rubble" unstable foundation is created in case cartilage strips are thicker and longer.

Stacked cartilage grafting is our preferred technique due to its certain advantages:

- (1) Carefully arranged cartilage strips avoid any irregularity of the constructs and provide an aesthetically pleasing natural contour.
- (2) It does not require wrapping in fascia as the sharp edges do not show through the thick skin. In fact, the technique allows contouring of the edges that they are neither too sharp nor too blunt, hence a better definition can be achieved.
- (3) Complications like resorption, warping, and infection are negligible.
- (4) Show excellent versatility in terms of achieving desired shape, volume, and long-lasting results.

Its use is limited to the cases where the grafts are used for contour restoration (dorsum augmentation, tip grafts, and contour fill), and this graft cannot be used for structural

reconstruction (creating a neoseptum, spreader grafts, and upper and lower lateral cartilage reconstruction).

Conclusion

Use of cartilage strips in two to three layers is not new.^{18–21} However, our technique describes utilization of numerous pieces sometimes as many as more than 20 and assembly of both regular and irregular shapes to increase the volume. The skill also lies in avoiding the random rubble-like foundation (→Fig. 15). To arrange these pieces and stack them in a desired shape can be likened to assembling the irregularly shaped pieces of the jigsaw to create a meaningful end product. The Mumbai Technique of stacked cartilage graft ensures economical use of every bit and piece of the septum and conchal cartilage to overcome the limited availability of volume.

It is an excellent option where patient is reluctant for costal cartilage harvest or where limited volume of cartilage is available. If the technique is utilized well, it can be used for a variety of indications especially dorsal augmentation and contour defects of nose giving long-lasting results with advantage of having minimal complications.

Conflict of Interest

None declared.

References

- Bhat U, Patel B. Primary rhinoplasty: an Indian perspective. *Indian J Plast Surg* 2008;41(suppl):S9–S19
- Pandey S, Chittoria RK, Mohapatra DP, Friji MT, Sivakumar DK. Mnemonics for Gillies' principles of plastic surgery and its importance in residency training program. *Indian J Plast Surg* 2017;50:114–115
- Izu SC, Kosugi EM, Brandão KV, et al. Normal values for the Rhinoplasty Outcome Evaluation questionnaire. *Rev Bras Otorrinolaringol (Engl Ed)* 2012;78(04):76–79
- Bhat U, Gupta T, Nair M, Mantri M, Pawar M, Baliarsing A. Three component cartilage framework reconstruction for correction of post-traumatic nasal septal collapse. *Indian J Plast Surg* 2017;50(03):236–243
- Peer LA. Cartilage grafting. *Br J Plast Surg* 1954;7:250–262
- Neligan PC. *Plastic Surgery*. London u.a. Elsevier Saunders; 2018
- Sheen JH. The ideal dorsal graft: a continuing quest. *Plast Reconstr Surg* 1998;102(07):2490–2493
- Safian J. Progress in nasal and chin augmentation. *Plast Reconstr Surg* 1966;37(05):446–452
- Daniel RK. Diced cartilage grafts in rhinoplasty surgery: current techniques and applications. *Plast Reconstr Surg* 2008;122(06):1883–1891
- Jang YJ, Yoo SH. Dorsal augmentation in facial profiloplasty. *Facial Plast Surg* 2019;35(05):492–498
- Lin SI, Hsiao YC, Chang CS, Chen PK, Chen JP, Ueng SH. Histology and long-term stability of diced cartilage graft for revision rhinoplasty in a cleft patient. *Plast Reconstr Surg Glob Open* 2016;4(06):e763
- Zholtikov V, Golovatinskii V, Ouerghi R, Daniel RK. Rhinoplasty: aesthetic augmentation with improvement of dorsal aesthetic lines. *Aesthet Surg J* 2021;41(07):759–769
- Cerkes N, Basaran K. Diced cartilage grafts wrapped in rectus abdominis fascia for nasal dorsum augmentation. *Plast Reconstr Surg* 2016;137(01):43–51
- Cakmak O, Buyuklu F, Yilmaz Z, Sahin FI, Tarhan E, Ozluoglu LN. Viability of cultured human nasal septum chondrocytes after crushing. *Arch Facial Plast Surg* 2005;7(06):406–409
- Rudderman RH, Guyuron B, Mendelsohn G. The fate of fresh and preserved, noncrushed and crushed autogenous cartilage in the rabbit model. *Ann Plast Surg* 1994;32(03):250–254
- Bujía J. Determination of the viability of crushed cartilage grafts: clinical implications for wound healing in nasal surgery. *Ann Plast Surg* 1994;32(03):261–265
- Hamra ST. Crushed cartilage grafts over alar dome reduction in open rhinoplasty. *Plast Reconstr Surg* 1993;92(02):352–356
- Gruber RP, Wall SH, Kaufman D. Open rhinoplasty: concepts and techniques. In: *Plastic and Reconstructive Surgery*. 2nd ed. Vol. 2 Philadelphia: Saunders (WB) Co Ltd.; 2005:491–492
- James DF. Controlling the stacking of cartilage grafts for nose tips. *Br J Plast Surg* 2004;10:1016
- Mao J, Carron M, Tomovic S, Narasimhan K, Allen S, Mathog RH. Cartilage grafts in dorsal nasal augmentation of traumatic saddle nose deformity: a long-term follow-up. *Laryngoscope* 2009;119(11):2111–2117
- Brenner MJ, Hilger PA. Grafting in rhinoplasty. *Facial Plast Surg Clin North Am* 2009;17(01):91–113, vii