



Management of Diffuse Carcinomatosis of the Bone Marrow from Occult Breast Cancer with Abemaciclib and Letrozole: Case Report and Literature Review

Ketan Makwana¹ Shaunak Valame¹

¹Department of Medical Oncology, Jawaharlal Nehru Cancer Hospital and Research Centre, Bhopal, Madhya Pradesh, India

Address for correspondence Ketan Makwana, MBBS, MD, DrNB Medical Oncology, Department of Medical Oncology, Jawaharlal Nehru Cancer Hospital and Research Centre, Bhopal 462001, Madhya Pradesh, India (e-mail: k.j.makwana1994@gmail.com).

Ind J Med Paediatr Oncol

Abstract

Occult breast cancer (OBC) signifies a rare subset of breast cancers, accounting for only 0.3 to 1% of all breast cancers. Diagnosing cancer of unknown primary requires a comprehensive approach, including histological examination, immunohistochemistry, multidisciplinary team assessments, and specialized therapy. We present the case of a postmenopausal woman diagnosed with OBC with diffuse carcinomatosis of the bone marrow (DCBM), which was hormone receptor positive and Her2neu negative. Treatment with aromatase inhibitor and the cyclin-dependent kinase 4/6 (CDK4/6) inhibitor abemaciclib yielded significant clinical improvement. The full potential of this therapy warrants investigation in real-world studies.

Keywords

- ▶ bone marrow metastasis
- ▶ cyclin-dependent kinase inhibitor proteins
- ▶ occult breast cancer

Introduction

In India, breast cancer has emerged as a significant concern. Its delayed presentation throws up unique challenges in management. Tumors metastasizing to the bone marrow, originating from nonhematologic malignancies, are well known from primary sites such as the lungs, breasts, stomach, and prostate.¹ Carcinoma of unknown primary (CUP) with disseminated carcinomatosis of the bone marrow (DCBM) represents a rare, advanced stage with a dismal prognosis. This case reports the causes of marrow suppression due to metastatic infiltration, and the challenges in diagnosing and management of DCBM.

Case Report

A 65-year-old postmenopausal woman presented with bony pains for 2 months. The pain interfered with her daily life and sleep. There were no comorbidities. Her Eastern Cooperative Oncology Group Performance Status (ECOG-PS) was 2. General

examination unveiled pallor and tenderness of both shoulder joints and the lumbar spine. Both her breasts and axillae were normal. The systemic examination was unremarkable.

Complete blood count showed bicytopenia (hemoglobin: 8.9 g/dL and platelet count: 95,000/mm³). Renal, hepatic function, and metabolic panel were normal. A bone marrow biopsy was conducted. The neoplastic cells were arranged in small clusters. Some were scattered singly. They were hyperchromatic and pleomorphic, with a few showing prominent small nucleoli and abundant pale to eosinophilic cytoplasm with signet ring cells suggesting a poorly differentiated carcinoma infiltrating the marrow. The tumor cells expressed cytokeratin, CK7, GATA3, GCDFP15, and estrogen receptor (ER)—Allred score 4 + 3 = 7/8 (▶ **Fig. 1A**), progesterone receptor (PgR)—Allred score 2 + 1 = 3/8 (▶ **Fig. 1B**), Ki67 < 10% (▶ **Fig. 1C**). They were immunonegative for CK20, p40, CDX2, Pax8, TTF1, and Her2neu score of 0 (▶ **Fig. 1D**), suggesting metastatic carcinoma from a breast primary (▶ **Fig. 2**). Bilateral mammosonography and magnetic resonance imaging (MRI) of the breasts were normal.

DOI <https://doi.org/10.1055/s-0044-1787710>.
ISSN 0971-5851.

© 2024. The Author(s).

This is an open access article published by Thieme under the terms of the Creative Commons Attribution License, permitting unrestricted use, distribution, and reproduction so long as the original work is properly cited. (<https://creativecommons.org/licenses/by/4.0/>)
Thieme Medical and Scientific Publishers Pvt. Ltd., A-12, 2nd Floor, Sector 2, Noida-201301 UP, India

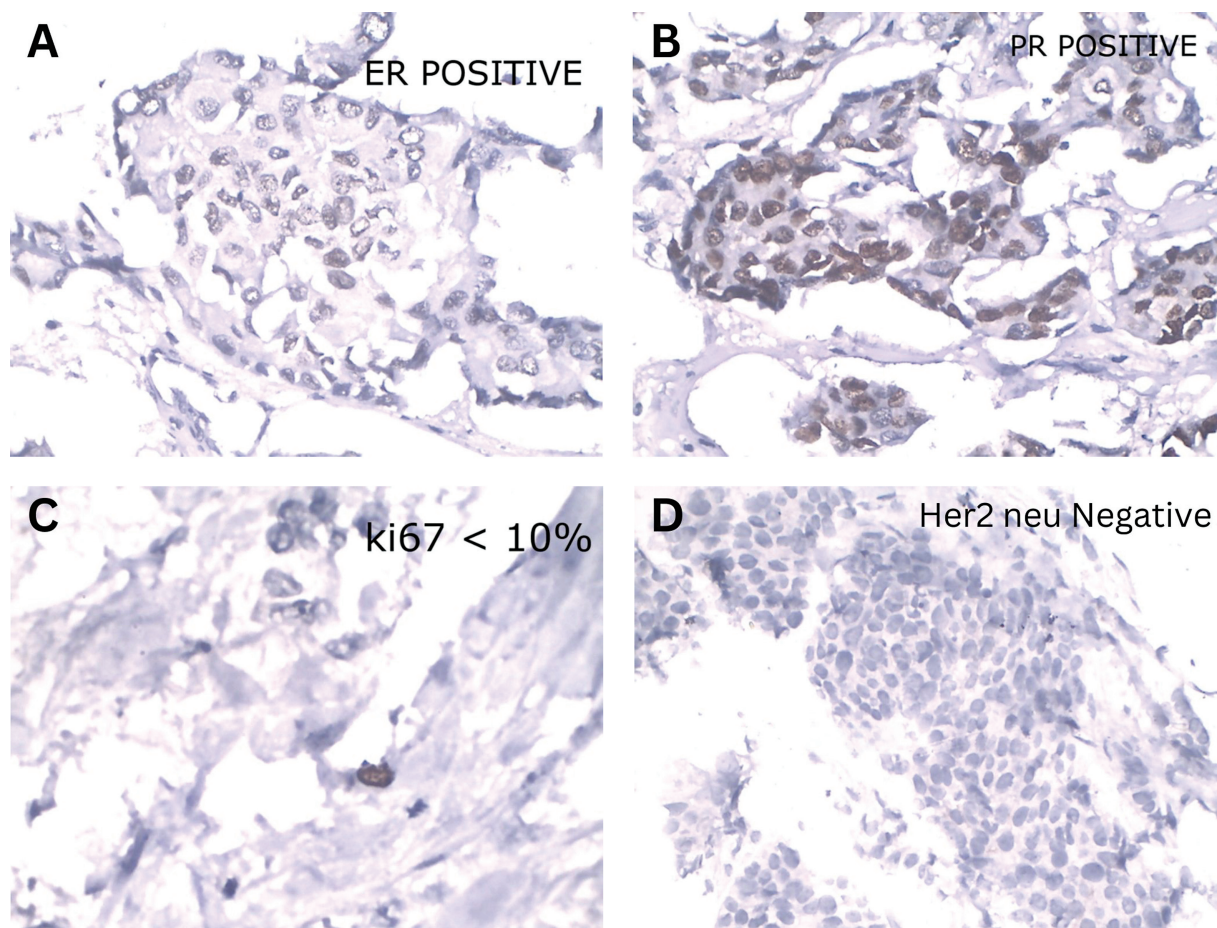


Fig. 1 Bone marrow biopsy specimen showing (A) strong staining for estrogen receptor (ER), (B) focal staining for PgR, (C) weak staining for Ki-67 and (D) negative staining for Her2 Neu.

Whole-body ^{18}F -fluorodeoxyglucose positron emission tomography with computed tomography (^{18}F -FDG-PET/CT) scan showed metabolically active lytic and sclerotic lesions involving almost the entire skeletal system, with no activity

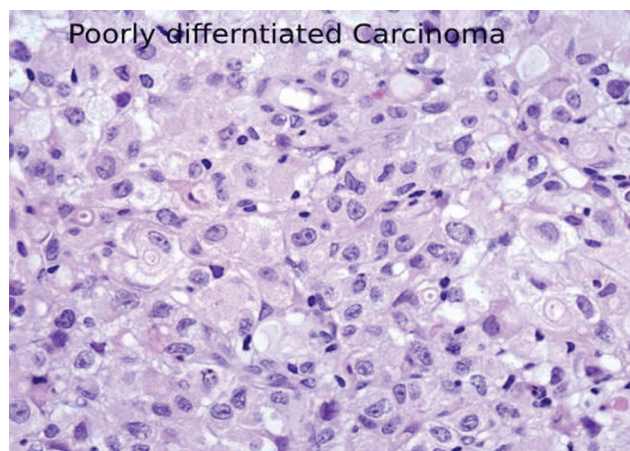


Fig. 2 Bone marrow biopsy showed involvement of myelofibrosis and metastases cells. The tumor cells are arranged in small clusters, scattered singly. The tumor cells are hyperchromatic and pleomorphic, few showing prominent small nucleoli and abundant pale to eosinophilic cytoplasm. Signet ring cells are seen.

elsewhere in the body (\rightarrow Fig. 3). Thus, a diagnosis of occult breast primary with DCBM was made.

A multidisciplinary tumor board discussion debated over the options of chemotherapy versus aromatase inhibitor (AI) with CDK4/6 inhibitor. It was opined that the cytopenias might worsen with chemotherapy. After explaining to the patient and her caregivers, in October 2022 she commenced treatment with oral abemaciclib at a dosage of 150 mg twice daily in conjunction with letrozole at 2.5 mg once daily.

The patient tolerated the treatment well for the first 2 weeks. She developed grade 3 diarrhea, which was managed conservatively. However, she suffered three such episodes over the course of the next 2 weeks. Abemaciclib was stopped for 1 week until the diarrhea resolved and was restarted with reduced dose of 100 mg twice daily. There were no further episodes of diarrhea. The patient was monitored monthly, and a gradual improvement in hemoglobin and platelet counts was seen without the need for blood transfusion.

In August 2023, a response assessment showed no definite evidence of any viable residual or metastatic disease on FDG-PET/CT scan (\rightarrow Fig. 4). Her treatment was continued.

Zoledronic acid 4 mg was given intravenously once in 3 months. At her last visit in January 2024, she had fully recovered from anemia and thrombocytopenia. Pain

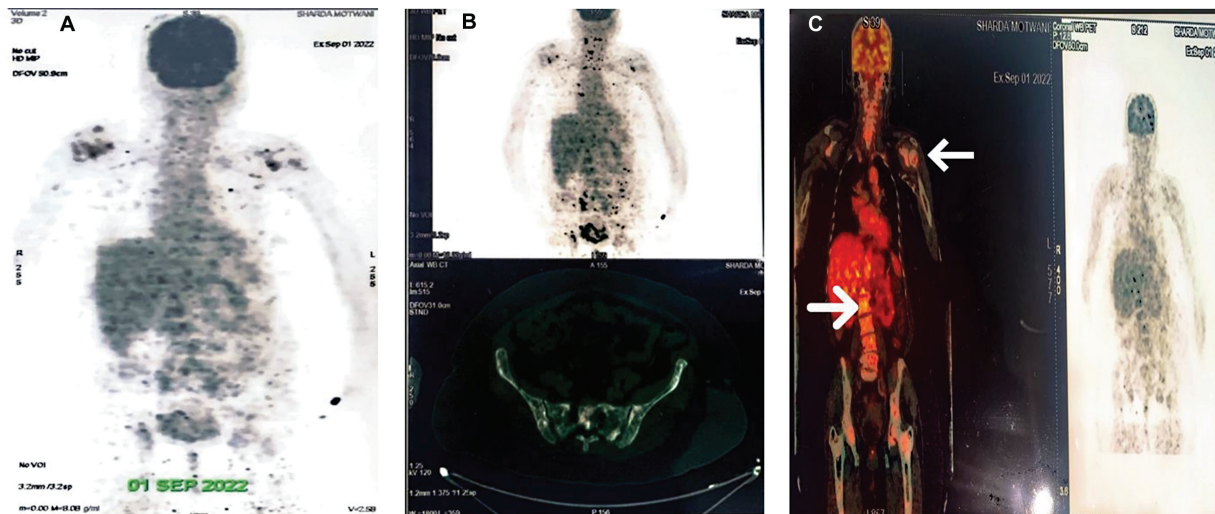


Fig. 3 (A–C) Whole-body fluorodeoxyglucose positron emission tomography and computed tomography (FDG-PET/CT) scan shows metabolically active lytic and sclerotic lesions (white arrows) involving almost the entire visualized skeletal system. There was no activity elsewhere in the body.

symptoms gradually improved and she stopped taking analgesics along with an improvement of the ECOG-PS from 2 to 0.

Discussion

Occult breast cancer (OBC) is a clinically identifiable metastatic carcinoma arising from a concealed primary breast tumor. This subset represents a mere 0.3 to 1% of all breast carcinomas, often presenting metastasis to the axillary and cervical lymph nodes as the initial manifestation of a CUP syndrome.² Because typical symptoms and clinical findings in the breast are lacking, diagnosis becomes challenging. Emphasis should be placed on conducting a thorough physical examination and imaging to locate the primary lesion and prevent misdiagnosis. In this patient, the presentation was with skeletal metastasis and bicytopenia. Only the immunohistochemistry (IHC) confirmed a DCBM. Anemia and thrombocytopenia frequently serve as the foremost clinical indicators in patients diagnosed with DCBM.³

For this patient, IHC analysis of bone marrow biopsy revealed positive staining with CK, GATA3, and gross cystic disease fluid protein-15 (GCDFP-15), which pointed to a primary from.

Managing patients with OBC with DCBM presents challenges due to associated cytopenia. Typically, systemic chemotherapy is recommended as primary treatment.^{4,5} However, chemotherapy may exacerbate preexisting cytopenias.

Anti-estrogens, while less rapid than chemotherapy in achieving a disease response, are better tolerated and do not exhibit myelotoxicity.⁶

CDK4/6 inhibitors combined with endocrine therapy (ET) are the standard of care for ER-positive/HER2-negative advanced breast cancer (ABC) in view of the substantial progression-free survival (PFS) benefit, overall survival (OS) advantage, and favorable toxicity profile.^{6–8}

However, studies investigating the effectiveness and safety of ET, either alone or in combination with CDK4/6 inhibitors, for metastatic breast carcinoma with DCBM are notably limited.

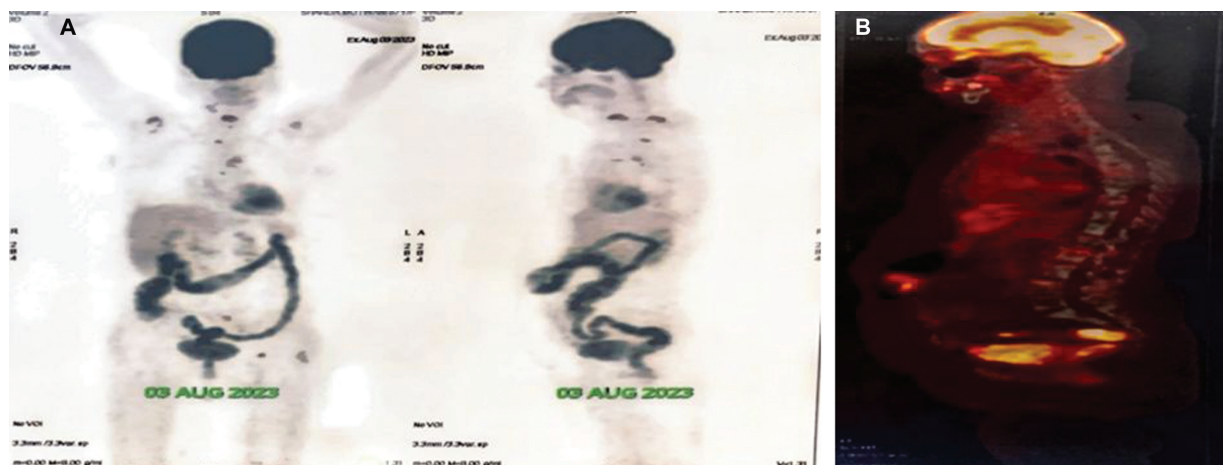

Fig. 4 (A, B) Whole-body positron emission tomography and computed tomography (PET/CT) scan shows no definite evidence of any viable residual/recurrent or metastatic disease anywhere in the whole body.

Studies such as MONARCH-2 and MONARCH-3 highlighted that abemaciclib, owing to its distinct pharmacodynamic profile, exhibits fewer hematological adverse events compared with palbociclib and ribociclib.^{7,9,10} The incidence of grade 3/4 neutropenia stands at 20% for abemaciclib, considerably lower than the 60% observed for palbociclib and ribociclib.⁸ With this rationale, abemaciclib and letrozole were started.

Nonetheless, a grade 3 diarrhea occurred, which required a one-step dose reduction of abemaciclib. Thereafter, the combination was tolerated well with complete metabolic resolution of the disease. Opting for ET alongside CDK4/6 inhibitors can emerge as a valuable treatment alternative. With a lower incidence of neutropenia among the available CDK4/6 inhibitors, abemaciclib seems to be the preferred drug.

Overall, the average survival time for patients with primary breast cancer who presents with DCBM is less than a year. There is, however, lack of data regarding OS in the era of CDK4/6 inhibitors. Our patient has completed 15 months of treatment (as of December 2023), and she showed good response. It remains uncertain for how long it will persist.

Conclusion

In summary, a combination of ET with a CDK4/6 inhibitor shows promise for providing clinical benefit compared with chemotherapy in DCBM. It demonstrates commendable response rates and time to response, closely resembling the efficacy observed with chemotherapy.

Moreover, this combination exhibits lower toxicity and leads to maintained quality-of-life outcomes. Typically, such patients are not enrolled in clinical trials. There is lack of data on the use of CDK4/6 inhibitors in patients experiencing visceral crises or those with life-threatening manifestations.

Patient Consent

Written consent has been obtained from the patient prior to submission and publication of this article.

Funding

None.

Conflict of Interest

None declared.

Acknowledgment

I would like to thank my patient and her family for giving support and publishing her report for betterment of other patients.

References

- Rani HS, Hui M, Manasa PL, et al. Bone marrow metastasis of solid tumors: a study of 174 cases over 2 decades from a single institution in India. *Indian J Hematol Blood Transfus* 2022;38(01):8–14
- Walker GV, Smith GL, Perkins GH, et al. Population-based analysis of occult primary breast cancer with axillary lymph node metastasis. *Cancer* 2010;116(17):4000–4006
- Yang R, Jia L, Lu G, Lv Z, Cui J. Symptomatic bone marrow metastases in breast cancer: a retrospective cohort study. *Front Oncol* 2022;12:1042773
- Shinden Y, Sugimachi K, Tanaka F, et al. Clinicopathological characteristics of disseminated carcinomatosis of the bone marrow in breast cancer patients. *Mol Clin Oncol* 2018;8(01):93–98
- Demir L, Akyol M, Bener S, et al. Prognostic evaluation of breast cancer patients with evident bone marrow metastasis. *Breast J* 2014;20(03):279–287
- Yamaguchi T, Masumoto M, Sakurai U, Nakane M. Disseminated carcinomatosis of the bone marrow from occult breast cancer responding to a sequence of endocrine therapy. *Case Rep Oncol* 2020;13(01):193–199
- Roncato R, Angelini J, Pani A, et al. CDK4/6 inhibitors in breast cancer treatment: potential interactions with drug, gene, and pathophysiological conditions. *Int J Mol Sci* 2020;21(17):6350
- Sledge GW Jr, Toi M, Neven P, et al. The effect of abemaciclib plus fulvestrant on overall survival in hormone receptor-positive, ERBB2-negative breast cancer that progressed on endocrine therapy-MONARCH 2: a randomized clinical trial. *JAMA Oncol* 2020;6(01):116–124
- Goetz MP, Toi M, Campone M, et al. MONARCH 3: abemaciclib as initial therapy for advanced breast cancer. *J Clin Oncol* 2017;35(32):3638–3646
- Preusser M, De Mattos-Arruda L, Thill M, et al. CDK4/6 inhibitors in the treatment of patients with breast cancer: summary of a multidisciplinary round-table discussion. *ESMO Open* 2018;3(05):e000368