





Gigantic Macromastia: Modified Superomedial Pedicle is a Good Solution

James Roy Kanjoor¹  Aakash Jain¹  Sathya Pakkiri¹

¹Roys Cosmetic Surgery Centre, Coimbatore, Tamil Nadu, India

Indian J Plast Surg

Address for correspondence James Roy Kanjoor, MCh, FRCS, Roys Cosmetic Surgery Centre, Coimbatore, Tamil Nadu 641043, India (e-mail: kanjoorjames@gmail.com).

Abstract

Background Reduction of very huge breast—gigantic macromastia—is a challenge to breast surgeons in choosing the right procedure to obtain an optimal outcome. The feasibility of a superomedial pedicle (SMP) with some modifications proves to be a good option to achieve a viable nipple areolar complex (NAC) with good size and shape after good resection above 800 g.

Materials and Methods Out of the 35 patients with 70 breast reductions, 15 can be considered gigantic macromastia with reductions above 800 g. A retrospective analysis of 30 breast reductions in these 15 patients from 2010 to 2023 was done. All cases were done using SMP with some modifications. The sternal notch to the nipple, the new NAC site, pedicle length, resection weight, and complications were analyzed. The modifications followed were lowering the new NAC, narrowing the distance between medial and lateral pillar width, medializing the pedicle, and lengthening the vertical limb.

Results There was no total necrosis of the NAC. Partial necrosis occurred in three patients that were managed conservatively and one case of fat necrosis needed debridement. All of them had a good size, shape, and form.

Conclusion SMP is a versatile technique with flexibility to modify the dimensions to get a robust blood supply to the NAC, after obtaining an adequate resection.

Keywords

- ▶ gigantic macromastia
- ▶ superomedial pedicle (SMP)
- ▶ nipple areolar complex (NAC)
- ▶ partial necrosis

Introduction

Huge breasts are heavy and the women suffer from a myriad of difficulties like breast pain, shoulder and back pain, shoulder strap marks, and intertrigo over the cleavage area and under breasts. The ill-fitting garments and the bullying remarks end up in psychosocial handicap.¹ Patients with symptomatic huge breasts usually seek surgical correction. Unlike small breast reductions where the aim is lift and aesthetics, the huge reduction targets a functional improvement. Gigantic macromastia is defined as an expected breast resection weight of 800 to 2,000 g or more.^{2,3} Any reduction of breasts loses its value if the outcome is not aesthetic and

functionally useless if sexuality of the nipple areolar complex (NAC) and breastfeeding ability of the postsurgical breast were lost. Usual recommendations for such macromastia are amputation and free nipple areolar grafting or inferior pedicle or bipedicle techniques.^{4,5} Amputation of the breast with a free nipple and areolar grafting usually results in partial or complete loss of the graft, pigmentary stigma, and above all loss of sensation and breastfeeding inability. The inferior pedicle too has vascular insufficiency⁶ and bottoming out issues. A well-vascularized NAC, medial ends, and lateral bulges are the difficult areas that restricted the ultimate aesthetic appearance. In a gigantic macromastia, the excess breast tissue at the medial margin tends to bulge

DOI <https://doi.org/10.1055/s-0044-1787721>.
ISSN 0970-0358.

© 2024. Association of Plastic Surgeons of India. All rights reserved. This is an open access article published by Thieme under the terms of the Creative Commons Attribution-NonDerivative-NonCommercial-License, permitting copying and reproduction so long as the original work is given appropriate credit. Contents may not be used for commercial purposes, or adapted, remixed, transformed or built upon. (<https://creativecommons.org/licenses/by-nc-nd/4.0/>)

Thieme Medical and Scientific Publishers Pvt. Ltd., A-12, 2nd Floor, Sector 2, Noida-201301 UP, India

more medially tending to cross the midline at the time of excising either as a dog ear or the scar crossing the midline predisposing to hypertrophy.

The lateral chest wall also shows the excess tissue of fat and skin as an unsightly fullness and a saggy fold, hindering sometimes adduction of the shoulder.⁷

Superomedial pedicle (SMP) is gaining popularity as a dominant procedure in all breast reductions. With few modifications, it has become a reliable technique in macromastia reductions.⁸

Materials and Methods

From 2013 to 2023 huge breast reductions where removal of greater than 800 g of tissue were retrospectively collected and analyzed for the demographics and the dimensions of the flap (►Table 1).

The modifications in the flap dimensions followed in the macromastia series evolved passively over the years. When compared with the actual dimensions and the final modified markings, few modifications established themselves as very dependable for a robust flap. The length–breadth ratio and the transposition angle with the pivot point appeared safe even in very long pedicles. The longest sternal notch–nipple (SN-N) was 42 cm and the highest resected weight was 2.1 kg. The usual new NAC site was 22 to 23 cm.

Modifications in the Design Followed by ►Fig 1A–C

1. When the new NAC site which was marked by the anterior projection of the inframammary fold (IMF) over the breast meridian was around 20 to 21 cm, it was lowered by 2 to 3 cm.
2. The medial and lateral pillars were shifted inside to reduce the width of the excision.
3. The vertical length of the pillars was usually 5 to 6 cm. When huge reductions were anticipated 1 to 2 cm lengthening resulted in 6 to 7 cm.
4. Medializing the SMP: shifting the base of the flap downwards on the medial pillar resulted in two favorable measurements—shortening the length and widening the base. The crucial help was the pivot being lowered thereby the transposition angle became less acute and avoided the risk of kinking and venous stasis.
5. The medial end of inverted-T was shifted a few centimeters laterally such that the incision lines at the sternal midline stayed apart. The tissues at this medial end were aggressively defatted which eliminated a bulge or dog ear (►Fig. 2).
6. The new NAC disc measurement was kept at 38 mm and the new NAC window was kept at 40 to 42 mm so that, after the inset the NAC gently stretched.
7. The lateral chest wall excess tissue was addressed by primary excision up to the midaxillary line in small and posterior axillary lines in huge folds. Bulges extending posteriorly were lipo-aspirated (►Fig. 3).

Preoperatively, it usually took 30 to 45 minutes to mark the new landmarks in standing position. These markings were measured and the necessary modifications were done to get a favorable length–breadth ratio (►Figs 4 and 5)

Total intravenous sedation was the preferred anesthesia. The pedicle was deepithelized with a new NAC of 38 mm and was incised carefully without a shearing force. A flap thickness of 1.5 cm at the tip and around 3 cm lower down close to the chest wall was dissected with coagulation diathermy. The breast tissue was excised all around—inferior, lateral, and superiorly leaving a flap thickness of 1.5 to 3 cm. The pedicle which was more medially designed was transposed to the new NAC window of 42 mm which was about 2 to 4 mm wider than the new NAC of 38 mm. The medial and lateral pillars were closed with 2-0 Vicryl for glandular tissue and 3-0 Monocryl for subcuticular closure. The new NAC was inset in a layered fashion. The lateral chest was suctioned. Steri-Strip reinforcement was done all along the suture line. No drain was used. Waterproof dressing was applied leaving a small vent around the nipple. A supportive medical bra of the correct size was applied on the table and recommended for 4 weeks. Prophylactic intravenous antibiotic cephalosporin followed by oral for 5 days was given. Patients were usually discharged the same evening or the following morning. Patients were reviewed on postoperative days 3 and 10 with the change of dressing. Scar prophylaxis with silicone gel was started from the third week onwards and continued for 3 months.

Results

The overall outcome after starting to follow these modifications was encouraging. Thirty breasts in 15 patients were included in this cohort.

Patient demographics and comorbidities are listed in ►Table 2.

The mean age was 36.4 ± 8.6 years. The mean body mass index was 35.02 ± 3.4 , on an average >800 g weight of breast resected each side and the highest being 2,100 g. Regarding surgical technique, a modified SMP was used in all cases. The mean SN-N measurement was 34.45 ± 4.4 cm. There was a 26.6% rate of any complications, the majority of which were minor, including any wound healing complications, partial nipple necrosis (20%), and fat necrosis with intervention (6.6%). There was no statistically significant difference in breast reduction complications and outcomes using the SMP, regardless of the SN-N distance, mean distance (cm) (36 ± 6.5) cm, and excised weight of the breast (1317.5 ± 602.5) g. The mean follow-up time was 40.5 ± 8.1 months.

Surgical Complications

Complications are listed in (►Table 3). During the early period, we had three partial necrosis of the NAC which were managed conservatively. There was no complete loss of nipple. Two breasts in one patient presented with hard areas indicative of fat necrosis. One breast had fat necrosis which needed debridement. There were no hematomas or seromas and no T junction necrosis. There were no systemic

Table 1 Master chart for breast reduction

Sl.no.	Age	BMI	SN-NAC (cm)		Old-areolar diameter (mm)		New areolar diameter (mm)		Pedicle length (cm)		Weight excised (g)		New-NAC site (mm)		Medial to lateral-vertical line (cm)		Complications
			RT	LT	RT	LT	RT	LT	RT	LT	RT	LT	RT	LT	RT	LT	
1	32/F	28.5	33	33	76	76	38	38	9 × 8	9 × 8	800	800	23	23	12	12	–
2	24/F	25.8	30	31	92	92	42	42	10 × 12	10 × 12	1274	1119	24	24	13	13	–
3	37/F	36	42	42	81	83	42	42	10 × 12	10 × 12	1800	2100	24	24	12	12	–
4	30/F	44.7	41	41	85	85	42	42	10 × 8	10 × 8	1950	1800	26	26	13	13	Fat necrosis with intervention
5	28/F	37.5	38	38	70	70	38	38	12 × 8	12 × 8	1276	1191	24	24	12	12	–
6	46/F	31.9	27	27	80	80	41	41	10 × 8	10 × 8	822	820	20	20	10	10	–
7	56/F	36.8	42	42	100	100	42	42	12 × 8	12 × 8	1075	1100	24	24	12	12	–
8	40/F	34.5	34	33.5	66	63	38	38	10 × 8	10 × 8	910	930	23	23	12	12	–
9	28/F	28	34	33	70	70	36	36	9 × 8	9 × 8	815	845	24	23	13	13	–
10	34/F	35.1	32	32	56	56	42	42	10 × 8	10 × 8	835	860	23	23	10	10	Partial nipple necrosis
11	38/F	36	38	38	75	75	40	40	10 × 8	10 × 8	810	805	24	24	12	12	–
12	37/F	31.6	30	30	80	80	40	40	12 × 8	12 × 8	835	815	22	22	10	10	–
13	39/F	39.6	39	39	68	66	38	38	15 × 8	15 × 8	1800	1800	24	24	13	13	Partial nipple necrosis
14	43/F	34.5	37	37	90	90	42	42	12 × 8	12 × 8	940	960	22	22	12	12	Partial nipple necrosis
15	35/F	44.8	35	35	100	100	42	42	13 × 8	13 × 8	1000	1125	24	24	13	13	–

Abbreviations: BMI, body mass index; F, female; LT, left; M, male; NAC, nipple areolar complex; RT, right; SN, sternal notch.

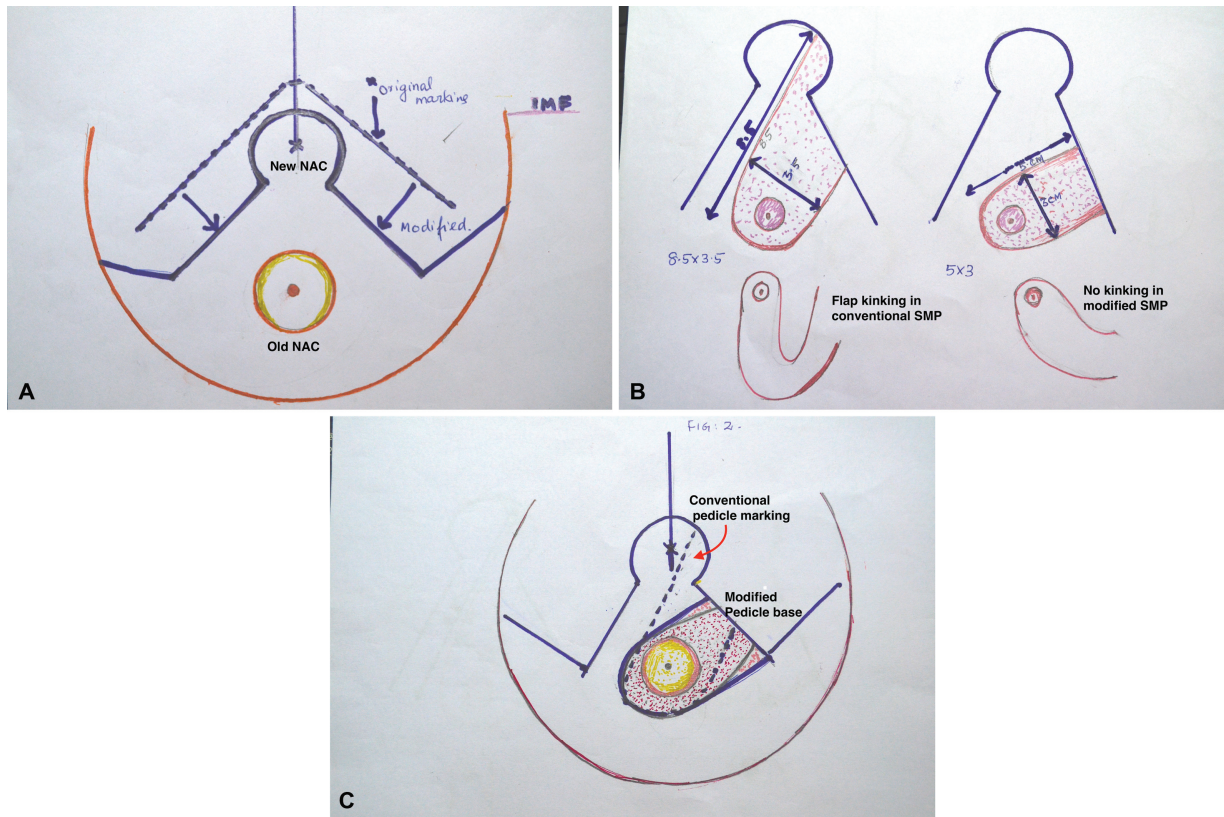


Fig. 1 Diagrammatic representation of the modifications follows: (A) Modification number 1. (B) Modification number 2. (C) Modification number 3.

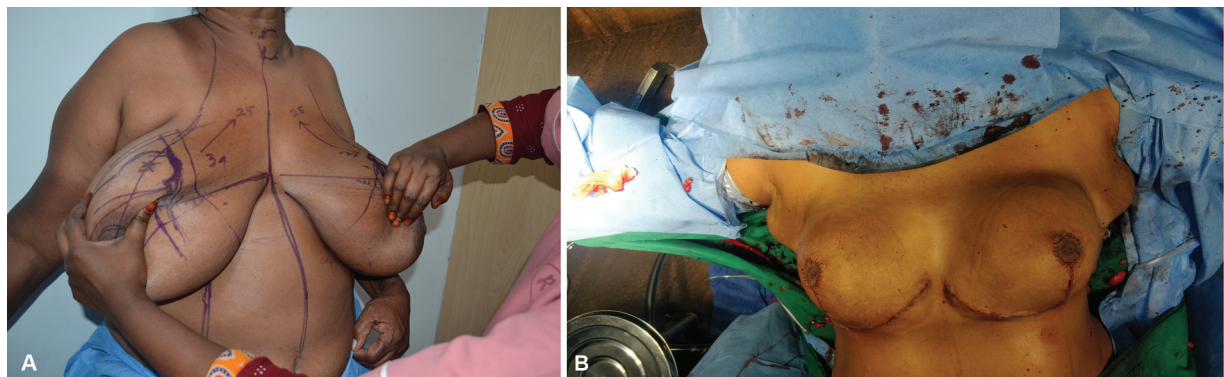


Fig. 2 (A) The medial end of the incision was foreshortened more laterally to avoid meeting at the midline. (B) On table result.

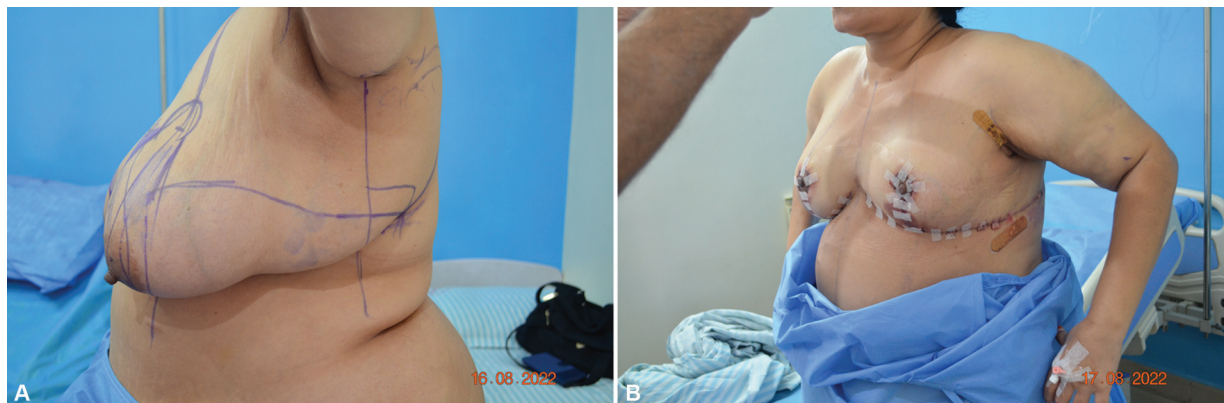

Fig. 3 (A) Lateral chest wall deformity in huge breast. (B) Immediate postop after concomitant excision and liposuction of lateral folds.

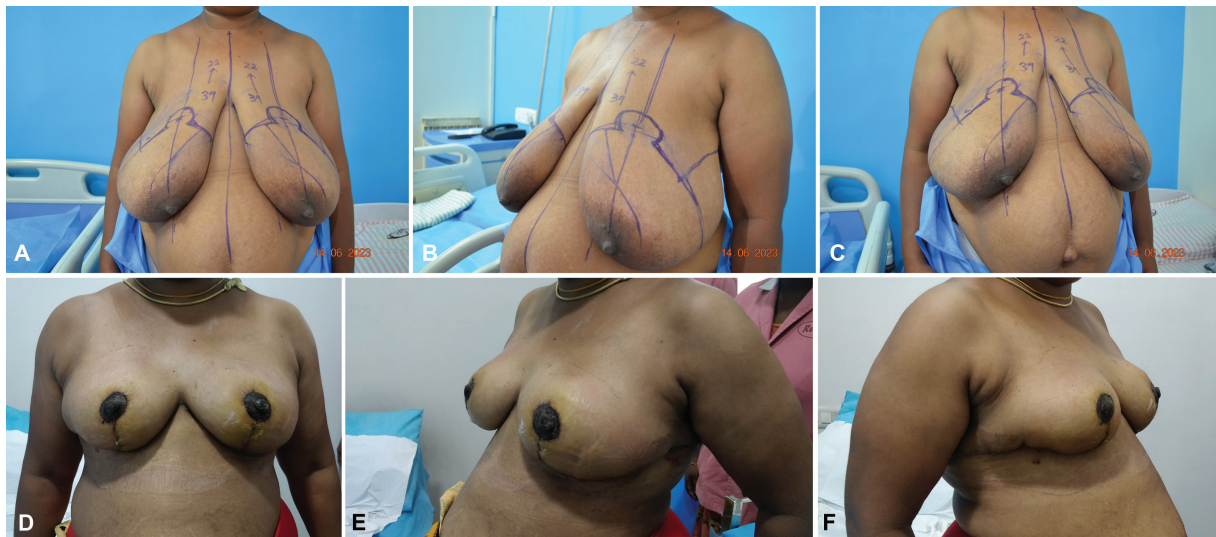

Fig. 4 (A) Front view of gigantic macromastia patient 1. (B) Left oblique view. (C) Right oblique view. (D) Postop frontal view after resection of 1.5 kg of the right breast and 1.4 kg of the left breast. (E) Postop right oblique view. (F) Postop left oblique view.

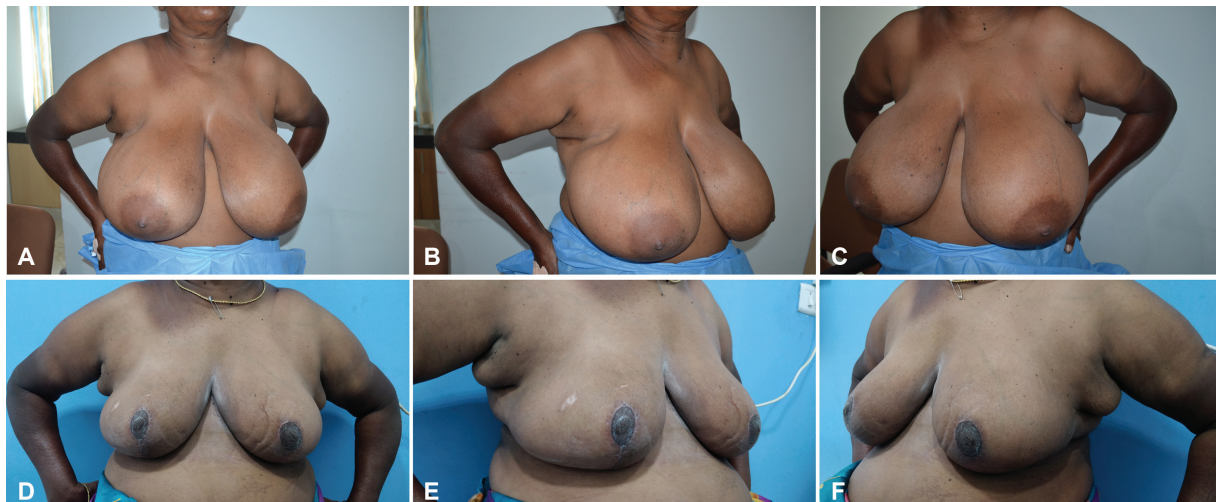

Fig. 5 (A) Front view of gigantic macromastia patient 2. (B) Right oblique view. (C) Left oblique view. (D) Postop frontal view after resection of 1.8 kg of the right breast and 1.7 kg of the left breast. (E) Postop right oblique view. (F) Postop left oblique view.

Table 2 Patient demographics and comorbidities in the study cohort

Sl. No.	Variables	Value
1	No. of patients	15
2	Mean age \pm SD (y)	36.4 \pm 8.6
3	Mean BMI \pm SD (kg/m ²)	35.02 \pm 3.4
4	Current or former tobacco user	—
5	Diabetes mellitus	4 (26.6%)
6	First-degree family history of breast cancer	1 (6.6%)
7	Second-degree family history of breast cancer	2 (13.3%)
8	Mean follow-up \pm SD (mo)	40.5 \pm 8.1

Abbreviations: BMI, body mass index; SD, standard deviation.

Table 3 Surgical complications

Sl. No.	Variables	Value (%)
1	Partial nipple necrosis	3 (20)
2	Total nipple necrosis	—
3	Wound healing complications	—
4	Scar with wound intervention	—
5	Fat necrosis without intervention	—
6	Fat necrosis with intervention	1 (6.6)
7	Seroma	—
8	Hematoma	—
9	Pulmonary embolism	—

complications like deep vein thrombosis or pulmonary embolism.

Discussion

Gigantic macromastia is a new terminology probably first used by Singolda et al⁶ to emphasize the heaviness of huge breasts upon women. The functional burden of heavy breasts is very clear to us.⁹ Smaller and moderate breast reductions target a lifted-up NAC with good shape and form with no loss of sensation and breastfeeding ability. On the contrary, the management of very huge breasts—gigantic macromastia—envisaged a great reduction amounting to total mastectomy during the early period. The recommendations were amputation with free nipple areolar graft,^{10–12} inferior pedicle,¹² or bipedicle reductions. Partial loss of the areola and nipple was very common resulting in pigmentary stigma and a featureless mound of tissue. When faced with huge breasts at a relatively young age which is not uncommon, this kind of reduction method is loathsome and functionless as a sexual organ and for breastfeeding.¹³

The inferior pedicle was considered sufficiently vascular in huge breasts but when SN-N and N-IMF measurements were longer than 18 to 20 cm, the dermoglandular blood vessels did not reach the NAC.⁶ Thus, the inferior pedicle reduction in gigantic breast reduction is not in a better position than the SMP reduction considering the anatomical vascular parameters. The reported complication rates of inferior pedicle reduction¹⁴ in larger breast reduction were slightly higher than that of SMP reductions.

High estimated resection weight of over 1,500 to 2,000 g and long SN-N distances over 38 to 40 cm were considered dangerous for a pedicled NAC. Amputation and free nipple areolar grafting were recommended.^{14,15} The aesthetic and functional characteristics of the breasts would be lost. Nipple grafting has a high incidence of nontake or partial loss with delayed healing in 18%.¹⁵ There is no other alternative flap method that has a sure survival prediction.⁴ Having done a few modifications which were primarily dimensional to get a 1 × 1 or 1 × 1.5 flap dimension proved to us that the NAC survived well. These modifications do not make any new innovations in the applied anatomy of blood and nerve supply to the breast. Four main vessels (1) the internal mammary, (2) the lateral thoracic, (3) the thoracoacromial, and (4) the anterior intercostal vessels supply the breast parenchyma.¹⁶ The internal mammary artery provides the dominant blood supply in 70% of the patients. It is the only vessel to contribute at least one perforator to the NAC in 100% of cases.^{17,18} The medial and lateral rami of the fourth intercostal nerves supply the NAC. Thus, the medial pedicle and SMP have the main axial neurovascular bundles.

The common complications of any plastic surgical procedure like hematoma, delayed wound healing, wound dehiscence, fat necrosis, infection, and hypertrophic scar were reported to be 43% by a large multicenter study.¹⁹ Vertical pattern reductions had higher incidence of the most common complications like delayed wound healing and wound dehiscence. Singolda et al⁶ reported 22.7% complications in

their series where only Wise-pattern skin resections were done in gigantic breast reductions. Lista and Ahmad²⁰ reported a very low overall complication rate of 5.6 where only vertical reductions were done. Only 22.2% of breasts underwent reductions of greater than 800 g. Whichever reduction technique is practiced a proper balance between the skin envelope and the conus and the postresected volume²¹ is the key factor in reducing the complications. Analyzing our results, partial necrosis in 3 (20%) early cases and fat necrosis in 1 case (6.6%), though numbers are only 15, clearly show that there is no correlation between the high resection weight and long SN-N. The longest 42 cm and heaviest 2,100 g breast reduction did not have any complications. Probably some rarely mentioned and often neglected factors like tissue density and breast flexibility play a definite role in the ultimate viability of the NAC.

Limitations

- (1) This study includes its retrospective nature.
- (2) The sample size was relatively small.
- (3) This study specifically focused on the results of using modified SMP in reduction mammoplasty; no comparison to inferior pedicle use for reduction mammoplasty was included.

Conclusion

After obtaining an adequate resection, the SMP is a versatile technique with the flexibility to modify the dimensions to get a robust blood supply to the NAC.

Conflict of Interest

None declared.

References

- 1 Hall-Findlay EJ, Shestak KC. Breast reduction. *Plast Reconstr Surg* 2015;136:531–544
- 2 Wettstein R, Christofides E, Pittet B, Psaras G, Harder Y. Superior pedicle breast reduction for hypertrophy with massive ptosis. *J Plast Reconstr Aesthet Surg* 2011;64(04):500–507
- 3 Dancey A, Khan M, Dawson J, Peart F. Gigantomastia—a classification and review of the literature. *J Plast Reconstr Aesthet Surg* 2008;61(05):493–502
- 4 Landau AG, Hudson DA. Choosing the superomedial pedicle for reduction mammoplasty in gigantomastia. *Plast Reconstr Surg* 2008;121(03):735–739
- 5 Fino P, Di Taranto G, Toscani M, Scuderi N. Surgical therapy of breast hypertrophy: a comparison of complications and satisfaction rate in large and small superior pedicle custom-made reduction mammoplasty. *Eur Rev Med Pharmacol Sci* 2016;20(21):4411–4415
- 6 Singolda R, Bracha G, Zoabi T, et al. Superomedial pedicle breast reduction for gigantic breast hypertrophy: experience in 341 breasts and suggested safety modifications. *Aesthetic Plast Surg* 2021;45(02):375–385
- 7 Bar-Meir ED, Lin SJ, Momoh AO, et al. The lateral chest wall: a separate aesthetic unit in breast surgery. *Plast Reconstr Surg* 2011;128(06):626e–634e
- 8 Bauermeister AJ, Gill K, Zuriarrain A, Earle SA, Newman MI. “Reduction mammoplasty with superomedial pedicle technique:

- a literature review and retrospective analysis of 938 consecutive breast reductions". *J Plast Reconstr Aesthet Surg* 2019;72(03): 410–418
- 9 Sak MC, Akin S, Ersen B, Tunalı O, Ismail A. Management of gigantomastia: outcomes of superomedial pedicle with vertical scar or wise pattern skin excision. *World J Plast Surg* 2017;6(02): 206–211
 - 10 Colen SR. Breast reduction with use of the free nipple graft technique. *Aesthet Surg J* 2001;21(03):261–271
 - 11 Lacerna M, Spears J, Mitra A, et al. Avoiding free nipple grafts during reduction mammoplasty in patients with gigantomastia. *Ann Plast Surg* 2005;55(01):21–24, discussion 24
 - 12 Gerzenshtein J, Oswald T, McCluskey P, Caplan J, Angel MF. Avoiding free nipple grafting with the inferior pedicle technique. *Ann Plast Surg* 2005;55(03):245–249
 - 13 Ashour T, Khachaba Y, El Naggat A. Supero-medial reduction mammoplasty: a safe and reliable technique in gigantomastia and severe breast ptosis. *Electron Physician* 2018;10(08):7230–7234
 - 14 Hammond DC, Loffredo M. Breast reduction. *Plast Reconstr Surg* 2012;129(05):829e–839e
 - 15 Hall-Findlay EJ. Pedicles in vertical breast reduction and mastopexy. *Clin Plast Surg* 2002;29(03):379–391
 - 16 Nahabedian MY, McGibbon BM, Manson PN. Medial pedicle reduction mammoplasty for severe mammary hypertrophy. *Plast Reconstr Surg* 2000;105(03):896–904
 - 17 Kerrigan CL, Comizio RC, Ho O. Superomedial pedicle breast reduction using a vertical pattern. In: Hall-Findlay EJ, Evans GRD, eds. *Aesthetic and Reconstructive Surgery of the Breast*. 1st ed. London: Saunders Ltd; 2010:284–285
 - 18 van Deventer PV, Graewe FR. The blood supply of the breast revisited. *Plast Reconstr Surg* 2016;137(05):1388–1397
 - 19 Cunningham BL, Gear AJ, Kerrigan CL, Collins ED. Analysis of breast reduction complications derived from the BRAVO study. *Plast Reconstr Surg* 2005;115(06):1597–1604
 - 20 Lista F, Ahmad J. Vertical scar reduction mammoplasty: a 15-year experience including a review of 250 consecutive cases. *Plast Reconstr Surg* 2006;117(07):2152–2165, discussion 2166–2169
 - 21 Blondeel PN, Hijjawi J, Depypere H, Roche N, Van Landuyt K. Shaping the breast in aesthetic and reconstructive breast surgery: an easy three-step principle. *Plast Reconstr Surg* 2009;123(02):455–462