



Peripherally Inserted Central Venous Catheter (PICC) Line Use for Conjoined Twins: Single-Center Experience

Mohamed Elzahrani^{1,2} Yousof Al Zahrani^{1,2} Alwaleed Alqarni^{1,2} Meshal Alothri^{1,2}
Mohammed Al Moaiqel^{1,2} Mohammed Alotaibi^{1,2} Amin Alzahrani^{1,2} Abdulaziz Almulhim³

¹ Department of Medical Imaging, King Abdulaziz Medical City, Riyadh, Saudi Arabia

² Department of Medical Imaging, Ministry of Health, Eastern Governance, Riyadh, Saudi Arabia

³ King Abdullah International Medical Research Center, Riyadh, Saudi Arabia

Address for correspondence Mohamed R. Elzahrani, MBBS, King Abdulaziz Medical City, Riyadh 12347, Saudi Arabia (e-mail: dr.mohamedelzahrani@gmail.com).

Arab J Intervent Radiol

Abstract

Purpose This article assesses the feasibility, safety, and efficacy of peripherally inserted central catheters (PICCs) in conjoined twins.

Material and Methods A retrospective chart review of all consecutive conjoined twins who had PICC placement at a tertiary center. Seventeen conjoined twins (12 females; 71%) had 25 PICC insertions. The average age of patients at PICC insertion was 15.9 ± 19.3 months. The most common type of twin was thoraco-omphalopagus (5 patients; 29%). The most common access was the brachial vein ($N = 10$, 40%). Thirteen procedures (52%) were performed before separation.

Results Seven long-term minor complications were identified (28%). The most common complication was malpositioning (8%). Average dwell time was 122 days while the average fluoroscopy time was 2 minutes and 3 seconds.

Conclusion Image-guided PICC placement in conjoined twins is safe and feasible. It provides excellent durable vascular access.

Keywords

- interventional
- peripherally inserted central catheter
- thrombosis

Introduction

Conjoined twins are a rare and challenging condition that requires meticulously planned and tailored management by a multidisciplinary team. It has an incidence of 1:250,000 live births, and a female predominance of 1:3. The majority (60%) of conjoined twin pregnancies end with intrauterine fetal demise or are stillborn.¹ Conjoined twins can be further divided into symmetrical twins and asymmetrical (parasitic) twins. Another type of parasitic twins is fetus in fetu (endoparasitic twins).² Symmetrical conjoined twins can be classified based on the location of union. The most common type of conjoined twin is thoracopagus/thoraco-omphalopagus

(► **Fig. 1**).^{3,4} Other types of twins include cephalopagus, craniopagus, ischiopagus, omphalopagus (► **Fig. 2**), and parapagus. Asymmetrical twins are a less common type of conjoined twins (6%) in which one twin is parasitic or dependent on the other twin.⁵ The treatment of conjoined twins is through planned separation. Emergent separation is only performed if the life of one or both of the twins is at risk. Otherwise, planned separation is performed after allowing the twins to grow.⁶

The use of radiological techniques is a cornerstone in the diagnosis and planning of conjoined twins' management and separation. The diagnosis of conjoined twins is often made

DOI <https://doi.org/10.1055/s-0044-1787786>.
ISSN 2542-7075.

© 2024. The Author(s).

This is an open access article published by Thieme under the terms of the Creative Commons Attribution License, permitting unrestricted use, distribution, and reproduction so long as the original work is properly cited. (<https://creativecommons.org/licenses/by/4.0/>)

Thieme Medical and Scientific Publishers Pvt. Ltd., A-12, 2nd Floor, Sector 2, Noida-201301 UP, India

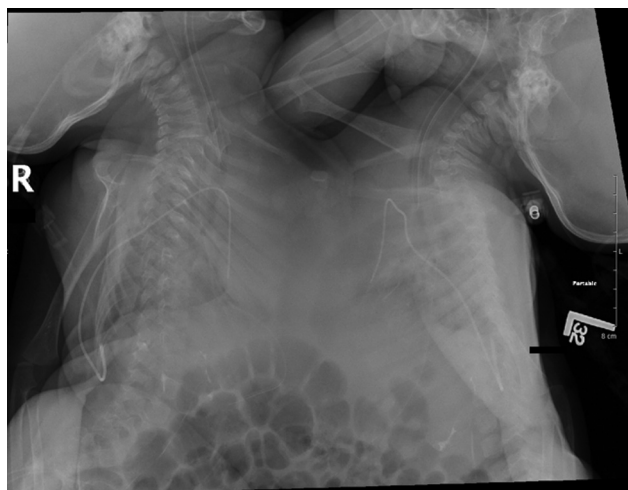

Fig. 1 Twins with the most common type of union (thoraco-omphalopagus).

during the prenatal ultrasound screening, and it can be detected in the 12th week of gestation. Further scanning at 20 weeks can help elucidate the shared viscera.⁷ During prenatal ultrasonography, continuous skin covering between two fetuses is the most sensitive and specific finding for conjoined twins.⁸ Planning for twin separation requires further imaging utilizing computerized tomography or magnetic resonance imaging. Although these modalities can be used antenatally, they will be more accurate if performed after delivery.⁷

The role of radiology in the management of conjoined twins also includes interventional procedures. One of these procedures is the insertion of peripherally inserted central venous catheters (PICCs). The use of PICCs in conjoined twins has been described in a few case reports.^{9–12} Due to the scarcity of studies on this topic, we aimed to assess the feasibility, safety, and efficacy of PICC use in conjoined twins.

Methods and Materials

The study was a retrospective chart review of hospital records in a tertiary medical city in King Abdulaziz Medical City, a tertiary medical city in Riyadh, Saudi Arabia. The study

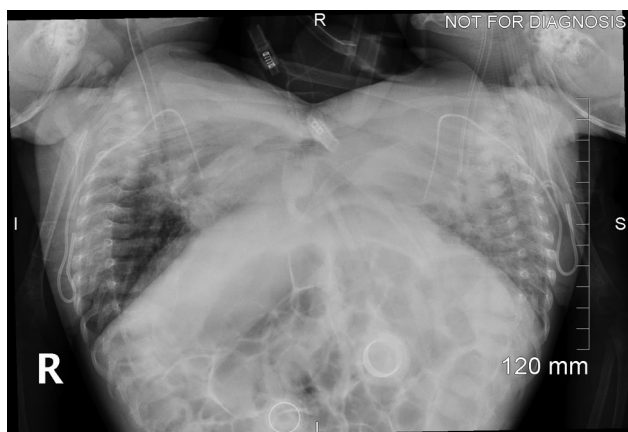


Fig. 2 Twins with fusion at the abdomen (omphalopagus).

received institutional review board approval and patients' informed consent was waived (Approval no.: IRB/0600/22).

The study included all known conjoined twin cases, regardless of separation status and other variables, in which one or both twins had a PICC inserted. Collected data included age, sex, type of twin, separation status, vein access, type of PICC, dates of insertion and removal, and complications (both intraoperative and postoperative). The type of conjoined twins was determined through the examination of pediatric radiologists' reports. The identification of intraoperative complications was through reviewing the procedure notes, while postoperative complications were identified through reviewing notes from PICC exchange and removal, as well as consultations and progress notes written by other teams (e.g., pediatric surgery, plastic surgery, pediatric intensive care unit).

All procedures were performed by interventional radiologists in the angiography suite under ultrasonographic and fluoroscopic guidance. Either sedation or general anesthesia was used in all PICC insertions. Local anesthesia was used in all cases as well. In preseparation twins, PICC lines were inserted or exchanged in the same setting for both patients. Note that 3 F cuffed catheters were the catheters of choice in younger mostly preseparation twins, while 4 F was used in older patients. Single lumen cuffed catheters were most often used. The brachial vein was the preferred access site. However, due to the awkward body orientation of certain types of twin (e.g., thoracopagus), femoral vein access was necessary in some cases. The tip of the catheter was placed at the cavoatrial junction. Catheters were flushed and fixed to the skin with dressing. The mean fluoroscopy time was 2 minutes and 3 seconds (ranging from 0:37 to 5:55). The procedure was deemed to be successful upon confirming that the catheter was functioning and in good position. Twenty-five PICC insertion procedures were performed on 17 patients. Twelve patients were female (71%) for whom 20 procedures were done, while only 5 male patients (29%) underwent 5 procedures. The average age of patients was 15.9 ± 19.3 months, with ages ranging from neonates (11 days old) to 6 years old. The most common type of conjoined twins in the study was thoraco-omphalopagus (5; 29%). Other variants include omphalo-ischiopagus, ischiopagus, thoraco-omphalo-ischiopagus, omphalopagus, and craniopagus (► **Table 1**).

Data coding and analysis were performed using the Statistical Package for the Social Sciences 23. Due to the limited sample size, Fisher's exact test was used in data analysis between categorical variables, and continuous variables were placed in categories (e.g., age category). Data are presented as percentages, frequency tables, and bar charts. To reject the null hypothesis, a p -value of 0.05 was set.

Results

The average number of procedures performed on females was 1.54 ± 0.97 , while male patients underwent one procedure each. The mean age at insertion for females was 17.25 months (range 11 days–6 years), while it was 11.4 months for males (range 5 months–2 year). Thirteen (52%) lines were

Table 1 Patient's data ($N = 17$)

Characteristics	Frequency	Percentage
Sex		
Males	5	29
Females	12	71
Type of twin		
Craniopagus	1	6
Ischiopagus	4	24
Omphalo-ischiopagus	4	24
Omphalopagus	1	6
Thoraco-omphalo-ischiopagus	2	11
Thoraco-omphalopagus	5	29

inserted on conjoined twins prior to separation and 12 (48%) after separation. The most common vein accessed was the brachial (10; 40%), followed by the basilic vein (9; 36%), cephalic vein (3; 12%), and femoral vein (3; 12%). The most utilized catheter size was 3 F (19; 76%) while 4 F was used six times (24%) and was most commonly used in children above 1 year of age. Single lumen catheters (17; 68%) were used more commonly compared with double lumen catheters (8; 32%) (► **Table 2**). The mean dwell time was 122 ± 116 days.

Among the 25 identified PICC insertions, 7 long-term complications were identified (28%), including 5 in preseparation twins (20%). Two instances of malpositioning requiring exchange or readjustments were reported, both cases had left brachial vein access and 3 F catheter size, one was exchanged 3 days later while the other was exchanged 16 days after being reported (► **Fig. 3**). One case of vein thrombosis required catheter removal the following day. The access was basilic and vein thrombosis was diagnosed 169 days after insertion. Another complication was an infection in which the causative organism was found to be *Enterococcus faecalis*. The PICC had right brachial access (3 F) and the infection was diagnosed 190 days after insertion. Irritation and erythema were identified in two patients. One patient removed the line himself and the line was removed for the other 5 days after it was noted. Both had right basilic access (3 F). The onset of irritation was 30 and 238 days after insertion, respectively (► **Table 3**). Vein stenosis in a patient with multiple PICC insertions was encountered intraoperatively requiring a venogram. The exchange was ultimately successful through the same vein. Patients younger than 12 months were statistically more likely to develop complications (p -value = 0.005). A possibly noteworthy finding seen in a patient that had undergone multiple PICC insertions was a keloid.

Discussion

The demographic variables collected in the study were in line with previous literature. For instance, among the study population, there was a clear predominance of females at 71%; this is

Table 2 Variables related to PICC insertions

Procedures' data	Frequency	Percentage
Age category at procedure		
Less than 1 year of age	12	48
1 year old and older	13	52
	$N = 25$	
Catheter size		
3 F	18	72
4 F	7	28
	$N = 25$	
Catheter type		
Single lumen	17	68
Double lumen	8	32
	$N = 25$	
Separation status		
Before separation	13	52
After separation	12	48
	$N = 25$	
Vein access		
Brachial vein	10	40
Femoral vein	3	12
Basilic vein	9	36
Cephalic vein	3	12
	$N = 25$	

Abbreviation: PICC, peripherally inserted central catheter.

close to the reported 1:3 ratio (75% females).¹ The most frequent type of twin reported, thoraco-omphalopagus, is also similar to previous literature.⁴ Among the few reports mentioning PICC use in conjoined twins, all but one utilized upper limb access; this is similar to our own review, in which only 13% (3 procedures) used lower limb access. All three sets of twins were thoraco-omphalopagus, which is similar to the previously mentioned case report, in which the upper

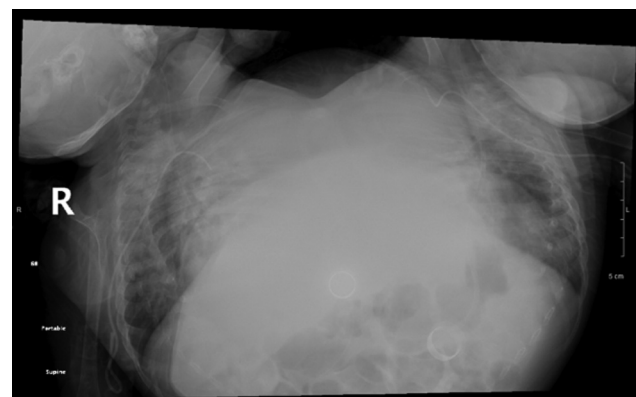


Fig. 3 The left peripherally inserted central catheter (PICC) is noted in incorrect position, representing the most common complication (malpositioning).

Table 3 Long-term complications of PICC use

Age at insertion	Gender	Twin type	Catheter duration	Separation	Access vein	Catheter details	Complication
5 mo	Female	Thoraco-omphalo-ischiopagus	190 d	Before	Right brachial	3 F single lumen	Infection
5 mo	Female	Thoraco-omphalo-ischiopagus	168 d	Before	Left brachial	3 F single lumen	Malpositioning
4 mo	Female	Ischiopagus	43 d	Before	Right basilic	3 F single lumen	Malpositioning
2 mo	Female	Omphalo-ischiopagus	30 d	Before	Left brachial	3 F double lumen	Erythema
5 mo	Male	Omphalo-ischiopagus	238 d	After	Right basilic	3 F single lumen	Irritation/Patient removed line
20 mo	Female	Thoraco-omphalopagus	169 d	After	Right basilic	3 F single lumen	Thrombosis

Abbreviation: PICC, peripherally inserted central catheter.

abdomen and sternum were fused.¹¹ This may be explained by the awkward body position of thoracopagus/thoraco-omphalopagus, which makes this type of access (lower limb/femoral access) a more viable option.

Complications associated with PICC insertions are divided into procedural (operative) and long-term (postoperative) complications. These can further be divided into major and minor complications. Major operative complications such as pneumothoraxes, hematomas, air embolism, and nerve damage¹³ were not reported in the study, and the only procedural challenge noted intraoperatively was venous stenosis in a patient that had a previous PICC insertion through the same access vein. Previous PICC insertions are a known cause of venous stenosis¹⁴ and could likely explain that complication.

In our review, the majority of complications were long term. Long-term complications are either mechanical, thrombotic, or infectious.¹³ These three groups were each encountered at least once. Once the complication is seen, prompt management, such as removal or replacement of the catheter, may be warranted. This illustrates the importance of continued vigilance by the treating physicians to the possible complications of PICCs and the importance of timely management of complications. Inspection of PICCs is especially important in this study population, as the diagnosis of these complications in nonverbal patients such as infants and small children depends on inspection and physical examination.

The study is limited by its small sample size inherently related to the rare condition of conjoined twins and the high rates of early mortality. Also, a few of the identified procedures had insufficient notes that did not include the data searched for in the standardized data collection sheet and therefore were discarded.

The PICC insertion procedure was largely safe, and the majority of complications were postoperative occurring on average 140 days after insertion. PICCs were found to be largely safe and effective. Nevertheless, the important role of long-term vigilance for the possible complications associated

with prolonged PICC use must be stated. There is a clear deficiency in literature concerned with PICC use, as well as other interventional procedures, in conjoined twins and the topic requires further investigation.

Note

The study was presented as an oral presentation in PAIRS 2023.

Ethical Approval Statement

This study has obtained IRB approval from King Abdullah International Medical Research Center and the need for informed consent was waived.

Conflict of Interest

None declared.

References

- Spitz L. Conjoined twins. *Prenat Diagn* 2005;25(09):814–819
- Sharma G, Mobin SS, Lypka M, Urata M. Heteropagus (parasitic) twins: a review. *J Pediatr Surg* 2010;45(12):2454–2463
- Mutchinick OM, Luna-Muñoz L, Amar E, et al. Conjoined twins: a worldwide collaborative epidemiological study of the International Clearinghouse for Birth Defects Surveillance and Research. *Am J Med Genet C Semin Med Genet* 2011;157C(04):274–287
- Edmonds LD, Layde PM. Conjoined twins in the United States, 1970–1977. *Teratology* 1982;25(03):301–308
- Conjoined twins - an epidemiological study based on 312 cases. *Acta Genet Med Gemellol (Roma)* 1991;40(3–4):325–335
- Mian A, Gabra NI, Sharma T, et al. Conjoined twins: from conception to separation, a review. *Clin Anat* 2017;30(03):385–396
- Spitz L. Conjoined twins. *Br J Surg* 1996;83(08):1028–1030
- Winkler N, Kennedy A, Byrne J, Woodward P. The imaging spectrum of conjoined twins. *Ultrasound Q* 2008;24(04):249–255
- Aldulaigan E, Arabi M, Alharbi A, Alotaibi M. Peripherally inserted central catheter insertion in conjoined thoraco-omphalopagus twins. *J Vasc Interv Radiol* 2017;28(09):1233
- Deepak C, Vandana S, Pradeep B, Nikhil K. Anesthetic management of separation of conjoint twins: challenges and limitations. *Saudi J Anaesth* 2019;13(02):140–143

- 11 Sinha A, Saxena R, Pathak M, Rodha MS. Conjoined thoracopagus twins - our experience of successful separation. *J Indian Assoc Pediatr Surg* 2021;26(05):354–357
- 12 Sato Y, Iura A, Kawamoto Y, Yamamoto S, Iritakenishi T, Fujino Y. Successful anesthetic management of separation surgery for pygopagus conjoined twins: a case report. *JA Clin Rep* 2021;7(01):6
- 13 Bakal CW. Chapter 35: Central venous access. In: *Vascular and Interventional Radiology Principles and Practice*. New York: Thieme; 2002:447–456
- 14 Shin HS, Towbin AJ, Zhang B, Johnson ND, Goldstein SL. Venous thrombosis and stenosis after peripherally inserted central catheter placement in children. *Pediatr Radiol* 2017;47(12):1670–1675