



# Isolated Tear of Coracobrachialis: An Unusual Presentation of Glenohumeral Internal Rotation Deficit

Abhinetri KSV<sup>1</sup> Nafisa Shakir Batta<sup>1</sup>  Aditya Sood<sup>2</sup> Riya Samanta<sup>1</sup>

<sup>1</sup> Department of Radiology, Mahajan Imaging, Sports Injury Centre, Safdarjung Hospital, Delhi, India

<sup>2</sup> Sports Medicine, Sports Injury Centre, Safdarjung Hospital, Delhi, India

**Address for correspondence** Abhinetri K.S.V., MBBS, MD, Department of Radiology, Mahajan Imaging, Sports Injury Centre, Safdarjung Hospital, Delhi, India (e-mail: abhinetri@gmail.com).

Indian J Radiol Imaging

## Abstract

An isolated injury to the coracobrachialis is an exceedingly uncommon occurrence, with only a handful of case reports documented in the literature. The majority of the reported cases attribute the injury to either direct trauma to the affected area or the contraction of the muscle, leading to the rupture of the muscle belly. In this article, we reported a case of indirect traumatic partial rupture of the coracobrachialis muscle, accompanied by a substantial hematoma at the proximal myotendinous junction had an unusual presentation of glenohumeral internal rotation deficit. To the best of our knowledge, no other case of isolated coracobrachialis injury has been reported in a bowler/cricketer.

## Keywords

- ▶ coracobrachialis tear
- ▶ coracobrachialis rupture
- ▶ GIRD

## Introduction

Isolated injury of the coracobrachialis is extremely rare with only a few case reports in literature.<sup>1</sup> Most cases that have been described are due to direct trauma to the affected area or contracted muscle resulting in rupture of the muscle belly. In this article, we report a case of indirect traumatic partial rupture of the coracobrachialis muscle with a large hematoma at the proximal myotendinous junction having an unusual presentation of glenohumeral internal rotation deficit (GIRD).

## Case Report

A 19-year-old male right-arm cricket bowler experienced sudden pain in the right shoulder after sustaining a sudden jerk injury while bowling, which initially subsided with analgesics and rest. However, upon resuming play 2 weeks after the

injury, the discomfort escalated, particularly on the anterior and posterosuperior aspects of the shoulder. Over time, the pain began to interfere with his daily activities, and sleeping on the affected side became increasingly challenging.

On inspection, no visible deformities were observed on the shoulder or the arm. During the physical examination, mild tenderness was noted upon palpation of the coracoid process. The patient exhibited mild restriction in flexion and abduction at the glenohumeral joint during active movements. Furthermore, internal rotation was limited to the T12 level on the right side, in contrast to the left side which reached the T7 level. During an overhead maneuver, scapular asymmetry was noted, characterized by a more prominent medial border, indicative of grade II scapular dyskinesia. The Neer test, Hawkins–Kennedy test, and abduction external rotation (ABER) test yielded positive results, with pain localized to the posterosuperior aspect of the shoulder. Despite these clinical signs, radiographic imaging did not reveal any significant abnormality.

DOI <https://doi.org/10.1055/s-0044-1787973>.  
ISSN 0971-3026.

© 2024. Indian Radiological Association. All rights reserved.  
This is an open access article published by Thieme under the terms of the Creative Commons Attribution-NonDerivative-NonCommercial-License, permitting copying and reproduction so long as the original work is given appropriate credit. Contents may not be used for commercial purposes, or adapted, remixed, transformed or built upon. (<https://creativecommons.org/licenses/by-nc-nd/4.0/>)  
Thieme Medical and Scientific Publishers Pvt. Ltd., A-12, 2nd Floor, Sector 2, Noida-201301 UP, India

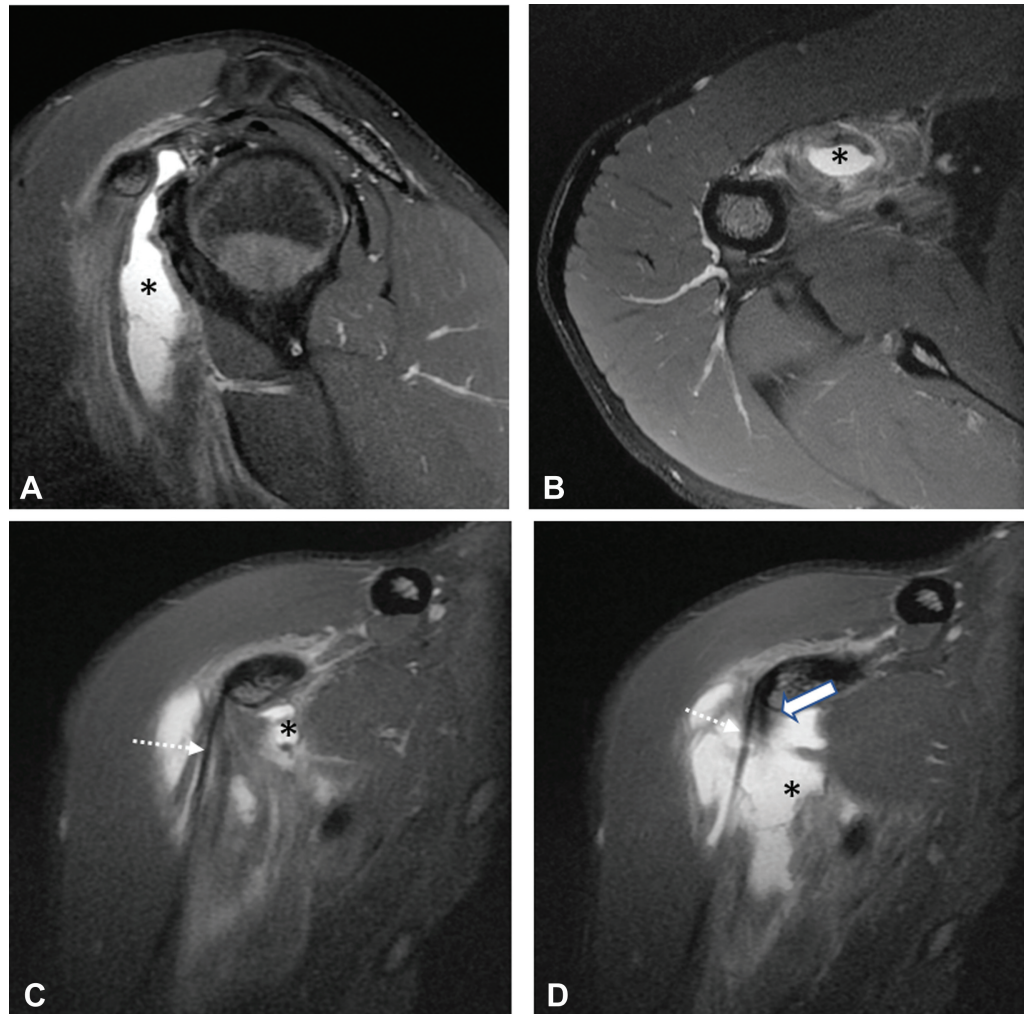
After initial history and clinical examination, a working diagnosis of GIRD/internal impingement of the right shoulder was established. Subsequent MRI of the right shoulder and upper arm revealed partial rupture of the coracobrachialis muscle at its proximal myotendinous junction with an associated hematoma measuring approximately  $5.8 \times 2.2 \times 1.4$  cm (►Fig. 1). This hematoma dissected through the muscle into the subcoracoid bursa, accompanied by significant surrounding intramuscular and myofascial edema. The tendinous origin and insertion of the coracobrachialis were intact. While the short head of biceps brachii tendon was splayed anteriorly by the hematoma, its coracoid attachment remained unaffected. The rotator cuff muscles and their tendons exhibited normal morphology and signal intensity, with no evident tear. The long head of biceps tendon (LHBT) displayed a normal course and appearance. The labrum appeared normal without any tears.

Conservative management was implemented, and the patient underwent a 6-week rehabilitation program.

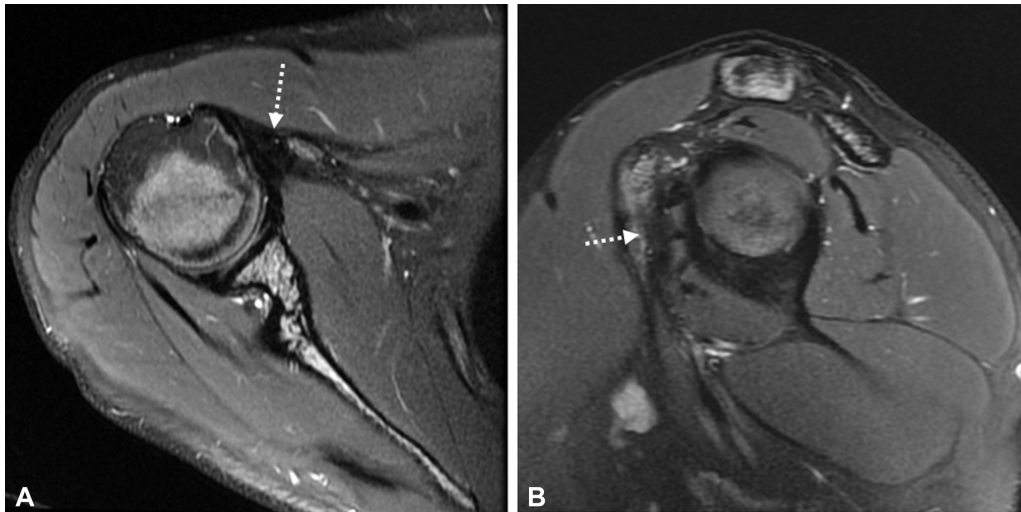
Subsequent to therapy, the pain subsided, and the range of internal rotation improved. A follow-up MRI performed after 3 months revealed scarring at the proximal myotendinous junction of the coracobrachialis with complete resolution of the hematoma (►Fig. 2).

## Discussion

Coracobrachialis injury is a seldom encountered condition, occurring infrequently either in isolation or in conjunction with other musculotendinous structures. Most cases reported in the literature have been injuries in combination with other muscles such as the short or the long head of biceps and the subscapularis. Saltzman et al<sup>2</sup> have described in their article proximal coracobrachialis tendon rupture along with subscapularis tendon rupture and medial dislocation of LHBT after traumatic anterior shoulder dislocation. Tobin et al<sup>3</sup> reported coracobrachialis muscle belly rupture along with injury of the short head of biceps in a parachutist.



**Fig. 1** Partial rupture of the coracobrachialis muscle with a large hematoma in a 19-year-old right arm bowler. (A, B) Proton density fat saturated (PDFS) images reveal a large hematoma (\*) within the proximal coracobrachialis muscle belly dissecting into the subcoracoid space with partial rupture of the muscle belly at the proximal myotendinous junction and extensive intramuscular edema. (C, D) Images reveal intact attachments of the coracobrachialis (solid white arrow) and the short head of biceps (dotted white arrow) tendons at the coracoid process with a hematoma (\*) and intramuscular edema in the coracobrachialis muscle.



**Fig. 2** (A, B) Follow-up MRI in the same patient 6 months after conservative treatment reveals PDFS hypointense scarring (dotted arrow) at the proximal myotendinous junction with complete resolution of the hematoma.

Gilcreest and Albi<sup>1</sup> reported a coracobrachialis muscle belly tear following direct trauma to the arm. To the best of our knowledge, there have been no reported cases of isolated coracobrachialis rupture to date.

The coracobrachialis muscle originates from the undersurface of the coracoid process apex and inserts onto the medial border of the mid humeral shaft.<sup>4</sup> The coracobrachialis primarily functions as a flexor and adductor of the arm at the glenohumeral joint. It also serves as an internal rotator of the shoulder and plays a role in stabilizing the glenohumeral joint when the arm is in a neutral position.

In our case, the unusual presentation was a result of the maladaptive scapulohumeral mechanics that developed as a response to injury. The patient presented with symptoms and signs that were more suggestive of impingement and posterosuperior pain secondary to the described internal rotation deficit and scapular dyskinesia rather than the primary injury itself. This deficit likely stemmed from the coracobrachialis tear and resulting hematoma, causing hindrance or prevention of shoulder abduction and external rotation, subsequently leading to scapular over-protraction and dyskinesia. Protective responses to the injury manifested as guarding, have further affected the scapulohumeral mechanics, ultimately resulting in the described internal rotation deficit.

## Conclusion

Injuries to the coracobrachialis may manifest with characteristics of GIRD, thereby necessitating consideration as a potential differential diagnosis in athletes who exhibit GIRD and experience posterosuperior shoulder pain.

### Funding

None.

### Conflict of Interest

None declared.

## References

- 1 Gilcreest EL, Albi P. Unusual lesions of muscles and tendons of the shoulder girdle and upper arm. *Surg Gynecol Obstet* 1939; 68:903-917
- 2 Saltzman BM, Harris JD, Forsythe B. Proximal coracobrachialis tendon rupture, subscapularis tendon rupture, and medial dislocation of the long head of the biceps tendon in an adult after traumatic anterior shoulder dislocation. *Int J Shoulder Surg* 2015; 9(02):52-55
- 3 Tobin WJ, Cohen LJ, Vandover JT. Parachute injuries. *J Am Med Assoc* 1941;117:1318-1321
- 4 Williams P, Warwick R, Dyson M, Bannister L. *Gray's Anatomy*. Edinburgh: Churchill Livingstone; 1989