



# Evaluation of the Articular Disc Using the Magnetic Resonance Cartigram in Asymptomatic and Symptomatic Temporomandibular Disorders

Aparna Sivakumar<sup>1</sup>  Anuradha Ganesan<sup>1</sup> Krithika Chandrasekar Lakshmi<sup>1</sup> Yesoda Aniyani<sup>1</sup>  
Saravanan Kannan<sup>2</sup>

<sup>1</sup> Department of Oral Medicine and Radiology, SRM Dental College, Bharathi Salai, Chennai, Tamil Nadu, India

<sup>2</sup> Department of Radiology in Saravana Imaging and Research Centre, Nandanam, Chennai, Tamil Nadu, India

**Address for correspondence** Aparna Sivakumar, Department of Oral Medicine and Radiology, SRM Dental College, Bharathi Salai, Chennai 600089, Tamil Nadu, India (e-mail: appuaparna1511@gmail.com).

Indian J Radiol Imaging

## Abstract

**Objectives** The study is aimed to perform magnetic resonance (MR) cartigram of the articular disc in patients with asymptomatic and symptomatic temporomandibular disorders (TMD).

**Methods** Thirty-nine volunteers were divided into three groups: 16 symptomatic TMD, 16 asymptomatic TMD, and 7 controls. The articular disc was divided into three segments (anterior, middle, and posterior) and analyzed using morphological magnetic resonance imaging (MRI) and T2 mapping sequences. T2 relaxation values were measured and assessed by an experienced radiologist and two observers. The T2 values in the discs were compared between the control, asymptomatic, and symptomatic groups using the Kruskal–Wallis test. The right and left discs were compared using the Wilcoxon signed rank test. Inter-examiner reliability among different examiners was evaluated.

**Results** The controls had the highest T2 values compared with the other groups. The comparison among the right and left sides of all the groups revealed statistically significant results in the anterior portion in the asymptomatic group and the middle portion in the symptomatic group ( $p < 0.05$ ). The inter-examiner reliability coefficients among the three examiners were consistently high, with values of 0.921, 0.920, and 0.930.

**Conclusion** Our study found the T2 relaxation time span was shorter than that reported in previous studies, which could be attributed to the early stage of cartilage deterioration in the individuals with TMD inferring treatment at this phase may be eventually effective with a good prognosis.

## Keywords

- ▶ temporomandibular joint
- ▶ temporomandibular disorders
- ▶ magnetic resonance imaging
- ▶ articular disc
- ▶ T2 mapping
- ▶ collagen fiber network

DOI <https://doi.org/10.1055/s-0044-1788608>.  
ISSN 0971-3026.

© 2024. Indian Radiological Association. All rights reserved.  
This is an open access article published by Thieme under the terms of the Creative Commons Attribution-NonDerivative-NonCommercial-License, permitting copying and reproduction so long as the original work is given appropriate credit. Contents may not be used for commercial purposes, or adapted, remixed, transformed or built upon. (<https://creativecommons.org/licenses/by-nc-nd/4.0/>)  
Thieme Medical and Scientific Publishers Pvt. Ltd., A-12, 2nd Floor, Sector 2, Noida-201301 UP, India

## Introduction

The temporomandibular joint (TMJ; often referred to as ginglymo-diarthrodial joint) is an intricate body joint composed of the mandibular condyle and the glenoid fossa of the temporal bone. A multitude of clinical illnesses that influence the muscles of mastication, TMJ, and pertaining structures, or both, are collectively referred to as temporomandibular disorders (TMDs).<sup>1</sup> TMD etiology is multifactorial, with both physiological and psychological factors contributing to the condition. Physiological variables can be broadly classified into arthrogenous (internal TMJ disorder) and myogenous (muscles) origin.<sup>2</sup>

Clinical evaluations and imaging are crucial for the assessment and therapy of TMD. As a result of greater contrast resolution, noninvasiveness, and capacity to obtain real-time imaging for demonstrating joint functionality, magnetic resonance imaging (MRI) has been acknowledged as the benchmark in the investigation of TMDs.<sup>3,4</sup>

It is employed to evaluate the disc location, disc form, accumulation of fluid in the joint area (joint effusion), the condyle's marrow signal, and pannus development (in the event of inflammatory arthritis).<sup>5</sup> It has been demonstrated that early in the course of TMD, disruption enabling the early diagnosis of these alterations, biochemical imaging techniques facilitate therapy aimed at preventing serious structural damage to the joint.<sup>6</sup>

MR cartigram, also known as T2 mapping or T2 value imaging, is a biochemical imaging technique that has been efficaciously used to identify cartilage damage in the knee joint,<sup>7,8</sup> intervertebral disc,<sup>9</sup> and hip<sup>10,11</sup> by using a T2 relaxation time as an auxiliary marker for depicting the water and collagen contents. Collagen arrangement, extracellular matrix framework, and water content can be detected through the interaction of water molecules with collagen fibers. Early structural alterations may be indicated by an alteration in T2 values.<sup>12,13</sup>

There are studies in the literature that have performed the T2 mapping method in healthy volunteers,<sup>12,14</sup> adolescents with TMD,<sup>15</sup> and disc dislocations.<sup>16,17</sup> The morphological MRI, together with T2 mapping, provides a diagnostic insight into the field of TMD and helps enhance the success rate of management. Hence, our study is designed to diagnose the early changes in the cartilage in asymptomatic and symptomatic TMD patients using MR cartigram.

## Materials and Methods

The present research was conducted in the oral medicine and radiology department from April 2022 to December 2023, with proper ethical consent obtained from the institutional review boards and ethical committees (SRMDC/IRB/2021/MDS/NO.901), under standardized ethical principles following the Helsinki declaration.

It is a cross-sectional observational study with a stratified random sampling technique in which 39 volunteers were included, who were divided into three distinct groups: group A—7 healthy volunteers without any symptoms of TMJ

disorders; group B—16 patients with TMD without pain but with symptoms of clicking, deviation while opening and closing the mouth, and locking of the jaw while opening the mouth; and Group C—16 patients with symptoms of pain along with clicking, deviation during jaw movement, pain and trouble in mouth opening, pain in the preauricular region, and spreading to surrounding areas.

Patients who are not willing to participate in the study; age below 18 years; pregnant and lactating patients; those with pacemakers, metallic implants, aneurysmal brain clips, metallic intraocular foreign bodies, and cochlear implants; claustrophobic, physically challenged, and mentally retarded patients; obese patients with weight greater than 150 kg who do not fit in the MRI machine; and those with a previous history of TMD who underwent treatment for it or are currently on it were excluded.

### Patient Examination

The age group of the patients ranged from 20 to 40 years, and the mean ages of symptomatic, asymptomatic, and controls were  $39.81 \pm 14.06$ ,  $26.44 \pm 7.68$ , and  $35.43 \pm 12.71$  years, respectively. The procedure was explained in detail, and informed consent was obtained. The study population was grouped under DC/TMD axis 1 criteria,<sup>18</sup> which included arthralgia (ICD-9 524.62; ICD 10 M26.62), anterior disc displacement with reduction, disc displacement with reduction with intermittent locking, disc displacement without reduction with limited mouth opening, disc displacement without reduction without limited mouth opening (ICD 9 524.63; ICD 10 M26.63), and degenerative joint diseases (ICD-9 715.18; ICD-10 M 19.91). A complete history and clinical assessment were performed on all patients.

### Magnetic Resonance Imaging

The participants underwent MRI of the bilateral TMJs using a 3-T scanner (SPECTRA, Siemens, Erlangen, Germany) with a 32-channel quadrature head and neck coil. No intravenous contrast agents were used and the imaging protocol included closed-mouth axial T2 fast spin echo (FSE) and coronal proton density fat-suppressed sequence (PDFS) sequences. Oblique sagittal T1 SE, PDFS images in closed- and open-mouth positions using standardized wedge blocks, and sagittal T2 mapping sequence (3D MAP IT, SIEMENS) were used to evaluate the T2 values in all three groups (**► Table 1**). The images were obtained in axial, coronal, and sagittal views and exported in the Digital Imaging and Communications in Medicine (DICOM) format, which were analyzed in the radiology department by the radiologist with more than 20 years of expertise in MRI research and diagnosis.

### Qualitative Assessment of Magnetic Resonance Imaging

Tasaki et al<sup>19</sup> divided articular disc location and function into five groups, with some variations. At closed- and open-mouth-position sagittal proton-attenuation-weighted MR images, partial anterior disc displacement with reduction (PADDWR), partial anterior disc displacement without reduction (PADDWOR), anterior disc displacement with

**Table 1** Scan parameters

Parameters	Axial T2 FSE <sup>a</sup>	Coronal PDFS <sup>b</sup>	Oblique sagittal TSE <sup>c</sup>	Sagittal PDFS	T2 mapping
FOV (mm × mm)	190 × 210	150 × 150	130 × 130	130 × 130	163 × 180
Number of slices (left + right)	25	15	28	28	30
Slice thickness (mm)	2.5	2.0	2.0	2.0	2.5
Slice separation (mm)	2.5	2.0	2.0	2.0	2.5
Number of averages	3	2	1	2	1
TR (ms)	3200	3400	500	3,960	600
TE (ms)	84	34	22	36	4.4
Acquisition matrix (pix)	320 × 75	320 × 70	256 × 70	320 × 70	384 × 80

Abbreviations: FOV, field of view; TE, echo time; TR, repetition time.

<sup>a</sup>Axial T2 FSE: fast spin echo sequence.

<sup>b</sup>Coronal PDFS: proton density fat-suppressed sequence.

<sup>c</sup>Oblique sagittal TSE: turbo spin echo sequence.

reduction (ADDWR), or anterior disc displacement without reduction (ADDWOR) were utilized to assess anterior disc displacement with or without reduction. Murakami et al<sup>20</sup> classified articular disc configurations as biconcave, biplanar, hemi-convex, thickening of the posterior band, biconvex, or folding on closed-mouth-position oblique sagittal proton-attenuation-weighted MR images. Larheim et al<sup>21</sup> established four classifications for joint effusion. On closed-mouth oblique sagittal fat-suppressed T2-weighted MR images, fluid levels can range from modest to considerable. Kirk<sup>22</sup> graded osteoarthritis as negative or positive based on the presence of condylar osteophytes or erosion on closed-mouth oblique sagittal proton-attenuation-weighted MR images. Larheim et al<sup>23</sup> classified bone marrow abnormalities of the mandibular condyle as negative or positive based on the presence of edema or osteonecrosis on closed-mouth oblique sagittal proton-attenuation- and T2-weighted MR images.

### Evaluation of T2 Relaxation Times

T2 maps were displayed in color coding by using the 3D MAP IT software tool provided by the MR scanner manufacturer (► Fig. 1). The T2 relaxation times were manually calculated by the experienced radiologist and two maxillofacial radiologists (observer 2 with 5 years of experience and observer 3 with 3 years of experience in TMJ T2 mapping) and were blinded to the volunteers.

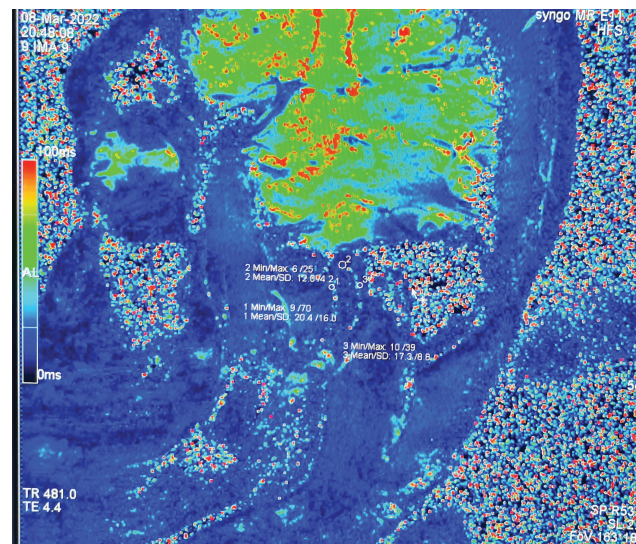
### Statistical Analysis

The assessment of data was performed by SPSS (IBM SPSS statistics for Windows version 26.0, IBM Corp., released 2019). The descriptive statistics of the demographic data have been presented as mean and standard deviation. A *p*-value less than 0.05 was considered significant statistically. The T2 relaxation time was compared among discs in the control, asymptomatic, and symptomatic groups using the Kruskal–Wallis test. A comparison between the right and left discs was done using the Wilcoxon signed rank test. Inter-examiner reliability among various examiners was assessed.

## Results

The morphological analysis of the TMJ among all the groups in terms of disc position, disc configuration, effusion in the joint, osteoarthritis, and bone marrow abnormalities revealed that seven participants (14 TMJs) in the control group had a normal disc position, a biconcave disc, and negative effusion, osteoarthritis, and bone marrow abnormalities. In both the asymptomatic and symptomatic groups, 16 participants (32 TMJs) showed the highest counts in ADDWR, followed by ADDWOR, biconcave disc, and minimal joint fluid, and they were negative for osteoarthritis and bone marrow abnormalities.

The reliability coefficients for comparisons between dataset pairs were consistently high, with values of 0.921, 0.920, and 0.930, which indicate a strong level of agreement among



**Fig. 1** T2 mapping of the temporomandibular joint showing T2 relaxation values in the anterior, middle, and posterior zones of the articular disc.

**Table 2** Inter examiner reliability among various examiners

	Inter examiner reliability	No. of items
Examiner 1 vs. examiner 2	0.921	12
Examiner 1 vs. examiner 3	0.920	12
Examiner 2 vs. examiner 3	0.930	12

examiners in their evaluations of the items within each dataset pair (► **Table 2**).

A comparison of T2 relaxation intervals of all the three portions of the disc in all the groups was performed. The variance in the outcome was found to be statistically significant ( $p < 0.05$ ) in the left anterior disc, right middle disc, left middle disc, right posterior disc, and left posterior disc T2 relaxation time, with controls exhibiting the highest mean relaxation time (► **Table 3**).

Among the symptomatic participants, a higher relaxation time for the right middle disc was observed compared with the left middle disc, which was statistically significant with a  $p$ -value of 0.008 (► **Table 4**). Among the asymptomatic participants, a higher relaxation time was observed for the right anterior disc compared with the left anterior disc, and this distinction was statistically significant with a  $p$ -value of 0.016 (► **Table 5**). No significance in the relaxation time between the right and left discs was observed in the control group (► **Table 6**).

## Discussion

TMD is the second most predominant musculoskeletal condition, with a major public health concern, affecting 5 to 12% of the general population and being the most popular source of chronic pain of nondental origin in the orofacial area.<sup>3,19,24</sup> MRI is a highly advanced technique for monitoring TMJ and soft-tissue ailments such as the articular cartilage within the TMJ. Quantitative imaging techniques are highly significant for early detection of cartilage changes.<sup>4</sup>

MRI techniques such as relaxometry (T2\*, T1-rho mapping, and T1), sodium imaging, delayed gadolinium-enhanced MRI of cartilage (dGEMRIC), glycosaminoglycan-specific chemical exchange saturation transfer (gagCEST), diffusion-weighted imaging (DWI), and diffusion tensor imaging (DTI) can determine and measure the biochemical characteristics of cartilage. T2\* mapping offers advantages such as fast imaging, excellent resolution, and isotropic 3D cartilage evaluation, and utilizes commercially available pulse sequences and integrated processing software without contrast media administration or specialized equipment.<sup>6</sup>

In our study, we aimed to assess the TMJ, T2 transverse relaxation time using the MR cartigram in volunteers who are healthy and those with asymptomatic and symptomatic TMD. We used 3-T MRI with a high magnetic field and a dedicated 32-channel quadrature head and neck coil similar to many other previous studies.<sup>12,15,16,25,26</sup> The head coil enhances picture resolution and preciseness for the articular disk. Higher magnetic fields (3 T) have been proven to

**Table 3** Comparison of T2 relaxation interval of all the three portions of the disc in all the groups

Parameter	Group	N	Mean	Standard deviation	p-Value <sup>a</sup>
Right anterior disc	Symptomatic cases	16	13.81	2.69	0.29
	Asymptomatic cases	16	14.94	3.45	
	Control	7	17.14	1.46	
	Total	39	14.87	3.05	
Right middle disc	Symptomatic cases	16	13.56	2.76	0.001
	Asymptomatic cases	16	13.38	3.38	
	Control	7	20.57	1.51	
	Total	39	14.74	3.94	
Right posterior disc	Symptomatic cases	16	15.19	4.51	0.003
	Asymptomatic cases	16	13.38	2.42	
	Control	7	20.86	3.29	
	Total	39	15.46	4.39	
Left anterior disc	Symptomatic cases	16	14.06	3.84	0.002
	Asymptomatic cases	16	12.06	2.26	
	Control	7	18.00	2.65	
	Total	39	13.95	3.67	
Left middle disc	Symptomatic cases	16	12.06	2.82	0.000
	Asymptomatic cases	16	12.69	2.91	
	Control	7	21.57	2.99	
	Total	39	14.03	4.56	
Left posterior disc	Symptomatic cases	16	13.56	2.94	0.001
	Asymptomatic cases	16	13.56	2.10	
	Control	7	19.86	3.29	
	Total	39	14.69	3.58	

<sup>a</sup>Significance levels according to the results of Kruskal Wallis test.



**Table 4** Comparing the relaxation time between right and left discs among symptomatic patients

Symptomatic cases	Paired differences		p-Value <sup>a</sup>
	Mean difference	Standard deviation	
Right anterior disc–left anterior disc	–0.25000	3.04412	0.776
Right middle disc–left middle disc	1.50000	3.28634	0.008 <sup>b</sup>
Right posterior disc–left posterior disc	1.62500	4.03113	0.149

<sup>a</sup>Significance levels according to the results of Wilcoxon signed rank test.

<sup>b</sup>Highly significant.

**Table 5** Comparing the relaxation time between right and left discs among asymptomatic patients

Asymptomatic cases	Paired differences		p-Value <sup>a</sup>
	Mean difference	Standard deviation	
Right anterior disc–left anterior disc	2.87500	3.72156	0.016 <sup>b</sup>
Right middle disc–left middle disc	0.68750	3.89391	0.859
Right posterior disc–left posterior disc	–0.18750	2.40052	0.687

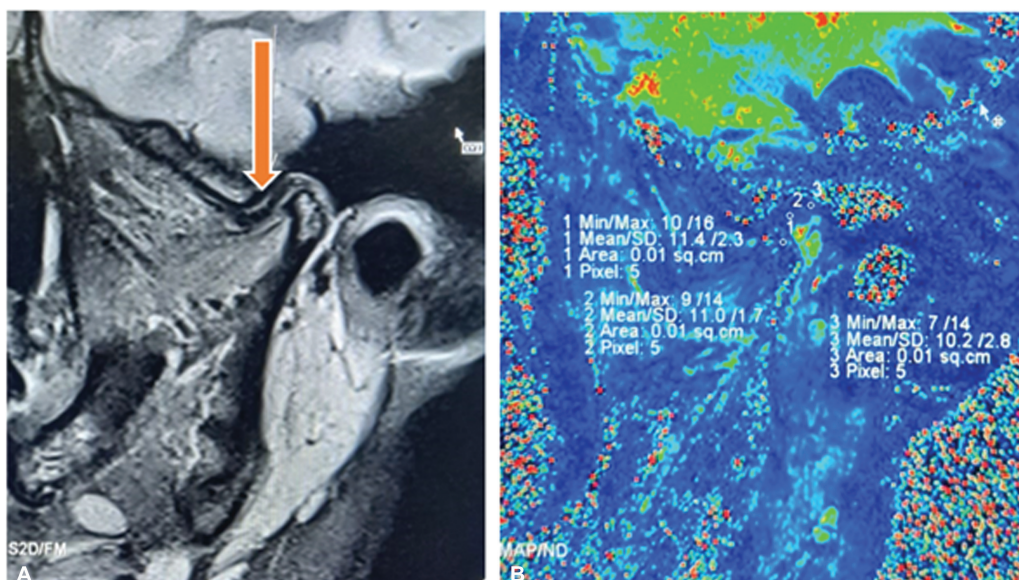
<sup>a</sup>Significance levels according to the results of Wilcoxon signed rank test.

<sup>b</sup>Moderate significance.

**Table 6** Comparing the relaxation time between right and left discs among controls

Control	Paired differences		p-Value <sup>a</sup>
	Mean difference	Standard deviation	
Right anterior disc–left anterior disc	–0.85714	2.26779	0.317
Right middle disc–left middle disc	–1.00000	2.51661	0.288
Right posterior disc–left posterior disc	1.00000	3.00000	0.495

<sup>a</sup>Significance levels according to the results of Wilcoxon signed rank test.



**Fig. 2** (A) Morphological magnetic resonance imaging (MRI) of the right closed mouth sagittal proton density fat saturated (PDFS) image of control group individual showing normal disc position. (B) T2 mapping showing T2 relaxation values in the anterior, middle, and posterior zones of the disc of the same patient.

improve structural analysis in healthy TMJs (**►Fig. 2**) improves the signal-to-noise ratio, and reduces examination time while providing better joint delineation.<sup>19</sup>

In the qualitative analysis, the asymptomatic and symptomatic groups showed almost similar results. In disk position, the highest occurrence of anterior disk displacement with reduction was observed in 25 TMJs (10 right and 15 left joints) across 16 patients (**►Fig. 3**) and anterior disk displacement without reduction was observed in 16 TMJs (8 right and 8 left joints) across 10 patients (**►Fig. 4**). In disk configuration, the majority were biconcave (52 TMJs in 26 patients), followed by biplanar (14 TMJs in 7 patients), hemi-convex (8 TMJs in 4 patients), or folded configurations (4 TMJs in 2 patients). Minimum to moderate joint fluid was observed in 11 TMJs in 9 patients (**►Fig. 5**), no osteoarthritis, or any bone marrow abnormalities was seen in any group, which is similar to the Kakimoto et al study.<sup>17</sup> In the quantitative analysis, we compared the mean T2 relaxation time in the anterior, posterior, and intermediate zones based on the anatomical configuration of the disk in all three groups bilaterally. The collagen fibers in the articular disk run largely mediolaterally in the anterior and posterior bands and anteroposteriorly in the middle band.<sup>12–14,27</sup>

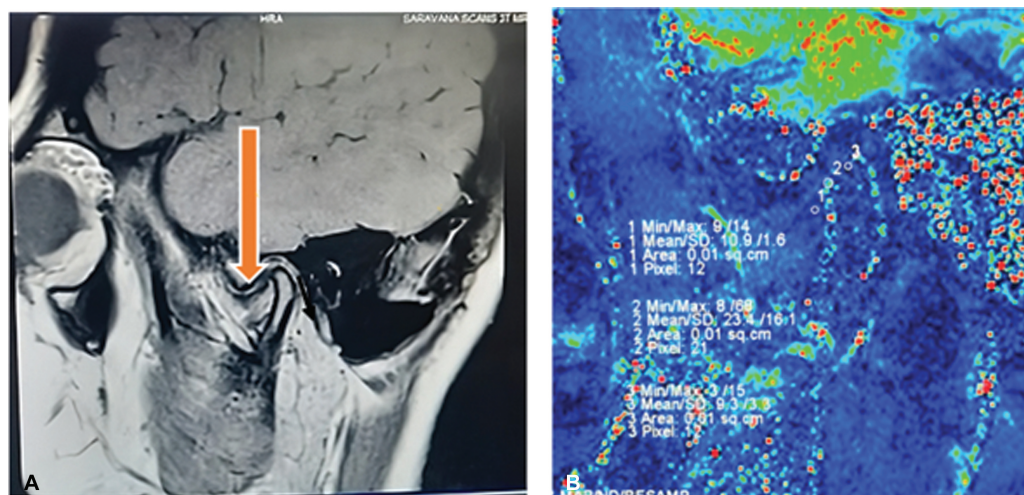
The T2 MRI time constant detects slow molecular movements of water protons and tissue network anisotropy. The restricted transportation of cartilage fluid in an extremely heterogeneous network results in T2 values ranging from 15 to 60 milliseconds. The dipolar interaction decreases when the fixed magnetic field ( $B_0$ ) and cartilage collagen fibers align at 54.74 degrees, known as the magic angle effect.<sup>28,29</sup> Using collagen anisotropies and regular perpendicular orientations, the magic-angle effect anticipates spatial variances in T2 values in cartilage.

In our study, the control group had the highest mean relaxation time, overall indicating a longer duration compared with both asymptomatic and symptomatic cases with statistically significant variation ( $p < 0.05$ ) in the left anterior, right, and left middle and posterior discs among the

groups. Similarly, Zhao et al<sup>24</sup> calculated the average T2 relaxation value of the whole disc and found that it was greater in the control population ( $39.284 \pm 5.634$  milliseconds) compared those with anterior disc displacement with reduction ( $33.634 \pm 4.235$  milliseconds) and without reduction ( $30.982 \pm 3.205$  milliseconds). Stress dispersion through the cartilage and soft tissues in TMD can affect water content and, thus, T2 values. Bittersohl et al<sup>30</sup> assessed the T2 values in the femoral and acetabular cartilage, which demonstrated a reduction in the T2 values with increasing cartilage damage and stated that lesser T2\* relaxation values suggested the influence of microscopic susceptibility areas on T2 relaxation. In contrast, a higher T2 value in the TMD patients compared with healthy individuals indicates that the collagen–proteoglycan matrix immobilizes water protons in the cartilage, causing T2 decay and low signal intensity on T2-weighted imaging. Lack of collagen and proteoglycan in degenerative cartilage enhances water movement, leading to increased signal intensity on T2-weighted imaging.<sup>31</sup> Bristela et al<sup>16</sup> reported that T2 mapping high sensitivity, moderation effect, and limited size of the TMJ make it inappropriate for frequent usage in diagnosing TMD. In the present study, while comparing the right and left discs, the highest T2 relaxation time was seen in the right middle compartment in the symptomatic group and in the right anterior compartment in the asymptomatic group, with significant results ( $p < 0.05$ ). According to Mingjun et al,<sup>31</sup> the T2 value of the anterior portion was the greatest in the patient and normal groups.

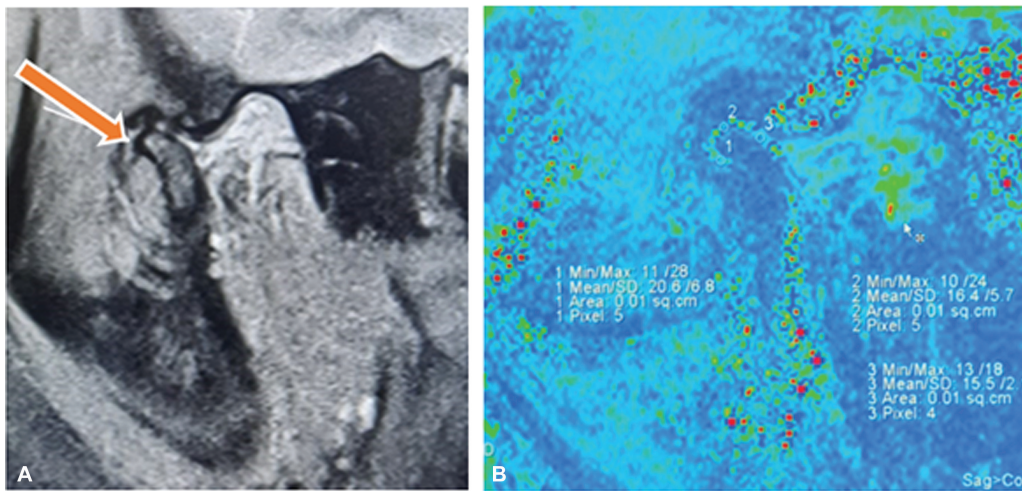
Due to the TMJ intricacy, region of interest (ROI) selection and T2 relaxation duration results vary significantly between investigations. The reliability coefficients between dataset pairs of the observers are consistently high, with values of 0.921, 0.920, and 0.930, indicating a strong level of agreement among examiners similar to other studies.<sup>16,25</sup>

The current research's primary attributes are that we used a 3-T MRI scanner with a dedicated 32-channel quadrature head and neck coil. We divided the patients based on pain

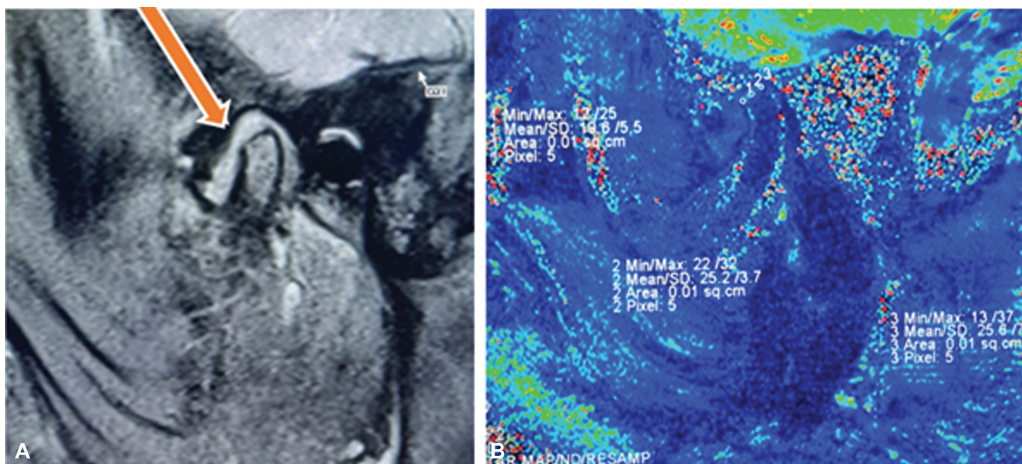


**Fig. 3** (A) Morphological magnetic resonance imaging (MRI) of the left closed mouth sagittal proton density fat saturated (PDFS) image of an asymptomatic group individual showing anterior disc displacement with reduction. (B) T2 mapping showing T2 relaxation values in the anterior, middle, and posterior zones of the disc of the same patient.





**Fig. 4** (A) Morphological magnetic resonance imaging (MRI) of the left open mouth sagittal proton density fat-saturated (PDFS) image of a symptomatic group individual showing anterior disc displacement without reduction. (B) T2 mapping showing T2 relaxation values in the anterior, middle, and posterior zones of the disc of the same patient.



**Fig. 5** (A) Morphological magnetic resonance imaging (MRI) of the right closed mouth sagittal proton density fat-saturated (PDFS) image of a symptomatic group individual showing moderate joint effusion. (B) T2 mapping showing T2 relaxation values in the anterior, middle, and posterior zones of the disc of the same patient.

and other symptoms into the symptomatic, asymptomatic, and control groups, and assessed with both morphological MRI and MR cartigram. There was good interobserver reliability among three observers for evaluating the T2 values. It infers that the T2 relaxation time was less, which can be substantiated as early changes in the degeneration of the cartilage in both asymptomatic and symptomatic TMD patients. Meanwhile, the T2 mapping values can be regulated by factors like magnetic field strength, sequence type, coil architecture, and estimating method. This study displays the T2 mapping approach, facilitates the investigation of TMJ discs, and incorporates qualitative as well as quantitative evaluations, resulting in a more precise diagnosis of the degree of impairment in TMD patients.

The limitations of the study were primarily attributed to the time constraints resulting in uneven sample distribution, a small sample size and a lacunae in the long term follow up of the patients post the customized intervention. Also, long-term follow-up of all the patients after

customized intervention was not done due to the limitation in the time period.

In the future, MR cartigram can be used to evaluate the progression of the condition pre- and postintervention and to evaluate the reaction to conservative, pharmacologic, or invasive treatments of TMD. In future studies, ultra-short echo-time enhanced T2\* (UTE-T2\*) cartilage mapping can be implemented, which is an advancement of the T2 mapping sequence that uses much shorter echo time (TE; 8 microseconds) as compared with regular MRI. This allows for the detection of signals from tissues with short T2 and easily evaluating the alterations in the TMJ disc and deep cartilage.

## Conclusion

Combining biochemical imaging with a high-field-strength MR scanner can help detect TMD early on. The overall results reveal that irrespective of the presence or absence of pain, the T2 relaxation time was almost similar in both

asymptomatic and symptomatic TMD groups, which was significantly less with respect to the healthy volunteers, which could be attributed to the early stage of cartilage deterioration in the TMD patients in our study. Treatment at this phase may eventually be effective with a good prognosis. Since MR cartigram is a highly advanced tool for detecting minute changes in the TMJ disc during the early stages of disease, further investigations are needed to thoroughly understand the clinical implications and the association of T2 values with cartilage deterioration.

#### Ethical Approval

All procedures followed were in accordance with the ethical standards of the responsible committee on human experimentation (institutional and national) and with the Helsinki Declaration of 1975, as revised in 2008 (5). Informed consent was obtained from all patients for being included in the study.

This article does not contain any studies with human or animal subjects performed by the any of the authors.

#### Informed Consent

Additional informed consent was obtained from all patients for which identifying information is included in this article.

#### Funding

None.

#### Conflict of Interest

None declared.

#### References

- Maini K, Dua A. Temporomandibular Syndrome. Treasure Island, FL: StatPearls Publishing; 2023
- Li DTS, Leung YY. Temporomandibular disorders: current concepts and controversies in diagnosis and management. *Diagnostics (Basel)* 2021;11(03):459
- Bag AK, Gaddikeri S, Singhal A, et al. Imaging of the temporomandibular joint: an update. *World J Radiol* 2014;6(08):567–582
- Tomas X, Pomes J, Berenguer J, et al. MR imaging of temporomandibular joint dysfunction: a pictorial review. *Radiographics* 2006;26(03):765–781
- Tresoldi M, Dias R, Bracci A, Segù M, Guarda-Nardini L, Manfredini D. Magnetic resonance imaging evaluation of closed-mouth TMJ disc-condyle relationship in a population of patients seeking for temporomandibular disorders advice. *Pain Res Manag* 2021;2021:5565747
- Stehling C, Vieth V, Bachmann R, et al. High-resolution magnetic resonance imaging of the temporomandibular joint: image quality at 1.5 and 3.0 tesla in volunteers. *Invest Radiol* 2007;42(06):428–434
- Safna MA, Sunil M, Keshav Kumar ADT. T2 mapping [cartigram] in the evaluation of the articular cartilage in traumatic knee injury. *MedPulse – International. J Radiol* 2019;9(02):59–62
- Cha JG, Lee JC, Kim HJ, et al. Comparison of MRI T2 relaxation changes of knee articular cartilage before and after running between young and old amateur athletes. *Korean J Radiol* 2012;13(05):594–601
- Welsch GH, Trattinig S, Paternostro-Sluga T, et al. Parametric T2 and T2\* mapping techniques to visualize intervertebral disc degeneration in patients with low back pain: initial results on the clinical use of 3.0 Tesla MRI. *Skeletal Radiol* 2011;40(05):543–551
- Apprich S, Mamisch TC, Welsch GH, et al. Evaluation of articular cartilage in patients with femoroacetabular impingement (FAI) using T2\* mapping at different time points at 3.0 tesla MRI: a feasibility study. *Skeletal Radiol* 2012;41(08):987–995
- Hesper T, Hosalkar HS, Schleich C, et al. T2\* mapping for hip joint cartilage assessment: pre-MRI exercise and time of imaging do not bias the T2\* measurement in asymptomatic volunteers. *Cartilage* 2017;8(04):400–405
- Schmid-Schwab M, Bristela M, Pittschieler E, et al. Biochemical analysis of the articular disc of the temporomandibular joint with magnetic resonance T2 mapping: a feasibility study. *Clin Oral Investig* 2014;18(07):1865–1871
- Mosher TJ, Dardzinski BJ. Cartilage MRI T2 relaxation time mapping: overview and applications. *Semin Musculoskelet Radiol* 2004;8(04):355–368
- Cao Y, Xia C, Wang S, He S, Wamalwa P, Chen S. Application of magnetic resonance T2 mapping in the temporomandibular joints. *Oral Surg Oral Med Oral Pathol Oral Radiol* 2012;114(05):644–649
- Zhao Z, Ge H, Xiang W, Bai G. Exploration of MRI T2 mapping image application in articular disc displacement of the temporomandibular joint in adolescents. *Int J Gen Med* 2021;14:6077–6084
- Bristela M, Skolka A, Eder J, et al. T2 mapping with 3.0 T MRI of the temporomandibular joint disc of patients with disc dislocation. *Magn Reson Imaging* 2019;58(58):125–134
- Kakimoto N, Shimamoto H, Chindasombatjaroen J, et al. Comparison of the T2 relaxation time of the temporomandibular joint articular disc between patients with temporomandibular disorders and asymptomatic volunteers. *AJNR Am J Neuroradiol* 2014;35(07):1412–1417
- Schiffman E, Ohrbach R, Truelove E, et al; International RDC/TMD Consortium Network, International association for Dental Research Orofacial Pain Special Interest Group, International Association for the Study of Pain. Diagnostic criteria for temporomandibular disorders (DC/TMD) for clinical and research applications: recommendations of the International RDC/TMD Consortium Network\* and Orofacial Pain Special Interest Group. *J Oral Facial Pain Headache* 2014;28(01):6–27
- Tasaki MM, Westesson PL, Isberg AM, Ren YF, Tallents RH. Classification and prevalence of temporomandibular joint disc displacement in patients and symptom-free volunteers. *Am J Orthod Dentofacial Orthop* 1996;109(03):249–262
- Murakami S, Takahashi A, Nishiyama H, Fujishita M, Fuchihata H. Magnetic resonance evaluation of the temporomandibular joint disc position and configuration. *Dentomaxillofac Radiol* 1993;22(04):205–207
- Larheim TA, Westesson PL, Sano T. MR grading of temporomandibular joint fluid: association with disc displacement categories, condyle marrow abnormalities and pain. *Int J Oral Maxillofac Surg* 2001;30(02):104–112
- Kirk WS Jr. Sagittal magnetic resonance image characteristics and surgical findings of mandibular condyle surface disease in staged internal derangements. *J Oral Maxillofac Surg* 1994;52(01):64–68
- Larheim TA, Westesson PL, Hicks DG, Eriksson L, Brown DA. Osteonecrosis of the temporomandibular joint: correlation of magnetic resonance imaging and histology. *J Oral Maxillofac Surg* 1999;57(08):888–898, discussion 899
- Dhanasekaran SM, Kannan A, Lakshmi KC, Anuradha G, Aniyani KY. Efficacy of pulsed shortwave therapy in symptomatic TMD patients: randomized control trial. *J Indian Acad Oral Med Radiol* 2022;34(02):146–149
- Wongratwanich P, Nagasaki T, Shimabukuro K, et al. Intra- and inter-examination reproducibility of T2 mapping for temporomandibular joint assessment at 3.0 T. *Sci Rep* 2022;12(01):10993
- Radha R, Yesodha AK, Kannan A, Krithika CL, Anuradha G. Magnetic resonance T2 mapping in temporomandibular joints:



- comparison among different age groups—an observational study. *Innovations* 2022;68:246–254
- 27 Meera R, Kannan A, Krithika CL, Aniyar KY. Correlation between clinical pain in temporomandibular disorders and signal intensity of the retrodiscal tissue using fluid attenuation inversion recovery MRI: a cross sectional study. *Matrix* 2022;8(01):20–25
- 28 Nikkuni Y, Nishiyama H, Hyayashi T. The relationship between masseter muscle pain and T2 values in temporomandibular joint disorders. *Oral Surg Oral Med Oral Pathol Oral Radiol* 2018;126(04):349–354
- 29 Xia Y. Magic-angle effect in magnetic resonance imaging of articular cartilage: a review. *Invest Radiol* 2000;35(10):602–621
- 30 Bittersohl B, Miese FR, Hosalkar HS, et al. T2\* mapping of acetabular and femoral hip joint cartilage at 3 T: a prospective controlled study. *Invest Radiol* 2012;47(07):392–397
- 31 Mingjun YE, Mingle WU, Shan SHEN. Application value of magnetic resonance T2 mapping imaging in anterior disc displacement of temporomandibular joint. *Int J Applied Science Research* 2022;1(05):1–9