



Endovascular Treatment of Ruptured Broad-Necked Intracranial Aneurysms with Double Microcatheter Technique: Case Series with Brief Review of Literature

Mohan Karki¹ Girish Rajpal¹

¹Department of Neurointerventional Surgery, Max Super Speciality Hospital, Vaishali, Uttar Pradesh, India

Address for correspondence Girish Rajpal, MCh, FINR, Department of Neurointerventional Surgery, Max Super Speciality Hospital, Vaishali 201012, Uttar Pradesh, India (e-mail: brainsavior12@gmail.com).

Asian J Neurosurg

Abstract

Objective Treatment of ruptured broad-necked intracranial aneurysms by endovascular therapy is technically burdensome. It is commonly treated with stent- and balloon-assisted coils embolization. The aim of this study was to evaluate clinical and radiological outcomes following double micro-catheter (MC) technique.

Materials and Methods A retrospective study was done on 16 broad-necked (neck diameter ≥ 4 mm and dome-to-neck ratio < 2) ruptured intracranial aneurysms in 16 patients treated with double MC technique at our center between December 2021 and December 2023. Clinical outcome was evaluated by modified Rankin Score, postcoiling radiological outcome was evaluated by Raymond–Roy occlusion grade, and treatment-related complications were assessed.

Results There were 16 patients, 9 females and 7 males; with a mean age of 51.3 years (35–70 years). All the patients underwent dual MC coils embolization for all aneurysms. Raymond–Roy occlusion class I was achieved in 81.3% (13) cases and Raymond–Roy class II was achieved in 18.7% (3) cases immediately after the procedure. There were no serious postprocedure-related complications or recanalization of the aneurysm at the mean follow-up of 4.8 months (range 2–10 months).

Conclusion Our study presents the safety and effectiveness of double MC system for treating ruptured broad-necked intracranial aneurysm. Large numbers of studies with longer follow-up period are required to secure validity of double MC technique.

Keywords

- ▶ coiling
- ▶ double microcatheter
- ▶ technique
- ▶ broad-necked intracranial aneurysm
- ▶ outcome

Introduction

The treatment of aneurysms by the endovascular method was developed in 1990 with the arrival of the Guglielmi detachable coil system and established a new era in the neurointervention field with multiple randomized clinical

trials reporting the safety and effectiveness of coiling.¹ Small-necked intracranial aneurysm has presented a higher frequency of obtaining complete aneurysmal sac occlusion.² Treatment of broad-necked intracranial aneurysm by endovascular therapy (defined as neck diameter ≥ 4 mm and

DOI <https://doi.org/10.1055/s-0044-1788803>.
ISSN 2248-9614.

© 2024. Asian Congress of Neurological Surgeons. All rights reserved.

This is an open access article published by Thieme under the terms of the Creative Commons Attribution-NonDerivative-NonCommercial-License, permitting copying and reproduction so long as the original work is given appropriate credit. Contents may not be used for commercial purposes, or adapted, remixed, transformed or built upon. (<https://creativecommons.org/licenses/by-nc-nd/4.0/>)

Thieme Medical and Scientific Publishers Pvt. Ltd., A-12, 2nd Floor, Sector 2, Noida-201301 UP, India

dome-to-neck ratio <2) still prevails technically troublesome because of the increased risk of coils migration or entrenchment into parent vessels.³⁻⁵ Numerous new endovascular tools and techniques have been evolved to overwhelm these constraints such as three-dimensional (3D) coils,⁶ balloon remodeling method,⁷ and stent-assisted coils embolization.⁸ The treatment of ruptured or unruptured aneurysm with intracranial stent has a higher complication rate because of stent predisposing to thrombosis and requires antiplatelet therapy which may increase the possibility of bleeding in postoperative period.^{9,10} Therefore, double microcatheter (MC) is another technique for ruptured or nonruptured broad-necked intracranial aneurysm treatment. In our study, it tried to assess the safety and efficacy of this technique.

Materials and Methods

Patient Sample

This study included 16 patients with 16 broad-necked ruptured intracranial aneurysms who underwent double MC coil embolization between December 2021 and December 2023 at our center. There were seven males and nine females with a male-to-female ratio of 1:1.3. The mean age of patients was 51.3 years (range 35–70 years). Broad-necked aneurysm was defined as a neck diameter ≥ 4 mm and dome-to-neck diameter less than 2 mm. The mean neck diameter was 4.5 (range 4–5.3) mm. Demographic information including the patient's age and sex, clinical manifestations (Hunt and Hess grade), and aneurysm morphology (neck, dome, and height) were carefully reviewed (► **Table 1**). Modified Rankin scale (mRS) score at the time of discharge and follow-up was applied to evaluate the clinical outcome. The angiographic results were classified according to Raymond–Roy occlusion classification system¹¹ as follows: class 1: no filling of aneurysm neck or dome; class 2: residual filling of neck but not dome; and class 3: residual filling of neck and dome. Large aneurysm with wide neck can be treated by single MC but chances of recurrence are more in such cases, so we excluded this aneurysm. And double MCs are also dangerous to place in very small aneurysm having dome diameter less than 4 mm with wide neck. So, we included moderate-sized aneurysms with neck diameter >4 mm having dome to neck ratio <2 . Initial and angiographic follow-up also were reviewed. Overall, follow-up ranged from 2 to 10 months, with a mean of 4.8 months.

Techniques

All aneurysms were performed on a monoplane angiography unit using a common femoral approach under general anesthesia. A 3,000 IU heparin bolus was administered before placement of the guiding catheter followed by a continuous infusion of 10 IU/kg/h. The morphologic characteristics of the aneurysm were carefully evaluated including the size of the neck, width and height; the diameter and tortuousness of the parent artery; major branches originating from aneurysmal sac with digital subtraction angiography along with 3D angiographic reconstruction technique. A hemostatic valve

Table 1 Patient and aneurysm characteristics

Characteristics	Frequency (n = 16)
Age (y)	51.3 (35–70)
Sex	
Male	7 (43.7%)
Female	9 (56.3%)
Mean admission GCS	10.9 (8–15)
Mean admission Fisher's scale	1.8 (I–IV)
Mean admission Hunt and Hess grade	1.7 (1–4)
Aneurysm location	
Anterior circulation	12 (75%)
AcomA	5 (41.7%)
PcomA	1 (8.3%)
DACA	1 (8.3%)
MCA	5 (41.7%)
Posterior circulation	
Basilar artery	4 (25%)
Aneurysm size (mm)	
Mean neck diameter	4.5 (4–5.3)
Mean fundus diameter	4.7 (4–6)
Mean height diameter	5.3 (4.5–6.6)
Medical history	
HTN	5 (31.2%)
DM	1 (6.3%)
HTN + DM	3 (18.8%)
No history	7 (43.7%)
Mean hospital stay (d)	8 (5–14)
Mean follow-up (mo)	4.8 (2–10)

Abbreviations: AcomA, anterior communicating artery; DACA, distal anterior cerebral artery; DM, diabetes mellitus; GCS, Glasgow coma scale; HTN, hypertension; MCA, middle cerebral artery; PcomA, posterior communicating artery.

with three ports was connected with a 6F long sheath (6 × 90; Cook). A long sheath was placed in the common carotid artery/subclavian artery with the help of a 5F diagnostic catheter (Vert, Cook) and 0.035-inch glide wire (Radio Focus, Terumo). We selected a catheter, 1.7F (distal) 2.4F (proximal) of excelsior SL-10 where two such MCs can be easily accommodated and manipulated without any difficulties through a 6F guiding catheter. Envoy 6F guiding catheter (Envoy, Codman) through which two MCs can be advanced was positioned in the C3 segment of the internal carotid artery/V3 segment of the vertebral artery with the help of a guiding wire. Then MC (Excelsior SL 10, Stryker) was placed in the sac of an aneurysm with the support of 0.014-inch microwire (Synchro 2, Stryker). Another Excelsior SL 10 was placed in the sac of an aneurysm below the first MC (► **Fig. 1**). Soft helical (Target 360 Ultra, Stryker or Optima, Balt) or 3D

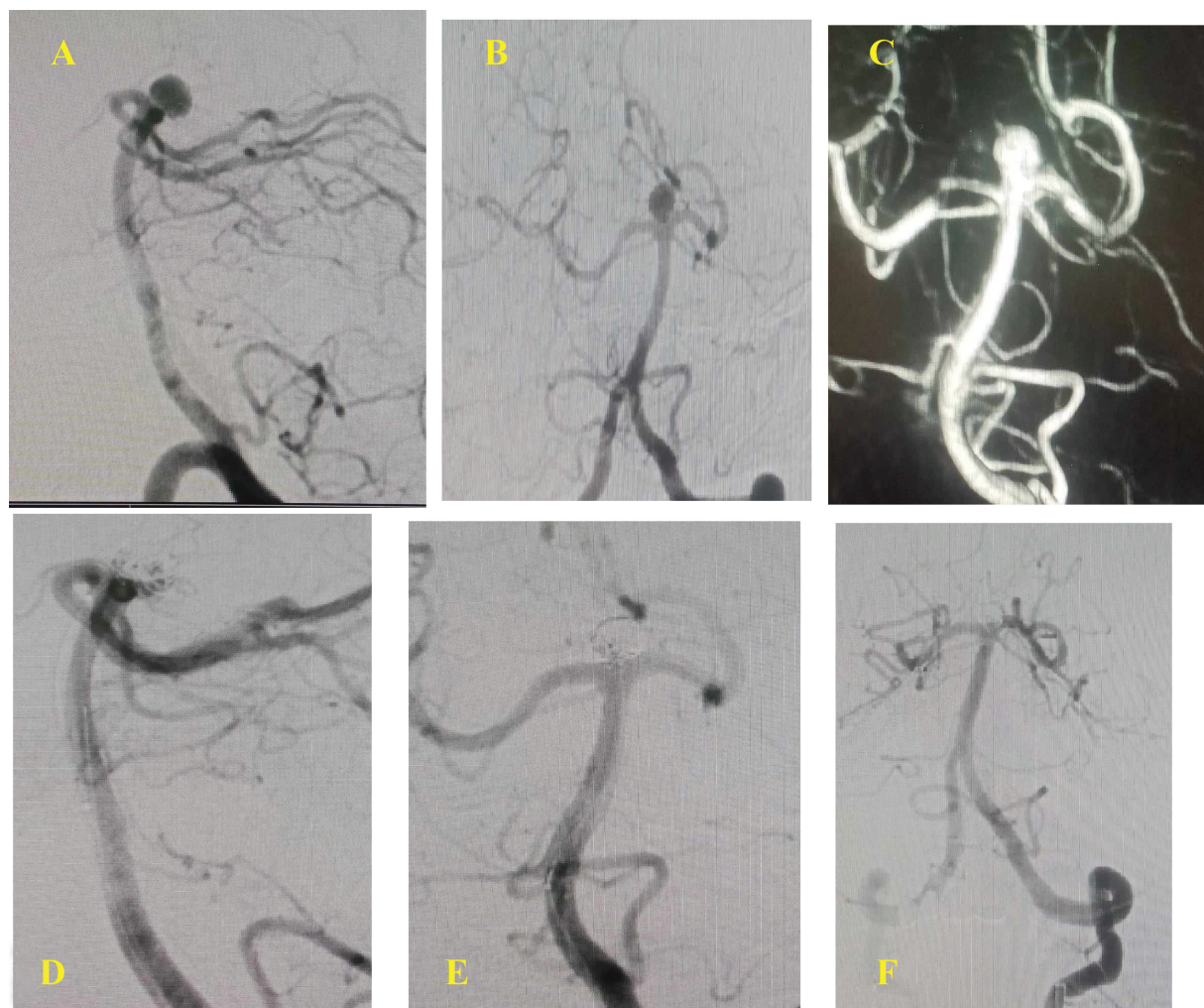


Fig. 1 Angiography of a 66-year-old woman with a ruptured aneurysm. (A, B) The vertebral artery angiogram shows lateral and cranial views of the basilar artery aneurysm. 3D reconstruction image shows wide-necked basilar tip aneurysm (neck fundus \times height: $5.2 \times 5.9 \times 6.1$ mm). (D) Two microcatheters are positioned in aneurysm sac. First coil, complex-10, supersoft (Optima, Balt) $5 \text{ mm} \times 10 \text{ cm}$ was advanced from the first microcatheter but not detached. Frame complex (Axium Prime, eV3) $3.5 \text{ mm} \times 8 \text{ cm}$ was advanced from the second microcatheter and the coil from the first microcatheter was detached. Then, bare platinum (Axium Prime) $3 \text{ mm} \times 6 \text{ cm}$, complex-10, supersoft $2.5 \text{ mm} \times 4 \text{ cm}$, and complex-10, supersoft $2 \text{ mm} \times 6 \text{ cm}$ were deployed. (E) Immediately after coil embolization, the angiogram shows compact occlusion of aneurysmal sac. (F) Six months after embolization, the angiogram shows no interval changes and stable coils.

coil (Axium 3D, eV3) was first attempted into the aneurysm to form a relatively stable frame. Actually, we used to deploy both coils simultaneously or one or two loops of first coil followed by second coil loops so that both coils interlock with each other preventing prolapse of coils loop into the parent vessel. So, depending on this method rather than choosing the first long coils, we choose two coils of similar dimensions approximately half of the coils' dimension chosen in the case of a single coil to be used for simple coiling. After a stable frame was obtained, one of the two coils was detached, and the next smaller coil was advanced to fill the frame. This process was continued alternatively until the aneurysms were as densely packed as possible.

Results

A total of 16 patients were treated with double MC technique between December 2021 and December 2023;

43.7% were male and 56.3% were female with a mean age of 51.3 years. Seven patients (43.7%) had no medical history; three patients (18.8%) had both hypertension (HTN) and diabetes mellitus (DM) history; five patients (31.2%) and one patient (6.3%) had only a history of HTN and DM, respectively. We reported that eight patients (50%) had Hunt and Hess grade 1, five patients (31.2%) had Hunt and Hess grade 2, two patients (12.5%) had Hunt and Hess grade 3, and one patient (6.3%) had Hunt and Hess grade 4 at the time of admission.

The majority of aneurysms (75%) were located in anterior location, including anterior communicating artery ($n=5$, 41.7%), distal anterior cerebral artery ($n=1$, 8.3%), posterior communicating artery ($n=1$, 8.3%), and middle cerebral artery ($n=5$, 41.7%). Four aneurysms (25%) were located in posterior circulation of basilar artery. The mean neck diameter, mean dome diameter, and mean height diameter were 4.5 ($4\text{--}5.3$) mm, 4.7 ($4\text{--}6$) mm, and 5.3 ($4.5\text{--}6.6$) mm,

Table 2 Procedure-related clinical and angiographic outcomes at discharge as well as follow-up period

Characteristics	Frequency
Raymond–Roy scale (at procedure time)	
Class I	13 (81.2%)
Class II	3 (18.8%)
Class III	0 (0%)
Raymond–Roy scale (at follow-up)	
Class I	14 (87.5%)
Class II	2 (12.5%)
Class III	0 (0%)
Modified Rankin score (at discharge time)	
0	8 (50%)
1	5 (31.2%)
2	2 (12.5%)
3	1 (6.3%)
4	0 (0%)
5	0 (0%)
6	0 (0%)
Modified Rankin score (at follow-up)	
0	11 (68.7%)
1	5 (31.3%)
2	0 (0%)
3	0 (0%)
4	0 (0%)
5	0 (0%)
6	0 (0%)
Complication	0 (0%)

respectively. Immediately postprocedure, Raymond–Roy occlusion class I in 13 patients (81.2%) and occlusion Raymond–Roy occlusion class II in 3 patients (18.8%) were noted. There were eight patients who had mRS score 0, five patients had mRS score 1, two patients had mRS score 2, and one patient had mRS score 3 during discharge period (► **Table 2**). One patient developed aphasia in next day of coils embolization. We performed angiography, but no procedural-related complication was found. Patient improved in aphasia after 4 days. No any procedure-related complications and recanalization of aneurysms were found at the follow-up period.

Discussion

Before the evolution of endovascular technique, surgical management was the most common method to treat aneurysm by the use of clip across the neck of aneurysm. An Italian neurosurgeon, Guido Guglielmi in 1990 first introduced detachable platinum coils for the management of intracranial aneurysm by endovascular technique. Aneu-

rysm treatment by the endovascular method has comparatively lower morbidity and mortality than surgical clipping.¹² However, permanent morbidities and mortality, incomplete aneurysmal occlusion or coils breach into parent vessels, or recanalization leading to required retreatment for management of broad-necked intracranial aneurysm by endovascular technique have been described.^{3,13,14} Treatment for broad-necked intracranial aneurysm has been reported with various techniques such as balloon remodeling techniques⁷ and intracranial stent⁸ and multiple MC technique¹⁵ have been described in the literature.

Neck remodeling technique with balloon or stent has previously been performed to treat broad-necked aneurysm that helps the formation of coils compactness by preventing coils migration into parent vessels; however, there are some limitations and technical troubles in carrying out them. Some studies reported raised risk of aneurysm rupture because of compressive pressure created by balloon inflation; raised the risk of distal ischemic complication by temporary vessel occlusion, dissection of vessels, and thromboembolic complication by balloon remodeling technique.^{7,16,17} Overall incidences of thromboembolic events with balloon- and stent-assisted techniques ranging from 4 to 14%^{18,19} and from 0 to 21%,^{20–24} respectively, have been mentioned. A study done for wide-necked aneurysm treatment with dual MC technique described that thromboembolic complication and intraoperative aneurysmal rupture were found in six (10.7%) patients and one (1.8%) patient, respectively.²⁵ Similarly, Lee et al reported that thromboembolic complication in 11 (14.6%) patients, permanent neurological deficit in 1 (1.3%) patient, and coils migration in 2 (2.7%) patients were noted.²⁶

Double MC technique is new concept that helps to make stable coils frame under support of a MC such as balloon- and stent-assisted techniques for wide-necked intracranial aneurysm. However, this technique has also minimal likelihood in increased risk of thromboembolic complication with the use of double MC as compared with multiple balloon- and stent-assisted techniques. Continuous catheter infusion with systemic heparinization (10 IU/kg/h) should be used to prevent from thromboembolic complication. We did not find any thromboembolic event in our patients. One of the drawbacks of ruptured or nonruptured aneurysm with stent-assisted coiling is that dual antiplatelet therapy is inevitably needed pre- and postoperatively because stent has property of generation of thrombus,^{20,21} lead to tendency of bleeding complication at postoperative period. But, double MC technique does not require long-term antiplatelet therapy. Therefore, we can believe that the treatment of ruptured broad-necked intracranial aneurysm is safe and effective by double MC.

A good clinical outcome (mRS score, 0–2) was observed in 93.7% patients at the time of discharge in our case series, whereas 64.3% patient had good outcome (mRS score, 0–2) at the time of discharge.²⁵ Durst et al explained that an excellent clinical outcome (mRS score, 0–2) was noted in 93% of patients at long-term follow-up period, whereas 100%

patients had excellent clinical outcome (mRS score, 0–2) at the follow-up period (range, 2–10 month) in our study.²⁷ Xu et al described total occlusion (Raymond–Roy occlusion class I) in 46 (79%) aneurysm, a neck remnant (Raymond–Roy occlusion class II) in 7 (13%), and body filling (Raymond–Roy occlusion class III) in 5 (8%); and complication rate associated with technique was 5% (3/58); procedure-related mortality was 0%, and recanalization developed in 3 (9%) at the mean follow-up of 12.5 months.²⁸ Similarly, Yoon et al described that total occlusion (Raymond–Roy occlusion class I) in 27 (48.2%) aneurysms, contrast filling neck of aneurysm (Raymond–Roy occlusion class II) in 15 (26%), and contrast filling the sac of aneurysm (Raymond–Roy occlusion class III) in 14 (25%), and technique-related complication rate was 5% (3/58), procedure-related mortality was 0%, and recanalization developed in 21 (56.8%) at the mean follow-up of 20.6 months.²⁵ In our case, there was no re-canalization reported at the mean follow-up of 4.8 months. However, our case report has some limitations such as number of cases are too small size; angiographic follow-up period is too short, and it is retrospective nature of the study. Therefore, larger numbers of case series with longer angiographic follow-up information are required to evaluate safety and validity of double MC technique for management of ruptured broad-necked intracranial aneurysms.

Conclusion

In this case study, it presents that the double MC technique is safe and effective for management of ruptured broad-necked intracranial aneurysm with dual MC technique when there is a probability of failure of coil compactness due to coils migration or impingement. And it also replaces stent- and balloon-assisted coils embolization. Therefore, double MC technique can be considered as an alternative option in broad-necked intracranial aneurysm.

Authors' Contributions

M.K. conceived and designed the study, and responsible for data collection and manuscript writing and drafting. G. R. was responsible for editing and providing technical feedback with design and analyses.

Ethical Approval

This is a retrospective study, so informed consent was taken from the institute, and all involved participants were included in this study.

Funding

None.

Conflict of Interest

None declared.

Acknowledgment

We would like to thank Cath laboratory team for their valuable time for helping to collect data and images.

References

- Molyneux A, Kerr R, Stratton I, et al; International Subarachnoid Aneurysm Trial (ISAT) Collaborative Group. International Subarachnoid Aneurysm Trial (ISAT) of neurosurgical clipping versus endovascular coiling in 2143 patients with ruptured intracranial aneurysms: a randomized trial. *J Stroke Cerebrovasc Dis* 2002;11(06):304–314
- Viñuela F, Duckwiler G, Mawad M. Guglielmi detachable coil embolization of acute intracranial aneurysms: perioperative anatomical and clinical outcome in 403 patients. *J Neurosurg* 1997;86(03):475–482
- Fernandez Zubillaga A, Guglielmi G, Viñuela F, Duckwiler GR. Endovascular occlusion of intracranial aneurysms with electrically detachable coils: correlation of aneurysm neck size and treatment results. *AJNR Am J Neuroradiol* 1994;15(05):815–820
- Turjman F, Massoud TF, Sayre J, Viñuela F. Predictors of aneurysmal occlusion in the period immediately after endovascular treatment with detachable coils: a multivariate analysis. *AJNR Am J Neuroradiol* 1998;19(09):1645–1651
- Hendricks BK, Yoon JS, Yaeger K, et al. Wide-neck aneurysms: systematic review of the neurosurgical literature with a focus on definition and clinical implications. *J Neurosurg* 2019;133(01):159–165
- Vallée JN, Pierot L, Bonafé A, et al. Endovascular treatment of intracranial wide-necked aneurysms using three-dimensional coils: predictors of immediate anatomic and clinical results. *AJNR Am J Neuroradiol* 2004;25(02):298–306
- Moret J, Cognard C, Weill A, Castaings L, Rey A. The “Remodelling Technique” in the treatment of wide neck intracranial aneurysms. Angiographic results and clinical follow-up in 56 cases. *Interv Neuroradiol* 1997;3(01):21–35
- De Paula Lucas C, Piotin M, Spelle L, Moret J. Stent-jack technique in stent-assisted coiling of wide-neck aneurysms. *Neurosurgery* 2008;62(5, suppl 2):ONS414–ONS416, discussion ONS416–ONS417
- Ryu CW, Park S, Shin HS, Koh JS. Complications in stent-assisted endovascular therapy of ruptured intracranial aneurysms and relevance to antiplatelet administration: a systematic review. *AJNR Am J Neuroradiol* 2015;36(09):1682–1688
- Chung J, Lim YC, Suh SH, et al. Stent-assisted coil embolization of ruptured wide-necked aneurysms in the acute period: incidence of and risk factors for periprocedural complications. *J Neurosurg* 2014;121(01):4–11
- Raymond J, Guilbert F, Weill A, et al. Long-term angiographic recurrences after selective endovascular treatment of aneurysms with detachable coils. *Stroke* 2003;34(06):1398–1403
- Molyneux A, Kerr R, Stratton I, et al; International Subarachnoid Aneurysm Trial (ISAT) Collaborative Group. International Subarachnoid Aneurysm Trial (ISAT) of neurosurgical clipping versus endovascular coiling in 2143 patients with ruptured intracranial aneurysms: a randomised trial. *Lancet* 2002;360(9342):1267–1274
- Guglielmi G, Viñuela F, Duckwiler G, et al. Endovascular treatment of posterior circulation aneurysms by electrothrombolysis using electrically detachable coils. *J Neurosurg* 1992;77(04):515–524
- Tateshima S, Jones JG, Mayor Basto F, Vinuela F, Duckwiler GR. Aneurysm pressure measurement before and after placement of a Pipeline stent: feasibility study using a 0.014 inch pressure wire for coronary intervention. *J Neurointerv Surg* 2016;8(06):603–607
- Kwon OK, Kim SH, Oh CW, et al. Embolization of wide-necked aneurysms with using three or more microcatheters. *Acta Neurochir (Wien)* 2006;148(11):1139–1145, discussion 1145
- Phatourous CC, Halbach VV, Malek AM, Dowd CF, Higashida RT. Simultaneous subarachnoid hemorrhage and carotid cavernous fistula after rupture of a paraclinoid aneurysm during balloon-

- assisted coil embolization. *AJNR Am J Neuroradiol* 1999;20(06):1100–1102
- 17 Soeda A, Sakai N, Sakai H, et al. Thromboembolic events associated with Guglielmi detachable coil embolization of asymptomatic cerebral aneurysms: evaluation of 66 consecutive cases with use of diffusion-weighted MR imaging. *AJNR Am J Neuroradiol* 2003;24(01):127–132
 - 18 Raymond J, Roy D, Leblanc P, et al. Endovascular treatment of intracranial aneurysms with radioactive coils: initial clinical experience. *Stroke* 2003;34(12):2801–2806
 - 19 Layton KF, Cloft HJ, Gray LA, Lewis DA, Kallmes DF. Balloon-assisted coiling of intracranial aneurysms: evaluation of local thrombus formation and symptomatic thromboembolic complications. *AJNR Am J Neuroradiol* 2007;28(06):1172–1175
 - 20 Benitez RP, Silva MT, Klem J, Veznedaroglu E, Rosenwasser RH. Endovascular occlusion of wide-necked aneurysms with a new intracranial microstent (Neuroform) and detachable coils. *Neurosurgery* 2004;54(06):1359–1367, discussion 1368
 - 21 Fiorella D, Albuquerque FC, Han P, McDougall CG. Preliminary experience using the Neuroform stent for the treatment of cerebral aneurysms. *Neurosurgery* 2004;54(01):6–16, discussion 16–17
 - 22 Lubicz B, François O, Levivier M, Brotchi J, Balériaux D. Preliminary experience with the enterprise stent for endovascular treatment of complex intracranial aneurysms: potential advantages and limiting characteristics. *Neurosurgery* 2008;62(05):1063–1069, discussion 1069–1070
 - 23 Yahia AM, Gordon V, Whapham J, Malek A, Steel J, Fessler RD. Complications of Neuroform stent in endovascular treatment of intracranial aneurysms. *Neurocrit Care* 2008;8(01):19–30
 - 24 Dos Santos Souza MP, Agid R, Willinsky RA, et al. Microstent-assisted coiling for wide-necked intracranial aneurysms. *Can J Neurol Sci* 2005;32(01):71–81
 - 25 Yoon PH, Lee JW, Lee YH, Kwon YS, Yang KH. Dual microcatheter coil embolization of acutely ruptured wide-necked intracranial aneurysms. *Interv Neuroradiol* 2017;23(05):477–484
 - 26 Lee JY, Seo JH, Cho YD, Kang HS, Han MH. Endovascular treatment of wide-neck intracranial aneurysms using a microcatheter protective technique: results and outcomes in 75 aneurysms. *AJNR Am J Neuroradiol* 2011;32(05):917–922
 - 27 Durst CR, Starke RM, Gaughen JR Jr, et al. Single-center experience with a dual microcatheter technique for the endovascular treatment of wide-necked aneurysms. *J Neurosurg* 2014;121(05):1093–1101
 - 28 Xu X, Zheng Y, Wang D, Cui J, Shang X. Improved endovascular coiling of wide-neck intracranial aneurysms in elderly patients by double-microcatheter technique. *Cell Biochem Biophys* 2015;71(03):1281–1286