



Are There Left–Right Differences in Ruptured Middle Cerebral Artery Bifurcation Aneurysms? A Single-Center Retrospective Study and Review of the Literature

Joji Inamasu¹ Katsuya Saito¹

¹Department of Neurosurgery, Saiseikai Utsunomiya Hospital, Utsunomiya, Japan

Asian J Neurosurg

Address for correspondence Joji Inamasu, MD, Department of Neurosurgery, Saiseikai Utsunomiya Hospital, Utsunomiya 321-0974, Japan (e-mail: inamasu@fujita-hu.ac.jp).

Abstract

Background The left (Lt) and right (Rt) middle cerebral artery bifurcation (MCAB) aneurysms have mostly been regarded as identical. Considering substantial Lt–Rt differences in hemispheric infarction, however, the presence of Lt–Rt differences may not be denied totally in patients with ruptured MCAB aneurysms. We herein investigated whether such Lt–Rt differences existed by a single-center retrospective study.

Materials and Methods Clinical data prospectively acquired between 2011 and 2021 on 99 patients with ruptured MCAB aneurysms were analyzed. They were dichotomized based on the laterality, and demographic and outcome parameters were compared. Additionally, a literature review was conducted to elucidate possible Lt–Rt differences in the frequency of ruptured MCAB aneurysms (Rt/Lt ratio).

Results Among the 99 patients, 42 had Lt and 57 had Rt ruptured MCAB aneurysms, with the Rt/Lt ratio of 1.36. Neither demographic, radiographic, nor outcome variables differed significantly between the two groups. A total of 19 studies providing information on the laterality of the ruptured MCAB were retrieved by literature search. A sum total for the Lt and Rt MCAB aneurysms was 671 and 940, making the Rt/Lt ratio of 1.40. After adding our data, a sum total for the Lt and Rt MCAB aneurysms was 713 and 997, making the Rt/Lt ratio of 1.40.

Conclusion The Rt ruptured MCAB aneurysms were 1.40 times more frequent than the Lt-sided counterpart. While there may be some Lt–Rt differences in the MCA anatomy, it remains to be seen whether such anatomical differences are truly responsible for the disproportionately higher frequency of Rt MCAB aneurysms.

Keywords

- ▶ middle cerebral artery
- ▶ aneurysm
- ▶ left–right differences
- ▶ subarachnoid hemorrhage
- ▶ frequency

Introduction

Saccular aneurysms arising from the middle cerebral artery bifurcation (MCAB) are frequently encountered in our neurosurgical practice: ruptured MCAB aneurysms account for

~25 to 30% of aneurysmal subarachnoid hemorrhage (aSAH).¹ Traditionally, the left (Lt) and right (Rt) MCAB aneurysms have been regarded by neurosurgeons as a single category, and only a few studies have been made to evaluate possible Lt–Rt differences in aSAH patients.^{1,2} Considering

DOI <https://doi.org/10.1055/s-0044-1788804>.
ISSN 2248-9614.

© 2024. Asian Congress of Neurological Surgeons. All rights reserved.

This is an open access article published by Thieme under the terms of the Creative Commons Attribution-NonDerivative-NonCommercial-License, permitting copying and reproduction so long as the original work is given appropriate credit. Contents may not be used for commercial purposes, or adapted, remixed, transformed or built upon. (<https://creativecommons.org/licenses/by-nc-nd/4.0/>)

Thieme Medical and Scientific Publishers Pvt. Ltd., A-12, 2nd Floor, Sector 2, Noida-201301 UP, India

substantial Lt-Rt differences in patients with hemispheric or insular infarction,³⁻⁶ however, the presence of Lt-Rt differences cannot totally be denied in patients with ruptured MCAB aneurysms. We herein investigated whether such differences existed or not. In addition, a literature review was conducted to elucidate possible Lt-Rt differences in the frequency of ruptured MCAB aneurysms.

Materials and Methods

Study Population

This study used data from a total of 428 patients with aSAH admitted to our institution from January 2011 to December 2021. Among the 428 aSAH patients registered, there were 99 ruptured MCAB aneurysm patients (23%). They were dichotomized to the Lt ($n=42$) versus Rt MCAB aneurysm ($n=57$) groups. Therefore, the Rt/Lt ratio was 1.36. Demographic, clinical, radiographic, and outcome variables were compared between the two groups. Demographic variables compared included age, gender, proportion of severe SAH represented by the World Federation of Neurosurgical Societies (WFNS) grade IV/V SAH, presence of hypertension, diabetes mellitus, smoking, three familial connective tissue diseases known to be associated with brain aneurysm formation (Ehlers-Danlos' syndrome, Marfan's syndrome, and polycystic kidney diseases), and treatment modalities for the ruptured aneurysm (i.e., clipping vs. coiling). The frequency of those who had sustained symptomatic vasospasm was also compared. The patient outcomes were evaluated using a modified Rankin scale (mRS) score ≤ 2 at 3 months after aSAH onset.

Radiographic Measurement

An effort was made to elucidate possible Lt-Rt differences in the radiographic anatomy in the 99 ruptured MCAB aneurysm patients. Parameters measured included the diameter of the ruptured aneurysms, length of the M1 segment, aspect ratio,⁷ and presence of the mirror (contralateral) MCAB aneurysms measured using source images of the three-dimensional-computed tomography angiography in each patient.

Statistical Analysis

The Fisher's exact test was used for categorical variables and unpaired *t*-test for continuous variables. JMP (SAS Institute, Cary, North Carolina, United States) was used for statistical analysis. Data are indicated by mean \pm standard deviation, and $p < 0.05$ was considered statistically significant.

Literature Review

To evaluate possible differences in the Lt/Rt ratio, a review of the literature was conducted using internet databases PubMed, Scopus, and Google Scholar. The keywords for the literature search included ruptured, middle cerebral artery aneurysm, subarachnoid hemorrhage, Lt, and Rt. The literature published since 2001 with a sample size of >10 cases was searched extensively and reviewed rigorously. Literature

in which no Lt-Rt distinction of MCAB aneurysms had been made was excluded from the analysis. Literature focusing solely on unruptured MCAB aneurysms was also excluded. Literature in which no distinction had been made between ruptured and unruptured MCAB aneurysms was analyzed separately.

Results

Demographic and Clinical Variables

The Lt MCAB aneurysm group ($n=42$) consisted of 19 men and 23 women, with a mean age of 62.1 ± 13.5 years. The Rt MCAB aneurysm group ($n=57$) consisted of 22 men and 35 women, with a mean age of 62.2 ± 11.5 years. Neither gender ratio nor age differed significantly between the two groups. The proportion of severe aSAH patients, represented by WFNS grade IV/V aSAH, was 57% in the Lt and 61% in the Rt MCAB aneurysm groups. The difference was not statistically significant ($p=0.68$). There were no significant differences in the frequency of comorbid diseases (hypertension, diabetes mellitus, smoking, familial connective tissue diseases) between the two groups. There was no significant difference in the clipping versus coiling ratio. There was no significant difference in the frequency of those with symptomatic vasospasm (29 vs. 23%, $p=0.64$). In addition, none of the radiographic parameters (aneurysm diameter, M1 length, aspect ratio, and frequency of mirror MCAB aneurysm) differed significantly between the two groups. The results of those two-group comparisons are shown in ►Table 1.

Outcomes

The frequency of favorable outcomes, represented as mRS score ≤ 2 at 3 months after aSAH onset, was compared after excluding 12 cases whose outcome data had been unavailable. The frequency was 47% in the Lt ($n=38$) and 49% in the Rt ($n=49$) MCAB aneurysm groups. The difference was not statistically significant ($p=1.00$, ►Fig. 1).

Literature Review

A total of 19 studies that provided detailed information on the laterality of the ruptured MCAB aneurysms were retrieved following the literature search (►Table 2).^{1,8-25} Each study is plotted in ►Fig. 1 based on its Rt/Lt ratio. In the great majority (17/19), the ratio exceeded 1.0. The sum total for the Lt and Rt MCAB aneurysms was 671 and 940, respectively, and therefore, the Rt/Lt ratio by the pooled literature analysis was 1.40 (►Fig. 2). After adding our data, the sum total for the Lt and Rt MCAB aneurysms was 713 and 997, respectively, and therefore, the Rt/Lt ratio was 1.40 (►Fig. 2).

Aside from the analysis described earlier focusing solely on the ruptured aneurysms, a total of seven studies that provided detailed information on the laterality of the MCAB aneurysms but failed to provide distinction between ruptured and unruptured status were retrieved following the literature search (►Table 3).²⁶⁻³² Each study is plotted in ►Fig. 2 based on its Rt/Lt ratio. In all studies (7/7), the

Table 1 Comparison of demographic variables between Lt and Rt ruptured MCAB aneurysms

	Lt MCAB (n = 42)	Rt MCAB (n = 57)	p-Value
Age (y)	62.1 ± 13.5	62.2 ± 11.5	0.99
Male:female	19:23	22:35	0.54
Severe SAH (WFNS grade IV/V)	24 (57%)	35 (61%)	0.68
Hypertension	22 (52%)	28 (49%)	0.84
Diabetes mellitus	3 (7%)	5 (9%)	1.00
Smoking	15 (36%)	26 (46%)	0.41
Familial connective tissue diseases ^a	2 (5%)	2 (4%)	1.00
Clipping vs. coiling ^b	36:1	48:1	1.00
Symptomatic vasospasm	12 (29%)	13 (23%)	0.64
Mean aneurysm diameter (mm)	6.5 ± 4.3	7.1 ± 5.4	0.59
M1 segment length (mm, ruptured side)	183 ± 53	174 ± 46	0.53
Aspect ratio	1.69 ± 0.56	1.76 ± 0.58	0.58
Mirror (contralateral MCAB) aneurysm	4 (10%)	4 (7%)	0.72

Abbreviations: Lt, left; MCAB, middle cerebral artery bifurcation; Rt, right; SAH, subarachnoid hemorrhage; WFNS, World Federation of Neurosurgical Societies.

^aConnective tissue diseases: defined here as those with a history of Ehlers–Danlos' syndrome, Marfan's syndrome, and polycystic kidney diseases, all known to be associated with brain aneurysm formation.

^bClipping versus coiling: 12 patients treated conservatively had been excluded.

Rt/Lt ratio exceeded 1.0. The sum total for the Lt and Rt MCAB aneurysms was 344 and 481, respectively, and therefore, the Rt/Lt ratio was 1.40 (►Fig. 3).

Discussion

Unlike patients with hemispheric or insular ischemic stroke,^{3–6} no significant Lt–Rt differences in demographic and outcome variables were found in our cohort of ruptured MCAB aneurysm patients. The lack of difference in the outcomes, evaluated with the mRS scores mainly focusing on the ability to walk independently, is compatible with the results of previous studies,^{2,23} and it is understandable why many neurosurgeons have not paid much attention to this Lt–Rt difference in the MCAB aneurysms. Nevertheless, consider-

ing the proximity of Broca's area and Lt MCA, it is not surprising that patients with ruptured MCA aneurysms fared worse in the recovery of postoperative language functions.³³ Therefore, the presence of the Lt–Rt difference in ruptured MCAB patients may not completely be excluded, particularly in the domain of cortical higher functions. Continued efforts to investigate this issue may not be futile.

Regarding the Lt/Rt ratio of ruptured MCAB aneurysms, there was striking concordance between the analysis on literature and the analysis on our cohort, pointing the Lt/Rt ratio of 1.40 (►Fig. 2). In addition, the Lt/Rt ratio was also 1.40 in a separate analysis on studies without distinction between ruptured and unruptured MCAB aneurysms (►Fig. 3).^{26–32} Although we made the separate analysis fearing for possible inhomogeneity between ruptured and unruptured aneurysm patients (►Fig. 3, ►Table 3), the results might virtually be identical. Interestingly, the Lt/Rt ratios were comparable among the Asian and Caucasian populations (►Tables 2 and 3), indicating that the ratio may not be affected by ethnicity. This is probably the first study to report on the marked Lt–Rt difference regarding the frequency of ruptured MCAB aneurysms. While the reason why the Rt MCAB aneurysms develop more frequently than the Lt MCAB aneurysms remains unclear, the Lt–Rt difference in the MCA anatomy may possibly be involved. Recently, da Cunha and da Cunha Correia reported that those with an MCAB aneurysm had significantly shorter M1 segment than those without aneurysm,³⁴ suggesting that short M1 may be a risk factor for MCAB aneurysm formation. Many anatomical and radiological studies have shown that the M1 segment of the Rt side was shorter than that of the Lt side, while the difference was significant in some^{35–37} and was not significant in others.^{38–40} There had been no significant Lt–Rt

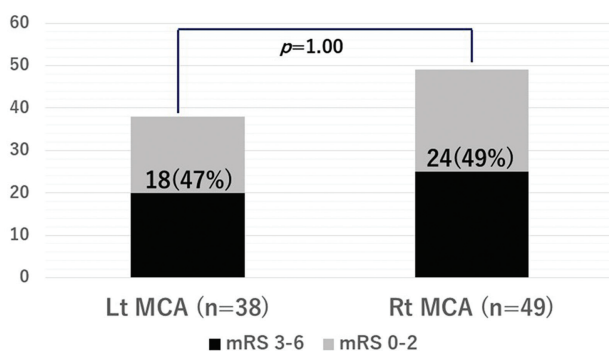


Fig. 1 The frequency of favorable outcomes (mRS ≤ 2 at 3 months after aSAH onset) was compared after excluding 12 patients whose data had been unavailable. The frequency was 47% in the Lt (n = 38) and 49% in the Rt (n = 49) MCAB aneurysm groups. The difference was not statistically significant. aSAH, aneurysmal subarachnoid hemorrhage; MCAB, middle cerebral artery bifurcation; Rt, right.

Table 2 Published articles describing Lt/Rt ratio of MCAB aneurysms (ruptured only)

No.	Authors ^(Ref. no.)	Journal, publication year	N	Ratio
1	Lee et al ¹⁶	<i>J Korean Neurosurg Soc</i> 2001	134	1:1.44
2	Choi et al ⁹	<i>J Korean Neurosurg Soc</i> 2004	85	1:1.56
3	Prat and Galeano ²¹	<i>Clin Neurol Neurosurg</i> 2007	12	1:1.40
4	Mutoh et al ²⁰	<i>Neurol Med Chir (Tokyo)</i> 2010	26	1:1.60
5	Kazumata et al ¹⁴	<i>Neurol Med Chir (Tokyo)</i> 2010	23	1:0.92
6	Lee et al ¹⁵	<i>J Cerebrovasc Endovasc Neurosurg</i> 2012	24	1:1.67
7	Lin et al ¹⁸	<i>J Neurosurg</i> 2012	40	1:1.26
8	Elsharkawy et al ¹²	<i>Neurosurgery</i> 2013	407	1:1.41
9	Inamasu et al ¹	<i>Stroke</i> 2013	79	1:1.47
10	Bohnstedt et al ⁸	<i>World Neurosurg</i> 2013	116	1:1.15
11	Zhang et al ²⁴	<i>World Neurosurg</i> 2017	30	1:1.14
12	Zijlstra et al ²⁵	<i>Neuroradiology</i> 2018	76	1:1.17
13	Mooney et al ¹⁹	<i>J Neurosurg</i> 2018	46	1:1.56
14	Hoz et al ¹³	<i>Roman Neurosurg</i> 2020	47	1:1.94
15	Xue et al ²³	<i>Front Neurol</i> 2021	40	1:1.50
16	Darsaut et al ¹⁰	<i>World Neurosurg</i> 2021	71	1:1.37
17	Dellaretti et al ¹¹	<i>Interdiscip Neurosurg</i> 2021	113	1:1.05
18	Sturiale et al ²²	<i>Neurosurg Rev</i> 2022	163	1:1.51
19	Li et al ¹⁷	<i>Front Surg</i> 2022	80	1:2.08
	Subtotal		1,611	1:1.40
	Our study		99	1:1.36
	Total		1,710	1:1.40

Abbreviations: Lt, left; MCAB, middle cerebral artery bifurcation; Rt, right.

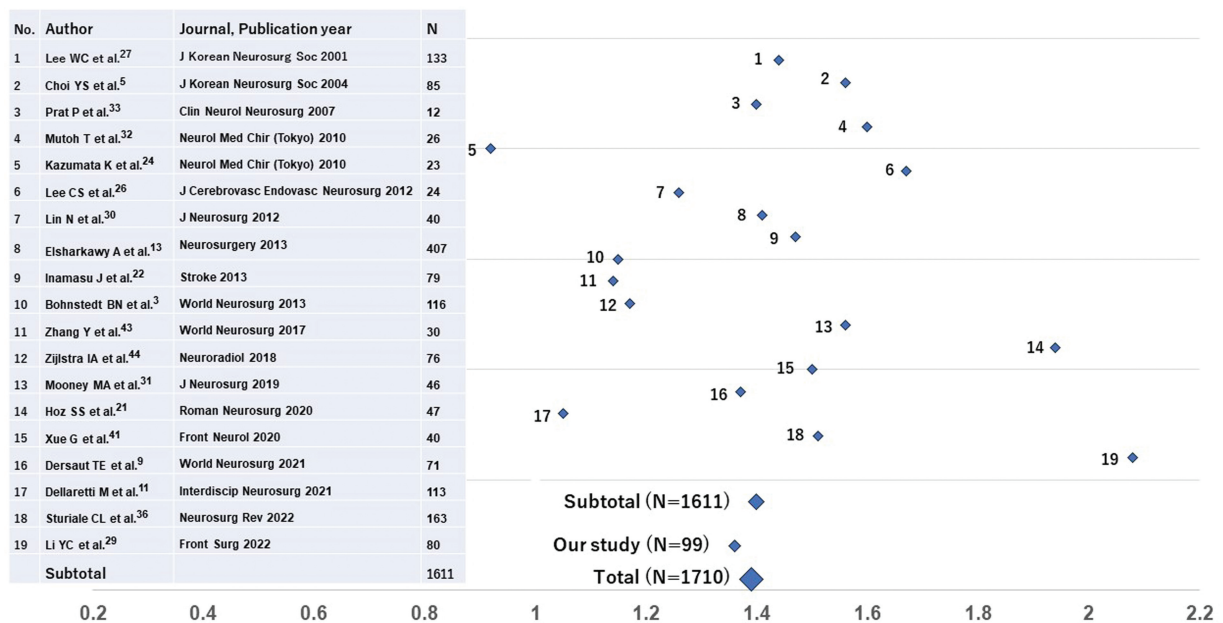


Fig. 2 A total of 19 studies providing detailed information on the side of the ruptured MCAB aneurysms were retrieved. Each study was plotted based on its Rt/Lt ratio. The sum total for the Lt and Rt MCAB aneurysms pooled from literature was 671 and 940, with the Rt/Lt ratio of 1.40 (subtotal). After adding our study with the Rt/Lt ratio of 1.36, the sum total for the Lt and Rt MCAB aneurysms was 713 and 997, with the Rt/Lt ratio of 1.40 (total). Lt, left; MCAB, middle cerebral artery bifurcation; Rt, right.

Table 3 Published articles describing Rt/Rt ratio of MCAB aneurysms (ruptured/unruptured)

No.	Authors ^(Ref. no.)	Journal, year	N	Lt/Rt ratio
1	Horowitz et al ³¹	<i>Surg Neurol</i> 2006	30	1:1.14
2	Ulmet al ³²	<i>Neurosurgery</i> 2008	84	1:1.38
3	Diaz et al ²⁷	<i>World Neurosurg</i> 2014	84	1:1.90
4	Hallout ³⁰	<i>World Neurosurg</i> 2015	251	1:1.44
5	Berro et al ²⁶	<i>J Neurosurg</i> 2019	187	1:1.28
6	Hagen et al ²⁹	<i>Cardiovasc Intervent Radiol</i> 2021	118	1:1.27
7	De Leacy et al ²⁸	<i>Front Neurol</i> 2022	71	1:1.45
	Total		825	1:1.40

Abbreviations: Lt, left; MCAB, middle cerebral artery bifurcation; Rt, right.

difference in the length of M1 segment in our cohort (► **Table 1**), however, and it remains unclear or questionable whether the Lt-Rt difference in the length of M1 segment truly explain the substantial Lt-Rt difference in the frequency of MCAB aneurysms. There may also seem to be a possible Lt-Rt difference in the MCAB angle, which is a known risk factor for aneurysm formation.^{41,42} The Rt MCAB angle was shown to be larger than the Lt MCAB angle in several studies,^{41,43,44} although the difference was nonsignificant. It remains to be seen in future studies whether those differences in the MCA anatomy could explain the higher frequency of the Rt MCAB aneurysms.⁴⁵

There are several limitations in this study. First, the outcomes were evaluated only at hospital discharge. Difference might have become more apparent with longer observation period. Second, while we made every effort to retrieve as many articles as possible to make the literature review comprehensive, the review was not systematically con-

ducted and might be affected by selection bias. Therefore, we are currently collecting resources for conducting systematic review on this issue. Third, we intentionally excluded unruptured MCAB aneurysms in this analysis, because of possible mismatch between number of patients and number of aneurysms which are often multiple.

Conclusion

The Rt ruptured MCAB aneurysms were 1.40 times more frequent than the Lt-sided counterpart. While there may be some Lt-Rt differences in the MCA anatomy, it remains to be seen whether such anatomical differences are truly responsible for the disproportionately higher frequency of Rt MCAB aneurysms. While the difference is unlikely to have great impact on our daily practice, a knowledge that the Lt MCAB and Rt MCAB aneurysms may not entirely be identical may lead to another finding which may have been unnoticed.

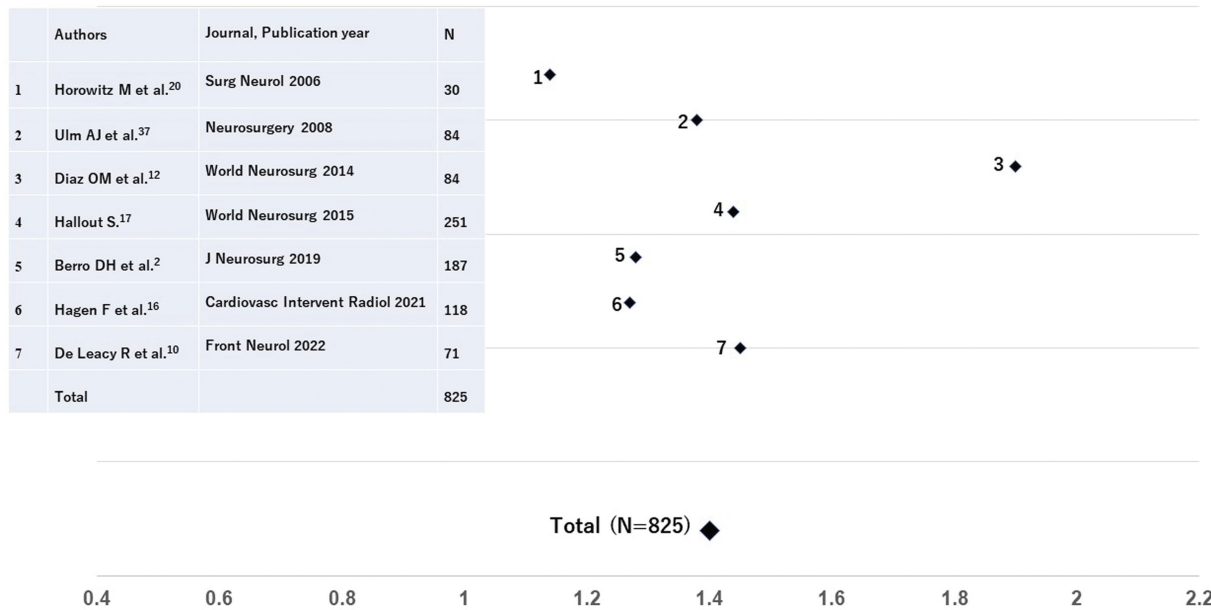


Fig. 3 A total of seven studies that provided detailed information on the laterality of the MCAB aneurysms but failed to provide distinction between ruptured and unruptured status were retrieved. Each study was plotted based on its Rt/Lt ratio. The sum total for the Lt and Rt MCAB aneurysms pooled from literature was 344 and 481, with the Rt/Lt ratio of 1.40 (total). Lt, left; MCAB, middle cerebral artery bifurcation; Rt, right.

Authors' Contributions

Joji Inamasu contributed to writing and data collection. Katsuya Saito contributed to data collection and supervision.

Availability of Data and Material

Raw data were generated at our institution. Derived data supporting the findings of this study are available from the corresponding author (J.I.) on request.

Ethical Approval

This study was approved by our institutional ethics committee (authorization no. 17-012). And conducted in accordance with the Declaration of Helsinki. The need for informed consent from each participant was waived by the ethical committee.

Funding

None.

Conflict of Interest

None declared.

References

- Inamasu J, Sugimoto K, Watanabe E, Kato Y, Hirose Y. Effect of insular injury on autonomic functions in patients with ruptured middle cerebral artery aneurysms. *Stroke* 2013;44(12):3550–3552
- Brawanski N, Kashefiolasl S, Won SY, et al. Does aneurysm side influence the infarction side and patients' outcome after subarachnoid hemorrhage? *PLoS One* 2019;14(11):e0224013
- Colivicchi F, Bassi A, Santini M, Caltagirone C. Prognostic implications of right-sided insular damage, cardiac autonomic derangement, and arrhythmias after acute ischemic stroke. *Stroke* 2005;36(08):1710–1715
- Kemmling A, Lev MH, Payabvash S, et al. Hospital acquired pneumonia is linked to right hemispheric peri-insular stroke. *PLoS One* 2013;8(08):e71141
- Li J, Zhang P, Liu Y, Chen W, Yi X, Wang C. Stroke lateralization in large hemisphere infarctions: characteristics, stroke-related complications, and outcomes. *Front Neurol* 2021;12:774247
- Rastogi V, Lamb DG, Williamson JB, et al. Hemispheric differences in malignant middle cerebral artery stroke. *J Neurol Sci* 2015;353(1-2):20–27
- Zheng Y, Xu F, Ren J, et al. Assessment of intracranial aneurysm rupture based on morphology parameters and anatomical locations. *J Neurointerv Surg* 2016;8(12):1240–1246
- Bohnstedt BN, Nguyen HS, Kulwin CG, et al. Outcomes for clip ligation and hematoma evacuation associated with 102 patients with ruptured middle cerebral artery aneurysms. *World Neurosurg* 2013;80(3-4):335–341
- Choi YS, Song YJ, Kim HD. Intracerebral hemorrhage secondary to ruptured middle cerebral artery aneurysms: therapeutic consideration and prognostic factors related to the site of hemorrhage. *J Korean Neurosurg Soc* 2004;35:284–289
- Darsaut TE, Keough MB, Sagga A, et al. Surgical or endovascular management of middle cerebral artery aneurysms: a randomized comparison. *World Neurosurg* 2021;149:e521–e534
- Dellaretti M, do Nascimento LM, de Oliveira Lima AD, et al. Efficacy and safety of surgical treatment for middle cerebral artery aneurysms: a retrospective case series. *Interdiscip Neurosurg* 2021;23:101018
- Elsharkawy A, Lehečka M, Niemelä M, et al. Anatomic risk factors for middle cerebral artery aneurysm rupture: computed tomography angiography study of 1009 consecutive patients. *Neurosurgery* 2013;73(05):825–837, discussion 836–837
- Hoz SS, Albanaa SA, Neamah AM, et al. Prognostic factors of ruptured middle cerebral artery aneurysms treated with surgical clipping. *Rom Neurosurg* 2020;34:245–253
- Kazumata K, Kamiyama H, Yokoyama Y, et al. Poor-grade ruptured middle cerebral artery aneurysm with intracerebral hematoma: bleeding characteristics and management. *Neurol Med Chir (Tokyo)* 2010;50(10):884–892
- Lee CS, Park JU, Kang JG, Lim YC. The clinical characteristics and treatment outcomes of patients with ruptured middle cerebral artery aneurysms associated with intracerebral hematoma. *J Cerebrovasc Endovasc Neurosurg* 2012;14(03):181–185
- Lee WC, Choi CH. Prognostic factors of ruptured middle cerebral artery aneurysm with intracerebral hematoma. *J Korean Neurosurg Soc* 2001;30(Suppl 1):S91–S98
- Li YC, Chen CC, Chen CT, et al. Delayed progressive mass effect after secured ruptured middle cerebral artery aneurysm: risk factors and outcomes. *Front Surg* 2022;9:852576
- Lin N, Ho A, Gross BA, et al. Differences in simple morphological variables in ruptured and unruptured middle cerebral artery aneurysms. *J Neurosurg* 2012;117(05):913–919
- Mooney MA, Simon ED, Brigeman S, et al. Long-term results of middle cerebral artery aneurysm clipping in the Barrow Ruptured Aneurysm Trial. *J Neurosurg* 2018;130(03):895–901
- Mutoh T, Ishikawa T, Moroi J, Suzuki A, Yasui N. Impact of early surgical evacuation of sylvian hematoma on clinical course and outcome after subarachnoid hemorrhage. *Neurol Med Chir (Tokyo)* 2010;50(03):200–208
- Prat R, Galeano I. Early surgical treatment of middle cerebral artery aneurysms associated with intracerebral haematoma. *Clin Neurol Neurosurg* 2007;109(05):431–435
- Sturiale CL, Scerrati A, Ricciardi L, et al. Clipping versus coiling for treatment of middle cerebral artery aneurysms: a retrospective Italian multicenter experience. *Neurosurg Rev* 2022;45(05):3179–3191
- Xue G, Zhou Y, Liu P, et al. Endovascular treatment of ruptured middle cerebral artery aneurysms with a low-profile visualized intraluminal support device. *Front Neurol* 2021;11:631745
- Zhang Y, Hu Q, Xue H, et al. Intrasyllian/intracerebral hematomas associated with ruptured middle cerebral artery aneurysms: a single-center series and literature review. *World Neurosurg* 2017;98:432–437
- Zijlstra IA, van der Steen WE, Verbaan D, et al. Ruptured middle cerebral artery aneurysms with a concomitant intraparenchymal hematoma: the role of hematoma volume. *Neuroradiology* 2018;60(03):335–342
- Berro DH, L'Allinec V, Pasco-Papon A, et al. Clip-first policy versus coil-first policy for the exclusion of middle cerebral artery aneurysms. *J Neurosurg* 2019;133(04):1124–1131
- Diaz OM, Rangel-Castilla L, Barber S, Mayo RC, Klucznik R, Zhang YJ. Middle cerebral artery aneurysms: a single-center series comparing endovascular and surgical treatment. *World Neurosurg* 2014;81(02):322–329
- De Leacy R, Bageac DV, Siddiqui N, et al. Safety and long-term efficacy outcomes for endovascular treatment of wide-neck bifurcation aneurysms of the middle cerebral artery: insights from the SMART Registry. *Front Neurol* 2022;13:830296
- Hagen F, Berlis A, Skalej M, Maurer CJ. Endovascular treatment of ruptured middle cerebral artery bifurcation aneurysms. a retrospective observational study of short- and long-term follow-up. *Cardiovasc Intervent Radiol* 2021;44(04):587–595
- Hallout S. Surgical treatment of middle cerebral artery aneurysms without using indocyanine green videoangiography assistance: retrospective monocentric study of 263 clipped aneurysms. *World Neurosurg* 2015;84(04):972–977

- 31 Horowitz M, Gupta R, Gologorsky Y, et al. Clinical and anatomic outcomes after endovascular coiling of middle cerebral artery aneurysms: report on 30 treated aneurysms and review of the literature. *Surg Neurol* 2006;66(02):167–171, discussion 171
- 32 Ulm AJ, Fautheree GL, Tanriover N, et al. Microsurgical and angiographic anatomy of middle cerebral artery aneurysms: prevalence and significance of early branch aneurysms. *Neurosurgery* 2008;62(5, suppl 2):ONS344–ONS352, discussion ONS352–ONS353
- 33 Vieira ACC, Andrade G, Souza MP, et al. Performance of language tasks in patients with ruptured aneurysm of the left hemisphere worses in the post-surgical evaluation. *Arq Neuropsiquiatr* 2016;74(08):638–643
- 34 da Cunha CEG, da Cunha Correia C. Middle cerebral artery extension and the risk for aneurysmal disease. *J Neurol Sci* 2018;390:219–221
- 35 Cieśllicki K. Experimental and numerical modelling of flow in the human cerebral arteries. *J Med Info Tech* 2004;7:17–26
- 36 Hassan NH, Mansor MAEB, Ibrahim AAS, Ibrahim AH. Anatomical measurement of cerebral arteries using digital subtraction angiography. *Ain Shams Med J* 2020;71:259–267
- 37 Hema N, Sharieff JH. Study of M1 segment of middle cerebral artery in human cadaveric brains with clinical implications of its early branches. *Int J Anat Res* 2018;6:5936–5944
- 38 Gunnal SA, Farooqui MS, Wabale RN. Study of middle cerebral artery in human cadaveric brain. *Ann Indian Acad Neurol* 2019;22(02):187–194
- 39 Sato D, Ogawa S, Torazawa S, Dofuku S, Sato M, Ota T. Evaluation of middle cerebral artery symmetry: a pilot study for clinical application in mechanical thrombectomy. *World Neurosurg* 2022;166:e980–e985
- 40 Umansky F, Juarez SM, Dujovny M, et al. Microsurgical anatomy of the proximal segments of the middle cerebral artery. *J Neurosurg* 1984;61(03):458–467
- 41 Kaspera W, Ćmiel-Smorzyk K, Wolański W, et al. Morphological and hemodynamic risk factors for middle cerebral artery aneurysm: a case-control study of 190 patients. *Sci Rep* 2020;10(01):2016
- 42 Tan J, Zhu H, Huang J, et al. The association of morphological differences of middle cerebral artery bifurcation and aneurysm formation: a systematic review and meta-analysis. *World Neurosurg* 2022;167:17–27
- 43 Baharoglu MI, Lauric A, Safain MG, Hippelheuser J, Wu C, Malek AM. Widening and high inclination of the middle cerebral artery bifurcation are associated with presence of aneurysms. *Stroke* 2014;45(09):2649–2655
- 44 Fan F, Xiang T, Tsauo J, et al. Comparison of cerebral artery angle in adults and fetuses. *Int J Morphol* 2015;33:942–947
- 45 Zhang J, Can A, Lai PMR, et al. Geometric features associated with middle cerebral artery bifurcation aneurysm formation: a matched case-control study. *J Stroke Cerebrovasc Dis* 2022;31(03):106268