



# Prevalence of the Absence of the Palmaris Longus and Functional Flexor Digitorum Superficialis of the Little Finger in the Indian Population

Subashini Rajendiran<sup>1</sup> Srinivasan Rajappa<sup>1</sup> Sandhiya Jaichandran<sup>1</sup> Anil Bhat<sup>2</sup> Mukund Thatte<sup>3</sup>

<sup>1</sup>Department of Hand Surgery, Sri Ramachandra Institute of Higher Education and Research, Porur, Chennai, Tamil Nadu, India

<sup>2</sup>Department of Hand Surgery, Kasturba Medical College, Manipal, Karnataka, India

<sup>3</sup>Department of Plastic Surgery, Bombay Hospital, Mumbai, Maharashtra, India

**Address for correspondence** Subashini Rajendiran, MBBS, DNB (Gen surgery), M.Ch (Plastic surgery), E.D.H.S, Department of Hand Surgery, Sri Ramachandra Institute of Higher Education and Research, Porur, Chennai, Tamil Nadu 600116, India (e-mail: doctor.subashini@gmail.com).

Indian J Plast Surg

## Abstract

**Background** The absence of the palmaris longus (PL) varies with race. The presence of a functional flexor digitorum superficialis (FDS) of the little finger also varies widely. The aim of this study is to determine the prevalence of the absence of the PL and functional FDS of the little finger in the Indian population.

**Materials and Methods** This is a prospective observational study conducted as a part of the Indian normative data project of the Indian Society for Surgery of the Hand. The presence of the PL was assessed by Schaeffer's test. The function of the FDS was assessed by the standard test and modified test and its function designated as absent, present independently, or present combinedly with the ring finger FDS.

**Results** A total of 200 volunteers including 84 males and 116 females in the 21- to 60-year age group were examined. Of the 400 hands examined, the PL was absent in 26 upper limbs (6.5%). The PL was absent unilaterally in 12 individuals (6%) and bilaterally in 7 individuals (3.5%). Of the 400 little fingers examined, FDS function was absent in 72 fingers (18%), while 67 fingers (16.75%) had a common function and 261 fingers (65.25%) had an independent function. Only 2% had a bilateral absence of both the PL and functional FDS tendons and 5% had a unilateral absence of both tendons.

**Conclusion** The PL and FDS of the little finger were more absent in the right side than in the left side, but the difference was not statistically significant. There was no significant association between the absence of the PL and the absence of the functional FDS of the little finger.

## Keywords

- ▶ tendon absence
- ▶ palmaris longus
- ▶ flexor digitorum superficialis absence
- ▶ Schaeffer's test
- ▶ Baker's test
- ▶ normative data

## Introduction

The palmaris longus (PL) and the flexor digitorum superficialis (FDS) are the frequently absent tendons of the upper limb. Both are frequently used donors for tendon reconstruction. In

addition, the absence of a functional FDS affects the outcome of isolated injury of the flexor digitorum profundus of the little finger. The prevalence of PL absence shows a wide variation among different ethnic groups.<sup>1,2</sup> The FDS of the little finger

DOI <https://doi.org/10.1055/s-0044-1788932>.  
ISSN 0970-0358.

© 2024. Association of Plastic Surgeons of India. All rights reserved. This is an open access article published by Thieme under the terms of the Creative Commons Attribution-NonDerivative-NonCommercial-License, permitting copying and reproduction so long as the original work is given appropriate credit. Contents may not be used for commercial purposes, or adapted, remixed, transformed or built upon. (<https://creativecommons.org/licenses/by-nc-nd/4.0/>)  
Thieme Medical and Scientific Publishers Pvt. Ltd., A-12, 2nd Floor, Sector 2, Noida-201301 UP, India

has various anatomical variations.<sup>3</sup> The study was conducted to determine the prevalence of the absence of the PL and functional FDS of the little finger in the Indian population.

## Materials and Methods

The study was a prospective study conducted at our institute after the Institute Ethical Committee clearance. The study population was 200 volunteers who responded to the pamphlet displayed on the notice board. All of them gave informed consent for the study and inclusion of their data. The volunteers included students, staff, employees of the institute, and patient attenders, and belonged to various states of the country.

The volunteers were assessed for the presence of the PL by Schaeffer's test in both hands as shown in ►**Fig. 1**. Schaeffer's test was done by palpating the PL while flexing the wrist and keeping the thumb opposed to the little finger.<sup>4,5</sup>

Then the function of the FDS of the little finger was assessed by the standard test and as described by Kaplan<sup>6</sup> the modified test as described by Baker et al<sup>7</sup>, and results were divided into independent, common, and absent functions.<sup>4</sup> The standard test as shown in ►**Fig. 2**, was performed by asking the volunteer to flex the little finger while restraining the FDP function of other fingers. If the volunteer flexed the proximal interphalangeal (PIP) joint of the little finger more than 90 degrees, the result was termed independent.<sup>6</sup>

The modified test as shown in ►**Figs. 3 and 4**, was performed by asking the volunteer to flex the little and ring fingers while restraining the FDP action of the middle and index fingers. If the volunteer was able to flex the little finger PIP more than 90 degrees with the DIP joint in neutral,

the test was considered positive and the result was termed common, the inference being the little finger FDS is adherent to the ring finger FDS.<sup>7</sup>

All statistical tests were conducted using SPSS and the association between the absence of the PL and functional little finger FDS was assessed using the chi-squared test.


## Results

Two hundred individuals aged between 21 and 60 years were examined. The mean age was 37 years. There were 84 males (42%) and 116 females (58%). The PL was absent unilaterally in 12 individuals (6%) and bilaterally in 7 individuals (3.5%). When unilaterally absent, it was absent on the right side in eight individuals and on the left side in four individuals.

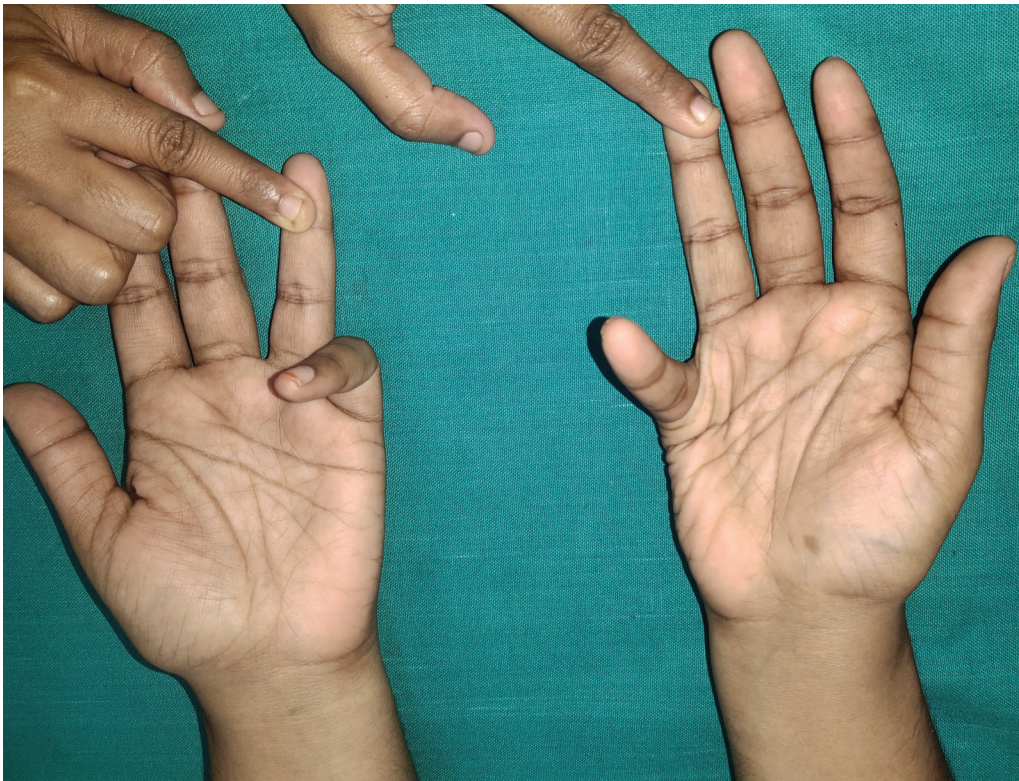Of the 400 hands examined, PL absence was seen in 26 upper limbs (6.5%). The PL was more absent in the right side and the difference in prevalence between the two sides was 1% (►**Table 1**). The association between absence in the right and left sides was not statistically significant with odds ratio of 39.5 (95% confidence interval [CI] = 9.5–163), risk ratio (Risk Ratio [RR]) = 21.5 (95% CI = 7.5–65.4), and chi-squared test value of 52 ( $p = 0$ ).

Of the 400 little fingers examined, FDS function was absent in 72 fingers (18%), while 67 fingers (16.75%) had a common/combined function and 261 fingers (65.25%) had an independent function (►**Table 2**).

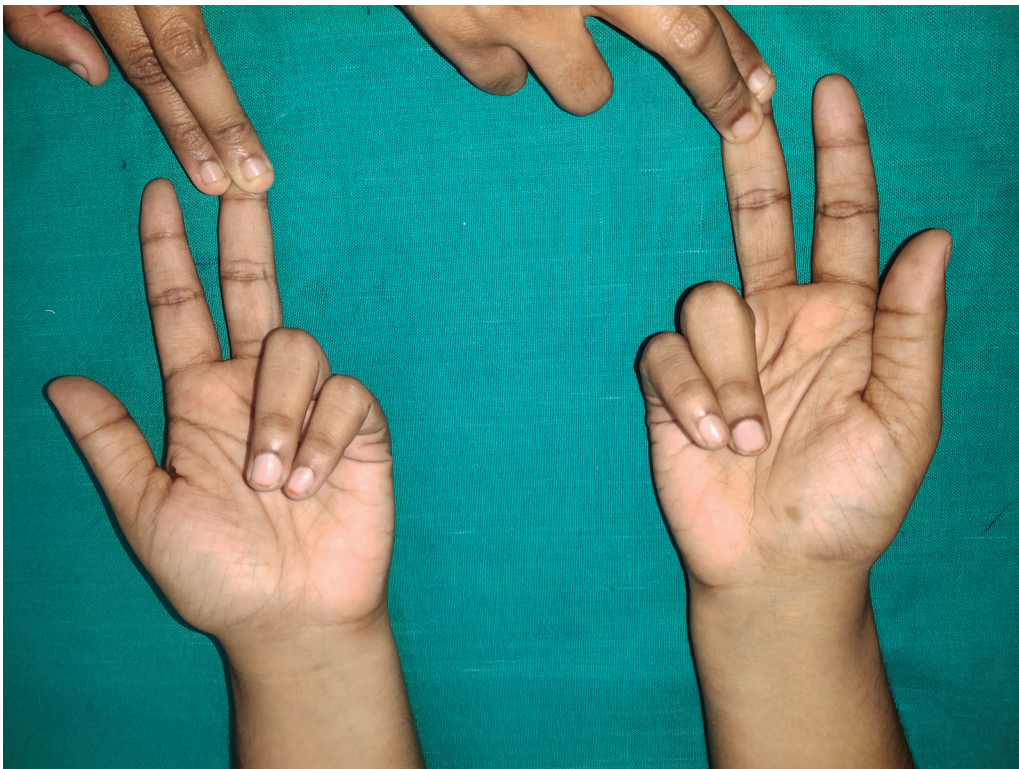The independent FDS function was bilaterally absent in 54 individuals (27%) and unilaterally absent in 31 individuals (15.5%). When unilaterally absent, it was absent on the right side in 18 individuals and on the left side in 13 individuals.



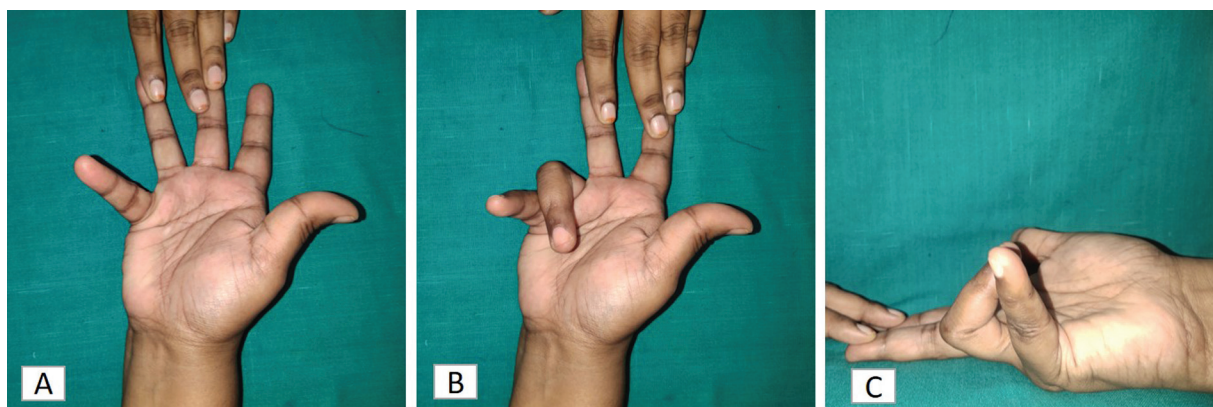
**Fig. 1** Schaeffer's test shows the presence of the palmaris longus in the left hand and its absence in the right hand.



**Fig. 2** The standard test shows the absence of functional flexor digitorum superficialis (FDS) of the little finger in the right hand and its presence in the left hand.



**Fig. 3** The modified test. The same hand in ► **Fig. 2** shows a functional flexor digitorum superficialis (FDS) of the little finger in the right hand on performing the modified test.



**Fig. 4** (A) The standard test shows the absence of the flexor digitorum superficialis (FDS) in the little finger. (B) The modified test also shows the absence of a functional FDS in the little finger. (C) Lateral view showing the absence of the FDS in the little finger in the modified test.

**Table 1** Prevalence of palmaris longus absence

Palmaris longus	Present	Absent
Right side ( $n = 200$ hands)	185 (92.50%)	15 (7.50%)
Left side ( $n = 200$ hands)	189 (94.50%)	11 (5.50%)
Total ( $n = 400$ hands)	374 (93.5%)	26 (6.5%)

The FDS of the little finger was more absent on the right side and the difference in prevalence between the two sides was 3%. The association between the absence on the right and left sides was not significant with an odds ratio of 17.6 (95% CI = 7.3–42.5), RR = 8.2 (95% CI = 4.3–15.5), and a chi-squared test value = 56 ( $p = 0$ ).

Only 2% had a bilateral absence of both the PL and functional FDS tendons and 5% had a unilateral absence of both tendons.

There was no significant association between the absence of the PL and functional FDS. For the absence on the right side, the odds ratio was 3 (95% CI = 1.02–9.2) and RR was 2.2 (95% CI = 1.1–4.4) and for absence on the left side, the odds ratio was 3.1% (95% CI = 0.8–11.4) and RR was 2.3 (95% CI = 1.0–5.5). The  $p$ -value was 0.03 on the right side and 0.06 on the left side.

## Discussion

### Prevalence of Palmaris Longus

Many textbooks quote that the PL is absent in 15% of the global population.<sup>4</sup> A systemic review of 32 studies by

Ioannis et al showed that its absence prevalence ranges between 1.5 and 63.9%.<sup>1</sup>

Our study, conducted in south India, found the prevalence of absence of the PL to be 6.5%. Mugalur et al studied the population in central India and reported an absence of 19.3%.<sup>8</sup> Another study from central India reported unilateral absence of 16.95% and bilateral absence of 3.3%.<sup>9</sup> Both studies showed a higher prevalence of absence than the current study. Three further studies from India showed that the PL was absent in 264 of 942 (28%) individuals studied,<sup>10</sup> 65 of 400 (16.25%) individuals studied,<sup>11</sup> and 73 of 266 (27.44%) studied.<sup>12</sup> Three cadaver studies were done in India. Pai et al found the absence to be 3.33%,<sup>13</sup> Patil et al found 16% to be absent,<sup>14</sup> and Lalit et al found 8.06% to be absent.<sup>15</sup> This emphasizes the significant variations in the prevalence of the absence of PL within our country. This sort of various prevalence within different regions in the same country is seen in the systemic review by Ioannis et al.<sup>1</sup>

### Prevalence of Functional FDS of the Little Finger

The absence of a functional FDS of the little finger has been discussed a lot. Furnas noted that 6 of 100 cadaver forearms had no muscle belly or tendon in the wrist representing the FDS of little finger.<sup>16</sup> Shrewsbury and Kuczynski noted 30% absence of the FDS tendon on dissecting 23 hands.<sup>17</sup> Kaplan found that 30.85% of the FDS of the little finger had a connection to the FDS of the index finger and 33.6% had a connection to the FDS of the ring finger while dissecting 68 cadaver hands.<sup>6</sup>

On clinical examination by applying the standard and modified tests, Austin et al found that 58% had an independent function, 21% had a combined function, and 21% had no function.<sup>18</sup> The study done by Watanabe et al showed an

**Table 2** Summary of clinical evaluation of functional FDS of the little finger

Standard and modified test for the FDS	Independent function	Combined function with FDS of the ring finger	Absent function
Right side ( $n = 200$ hands)	128 (64%)	33 (16.5%)	39 (19.5%)
Left side ( $n = 200$ hands)	133 (66.50%)	34 (17%)	33 (16.5%)
Total ( $n = 400$ hands)	261 (65.25%)	67 (16.75%)	72 (18%)

independent function in 67.5%, a combined function in 12.0%, and an absent function in 20.5%.<sup>19</sup> Similarly, in our study, the majority of 65.25% had an independent function of the FDS of the little finger, followed by absent FDS function in 18% and a common function in 16.75%.

### Association between Absence of the PL and Functional FDS of the Little Finger

There was no statistically significant association between the absence of the PL and functional FDS. This is similar to the findings in Thompson et al,<sup>20</sup> Alzahrani et al,<sup>21</sup> Kigera et al,<sup>22</sup> and Sebastin et al.<sup>4</sup>

The limitation of our study is the relatively small sample size and lack of multicentric representation.

### Conclusion

The prevalence of an absent PL in our study is 6.50%. There is no association between the absence of the PL and the side of the hand. The prevalence of independent functional absence of the FDS of the little finger is 18% and there is no association with the side of the hand. Also, there is no statistically significant association between an absent PL and an absent functional FDS of the little finger.

#### Authors' Contributions

Su.R. was the principal investigator for the project as a whole, and was responsible for data collection and writing the manuscript. Sr.R. was responsible for logistical support and editing the manuscript. A.B. was the coordinator of the ISSH Normative Data project, and contributed to editing of the manuscript. S.J. assisted in data collection. M.T. conceptualized the ISSH Normative Data project and contributed to editing of the manuscript.

#### Ethical Approval

Institutional review board clearance was obtained for the study and the study protocols conformed to the Declaration of Helsinki.

#### Funding

None.

#### Conflict of Interest

None declared.

#### Acknowledgments

We would like to acknowledge Dr. Senthilvadivu for her help in statistical analysis. We would like to acknowledge hand therapist Mr. Venubabu from the corresponding author's institute. We would like to thank the members of the Indian Society for Surgery of the Hand and the Normative Data Research Group of ISSH for their support and guidance.

### References

- Ioannis D, Anastasios K, Konstantinos N, Lazaros K, Georgios N. Palmaris longus muscle's prevalence in different nations and interesting anatomical variations: review of the literature. *J Clin Med Res* 2015;7(11):825–830
- Yammine K. Clinical prevalence of palmaris longus agenesis: a systematic review and meta-analysis. *Clin Anat* 2013;26(06):709–718
- Tan J, Kim CH, Lee HJ, Chen J, Chen QZ, Jeon IH. A new examination method for anatomical variations of the flexor digitorum superficialis in the little finger. *Clin Orthop Surg* 2013;5(02):138–144
- Sebastin SJ, Lim AY, Wong H-B. Clinical assessment of absence of the palmaris longus and its association with other anatomical anomalies: a Chinese population study. *Ann Acad Med Singap* 2006;35(04):249–253
- Schaeffer JP. On the variations of the palmaris longus muscle. *Anat Rec* 1909;3:275–278
- Kaplan EB. Muscular and tendinous variations of the flexor superficialis of the fifth finger of the hand. *Bull Hosp Jt Dis* 1969;30(01):59–67
- Baker DS, Gaul JS Jr, Williams VK, Graves M. The little finger superficialis: clinical investigation of its anatomic and functional shortcomings. *J Hand Surg Am* 1981;6(04):374–378
- Mugalur A, Shahane SM, Samant A, Pathak AC, Patil A, Reddy R. Anatomic variation of palmaris longus and flexor digitorum superficialis of little finger in Indian population. *SICOT J* 2015;1:5
- Agarwal P. Absence of the palmaris longus tendon in Indian population. *Indian J Orthop* 2010;44(02):212–215
- Sankar KD, Bhanu PS, John SP. Incidence of agenesis of palmaris longus in the Andhra population of India. *Indian J Plast Surg* 2011;44(01):134–138
- Sharma DK, Shukla CK, Sharma V. Clinical assessment of absence of palmaris longus muscle and its association with gender, body sides, handedness and other neighbouring anomalies in a population of central India. *J Anat Soc India* 2012;61:13–20
- Tejaswi HL, Shilpashree YD. Clinical assessment of agenesis of palmaris longus and flexor digitorum superficialis in Indian population. *International Journal of Recent Trends in Science And Technology* 2014;10:492–494
- Pai MM, Prabhu LV, Nayak SR, et al. The palmaris longus muscle: its anatomic variations and functional morphology. *Rom J Morphol Embryol* 2008;49(02):215–217
- Patil GV, Shishirkumar, Thejeswari, et al. Study of absence of palmaris longus muscle in South Indian population. *Int J Curr Res* 2014;6(08):7887–7889
- Lalit M, Piplani S, Mahajan A, Verma P. Morphological analysis of palmaris longus muscle and its anatomic variations: a cadaveric study in North India. *Ital J Anat Embryol* 2019;124:443–454
- Furnas DW. Muscle-tendon variations in the flexor compartment of the wrist. *Plast Reconstr Surg* 1965;36(03):320–323
- Shrewsbury MM, Kuczynski K. Flexor digitorum superficialis tendon in the fingers of the human hand. *Hand* 1974;6(02):121–133
- Austin GJ, Leslie BM, Ruby LK. Variations of the flexor digitorum superficialis of the small finger. *J Hand Surg Am* 1989;14(2, Pt 1):262–267
- Watanabe Y, Shirato R, Wada T, Iba K, Sonoda T, Yamashita T. Quantitative examination of isolated finger flexion associated with function of the flexor digitorum superficialis. *J Phys Ther Sci* 2020;32(11):748–753
- Thompson NW, Mockford BJ, Rasheed T, Herbert KJ. Functional absence of flexor digitorum superficialis to the little finger and absence of palmaris longus: is there a link? *J Hand Surg [Br]* 2002;27(05):433–434
- Alzahrani MT, Almalki MA, Al-Thunayan TA, Almohawis AH, Al Turki AT, Umedani L. Clinical assessment of the congenital absence of palmaris longus and flexor digitorum superficialis muscles in young Saudi population. *Anat Res Int* 2017;2017:5342497
- Kigera JWM, Mukwaya S, Katusiime A. The relationship between functional absence of the flexor digitorum superficialis to the fifth digit and absence of the palmaris longus. *EAJ* 2013;7(01):11–13