



Foot and Ankle Reconstruction Using Retrograde Lateral Supramalleolar Flap

Thach Ngoc Nguyen¹ Tuong Trong Mai¹ Khanh Hoa Vo¹ An Van Nguyen¹
An Nguyen Nguyen² Thi Cao³

¹Hospital for Traumatology and Orthopaedics, Ho Chi Minh City, Ho Chi Minh City, Vietnam

²Virginia Commonwealth University, Richmond, Virginia, United States of America

³University of Medicine and Pharmacy at Ho Chi Minh City, Ho Chi Minh City, Vietnam

Address for correspondence Thi Cao, PhD, MD, University of Medicine and Pharmacy at Ho Chi Minh City, 217 Hong Bang Street, Ward 11, District 5, Ho Chi Minh City 17000, Vietnam (e-mail: caothibacsi@ump.edu.vn).

Indian J Plast Surg

Abstract

Keywords

- ▶ retrograde lateral supramalleolar flap
- ▶ foot and ankle reconstruction
- ▶ soft-tissue defects
- ▶ reconstructive surgical procedures

Background Treatment of soft-tissue defects in the foot and ankle is a challenge. The use of a retrograde lateral supramalleolar flap is a promising technique for reconstruction. This study aims to assess the efficacy and outcomes of the technique.

Materials and Methods A prospective observational study was conducted from December 2017 to December 2022. Patients with soft-tissue defects in the foot and ankle underwent reconstruction using the retrograde lateral supramalleolar flap. Data on demographics, injury details, flap dimensions, complications, and outcomes were recorded and analyzed.

Results Forty-six flaps were used in the study. The average flap length was 17.47 cm. The maximum size of the flaps was 104 cm² with an average of 48.43 cm². Venous congestion occurred in nine flaps, leading to partial necrosis in four cases. The overall success rate was 91.3%.

Conclusion The retrograde lateral supramalleolar flap is effective in covering soft-tissue defects in the foot and ankle.

Introduction

The injury of the foot can lead to the exposure of critical structures such as tendons, bones, nerves, and vessels. In those cases, the wound should be covered to protect structures and a suitable flap is necessary for proper reconstruction.¹ Local flaps are often inadequate for covering medium to large wounds. The free flaps have been proposed as a solution to cover the wound in this region. However, the use of free flaps has some disadvantages, including needing expert surgeons proficient in microsurgery, high-quality instrumentation, and extended operative durations.¹ Another

option is the sural flap, a popular choice for foot reconstruction. However, Jaiswal et al demonstrated the superiority of the lateral supramalleolar (LSM) flap over the reverse sural flap in covering soft-tissue defects on the dorsum of the foot.² Additionally, the pivot point of the sural flap, located in the lower back calf, may adversely impact the aesthetic outcome of the ankle.³⁻⁵

The retrograde LSM flap, first introduced by Masquelet et al in 1988 to cover soft-tissue defects of the ankle and foot,⁶ is a promising alternative. Valenti et al refined the technique by elevating the subcutaneous pedicle.⁷ Many authors have reported successful outcomes in using

DOI <https://doi.org/10.1055/s-0044-1788991>.
ISSN 0970-0358.

© 2024. Association of Plastic Surgeons of India. All rights reserved. This is an open access article published by Thieme under the terms of the Creative Commons Attribution-NonDerivative-NonCommercial-License, permitting copying and reproduction so long as the original work is given appropriate credit. Contents may not be used for commercial purposes, or adapted, remixed, transformed or built upon. (<https://creativecommons.org/licenses/by-nc-nd/4.0/>)

Thieme Medical and Scientific Publishers Pvt. Ltd., A-12, 2nd Floor, Sector 2, Noida-201301 UP, India

this flap. They used the mixed-blood supply pattern to reconstruct ankle and foot defects.⁸⁻¹⁰ Some studies have also reported a high success rate in using the adipofascial LSM flap in limited sample sizes.^{11,12} Anatomically, the LSM flap receives antegrade blood flow from the peroneal artery (sometimes from the anterior tibial artery) and retrograde blood flow via anastomosis from the anterolateral malleolar artery to the descending branch of the perforating branch of the peroneal artery. Most of the reports were about the antegrade LSM flap, but there was only one report that demonstrated excellent outcomes in using the retrograde LSM flap in covering soft-tissue defects in the foot and ankle.⁹ In this study, the results and clinical experiences in using the retrograde LSM flap to cover larger soft-tissue defects are presented.

Materials and Methods

Study Settings

This study was prospective cross-sectional observational study performed from December 2017 to December 2022. The follow-up time was 6 to 30 months.

Participants

Forty-five patients with 46 retrograde LSM flaps (one patient underwent bilateral foot treatment) were in the study. All the patients had foot and ankle structure exposure, including bones, vessels, tendons, or nerves, within subunits such as the medial malleolus, midfoot, dorsum of the forefoot, and Achilles' tendon. The exclusion criteria consisted of exhibiting clinically significant previous injury in the lateral lower calf and peripheral vascular disease.

Sampling

After the wounds were free from necrotic tissues and local infection, the flap was used. In some challenging cases, debridement was performed, and a vacuum-assisted closure system was applied, with a 5-day interval preceding the application of retrograde LSM flaps (→ Fig. 1).

Measurement

The age, gender, injury etiology, associated injuries, and injury site were recorded preoperatively. The flap and pedicle settings were collected intraoperatively. The technical

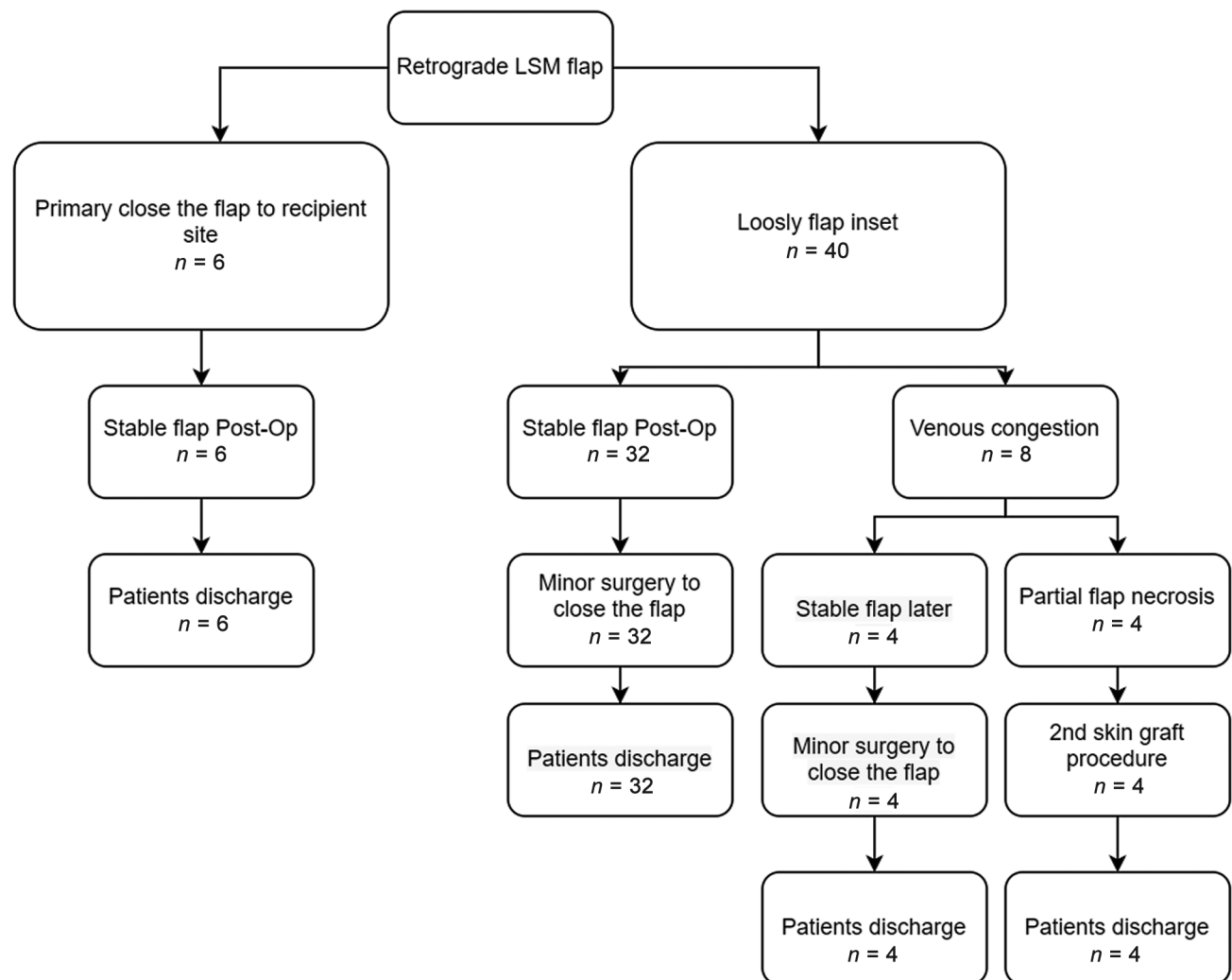


Fig. 1 Algorithmic approach for use of retrograde lateral supramalleolar (LSM) flap.

parameters such as total flap length (measured from the pivot point to the flap's distal edge), flap surface dimensions, wound size, and operation duration were recorded intraoperatively. Surgical complications, encompassing venous congestion, flap failure, and postoperative interventions, were observed within 1 to 7 days postsurgery.

Outcome Assessment

Consistent with previous research, successful outcomes were defined as instances where retrograde LSM flaps survived or exhibited minor complications, not necessitating major surgery repetition. This category included flaps with minor distal edge necrosis necessitating minor surgical interventions such as debridement and secondary suturing, excluding skin graft techniques typically performed in significant operations. Failure outcomes comprised flaps exhibiting partial necrosis necessitating repeat major surgery to ensure optimal outcomes.

Operation Technique

The flap's axis aligns with the leg's central line, positioning the anterior border of the flap at the tibia crest line, while ensuring the posterior limit does not extend beyond the hind of the fibular frontier. The pivotal landmark is identified at the intersection of the line connecting the malleoli and the axis of the fourth metatarsal bone (► Fig. 2). Measurements of the distance from the wound's proximal edge to the pivot point, along with wound dimensions, aid in estimating the

pedicle length. A preliminary flap design is delineated on the lateral aspect of the leg, with the flap's axis serving as a midline parallel to the anterior tibial crest and the posterior margin of the fibula. To facilitate a tension-free inset and pivot arch, 0.5-cm dimensions are added to the flap size and 2 cm to the pedicle length. The flap's dimensions are consistently slightly larger than the wound size to ensure optimal management of complex-shaped defects.

The subcutaneous pedicle, 3 cm in width with 1 cm of skin in the middle serving as a roof, resembles a tent structure. An exploratory incision is initiated at the anterior border of the pedicle, extending up to the subfascial plane, revealing the perforating branch of the peroneal artery on the surface of the interosseous membrane. The descending branch is isolated up to the pivot point, encompassing superficial veins within the pedicle to enhance venous outflow. Following confirmation of the pivot point, the emergence perforator branch of the peroneal artery is meticulously tied and separated under loupe magnification to prevent inadvertent vessel damage. After that, the flap is raised, the superficial peroneal nerve is separated at the distal edge, and the nerve stump is deeply buried under the muscle belly. The flap is then transferred to the recipient site through an incised skin tunnel, with the subcutaneous pedicle spread out to minimize thickening. At the middle of the pedicle, 1 cm of skin was sutured to the tunnel to form a tent roof, so the skin grafting was not used and there was no dog-ear. The flap was sutured loosely to

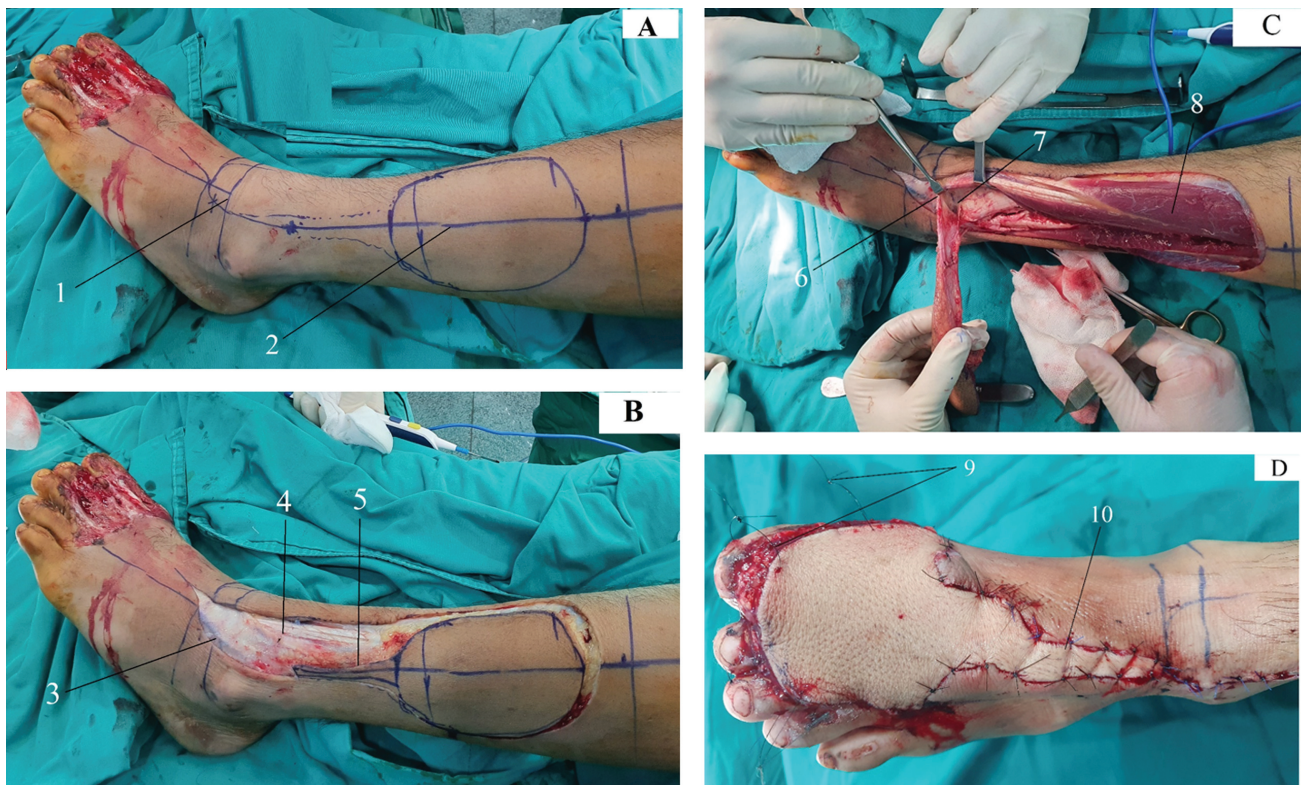


Fig. 2 Flap designing and dissecting. (A) Mapping the provisional flap. (B) First, explore the pedicle vessels. (C) Completely elevating the flap. (D) Suturing the flap to the recipient site.

Table 1 Quantitative data

Variables	Mean	Minimum	Maximum
Age of patient (y)	40.17	15	73
Wound size (cm ²)	37.61	9	80
Flap dimension (cm ²)	48.43	12	104
Total length of flap (cm)	17.47	10	24
Operation time (min)	90.98	60	200

prevent postoperative swelling. The thin skin graft was applied to the donor site. Finally, a careful inspection was made to be sure the pedicle was not under traction. A cast was used to stabilize the ankle to protect the flaps from stress.

Postoperative Follow-Up

Within 8 hours after surgery, the flap color, temperature, and capillary refill were evaluated carefully. Patients and their relatives were instructed to keep the affected limb in an appropriate position to avoid pressure on the pivot point, flap pedicle inset, and recipient site.

After 5 days, the gauze covering the skin graft at the donor site was removed. An additional closure was made, if necessary, with a minor surgery. In this way, the patient was often discharged on the seventh day. In case necrotic flaps are unrecoverable through minor surgical interventions, necrotic tissue is debrided, followed by a skin graft.

Statistical Method

Stata version 14.0 was used for data analysis. Qualitative variables such as causative injury, flap outcome, associated injuries, and leg site were shown by frequency and percentages. Quantitative variables including flap dimension, wound size, patients' age, and surgery time were subjected to analysis using mean or median, as deemed appropriate.

Results

The follow-up time ranged from 6 to 30 months, with a mean of 15.2 months. Forty-six retrograde LSM flaps were used on 45 patients (35 males and 10 females), with an average age of 41.17 years (range: 15–73 years). The mean size of wounds

Table 2 Patient characteristics

Variables	Total (n = 46)	Defect location			
		Forefoot (n = 33)	Midfoot (n = 8)	Heel (n = 3)	Medial malleolus (n = 2)
Gender					
Male	36	26	6	3	1
Female	10	7	2	0	1
Leg site					
Right	30	22	5	2	1
Left	16	11	3	1	1
Cause of injury					
Traffic	39	29	7	2	1
Labor	1	1	0	0	0
Ulcer	3	3	0	0	0
Burn	3	0	1	1	1
Pedicle inset					
Tunneled	12	7	3	0	2
Incised ceiling skin tunnel	34	26	5	3	0
Flap setting					
Primary close suture	6	5	1	0	0
Loosely inset	40	28	7	3	2
Venous congestion					
Yes	9	5	2	2	0
None	37	28	6	1	2
Flap outcomes					
Survival	38	28	6	2	2
Distal edge necrosis	4	2	1	1	0
Partial necrosis	4	3	1	0	0
Post-op intervention					
Skin graft	4	3	1	0	0
None	38	28	6	2	2
Minor surgery	4	2	1	1	0

Table 2 (Continued)

Variables	Total (n = 46)	Defect location			
		Forefoot (n = 33)	Midfoot (n = 8)	Heel (n = 3)	Medial malleolus (n = 2)
Associated injuries					
Phalange amputation	3	3	0	0	0
Medial malleolus fracture	1	0	0	0	1
Tarsal fracture	13	10	3	0	0
None	26	19	4	2	1
Extend skin loss	3	1	1	1	0

was 37.61 cm², while the mean flap dimension was 48.43 cm². The average flap length, measured from the pivot point to the distal edge was 17.47 cm (10–24 cm). The mean operative time was 90.98 minutes (►Table 1).

In this study, two-thirds of soft-tissue defects occurred in the forefoot, accounting for 33 of 46 flaps (71.74%; ►Table 2). Four flaps had partial necrosis, necessitating secondary skin graft procedures. The first case was a 61-year-old patient with a 6 × 11 cm wound in the midfoot, covered by a flap 7 × 12 cm in dimension and 19 cm in total length. Postoperative venous congestion caused partial flap necrosis. The second case was a 29-year-old patient with a 3 × 4 cm forefoot wound. The flap was 4 × 5 cm and 19 cm in total

length. Subsequent venous congestion resulted in partial flap necrosis, requiring a secondary skin graft procedure. Similarly, in the third case, a 50-year-old patient experienced venous congestion and partial flap necrosis following the use of a 6 × 11 cm flap to cover a 6 × 12 cm forefoot defect (►Fig. 3). The last case was a 51-year-old patient with a 5 × 11 cm forefoot wound. The flap was 5.5 × 12 cm. A secondary skin graft was used to cover the wound due to venous congestion and partial flap necrosis.

The overall successful outcome of this study was 91.3% (42 of 46 flaps). Donor site healing proceeded uneventfully following the skin graft procedure, with no evidence of tendon adhesion in any case.

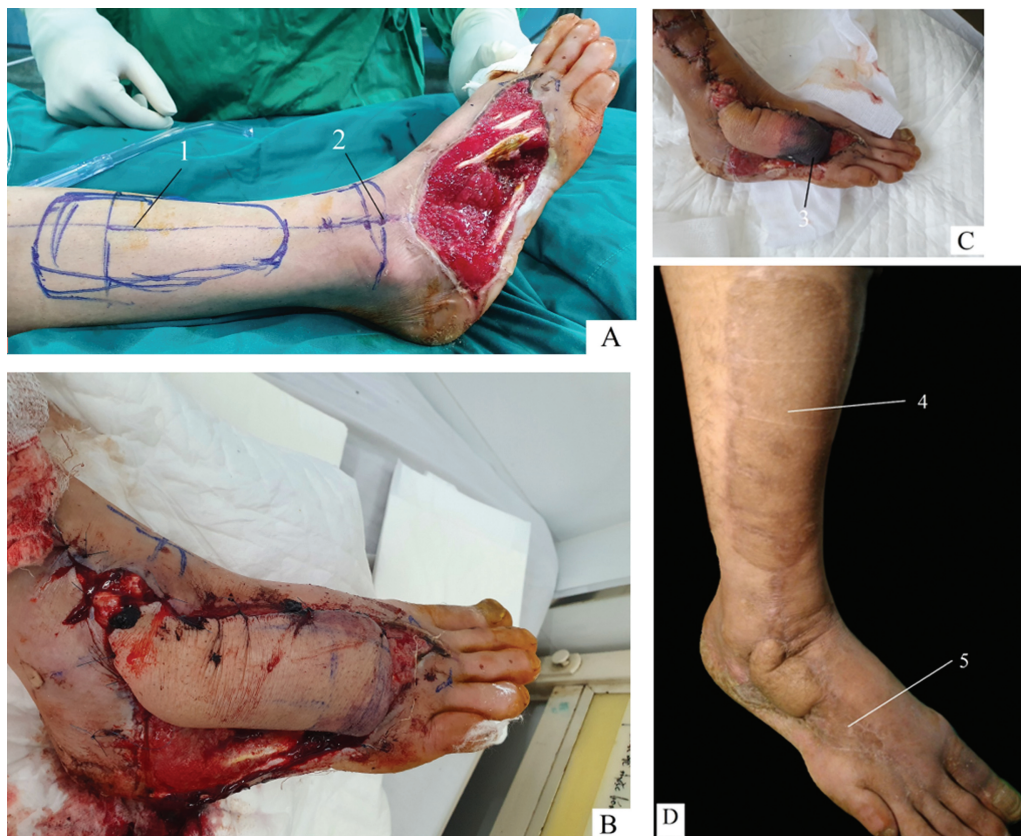

Fig. 3 Third failure case with partial flap necrosis. (A) Wound before surgery. (B) First operative day. (C) Severe venous congestion led to partial flap necrosis. (D) Result after the second skin graft procedure.

Discussion

The standard approach to foot reconstruction should optimize recipient site benefits and minimize donor site morbidity. In cases of severe foot trauma, the choice flap is the flap that can be used to cover the tissue defect, while bone fracture and tendon rupture can be managed simultaneously. Until now, there has been no optimal method for reconstructing foot areas although some techniques were proposed and performed.^{1,5,13} Despite its popularity, the sural flap remains cumbersome for midfoot and forefoot coverage due to its pivot point situated behind the ankle, approximately 2 cm above the lateral malleolus.^{3,4} The dorsal metatarsal artery perforator flap has been recently introduced, but it was used predominantly for forefoot reconstruction.¹⁴ While free flaps offer a viable option for foot reconstruction, they necessitate specialized expertise in microvascular techniques. As an alternative approach, in this study, the retrograde LSM technique was used, and it provided good coverage to soft-tissue defects. The mean wound size and flap dimension were 37.60 and 48.43 cm², respectively. This technique effectively covers soft-tissue defects in various foot subunits, including the forefoot, midfoot, medial malleolar, and heel. Because the retrograde LSM flap starts anterior to the ankle, the distance from it to the regions of the dorsal foot was short. This study had a mean total flap length of 17.46 cm (ranging from 10 to 24 cm); these lengths were chosen so that they were suitable for the wound. In this study, for all cases of the wound settled in the forefoot, the length of the flap reached the wound easily. The surgical procedure took a reasonable time, averaging about 90.98 minutes.

The identification of the surface landmark of the pivot point was very important in flap design and anticipation of flap viability.¹ In this study, the pivot point was at the intersection of the fourth metatarsal bone's axis and the line connecting the two malleoli. This placement, approximately 2 cm higher than the sinus tarsi point as suggested by previous authors, facilitates the preservation of the inferior extensor retinaculum during flap pedicle dissection.^{6,10} Preservation of this retinaculum is crucial for maintaining normal extensor tendon function and preventing the bow-string phenomenon, which may compromise foot function and postoperative aesthetic outcomes. Following the pivot point, the flap lengths can be up to 24 cm, enabling enough coverage of various foot subunits, including the distal margin of the dorsal forefoot.

The retrograde LSM flap, based on this pivot point, had a remarkable versatility. It can be used to cover soft-tissue defects in multiple foot subunits, encompassing the forefoot, midfoot, medial malleolus area, and even the heel region.

For the defects in the midfoot and forefoot, the sural flap had been usually used. However, the sural flap's posteriorly located pivot point necessitates the subcutaneous pedicle to traverse around the ankle to reach the anterior region, thereby compromising aesthetic outcomes in forefoot reconstruction. With a mean length of 17.46 cm, retrograde LSM

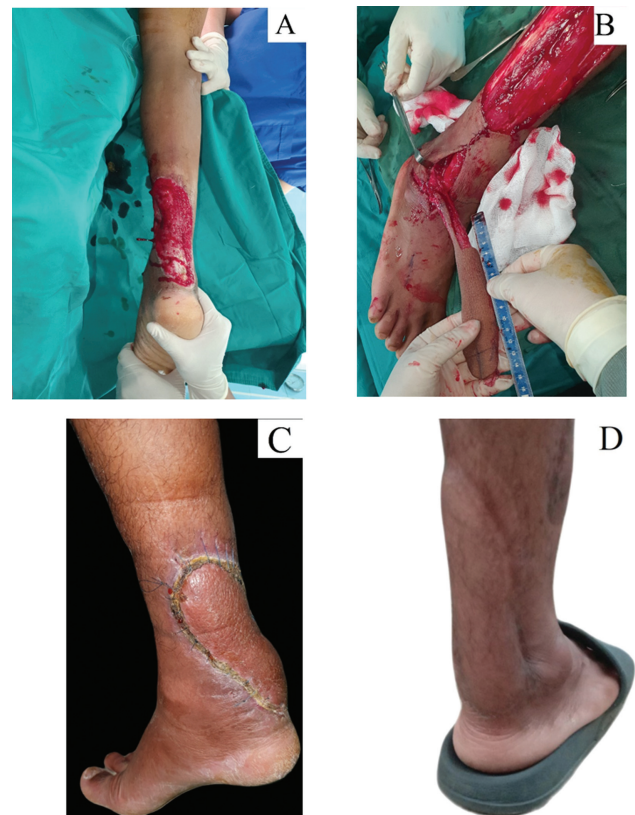

Fig. 4 Heel reconstruction by retrograde lateral supramalleolar (LSM) flap. (A) Wound before operation. (B) Flap dissection. (C) Flap healing in the recipient site 20 days postoperation. (D) At 14 months postoperation.

flaps provide adequate coverage for the midfoot and forefoot without disadvantage. Similarly, the sural flap is primarily utilized for heel reconstruction, but in the cases where the heel defects involve injury of the sural flap's perforators, retrograde LSM flaps serve as reasonable alternative procedures (► Fig. 4). In this study, such cases had excellent results, contrary to prior reports indicating challenges with retrograde LSM flap use in heel reconstruction.⁸ This study showed the potential efficacy of retrograde LSM flaps in heel reconstruction and offered valuable insights for future clinical applications.

Commonly, patients with bone fractures and soft-tissue defects will be repaired with a flap before bone fixation. In this study, a triple malleolus fracture was fixed and a soft-tissue defect was covered with a retrograde LSM flap simultaneously on a patient. The patient was a 37-year-old woman, involved in a traffic accident, and presented with a triple malleolus fracture and a soft-tissue defect at the medial malleolus area. The medial malleolus bone fixation was performed, and a retrograde LSM flap was applied using the same approach utilized for fibular reduction and plate internal fixation. The flap was then transferred to the recipient site through a skin tunnel. The bone was healed and the flap was integrated (► Fig. 5). This case illustrates the feasibility of simultaneously executing the retrograde LSM flap with bone fixation techniques. It gives an approach for patients with foot tissue defects associated with bone fractures involving the medial malleolus, metatarsals, and heel.

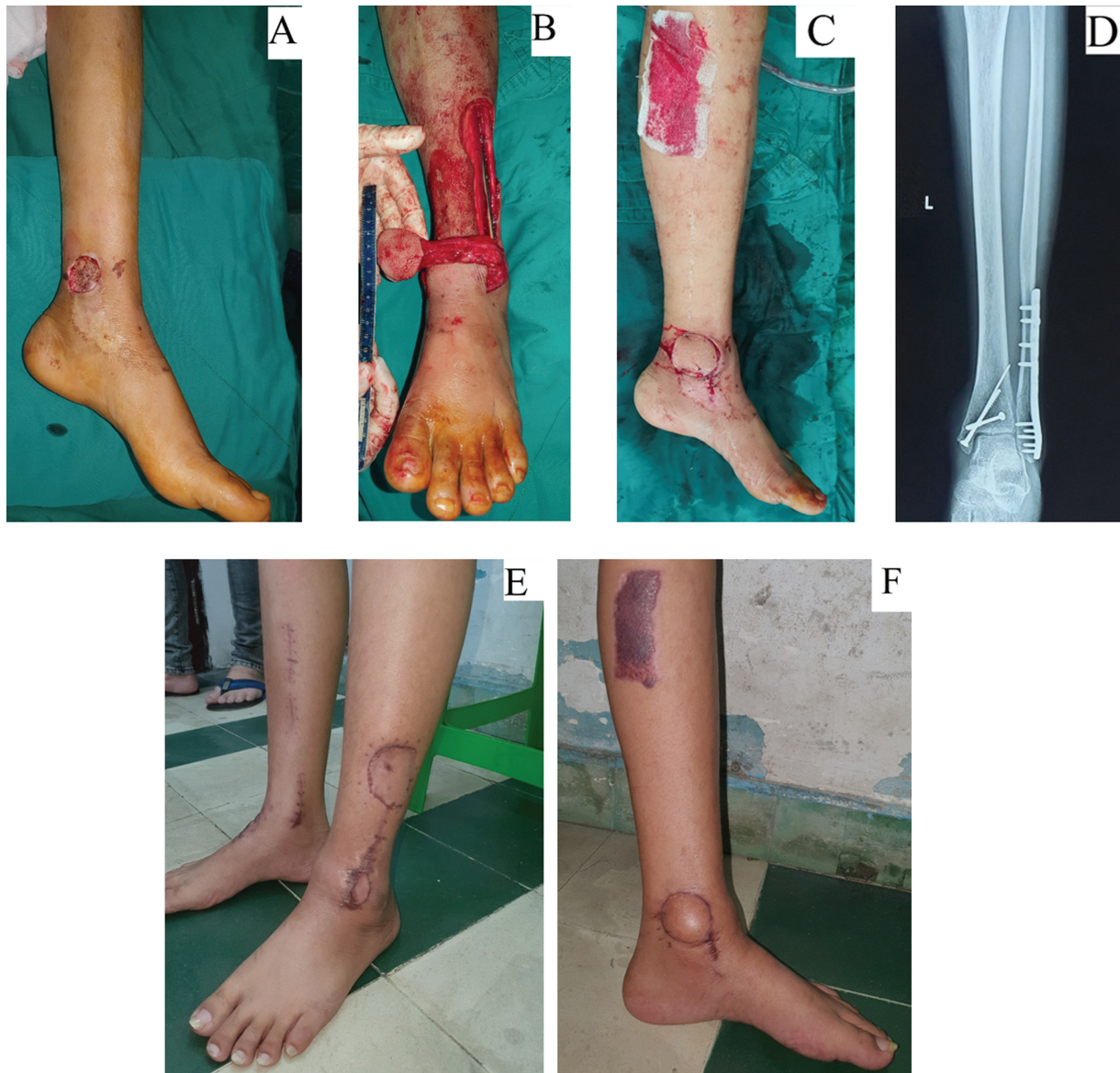

Fig. 5 Combined flap dissection with bone fixation in one procedure. (A) Expose medial malleolus fracture. (B) Bone fixation by plate and flap elevation. (C) Closing the wound by retrograde lateral supramalleolar (LSM) flap. (D) X-ray image of bone fixation. (E) Donor site healing by a skin graft. (F) Flap healing.

Although the overall success rate of the study was high (91.3%), there were failed cases. Two of the failed cases had pedicle tunnel techniques in which long flaps (19 cm in total length) were passed through a tunnel to the recipient site. This tunnel might be small and cause pressure on the pedicle, compromising the blood supply to the flaps. Additionally, maybe the flaps failed because their dimensions were large (66 cm²) and they covered soft-tissue defects far in the forefoot. It was wondered whether using vasodilators, maintaining a warm temperature around the postoperative flaps, and local heparin could help prevent venous congestion, rescue these flaps, and enhance flap survival.

The results of this study show that the LSM flap can be used in retrograde patterns, while previous authors extensively used it in a mixed pattern and smaller-scale studies focused on the retrograde pattern. The results also show that

the retrograde LSM flap can be used successfully for forefoot defects.

This study has some limitations. As a cross-sectional observational study, it lacked a control group for comparative analysis of the method's effectiveness. So it is difficult to determine whether this method is superior to others in covering soft-tissue defects in the foot and ankle region or not. The landmark surface of the pivot point used in the study is subjective. Despite it being exact in every case, it was not linked to any anatomy report. An anatomy study should be performed to find out the best pivot point.

Conclusion

The retrograde LSM flap has several advantages, including the capacity for widening flap dimensions, ease of design and

operation, and reduced technical complexity compared with microsurgery flaps. The flap can be used to cover soft-tissue defects of various foot subunits such as the heel, medial malleolus, midfoot, and especially the dorsal forefoot. It has compatibility with simultaneous bone reduction and internal fixation procedures.

Note

All the authors declare that this manuscript has not been published elsewhere in any languages. This manuscript is free of plagiarisms. All the authors are responsible for the accuracy of the results and methods. Each author has carefully read and approved the final version of this manuscript.

Ethical Approval

Finding a good choice for covering soft-tissue defects in subunits of the foot and ankle is essential to surgeons. In this study, we share our experience using the retrograde LSM flap. The study was performed at The Hospital for Traumatology and Orthopaedics Ho Chi Minh City and The University of Medicine and Pharmacy at Ho Chi Minh City. The University of Medicine and Pharmacy at Ho Chi Minh City approved the ethical issues for this study (280/HĐĐĐ-ĐHYD) following the Helsinki Declaration. All participants signed the informed consent form.

Funding

None.

Conflict of Interest

None declared.

Acknowledgments

The authors thank Lauren Mahyar, Steve Barrie, Hoang Minh The Nguyen, Tu Ngoc Nguyen, Ngan Ngoc Nguyen, and Duy Dinh Do for their help during the study.

References

- Li P, Zhang H, Zhu J, et al. Foot and ankle reconstruction using the lateral supramalleolar flap versus the anterolateral thigh flap in the elderly: a comparative study. *Int Wound J* 2022;19(06):1518–1527
- Jaiswal KS, Gupta S, Goil P, Mohammad A, Gupta P. Empirical evidence on the reliability of lateral supramalleolar flap over reverse sural flap for local soft tissue coverage of dorsum of the foot and ankle defects. *Indian J Plast Surg* 2023;56(02):159–165
- Anlatici R. Reverse sural flap for repair of foot and ankle defects: our cases, modifications, and a literature review. *Plast Surg Case Stud* 2020;6
- Chang SM, Li XH, Gu YD. Distally based perforator sural flaps for foot and ankle reconstruction. *World J Orthop* 2015;6(03):322–330
- Mehmood Hashmi P, Musaddiq A, Hashmi A, Zahid M. Comparison of distally based sural artery and supramalleolar flap for coverage of dorsum of foot and ankle defects; a cross-sectional study of 53 patients. *Ann Med Surg (Lond)* 2021;73:103109
- Masquelet AC, Beveridge J, Romana C, Gerber C. The lateral supramalleolar flap. *Plast Reconstr Surg* 1988;81(01):74–81
- Valenti P, Masquelet AC, Romana C, Nordin JY. Technical refinement of the lateral supramalleolar flap. *Br J Plast Surg* 1991;44(06):459–462
- Nambi GI, Varanambigai TKA. Clinical study of the lateral supramalleolar flap in the soft tissue reconstruction around the ankle region. *Indian J Plast Surg* 2020;53(01):83–89
- Nguyen TN, Trong Mai T, Cao T, Thai TT. Lateral supramalleolar flap for soft-tissue coverage of ankle and foot defects. *J Plast Surg Hand Surg* 2023;57(1–6):459–465
- Voche P, Merle M, Stussi JD. The lateral supramalleolar flap: experience with 41 flaps. *Ann Plast Surg* 2005;54(01):49–54
- Lee JH, Chung DW. Reverse lateral supramalleolar adipofascial flap and skin grafting for one-stage soft tissue reconstruction of foot and ankle joint. *Microsurgery* 2010;30(06):423–429
- Lee YH, Rah SK, Choi SJ, Chung MS, Baek GH. Distally based lateral supramalleolar adipofascial flap for reconstruction of the dorsum of the foot and ankle. *Plast Reconstr Surg* 2004;114(06):1478–1485
- Liu S, Tan J, Tao S, Duan Y, Hu X, Li Z. Reconstruction of a distal foot skin defect using an intermediate dorsal neurocutaneous flap. *Orthop Surg* 2020;12(02):442–449
- van Alphen NA, Laungani AT, Christner JA, Lachman N, Carlsen BT, Saint-Cyr M. The distally based dorsal metatarsal artery perforator flap: vascular study and clinical implications. *J Reconstr Microsurg* 2016;32(04):245–250