



Ultrasound-Assisted Chin Liposuction under Local Anesthesia: An Effective Tool for Facial Slimming in Indian Population

Shruti Marwah¹ Arjun Handa¹

¹ Handa Nursing Home, Raja Garden, New Delhi, India

Indian J Plast Surg

Address for correspondence Dr. Shruti Marwah, M.Ch. Plastic Surgery, Consultant Plastic Surgeon, Handa Nursing Home, 20 Raja Garden, New Delhi 110015, India (e-mail: shrutim150@gmail.com).

Abstract

An aesthetically pleasing neck is an important component of a youthful appearance of the face. It is frequently targeted by many surgical and nonsurgical methods to achieve the best results. Today, patients are looking for a minimally invasive option that gives permanent results and has a quick recovery. Therefore, ultrasound-assisted liposuction of the chin and jawline has become an important part of the cosmetic surgeon's armamentarium. The objective of this article is to describe the technique, mechanism of action, and most common complications and to establish ultrasound-assisted face liposuction under local anesthesia as an effective method to achieve facial slimming especially in the Indian population.

Keywords

- ▶ double chin
- ▶ chin liposuction
- ▶ VASER liposuction

Introduction

An aesthetically pleasing neck is an important component of a youthful facial appearance and is therefore a frequently targeted area for rejuvenation procedures. Today, patients want a minimally invasive option that gives the best results, is permanent, and has a quick recovery. In this article, we report on our experience with 50 patients who underwent ultrasound-assisted liposuction of the chin and jawline area under local anesthesia

Materials and Methods

Fifty patients underwent chin and jawline liposuction under local anesthesia between May 2022 and May 2023 in a hospital setting. Out of these, 44 patients were females and 6 patients were males. The age range of these patients was between 20 and 55 years.

Patients were selected on the basis of examination, which depicted lipodystrophy in the chin and jawline area. Out of 50 patients, 35 depicted minimal/no skin laxity, 5 had

moderate skin laxity, and 10 were in overweight/obese category (body mass index [BMI] > 28) and were looking for overall facial slimming. Patients warranting the need for general anesthesia for additional surgery such as browlift, rhinoplasty, or body liposuction were excluded from this study.

- On the day of the procedure, the patient was admitted, markings were done, and photographs were taken in the front, oblique, and side views (after taking due consent). They were given an injection of 1 g of ceftriaxone (▶ Fig. 1).
- The patient was positioned supine with neck extension and the areas were cleaned and draped.
- Tumescent solution (30 mL of plain 2% lignocaine, 1 mL of adrenaline, 1:1,000 in 1 L Ringer's lactate) was injected via three points, one each behind the chin and both the ears.
- Three tiny incisions were made, one each behind the chin and both ears approximately 2 mm in size, and an infiltration cannula was used to further infiltrate the required

DOI <https://doi.org/10.1055/s-0044-1790199>.
ISSN 0970-0358.

© 2024. Association of Plastic Surgeons of India. All rights reserved. This is an open access article published by Thieme under the terms of the Creative Commons Attribution-NonDerivative-NonCommercial-License, permitting copying and reproduction so long as the original work is given appropriate credit. Contents may not be used for commercial purposes, or adapted, remixed, transformed or built upon. (<https://creativecommons.org/licenses/by-nc-nd/4.0/>)
Thieme Medical and Scientific Publishers Pvt. Ltd., A-12, 2nd Floor, Sector 2, Noida-201301 UP, India

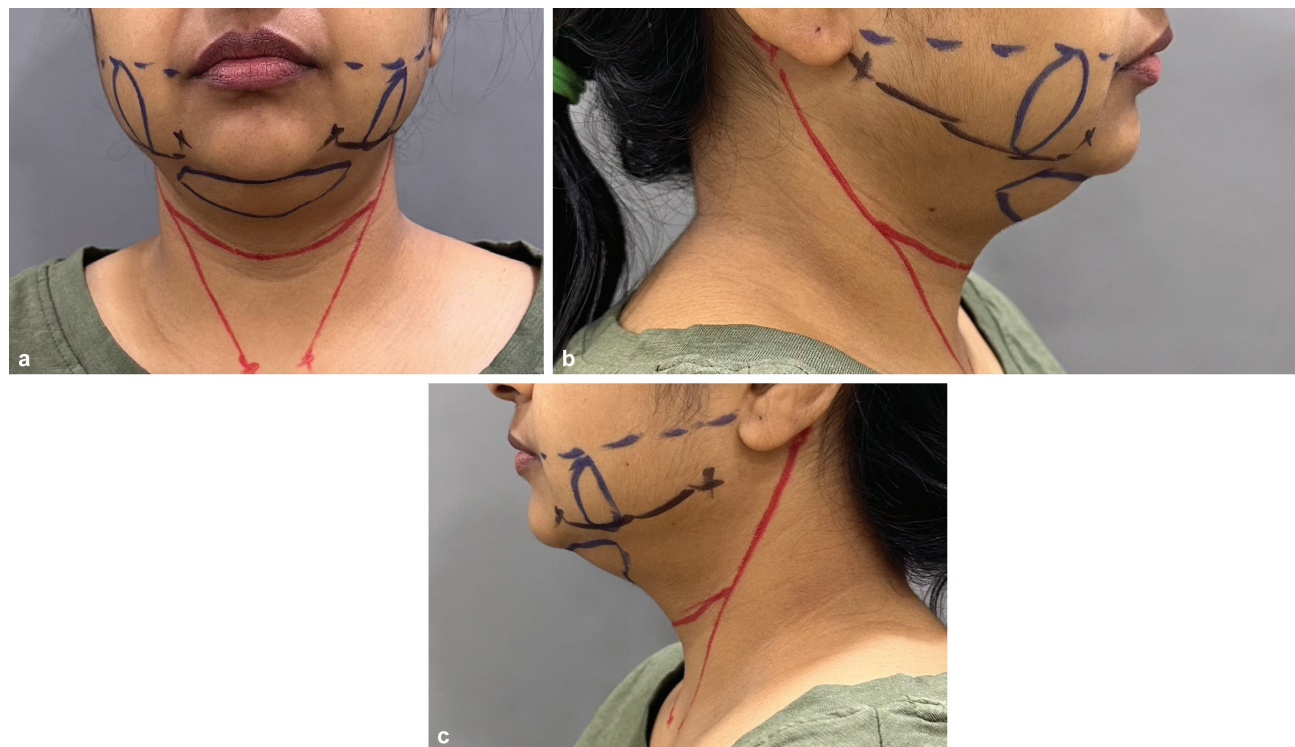


Fig. 1 (a) Front view of markings depicting the anterior border of sternocleidomastoid and superior and inferior extent of the area to be addressed. (b) Right side view of markings depicting the mandibular border, angle of the mandible. (c) Left side view of markings (similar to the right side).

volume, ranging from 150 to 250 mL based on the amount of fat in the supraplatysmal plane.

- VASER (vibration amplification of sound energy at resonance) was used at 20 to 40% setting for 2 to 3 minutes to emulsify the fat (► **Fig. 2**).

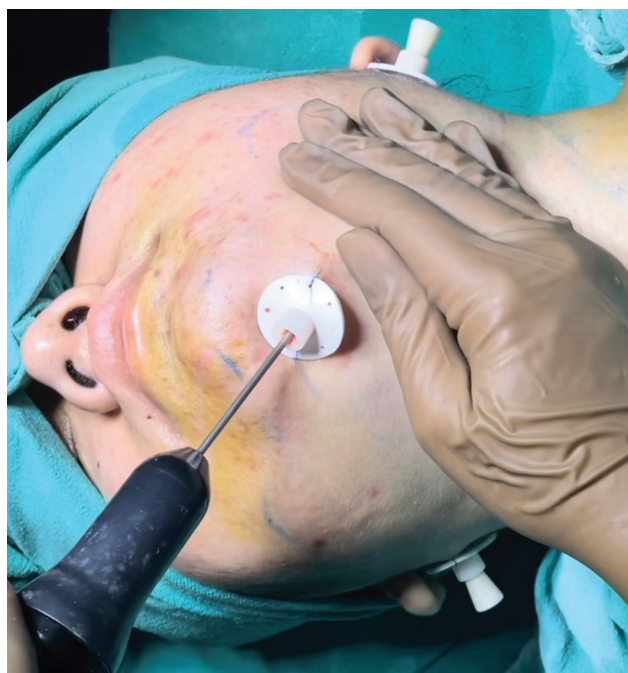

Fig. 2 Intra-op picture depicting VASER (vibration amplification of sound energy at resonance) probe inserted via secure skin ports.

- Fat was aspirated from all three sites in multiple directions, amount ranging from 25 to 150 mL.
- The sites were closed with 5-0 Prolene.
- A chin strap was placed on the table.
- All the patients were awake and conversant during the procedure and participated with positioning throughout. Continuous pulse oximetry and intermittent blood pressure monitoring readings were recorded.

The first follow-up was scheduled at 5 days to assess recovery and stitch removal. The patient was asked to wear the chin strap for 24 hours for 5 days and after that only at night for 2 weeks. The before and after results were assessed at 1, 3, and 6 months after the procedure and finally at 1 year.

The level of evidence is 4, with no randomization.

Results

Thirty-five patients achieved satisfactory results (surgeon's assessment), which were determined in terms of (1) removal of fat and (2) skin tightening (► **Fig. 3**).

Five patients did have residual skin laxity despite achieving overall facial slimming. Out of these, two were post massive weight loss (► **Fig. 4**) and three had some skin laxity prior to the procedure; all had been explained the need of neck lift prior to surgery. Ten patients were in overweight/obese category and while they did achieve a significant difference, further contouring of the neck or weight loss was advised to make the results even better (► **Fig. 5**).

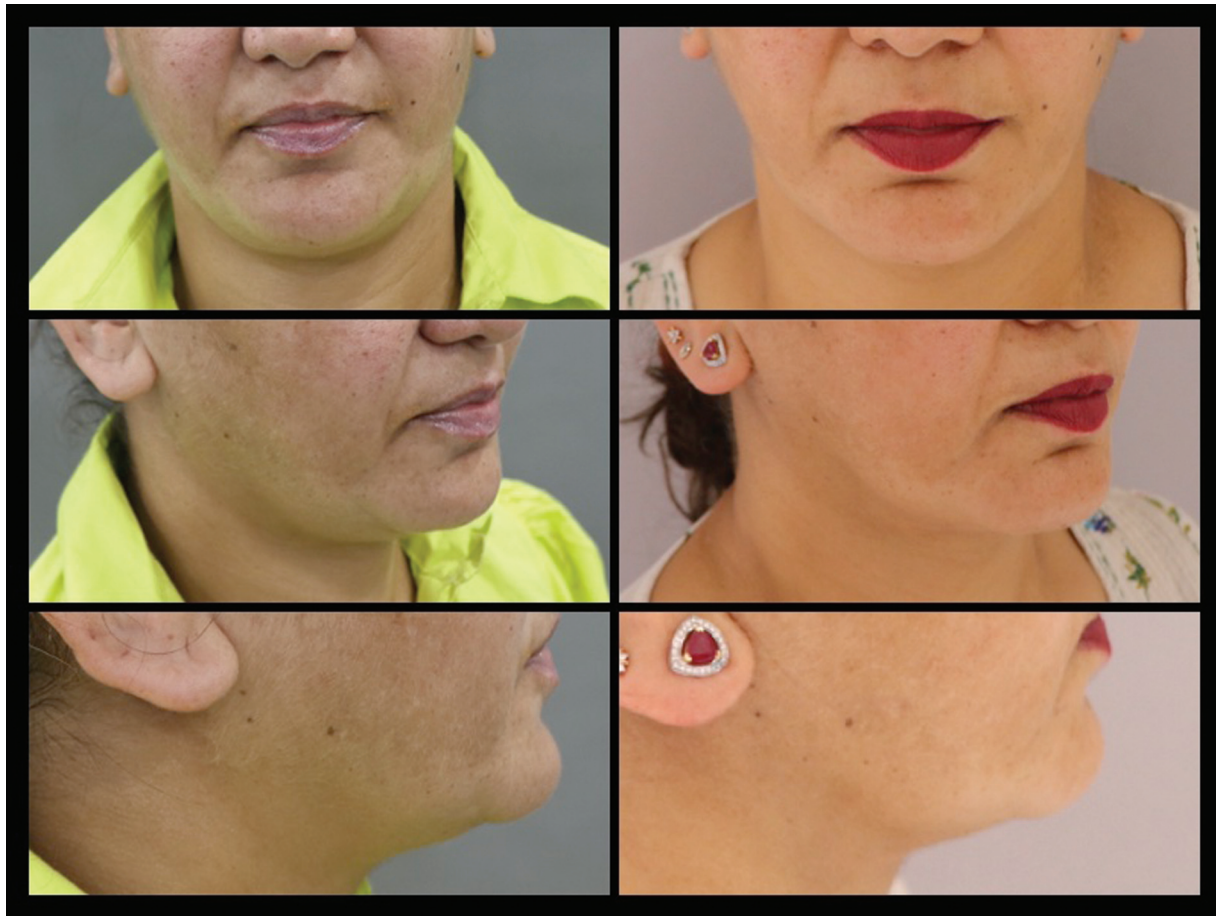

Fig. 3 Before and after pictures at the 6-month follow-up (front, oblique, and side view).

As per the patient satisfaction index (► **Table 1**), responses 1 and 2 were considered overall satisfactory results. Out of 50 patients, 40 responded as 1, 10 as 2, and none as 3 and 4.

The 40 patients included all 35 patients who achieved satisfactory results (according to surgeon), 3 patients from the overweight/obese category, and 2 patients who had some degree of residual laxity. Out of 10 patients who responded as 2, 3 were patients who had some residual laxity and 7 patients were in the overweight/obese category.

Discussion

Deposition of fat in the chin, neck, and jawline is a common problem even in the younger individuals. Signs of aging such as wrinkles, skin laxity, and submental and subplatysmal fat accumulation can lead to an increase of the cervicomental angle (CMA) and blunting of the mandibular border. Ellenbogen and Karlin established five criteria to characterize the youthful, aesthetic neck in their postoperative rhytidectomy patients.¹

Evaluation of the patient seeking neck rejuvenation includes two important factors, the degree of skin laxity and the amount of supraplatysmal fat deposition. Also, the presence of jowls, platysmal bands, subplatysmal fat, and submandibular gland laxity is important in determining the

eligibility of the patient for a stand-alone liposuction procedure.

Once it has been determined that there is minimal to no skin laxity, good skin tone, and lipodystrophy in the chin and jawline area, the patient is ideally considered a good candidate for ultrasound-assisted liposuction. However, we have included patients with excess fat deposition, skin laxity, or those requiring facelift or neck lift (as the ideal treatment) also in this study.

Various techniques have been described in literature. Goodstein reports subdermal suction with the cannula facing “upward,” Samdal describes to keep the opening of the cannula “downward,” and Courtiss starts his treatment with the “opening directed outward,” then turns it “inward” after a single space is formed.²⁻⁴

It is not well established from the literature whether the result is because of the effect of ultrasound energy on skin, the amount of fat removed, the creation of multiple tunnels or a single space, contractile healing of skin, redraping of skin over areas where fat has been removed, or the elasticity of the skin.⁵

Also, it is important that suction at the subdermal level be avoided, because this may cause damage to the subdermal vascular plexus, surface irregularities, pigmentation, and excessive induration.^{6,7}

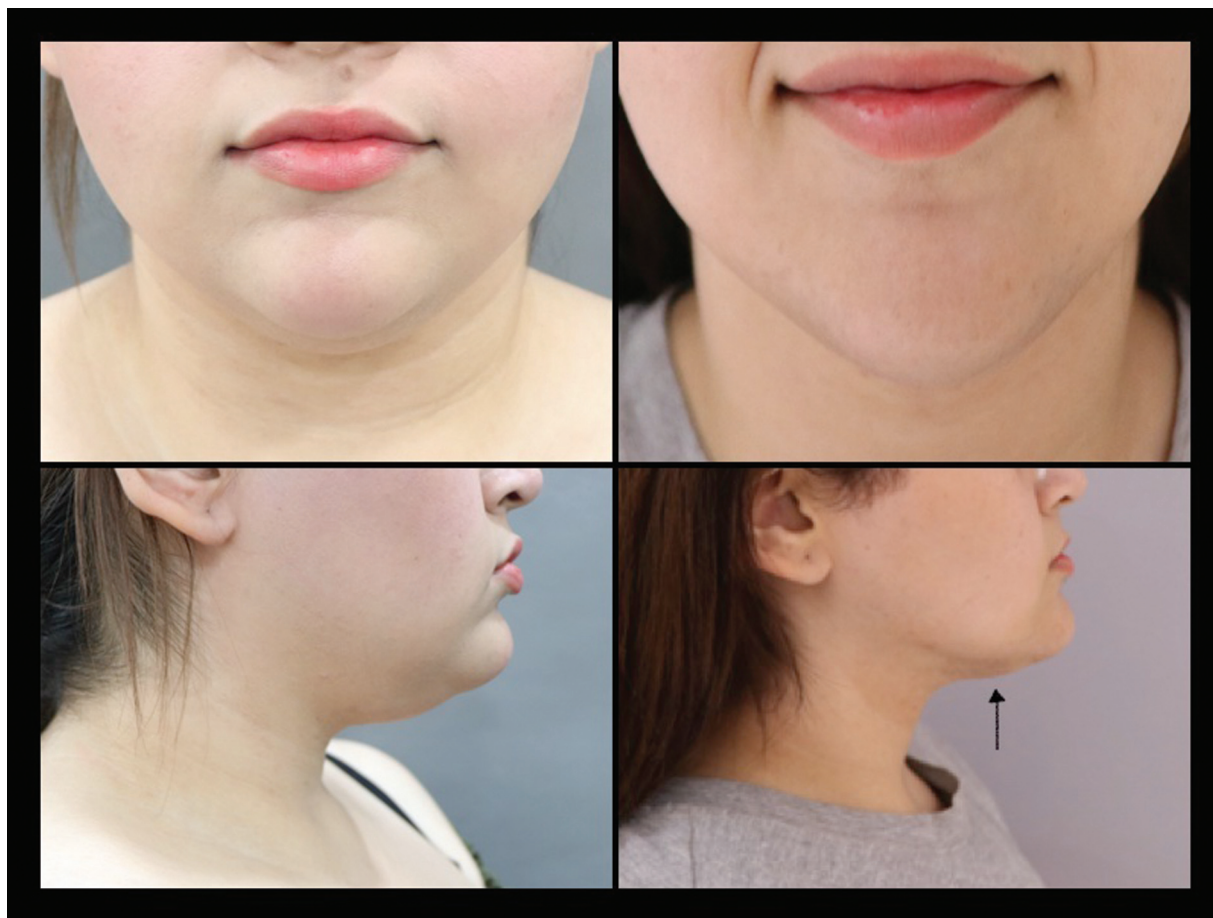

Fig. 4 Postbariatric surgery patient with mild skin laxity (arrow) at the 1-year follow-up with overall satisfactory result.

The most common complications of this procedure include bleeding, hematoma, seroma, hyperpigmentation, infection, paresis of the marginal mandibular nerve, fibrosis, over-resec-

tion, and rarely globus pharyngeus.^{8,9} Two out of 50 patients developed temporary neuropraxia of the marginal mandibular nerve, which got resolved within next 4 to 5 hours. It was attributed to probable seepage of tumescent solution in the subplatysmal plane and it resolved as soon as the effect of anesthetic wore off.

Why the procedure is an effective facial slimming method in the Indian population?

- Out of 50 patients, 15 patients were in a high BMI category (>28), and hence were looking for an effective facial slimming option. All 15 of them despite the requirement of a neck lift refused the surgery due to its longer recovery time and higher risk of complication. Therefore, in the Indian population where people with relatively higher BMI are looking for facial slimming

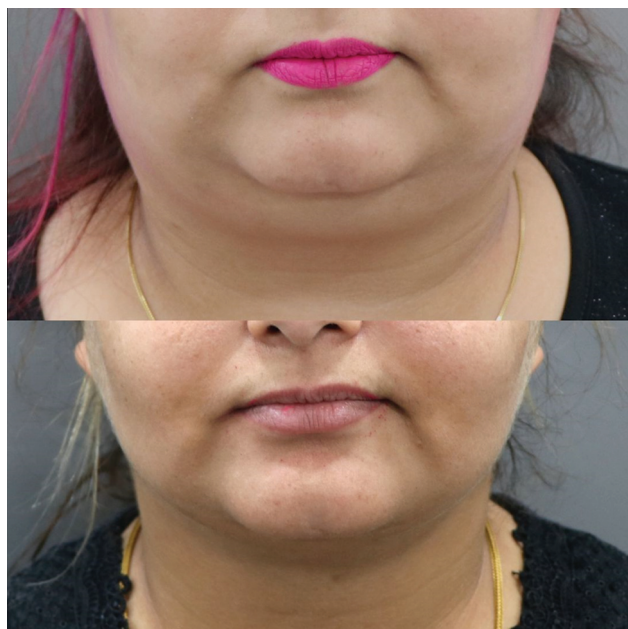

Fig. 5 Facial slimming achieved in a patient with high BMI (35); results at 3 months.

Table 1 Patient satisfaction index

	Patients' responses
1	Surgery met my expectations
2	Surgery improved my condition enough so that I would go through it again for same outcome
3	Surgery helped me but I wouldn't go through it again for the same outcome
4	I am the same or worse compared to before surgery

Table 2 Case reporting in aesthetic medicine (CREAM) guidelines¹⁰

Title	√
Authors	√
Abstract	√
Introduction	√
Patient and practice Information	√
Procedure details	√
Clinical assessment	√
Adverse events	√
Discussion	√
Conclusion	√
References	√
Fundings and Conflict of Interest	√
Informed consent	√
Ethical considerations	√
Acknowledgments	√
Key learning points	√

with no side effects and quicker recovery, ultrasound-assisted liposuction is advantageous.

- As compared to conventional liposuction, ultrasound-assisted liposuction offers faster recovery, lesser chances of complications, lesser swelling, bruising, and less patient discomfort.
- We performed all our procedures under local anesthesia; therefore, the distress of general anesthesia such as postoperative nausea and vomiting was avoided and hence this can be described as a “lunchtime liposuction” procedure.
- It can be effectively combined with buccal fat pad removal under local anesthesia to improve overall results of facial slimming.
- As compared to nonsurgical options, liposuction offers a one-time solution and long-lasting results as long as the patient maintains his or her weight.

Conclusion

In conclusion, we can say that ultrasound-assisted liposuction under local anesthesia is an effective and safe method to achieve facial slimming in carefully selected patients. It is a minimally invasive method that is associated with minimal complications, quick recovery time, and hence is becoming increasingly popular.

Funding

None.

Conflict of Interest

None declared.

References

- 1 Ellenbogen R, Karlin JV. Visual criteria for success in restoring the youthful neck. *Plast Reconstr Surg* 1980;66(06):826–837
- 2 Goodstein WA. Superficial liposculpture of the face and neck. *Plast Reconstr Surg* 1996;98(06):988–996, discussion 997–998
- 3 Samdal F. Treatment of the neck in facial rejuvenation surgery using a simplified method of syringe assisted microlipoextraction. *Scand J Plast Reconstr Surg Hand Surg* 1990;24(03):253–257
- 4 Courtiss EH. Suction lipectomy of the neck. *Plast Reconstr Surg* 1985;76(06):882–889
- 5 Di Giuseppe A. Ultrasound-assisted lipoplasty for face contouring with VASER. In: *Liposuction*. Berlin, Heidelberg: Springer; 2006
- 6 Rohrich RJ, Rios JL, Smith PD, Gutowski KA. Neck rejuvenation revisited. *Plast Reconstr Surg* 2006;118(05):1251–1263
- 7 Teimourian B. Complications associated with suction lipectomy. *Clin Plast Surg* 1989;16(02):385–394
- 8 Butterwick KJ. Liposuction of the neck. In: *Draeos ZD, ed. Cosmetic Dermatology: Products and Procedures*. Hoboken, NJ: Blackwell Publishing; 2010:463–471
- 9 Beeson WH, Slama TG, Beeler RT, Rachel JD, Picerno NA. Group A streptococcal fasciitis after submental tumescent liposuction. *Arch Facial Plast Surg* 2001;3(04):277–279
- 10 Rahman E, Philip-Dormston WG, Webb WR, et al. Developing consensus-based guidelines for case reporting in aesthetic medicine: enhancing transparency and standardization. *Aesthet Surg J Open Forum* 2023;5:ojad076