



# Congenital Umbilical Cord Hernia: Prenatal and Postnatal Management

Stephanie Rodriguez, MD<sup>1</sup>  Daisy Marty, MD<sup>2</sup> Barbara Folga, MD<sup>3</sup> Layan Alrahmani, MD<sup>1</sup>

<sup>1</sup>Department of Maternal Fetal Medicine, Loyola University Medical Center, Maywood, Illinois

<sup>2</sup>Department of Neonatology, Loyola University Medical Center, Maywood, Illinois

<sup>3</sup>Department of Pediatrics, Loyola University Medical Center, Maywood, Illinois

**Address for correspondence** Stephanie Rodriguez, MD, Department of Maternal Fetal Medicine, Loyola University Medical Center, 2160 S 1st Ave., Maywood, IL 60153 (e-mail: rv.stephanie@gmail.com).

AJP Rep 2024;14:e205–e207.

## Abstract

Congenital umbilical cord hernia is often misdiagnosed and easily confused with a small omphalocele. It is different from postnatally diagnosed umbilical hernias and is believed to arise from persistent physiological mid-gut herniation. Its incidence is estimated to be 1 in 5,000, although some articles reported the incidence rate of approximately 0.2%. It is very important to clearly diagnose these cases in the antenatal period so that the patients receive appropriate management postnatally and to decrease the stress in the parents as well. Umbilical cord hernias have not been associated with other chromosomal anomalies.

## Keywords

- ▶ umbilical cord hernia
- ▶ maternal
- ▶ omphalocele
- ▶ ultrasound

In this article, we describe a case of a patient who was diagnosed with an umbilical cord mass for which the course prenatally and postnatally was uncomplicated. It is very important to avoid misdiagnosing these cases, so that patients are appropriately treated in the postnatal course and to prevent complications such as bowel injury during cord clamping.

## Case Presentation

### Prenatal Course

A 29-year-old G3P2002 female was diagnosed at 25 weeks 4 days gestation with an umbilical cord mass measuring 2.5 × 1.9 cm in size.

The patient's past medical history is significant for sickle cell trait and obesity (pregnancy body mass index = 37.8 kg/m<sup>2</sup>). Her past gynecological history includes vaginal herpes and a history of two previous C-sections. The patient's family history is notable for hypertension on her maternal side. She denied any family history of umbilical cord masses or congenital anomalies. Patient's social history was non-contributory. She reports no known drug allergies; the

patient took prenatal vitamins and Valtrex during her pregnancy. Cell-free DNA obtained prenatally was low risk.

On ultrasound, the umbilical cord mass appeared echogenic and heterogeneous and did not appear to disrupt blood flow through the umbilical cord vessels. The mass likewise did not exhibit signs of peristalsis.

The differential diagnosis of this mass included but was not limited to a congenital umbilical cord hernia, cord teratoma, cord angiomyxoma, and cord hemangioma. Follow-up ultrasound examinations were recommended every 4 weeks (▶ **Figs. 1–3**) to further characterize the mass and assess fetal growth; no changes were noted on subsequent imaging. The remainder of the pregnancy was uncomplicated and the baby was delivered via repeat cesarean section at

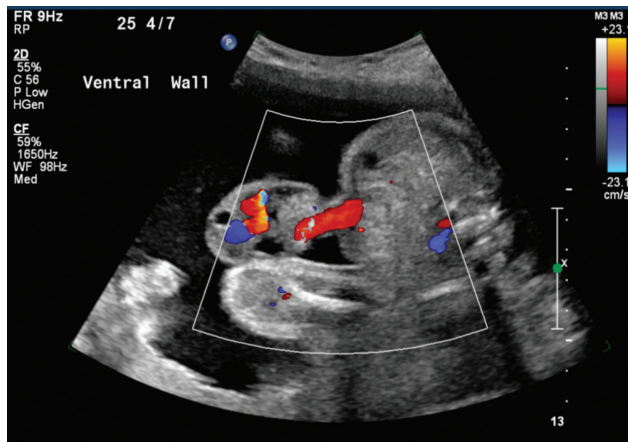
received  
July 6, 2024  
accepted  
August 4, 2024

DOI <https://doi.org/10.1055/s-0044-1790207>.  
ISSN 2157-6998.

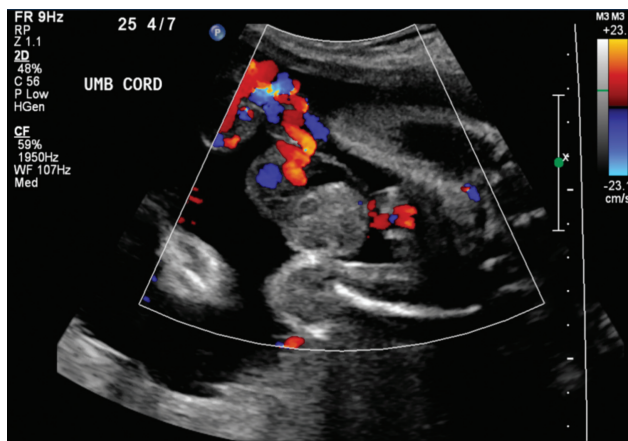
© 2024. The Author(s).

This is an open access article published by Thieme under the terms of the Creative Commons Attribution-NonDerivative-NonCommercial-License, permitting copying and reproduction so long as the original work is given appropriate credit. Contents may not be used for commercial purposes, or adapted, remixed, transformed or built upon. (<https://creativecommons.org/licenses/by-nc-nd/4.0/>)

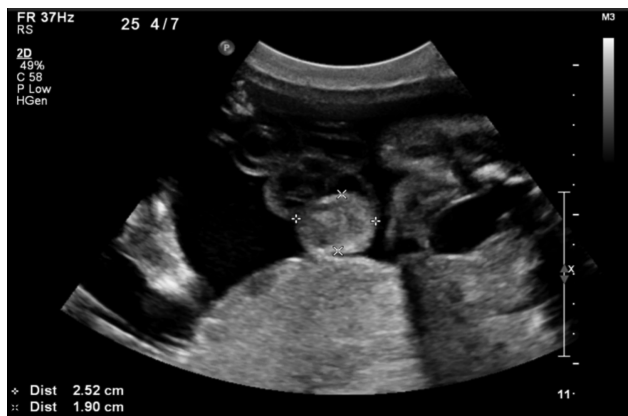Thieme Medical Publishers, Inc., 333 Seventh Avenue, 18th Floor, New York, NY 10001, USA



**Fig. 1** Umbilical cord insertion to the abdominal wall.



**Fig. 2** Free loop of the umbilical cord without interruption of blood flow.



**Fig. 3** Umbilical cord mass measuring 2.5 × 1.9 cm.

term and weighed 3.324 kg. During the procedure, the umbilical cord was cut long to prevent injury to the bowel.

### Postnatal Course

After delivery, the patient was transferred to a tertiary care facility for further management. Once in the neonatal intensive care unit, it was observed that the mass contained loops of

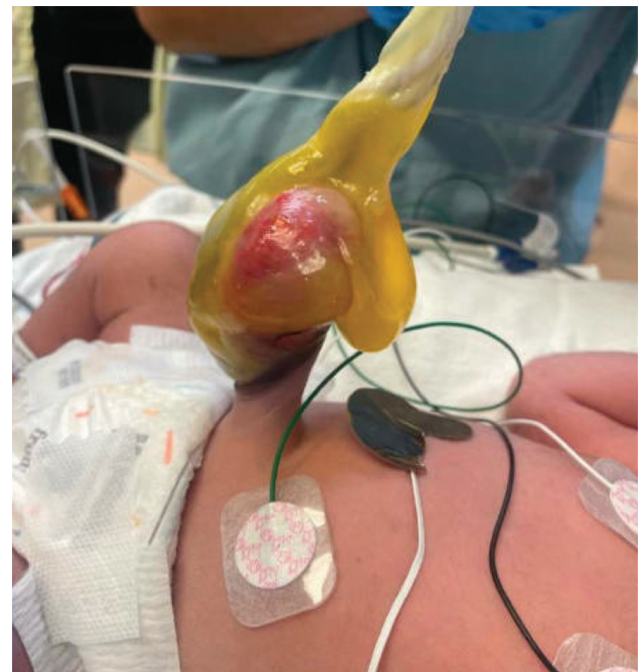bowel and was covered with a transparent membrane, Wharton's jelly. The umbilical stump measured 2.1 cm in size (►**Fig. 4**). After consultation with the pediatric surgical team, the mass was determined to be a congenital umbilical cord hernia. Prior to surgical repair, a workup was initiated to assess for other anomalies, with particular emphasis on midline structures. Abdominal and renal ultrasounds were unremarkable, while a neonatal echocardiogram revealed a large secundum atrial septal defect (ASD). A head ultrasound also showed small echogenic foci in the subependymal regions of the lateral ventricles. After obtaining these results, the patient was scheduled to undergo corrective surgery on day of life 2.

In the operating room, a mini-laparotomy was performed to allow for reduction of hernia contents with primary closure (►**Fig. 5**). Postoperatively, feedings were advanced as tolerated and the patient required total parenteral nutrition for 1 day for additional supplementation.

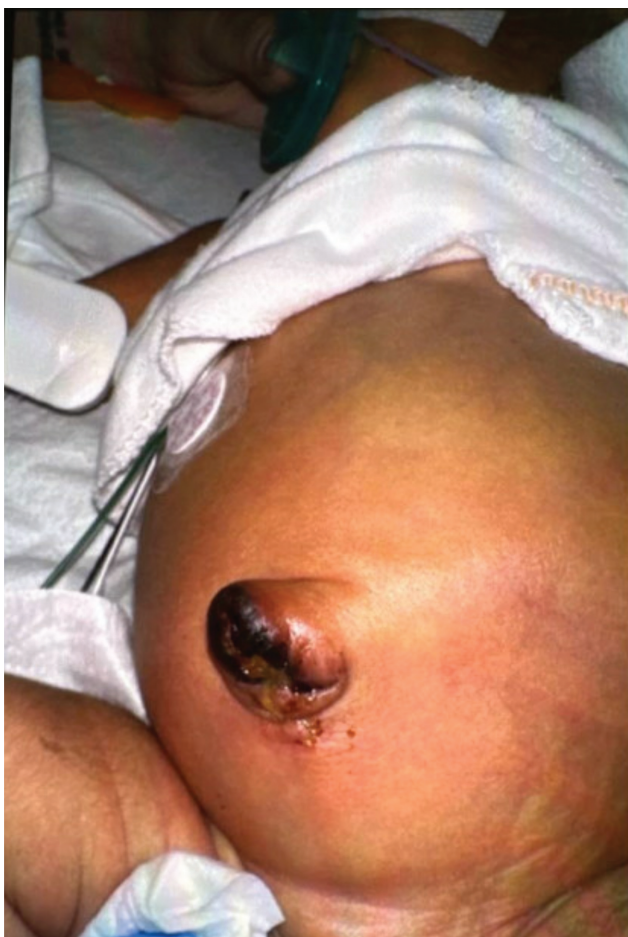Following hospital discharge, the patient and parents were instructed to follow up with the pediatric surgery team postoperatively, repeat the head ultrasound in 1 month's time, and follow up with pediatric cardiology in 6 months' time to monitor progression of the patient's ASD.

### Discussion

A congenital umbilical cord hernia is a rare and incompletely understood phenomenon in which intestinal contents protrude into the umbilical cord secondary to umbilical ring patency.<sup>1</sup> This condition is estimated to occur in 1/5,000 live births and is often misdiagnosed as a small omphalocele. In addition to differentiating these two entities, a congenital umbilical cord hernia should also be distinguished from a postnatally diagnosed umbilical hernia; the former is



**Fig. 4** Intestinal contents protruding through the umbilical cord, with an associated outer membrane.



**Fig. 5** Post-umbilical cord hernia repair and reduction.

postulated to arise from persistent physiological midgut herniation while the latter is due to failure of the fusion of the rectus abdominis muscle at the midline after retraction of physiologic intestinal contents during gestation.<sup>2,3</sup>

We described a patient who was diagnosed with having an umbilical cord mass on prenatal ultrasound at 25 weeks 4 days gestation, with follow-up examinations redemonstrating its presence. The differential diagnosis for umbilical masses is broad and includes omphalocele, umbilical hernia, and umbilical cord hernia. Because of the similarities of these conditions on prenatal ultrasound and on presentation, it is crucial for clinicians to be able to recognize, diagnose, and manage these defects accordingly.

Overall, this case highlights the role of an interdisciplinary team in managing patients with congenital abdominal defects and calls attention to the importance of a proper diagnosis and subsequent treatment plan, with the ultimate goal of preventing complications which would otherwise contribute to morbidity and mortality.

Umbilical cord hernias were first described in the literature by Hempel-Jorgensen in 1929.<sup>4</sup> In the embryonic period, a greater portion of the intestine lies in the proximal part of the umbilical cord. Normally, the intestines withdraw into the abdominal cavity at approximately 11 to 12 weeks of gestation, and the umbilical ring closes. In rare cases, the umbilical ring does not close and in these situations variable portions of the intestines remain in the extracoelomic cavity, which persists as congenital hernia into the umbilical cord.<sup>5</sup>

There exist some anomalies which are associated with congenital umbilical cord hernias; these include congenital short gut, intestinal atresia, ileal atresia, and colonic atresia, presumably a consequence of intrauterine vascular accidents.<sup>6</sup> Fetal demise has been reported, due to rupture of the umbilical cord complicated by in utero bowel evisceration and rupture of umbilical vessels.<sup>7</sup> It is important to obtain a prenatal diagnosis, to prevent any complications in the postnatal period and to decrease the neonatal mortality.

#### Conflict of Interest

None declared.

#### References

- 1 Ghabisha S, Ahmed F, Al-wageeh S, et al. Newborn with hernia umbilical cord: a case report and review of literature. *Open Access Surgery* 2021;14:17–20
- 2 Pal K, Ashri H, Al Wabari A. Congenital hernia of the cord. *Indian J Pediatr* 2009;76(03):319–321
- 3 Conze J, Prescher A, Schlachter M, Schumacher O. The umbilical hernia. *Curr Probl Surg* 2005;27:359–363
- 4 Hempel-Jorgensen P. Familial congenital umbilical hernia. *Ugeskr Laeger* 1929;91:273–274
- 5 Gajdhar M, Kundal VK, Mathur P, Gajdhar M. Pitfalls in the umbilical pit: giant hernia of the umbilical cord. *BMJ Case Rep* 2013;2013:bcr2013009381
- 6 Mirza B, Saleem M. Hernia of umbilical cord with congenital short gut. *J Neonatal Surg* 2014;3(02):26
- 7 Haas J, Achiron R, Barzilay E, Yinon Y, Bilik R, Gilboa Y. Umbilical cord hernias: prenatal diagnosis and natural history. *J Ultrasound Med* 2011;30(12):1629–1632