



# Modified Cranial Closing Wedge Osteotomy (AMA-Based CCWO) to Treat Cranial Cruciate Ligament Deficient Stifle in 204 Dogs Over 50 Kg: Magnitude of the Craniocaudal Angulation of the Proximal Tibia and Rate of Surgical Site Infection

Laurent Guénégo<sup>1</sup> Aldo Vezzoni<sup>2</sup> Luca Vezzoni<sup>2</sup>

<sup>1</sup>Clinique Vétérinaire du Vernet, Le Vernet, France

<sup>2</sup>Clinica Veterinaria Vezzoni, Cremona, Italy

**Address for correspondence** Laurent Guénégo, DVM, Clinique Vétérinaire du Vernet, 366 avenue de Labarthe, 31810 Le Vernet, France (e-mail: laurent.guenego@wanadoo.fr).

Vet Comp Orthop Traumatol

## Abstract

**Objectives** The aim of this retrospective study was to report the magnitude of the craniocaudal angulation of the proximal tibia (CCAPT) quantified by the angle between the anatomical axis (AA) and the mechanical axis (MA), called the AMA angle, and the tibial plateau angle (TPA) in dogs >50 kg that were treated by cranial closing wedge osteotomy based on the AMA angle (AMA-based CCWO). Furthermore, the percentage of dogs in which the AA and MA could be aligned postoperatively and the rate of surgical site infection (SSI) were reported.

**Study Design** Medical records (between January 2016 and September 2023) were reviewed for 204 dogs that had AMA-based CCWO stabilized with a double locking plate (DLP) fixation with or without joint exploration plus a Robert Jones bandage (RJB) and were given postoperative antibiotics.

**Results** The median (range) preoperative AMA angle and TPA were 3.1° (0–5.1°) and 30° (22–49.6°), respectively, and the postoperative AMA angle and TPA were 0° (–2.4 to 1.6°) and 9.2° (4–15°), respectively. The AA and MA were aligned in 82% of dogs. Grade 4 healing occurred in all osteotomies by 8 weeks postoperatively. Except for one dog, no SSIs were recorded.

**Conclusion** Concerning the magnitude of CCAPT in dogs >50 kg and the low SSI rate, AMA-based CCWO stabilized with a DLP fixation plus an RJB and postoperative antibiotics should be considered for treating cranial cruciate ligament-deficient stifles in this subset of dogs.

## Keywords

- ▶ cranial closing wedge osteotomy
- ▶ tibial plateau leveling osteotomy
- ▶ surgical site infection
- ▶ cranial cruciate ligament rupture
- ▶ dogs

## Introduction

Cranial cruciate ligament rupture (CCLR) is one of the major causes of lameness in dogs, leading to the development of

progressive osteoarthritis and stifle joint loss of function.<sup>1–3</sup> Stifle instability following CCLR is an important pathophysiological mechanism that can be addressed with various biomechanical techniques involving proximal tibial

received

December 1, 2023

accepted after revision

August 14, 2024

DOI <https://doi.org/>

10.1055/s-0044-1790511.

ISSN 0932-0814.

© 2024. The Author(s).

This is an open access article published by Thieme under the terms of the Creative Commons Attribution-NonDerivative-NonCommercial-License, permitting copying and reproduction so long as the original work is given appropriate credit. Contents may not be used for commercial purposes, or adapted, remixed, transformed or built upon. (<https://creativecommons.org/licenses/by-nc-nd/4.0/>)

Georg Thieme Verlag KG, Rüdigerstraße 14, 70469 Stuttgart, Germany

osteotomy. Tibial plateau leveling osteotomy (TPLO),<sup>3,4</sup> CORA-based leveling osteotomy (CBLO),<sup>5</sup> and modified cranial closing wedge osteotomy (mCCWO)<sup>6–12</sup> are the most frequently performed surgical procedures to decrease the tibial plateau angle (TPA) with the aim of neutralizing the cranial tibial thrust.

The magnitude of the craniocaudal angulation of the proximal tibia (CCAPT) is quantified by the angle between the anatomical axis (AA) and the mechanical axis (MA), also referred to as the AMA angle, and has been recognized<sup>13,14</sup> as a predisposing factor in the development of CCLR. Indeed, a recent study in which Labrador retrievers and Golden retrievers with and without CCLR were compared found that an AMA angle equal to or greater than 2.4° was predictive of CCLR with both a sensitivity and specificity of 0.95 and was a more accurate predictor than the TPA.<sup>14</sup> This has been confirmed in recent studies.<sup>14,15</sup> Thus, it has been proposed that the AMA angle should be considered with the TPA when a tibial plateau slope (TPS) alteration procedure must be performed, especially in dogs with a TPA >30°.<sup>16</sup>

AMA-based CCWO (cranial closing wedge osteotomy), a modified version of traditional CCWO, involves accurately placing the cranial wedge such that the AA and MA are superimposed following the osteotomy, after the TPS has been decreased and the desired TPA is obtained.<sup>12,16</sup> A recent study of TPLO and AMA-based CCWO in dogs with a TPA >30° compared with healthy Labradors found that mCCWO allows for better correction of the CCAPT, which is often associated with deficient stifles in this subset of dogs, and postoperative modification of the anatomy of the tibia to resemble unaffected dogs.<sup>16</sup>

Although several studies have investigated surgical treatment for proximal tibial osteotomies, very few have been performed in dogs >50 kg.<sup>17–21</sup> Furthermore, these studies do not consider the preoperative TPA or the magnitude of the CCAPT. Thus, it is difficult for surgeons to decide on the most suitable technique for treating CCLR in giant-breed dogs. In addition, body weight and a TPA >30° are risk factors for developing complications following proximal tibial osteotomy.<sup>22,23</sup> Recent studies of dogs >50 kg treated by TPLO have reported an incidence of major complications following surgery ranging from 19.8<sup>18</sup> to 45.8%<sup>21</sup> with surgical site infection (SSI) being the single most common major complication (reported incidence of 9.1,<sup>19</sup> 21.3,<sup>17</sup> 25.9,<sup>18</sup> 32.7,<sup>20</sup> and 37.5%<sup>21</sup> in the available literature), with more than 60% of SSI occurring during the first 15 days postoperatively.<sup>6,17,19</sup> Several studies indicate that the SSI rate decreases with the use of locking plates and postoperative antibiotic therapy.<sup>17,22–26</sup> Major complications such as SSI are particularly concerning due to their associated patient morbidity, economic impact, and higher incidence in dogs >50 kg.<sup>26</sup>

The objectives of our study were to document the preoperative AMA angle and TPA of a large case series of dogs weighing >50 kg with CCLR and to determine the proportion of dogs in which the anatomic and mechanical axes are aligned post-osteotomy. We hypothesized that most dogs >50 kg would have a preoperative AMA angle >2.4° that would be reduced to 0° postoperatively with the AMA-based

CCWO procedure. Rates of SSI in this subset of dogs are reported.

## Materials and Methods

### Data Collection

Clinical records of dogs >50 kg that underwent AMA-based CCWO procedures between January 2016 and September 2023 at the Vernet Veterinary Clinic, Le Vernet, France were retrospectively evaluated. To meet the inclusion criteria, patients should be affected by partial or complete unilateral naturally occurring CCLR and no evidence of any other concurrent stifle pathology upon physical and radiographic examinations. These dogs should have a complete set of medical records and radiographs taken preoperatively and at the 2-month follow-up plus a follow-up of at least 1 year postoperatively either at the clinic or if the owner could not return to the clinic they were contacted by phone. The following information was recorded: breed, sex, weight, side of the limb affected, and type of implant used.

Dogs were divided into a group that received a medial miniarthrotomy and a group that did not undergo joint inspection.<sup>27</sup>

The presence or absence of an SSI was recorded based on criteria adapted from the United States Centers for Disease Control and Prevention guidelines for classifying SSI and that were modified to include a minimum of 1 year of follow-up, which is consistent with previous studies assessing SSI following surgeries to treat CCLR in dogs.<sup>17,18,28–32</sup>

Dogs that presented a contralateral CCLR during the study had data from only the initial procedure included to ensure independence of the statistical analysis.

### Radiographic Measurements

The AMA angle and TPA were measured preoperatively and postoperatively as previously described.<sup>4,13,15</sup> The tibial long-axis shift (TLAS) was defined by an AMA angle that became negative when the AA shifted caudally to the MA postoperatively.<sup>16</sup> The population of dogs was subdivided into three groups according to the magnitude of the CCAPT with an AMA angle below or above 2.4°, beyond which the conformation of the proximal tibia has been shown to be a factor that increases the risk of CCLR.<sup>13,14</sup> Group 1 was defined as normal or minimal CCAPT, with an AMA angle ranging between 0° and 2.4°; dogs in group 2 had an abnormal CCAPT, with an AMA ranging between 2.4° and 3.4°; and dogs in group 3 had a hyper-CCAPT, with an AMA angle >3.4°.

### Follow-Up

At 2 months postoperatively, patellar ligament thickening and osteotomy healing were assessed. Patellar ligament thickening was graded using a 6-point scoring system as previously described.<sup>16,33,34</sup> Subjective grading of osteotomy healing was based on a 5-point scale, as previously described.<sup>29</sup> SSIs were assigned retrospectively into three categories of postoperative time frames: short term (0–2 months), mid-term (>2 to 1 year), and long term (>1 year).<sup>19,21</sup>

## Surgical Procedure

### Radiographic Planning

The CWO (closing wedge osteotomy) angle was defined by the magnitude of the angle ( $CWO = TPA \times 0.65$ ) and was equal to the angle of rotation angulation (ARA) between the AA and the MA.<sup>12,16</sup>

The desired target TPA (TPAd) was based on the preoperative TPA as follows:  $TPAd = TPA - 0.65 \times TPA$ .

A recent study described an elimination of 65% of the TPA, which is similar to the magnitude of correction of the TPA with the CBLO procedure.<sup>5,16</sup>

Two subgroups were defined on radiographs as a function of the availability to obtain a CWO angle that is exactly equal to the ARA, thus allowing perfect alignment of the AA and the MA postoperatively.

In subgroup 1 (AMA angle  $> 2.4^\circ$ ), the distal osteotomy was perpendicular to the AA, and the proximal osteotomy was perpendicular to the axis of rotation between the AA and the MA with the apex of the wedge at the caudal insertion of the medial collateral ligament (**► Fig. 1A**).

In subgroup 2 (AMA angle  $< 2.4^\circ$ ), the wedge was placed at the middle-distal end of the tibial crest with the distal

osteotomy perpendicular to the AA and the apex of the wedge at the caudal insertion of the medial collateral ligament (**► Fig. 1B**).

### Anesthesia Procedure

All dogs were premedicated with acepromazine (0.05 mg/kg subcutaneous [SC]) and morphine (0.2 mg/kg SC) 20 to 30 minutes before anesthesia induction. General anesthesia was induced with propofol (4–6 mg/kg intravenously [IV]), and isoflurane was maintained in 100% oxygen. When required, perioperative analgesia was completed with morphine 0.1 mg/kg IV. Isotonic saline was intravenously infused (5–10 mL/kg/h) before, during, and 12 hours after surgery.

Amoxicillin-clavulanate (20 mg/kg IV) was administered perioperatively and repeated every 90 minutes during the surgery.

### Surgical Technique

All dogs were positioned in lateral recumbency with the affected limb adjacent to the table.

A standard medial approach to the stifle and proximal tibia was made, and a craniomedial miniarthrotomy was performed in the first group.

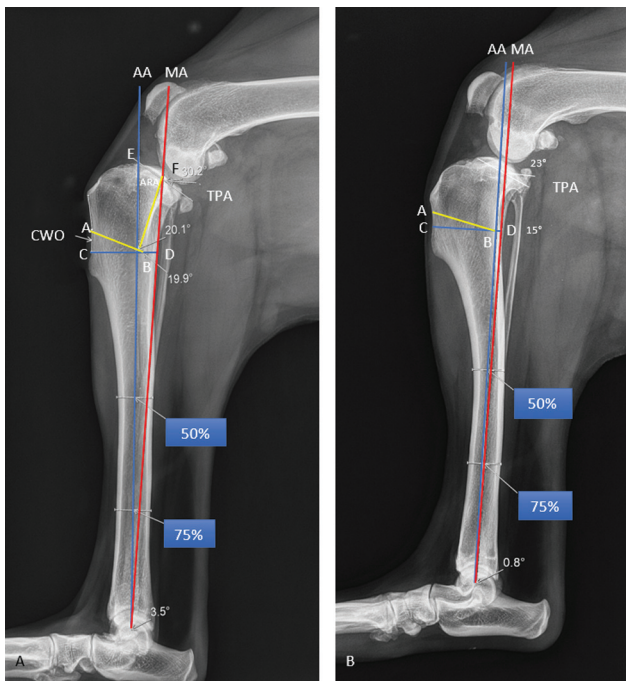
Caudal and lateral subperiosteal elevation and placement of moistened gauze swabs were applied before osteotomy was performed with an oscillating sagittal saw (Acculan, Aesculap, B. Braun, Sempach, Switzerland). The apex of the wedge was located at the caudal insertion of the medial collateral ligament. The medial fascia distal to the osteotomy was elevated from the length of the distal half of the plate, and the stem of the locking 3.5 mm broad TPLO plate was slid underneath. Just distal to the plate, a reduction forceps was applied perpendicular to the long axis of the tibia (perpendicular to the surgery table) with jaws on the cranial and caudal tibial cortex. The osteotomy was reduced using large fragment forceps inserted into the nonarticular cranial aspect of the stifle joint, and the second point was hooked behind the cranial jaw of the reduction forceps (forceps were parallel to the surgery table; **► Fig. 2**).

The cranial cortices of the tibial crest were aligned while closing the wedge. The cancellous bone inside the wedge was removed and packed on the caudal aspect of the tibia at the level of the osteotomy. Routine layered closure was performed after lavage.

Three groups of double plating constructs were used, each of them using 3.5 mm broad TPLO Synthes locking plates (Synthes TPLO plate, DePuy Synthes Vet, West Chester, Pennsylvania, United States; **► Fig. 3**). Grossly, the strongest possible double locking plate (DLP) construct was used, determined as a function of the weight of the dog and the width of the proximal tibia; a 3.5 mm cranial locking compression plate, 3 holes, 4 holes, and 5 or more holes were used in constructs 1 (50–60 kg), 2 (60–70 kg), and 3 (>70 kg), respectively.

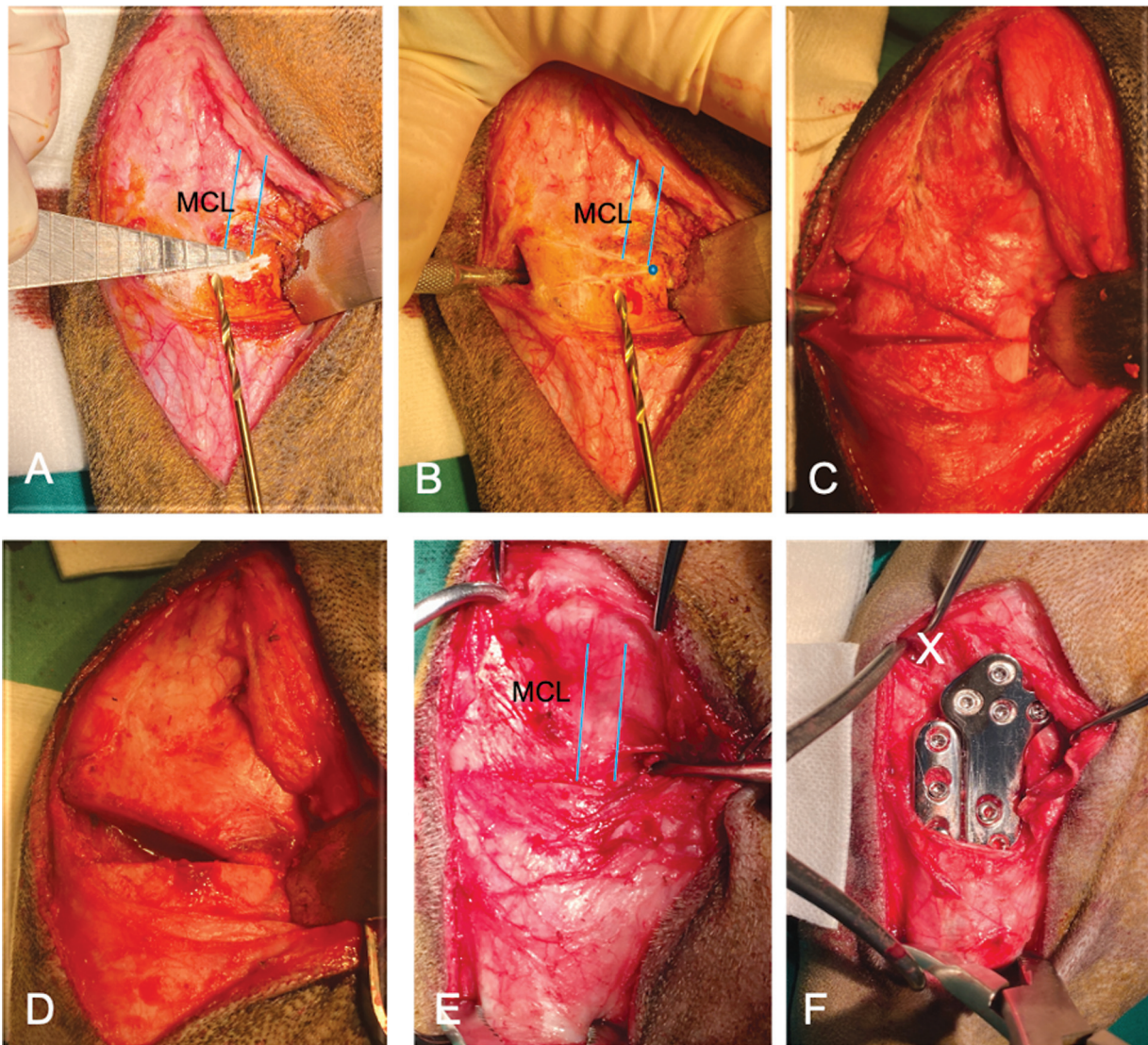
### Postoperative Care

A Robert Jones bandage (RJB)<sup>30</sup> was applied immediately postoperatively by the same four veterinary surgical nurses



**Fig. 1** Mediolateral radiographic views of two stifle joints showing the radiographic planning of AMA-based CCWO in two subgroups. (A) In subgroup 1 (AMA angle  $> 2.4^\circ$ ), the CWO angle (A–B–C) is equal to the ARA (E–B–F). Distal osteotomy (C–D) is perpendicular to the AA, and proximal osteotomy (A–B) is perpendicular to the axis of rotation (B–F) between the AA and the MA and with the apex of wedge (B) at the caudodistal insertion of the medial collateral ligament. (B) In subgroup 2 (AMA angle  $< 2.4^\circ$ ), the wedge (A–B–C) is placed at the middle-distal end of the tibial crest with the distal osteotomy (C–D) perpendicular to the AA and with the apex of wedge (B) at the caudodistal insertion of the medial collateral ligament.: AMA angle, the angle between the anatomical axis (AA) and the mechanical axis (MA); ARA, angle of rotation angulation; CWO, cranial closing wedge osteotomy; CCWO, cranial closing wedge osteotomy.





**Fig. 2** Intraoperative photographs showing the surgical steps of the AMA-based CCWO technique. Image (A) shows the appropriate size of a stainless-steel wedge (wedge osteotomy gauge set; Veterinary instrumentation, Sheffield, United Kingdom) and placement so that the distal border of the wedge is perpendicular to the AA materialized with the 2.5 mm drill bit. Image (B) shows the proximal and distal osteotomy line of the wedge marked on the bone with the apex of the wedge (blue point) at the caudodistal part of the MCL. Blue lines define the cranial and caudal borders of the MCL. Images (C) and (D) show the final osteotomy of the wedge and its retrieval. Images (E) and (F) show that the medial fascia distal to the osteotomy was elevated from the length of the distal half of the plate, and that the stem of the locking 3.5 mm broad TPLO plate was slid underneath. Just distal to the plate, a reduction forceps was applied perpendicular to the long axis of the tibia (perpendicular to the surgery table) with jaws on the cranial and caudal tibial cortex. The osteotomy was reduced using large fragment forceps inserted into the nonarticular cranial aspect of the stifle joint (denoted by "X" on the image), and the second point was hooked behind the cranial jaw of the reduction forceps (forceps were parallel to the surgery table). The cranial cortices of the tibial crest were aligned while closing the wedge. AMA, the angle between the anatomical axis (AA) and the mechanical axis (MA); CCWO, cranial closing wedge osteotomy; MCL, medial collateral ligament; TPLO, tibial plateau levelling osteotomy.

and maintained for 15 days. Dogs were discharged 24 hours after surgery with instructions for the administration of an oral nonsteroidal anti-inflammatory drug at a recommended dose for 15 days. Amoxicillin-clavulanate (12.5–25 mg/kg) was administered orally twice daily for 10 days. Skin sutures were removed after 15 days.

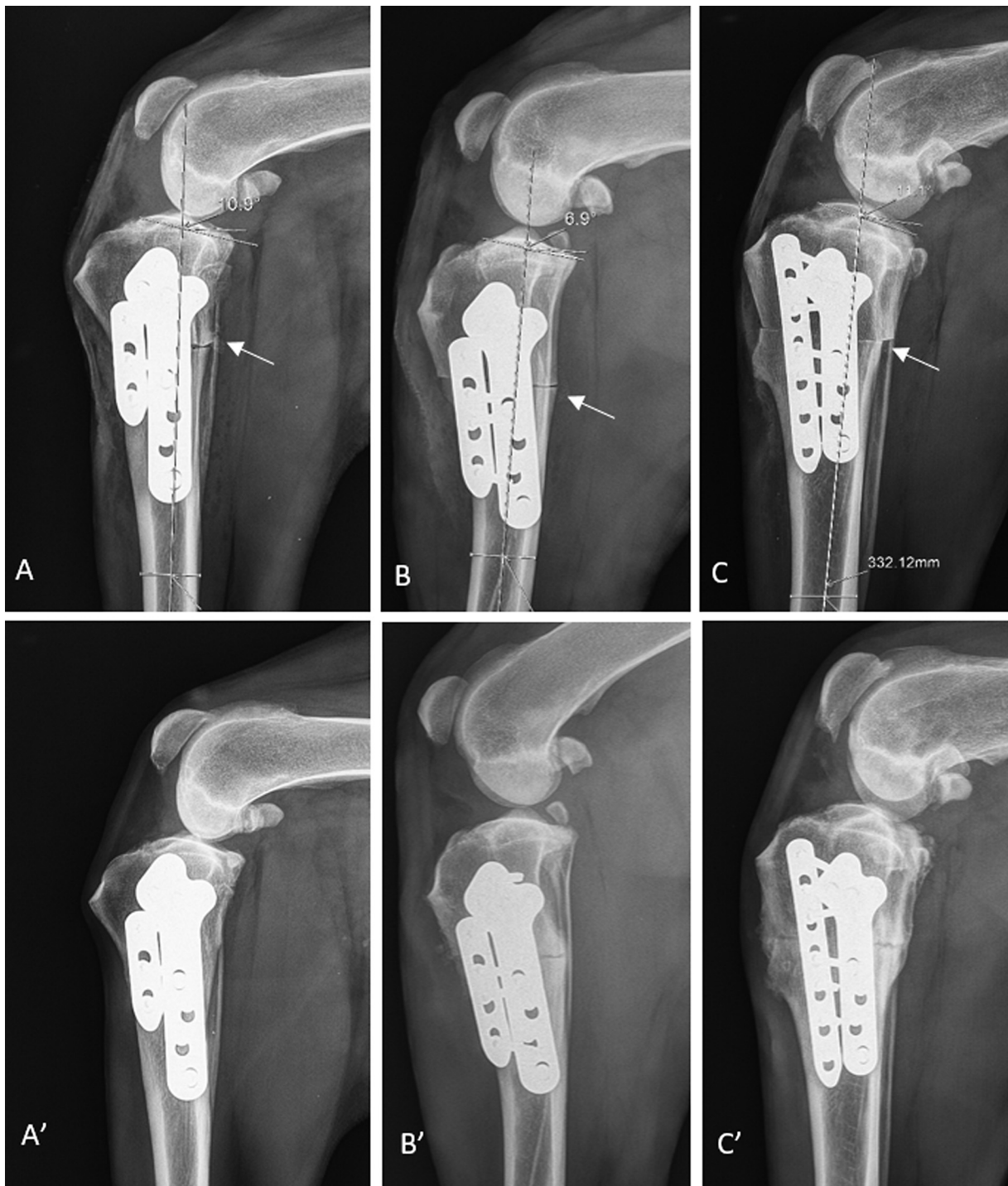
### Statistical Analysis

The normality of distributions was evaluated using the Shapiro-Wilk test. Since the data were not normally distributed, all the results are reported as the medians (min–max).

The statistical analysis was performed using a nonparametric approach in which comparisons across groups, with or without joint inspection, were made using the Mann–Whitney–Wilcoxon test. All statistical analyses were performed using XLSTAT 2018.1.49320 Addinsoft software. The significance threshold for all statistical tests was set at  $p < 0.05$ .

### Results

A total of 204 dogs were included in this study. The median (range) age, weight, sex, preoperative AMA angle, and TPA of



**Fig. 3** Mediolateral radiographic views of the stifle joints showing the three double plating constructs recorded and the corresponding osteotomy healing at 2 months postoperatively, each of them using a 3.5 mm broad TPLO Synthes locking plate that was attached using four locking screws proximally and two each of locking and standard cortical screws distally, the caudal margin of the plate was placed parallel to the caudal cortex of the tibia diaphysis, and a cranially 3 holes; construct 1 (A and A'), 4 holes; construct 2 (B and B'), 5 or more holes; construct 3 (C and C') 3.5 mm locking compression plate. White arrows show the cancellous bone retrieved from the wedge and packed on the caudal aspect of the tibia at the level of the osteotomy.

each breed with a minimum of six dogs, of the overall population and of groups 1, 2, and 3, are reported in **Table 1**.

Sixty-six percent of the dogs had contralateral CCLR; among them, 57% of cases occurred within 1 year after the first surgery.

Postoperatively, the AA and MA axes were aligned in 82% of cases, with a median AMA angle of 0°. In subgroup 1 (161

dogs), the AA aligned with the MA in 94% of dogs, and the AMA angle remained positive (median (range) 1° (0.6–1.6°) in 10 dogs.

In subgroup 2 (43 dogs), 75% of the dogs had a median (range) TLAS of  $-1.3^{\circ}$  ( $-0.4$  to  $-2.4^{\circ}$ ).

The distributions for groups 1, 2, and 3 were 21, 41, and 38%, respectively. The median (range) weight of 109 dogs



**Table 1** Population characteristics and preoperative values of the anatomical–mechanical axis angle (AMA angle) and tibial plateau angle (TPA), by breed, overall population, and the three AMA angle groups. The data are expressed as the medians (min–max)

Breed	N	Age (y)	Weight (kg)	Sex FN/F/MN/M	AMA angle (°)	TPA (°)
Cane Corso	60	3 (1.2–6.6)	54 (50–74)	28/0/2/30	3.1 (0–4.8)	30.1 (23.3–35.5)
BMD	32	3.6 (1.2–6.5)	54 (50–72)	20/0/0/12	3.8 (2.7–5)	31.6 (24–49.6)
Rottweiler	15	3.5 (1.2–10)	52 (50–66)	11/0/0/4	3 (1.2–4.6)	30 (24–41.4)
Pyrenees Mountain dog	12	3 (2–7)	62 (54–76)	5/1/1/5	2.4 (1.1–3.9)	28 (23–35)
Bordeaux dogue	11	3.4 (2.1–4.7)	61 (55–82)	6/0/0/5	4 (3.3–5.1)	30 (25–35)
Beauceron	11	4 (1.5–9)	52 (50–60)	5/0/0/6	2.3 (0.6–3.1)	30 (24–30)
NFL	9	3 (1–4.8)	73 (62–87)	2/0/0/7	2.7 (1.9–3.6)	27 (23–34.5)
Dogo Canario	7	2.9 (2–5.5)	52.5 (50–74)	1/0/1/5	3.2 (2.7–4)	31 (27.5–34)
Mastiff	7	2.5 (0.8–3.4)	72 (60–84)	3/0/0/4	3.5 (2.1–4.2)	28.6 (27–31)
Dogo Argentino	7	4 (1.5–6)	55 (50–66)	4/0/0/3	3.2 (3–3.8)	31.4 (28.3–34)
Overall population	204	3.2 (0.8–10)	57 (50–87)	97/3/5/99	3.1 (0–5.1)	30 (22–49.6)
Group 1 0 < AMA < 2.4°	39	4.4 (1.2–10)	58 (50–87)	18/0/0/21	2 (0–2.4)	27.7 (22–30.8)
Group 2 2.4 < AMA < 3.4°	86	3.1 (1.2–8)	54 (50–82)	39/3/2/43	3 (2.5–4.6)	29.2 (23.3–35.1)
Group 3 AMA > 3.4°	79	3.4 (0.8–6)	57 (50–84)	40/0/3/35	3.8 (3.4–5.1)	31.5 (25–49.6)

Abbreviations: BMD, Bernese Mountain dog; FN, female neutered; F, female; MN, male neutered; M, male; NFL, Newfoundland.

(53.4%) in construct 1, 87 dogs (42.6%) in construct 2, and 8 dogs (4%) in construct 3 was 54 kg (50–68 kg), 64 kg (60–77 kg), and 78 kg (72–82 kg), respectively. Ninety-seven dogs (47.6%) received a miniarthrotomy, and 107 (52.4%) did not undergo joint inspection.

Comparing dogs that underwent joint inspection and dogs that did not, there were no significant differences with respect to the side affected ( $p = 0.18$ ), age ( $p = 0.08$ ), weight ( $p = 0.88$ ), AMA angle ( $p = 0.67$ ), or TPA ( $p = 0.78$ ).

At the 2-month follow-up, osteotomy healing and patellar ligament thickening were 4/4 and grade 0/6, respectively, for all dogs.

An SSI was recorded in one dog (0.5%) that seemed to be resolved with the administration of antibiotics for an additional 15 days, but a fistula appeared 14 months postoperatively. The RJB of this dog had been removed by the owner 1 week postoperatively because it was not clean and dry, and the dog licked the surgical site and removed 2 cm of sutures that led to a superficial infection. In this dog, the bone plates were removed 14 months postoperatively. The bacteriological culture was positive (*Staphylococcus pseudintermedius*).

Seventy-seven percent of owners returned to the clinic for the 1-year follow-up (median (range): 16 months (12–60 months)), for surgery to treat the contralateral stifle, or for a reason not related to the stifle.

## Discussion

The results of our study support our hypothesis that most dogs weighing >50 kg affected by CCLR have a preoperative AMA angle >2.4° that is reduced to 0° postoperatively with the AMA-based CCWO procedure. In the current study, we

observed this in 82% of dogs treated. Indeed, the median preoperative AMA angle of the whole population of dogs was 3.1° with a median TPA of 30°. Overall, 21% of the dogs were observed to have an AMA angle lower than 2.4° and 79% higher than 2.4°, of which 38% were assessed as having hyper-CCAPT, with a median AMA angle of 3.9°.

Recent studies concerning the risk of complications following TPLO procedures have identified a heavy body weight and TPA >30° as significant predisposing factors.<sup>22,28</sup> In a recent study, dogs affected by CCLR with a preoperative TPA >30° and AMA angle >3° treated either by TPLO or AMA-based CCWO had a postoperative AMA angle that remained greater than 3° following TPLO compared with 0° following AMA-based CCWO, which suggests that misalignment of the AA and the MA persisted following TPLO in this subset of dogs.<sup>16</sup> A larger TPA, particularly when greater than or equal to 30°, requires a higher degree of rotation of the proximal tibia to achieve the desired post-TPLO TPA of 5° to 6°.<sup>22,31</sup> This results in increased caudal displacement of the weight-bearing axis and increased forces on the fibula<sup>22</sup> and the caudal aspect of the tibial plateau; additionally, this leads to increased caudal translation of the tibial plateau fragment (“balcony effect”), which may increase the risk of poor reduction and subsequent implant failure.<sup>5,17,22,31</sup> Solano and colleagues suggested that postoperative infection following TPLO in dogs >50 kg was significantly related to the stability of the construct.<sup>17</sup> The increase in caudal mechanical load consecutive to this “balcony effect” in the case of a preoperative TPA >30° and AMA angle >3° could lead to increased micromotion and instability at the osteotomy site as described by Windolf and colleagues in an experimental biomechanical study<sup>31</sup> and to a subsequent alteration of the vascular network that could provide favorable conditions for

bacterial proliferation.<sup>17</sup> These risks increase the odds of having a postsurgery complication by 1.10 for every 4.5 kg increase in body weight,<sup>22</sup> which has provided a cause for surgeons to improve the stability of radial osteotomy in dogs >50 kg treated with TPLO with a DLP procedure.<sup>6,17–20</sup> Further studies assessing the postoperative AMA angle and risks of SSI in dogs >50 kg are warranted to confirm this possible relationship.

In the study herein, the postoperative SSI rate was found to be 0.5%, which is less than previously published data in dogs >50 kg treated with TPLO.<sup>17–21</sup> Indeed, recent studies indicate that SSIs are the single most common minor and major complications in dogs >50 kg treated with TPLO, with reported incidences of 9.1,<sup>19</sup> 21.3,<sup>17</sup> 25.9,<sup>18</sup> 32.7,<sup>20</sup> and 37.5%<sup>21</sup> and with more than 60% of SSI occurring during the first 15 days postoperatively.<sup>6,17,19,21</sup>

DLP fixation has been used to treat dogs >50 kg either by TPLO or mCCWO<sup>6,19</sup> and has been shown to be a superior construct compared with the use of a nonlocking plate and decreases the risk of both implant failure and SSI.<sup>17,19</sup> We found that it was subjectively easier to apply a DLP than a locking plate plus a cerclage wire<sup>6</sup> and that our technique resulted in strong and stable fixation with grade 4 healing of all osteotomies by 8 weeks postoperatively.<sup>12,16</sup>

In a previous study involving 182 AMA-based CCWOs that were stabilized with a DLP (without the use of an RJB) and the administration of the same antibiotics as used in the current study for 10 days, almost all SSIs (5.5%) occurred during the first 15 days postoperatively.<sup>12</sup> These findings are consistent with those reported by Oxley and colleagues, in which an RJB was not applied following mCCWO and in which 10.8% of minor complications, such as incisional complications, wound self-trauma requiring re-suturing, and implant-associated infection, were reported to occur in the first postoperative period.<sup>6</sup> For the current study, in which an RJB was applied, the postoperative complication rate was lower and SSIs were not observed, except in one dog.

Despite the risk of complications associated with the application of an RJB,<sup>35</sup> which include pressure sores<sup>36</sup> and ischemic injuries,<sup>37</sup> the RJB acts as a barrier against surgical wound contamination<sup>35–39</sup> by protecting the incision site from self-induced patient trauma and by protecting the joint capsule sutures, the fascia, and the subcutaneous tissues from being overstretched if the dog is noncompliant, which is often the case in young, hyperactive, and heavy dogs, until the soft tissues are completely healed.

All dogs in the current study received postoperative antibiotics as previously recommended<sup>17–19,23–25,28,32</sup> despite preexisting controversy regarding their use following TPLO.<sup>22,24,40</sup>

Furthermore, Solano and colleagues demonstrated that failure to provide antibiotics following TPLO in dogs >50 kg was associated with a 2.96-fold increase in the risk of developing a postoperative infection and concluded that prophylactic postoperative antibiotics in this subset of dogs is justifiable.<sup>17</sup>

The limitations of the current study include the retrospective design, which does not account for incomplete clinical

records between the 2-month check-up and the minimum 1-year follow-up and could have affected the overall rate of infection. It is also possible that some dogs could have been clinically reassessed by the referring veterinarian for lameness due to inflammation and/or infection and, thus, may have been administered antibiotics without informing our clinic. However, given the very low percentage of SSI recorded in the current study, small fluctuations in the number of recorded SSIs would not be likely to alter this low incidence. Further research is warranted on the use of an RJB in other proximal tibial osteotomies and the associated SSI rate and should involve a prospective and multicentric design. Furthermore, the possible relationships between the magnitude of CCAPT, the postoperative AMA angle, and the occurrence of SSI in dogs >50 kg should be investigated.

## Conclusion

Given the findings of this study regarding the magnitude of the CCAPT recorded and the very low SSI rate, AMA-based CCWO with the use of a strong DLP fixation plus an RJB and postoperative antibiotics should be considered as a surgical treatment option in the existing panel of proximal tibial osteotomies that aim to alter the TPS to treat CCLR in dogs weighing >50 kg.

### Authors' Contribution

L.G. contributed to the conception and design of the study, data analysis, and data interpretation. A.V. and L.V. contributed to data analysis, data interpretation, and critical revision of the manuscript. All authors contributed to drafting and revision of the manuscript and approved the final version.

### Conflict of Interest

None declared.

### Acknowledgment

The author (L.G.) would like to thank Gwenaëlle Bergon, Virginie Favrais, Audrey Chagne, Marie Bonnet, and Marie Boyer for the technical support.

## References

- 1 Cook JL. Cranial cruciate ligament disease in dogs: biology versus biomechanics. *Vet Surg* 2010;39(03):270–277
- 2 Griffon DJ. A review of the pathogenesis of canine cranial cruciate ligament disease as a basis for future preventive strategies. *Vet Surg* 2010;39(04):399–409
- 3 Duerr FM, Martin KW, Rishniw M, Palmer RH, Selmic LE. Treatment of canine cranial cruciate ligament disease. A survey of ACVS Diplomates and primary care veterinarians. *Vet Comp Orthop Traumatol* 2014;27(06):478–483
- 4 Dejardin LM. Tibial plateau levelling osteotomy. In: *Textbook of Small Animal Surgery*. Philadelphia: W.B. Saunders Company; 2003:2133–2143
- 5 Raske M, Hulse D, Beale B, Saunders WB, Kishi E, Kunze C. Stabilization of the CORA based leveling osteotomy for treatment of cranial cruciate ligament injury using a bone plate augmented with a headless compression screw. *Vet Surg* 2013;42(06):759–764

- 6 Oxley B, Gemmill TJ, Renwick AR, Clements DN, McKee WM. Comparison of complication rates and clinical outcome between tibial plateau leveling osteotomy and a modified cranial closing wedge osteotomy for treatment of cranial cruciate ligament disease in dogs. *Vet Surg* 2013;42(06):739–750
- 7 Corr SA, Brown C. A comparison of outcomes following tibial plateau levelling osteotomy and cranial tibial wedge osteotomy procedures. *Vet Comp Orthop Traumatol* 2007;20(04):312–319
- 8 Wallace AM, Addison ES, Smith BA, Radke H, Hobbs SJ. Modification of the cranial closing wedge osteotomy technique for the treatment of canine cruciate disease. Description and comparison with standard technique. *Vet Comp Orthop Traumatol* 2011;24(06):457–462
- 9 Frederick SW, Cross AR. Modified cranial closing wedge osteotomy for treatment of cranial cruciate ligament insufficiency in dogs with excessive tibial plateau angles: Technique and complications in 19 cases. *Vet Surg* 2017;46(03):403–411
- 10 Christ JP, Anderson JR, Youk AO. Modified cranial closing wedge osteotomy in 25 dogs. *Vet Surg* 2018;47(05):683–691
- 11 Terreros A, Daye RM. Modified cranial closing wedge osteotomy to treat cranial cruciate ligament deficient stifles with excessive tibial plateau angles: complications, owner satisfaction, and midterm to long-term outcomes. *Vet Surg* 2020;49(06):1109–1117
- 12 Guénégo L, Payot M, Charru P, Verwaerde P. Alignment of the anatomical and mechanical axes during cranial closing wedge osteotomy (AMAbased-CCWO) for treatment of CCL disease in 182 dogs. Results and complications. Paper presented at: Proceedings of the 18th European Society of Veterinary Orthopaedic and Traumatology Congress; London, England; September 8–10, 2016:383–384
- 13 Guénégo L, Payot M, Charru P, Verwaerde P. Comparison of tibial anatomical-mechanical axis angle between predisposed dogs and dogs at low risk for cranial cruciate ligament rupture. *Vet J* 2017; 225:35–41
- 14 Guénégo L, Serri P, Charru P, Verwaerde P. Comparison of tibial anatomical-mechanical axis angle and patellar positions between Labrador retrievers and golden retrievers with and without cranial cruciate ligament rupture. *J Vet Sci Res* 2020;5:000199
- 15 Ševčík K, Karaffová V, Hluchý M, Ševčíková M, Ševčíková Z, Ledecký V. Relationship of mRNA expression of selected genes in peripheral blood and synovial fluid in cranial cruciate ligament deficient stifles of dogs. *Animals (Basel)* 2022;12(06):754
- 16 Guénégo L, Vezzoni A, Vezzoni L. Comparison of tibial anatomical-mechanical axis angles and patellar positions between tibial plateau levelling osteotomy (TPLO) and modified cranial closing wedge osteotomy (AMA-based CCWO) for the treatment of cranial cruciate ligament disease in large dogs with tibial plateau slopes greater than 30° and clinically normal Labrador retrievers. *BMC Vet Res* 2021;17(01):368
- 17 Solano MA, Danielski A, Kovach K, Fitzpatrick N, Farrell M. Locking plate and screw fixation after tibial plateau leveling osteotomy reduces postoperative infection rate in dogs over 50 kg. *Vet Surg* 2015;44(01):59–64
- 18 Hans EC, Barnhart MD, Kennedy SC, Naber SJ. Comparison of complications following tibial tuberosity advancement and tibial plateau levelling osteotomy in very large and giant dogs 50 kg or more in body weight. *Vet Comp Orthop Traumatol* 2017;30(04):299–305
- 19 Tuan J, Solano MA, Danielski A. Risk of infection after double locking plate and screw fixation of tibial plateau leveling osteotomies in dogs weighing greater than 50 kilograms. *Vet Surg* 2019; 48(07):1211–1217
- 20 Anderson TS, Barnes DC, Quinn RJ. Complications following TPLO in large and giant breed dogs stabilized with multiple locking plates. Paper presented at: Proceedings of the 28<sup>th</sup> annual scientific meeting of the European Congress of Veterinary Surgeons. Budapest, Hungary; July 4–6, 2019
- 21 MacCormick MRA, Daye RM. Use of a jumbo plate in dogs greater than 50 kg following tibial plateau leveling osteotomy does not prevent increase in tibial plateau angle through convalescence. *J Am Vet Med Assoc* 2023;261(12):1–8
- 22 Coletti TJ, Anderson M, Gorse MJ, Madsen R. Complications associated with tibial plateau leveling osteotomy: a retrospective of 1519 procedures. *Can Vet J* 2014;55(03):249–254
- 23 Nazarali A, Singh A, Weese JS. Perioperative administration of antimicrobials during tibial plateau leveling osteotomy. *Vet Surg* 2014;43(08):966–971
- 24 Clark AC, Greco JJ, Bergman PJ. Influence of administration of antimicrobial medications after tibial plateau leveling osteotomy on surgical site infections: a retrospective study of 308 dogs. *Vet Surg* 2020;49(01):106–113
- 25 Frey TN, Hoelzler MG, Scavelli TD, Fulcher RP, Bastian RP. Risk factors for surgical site infection-inflammation in dogs undergoing surgery for rupture of the cranial cruciate ligament: 902 cases (2005–2006). *J Am Vet Med Assoc* 2010;236(01):88–94
- 26 Nicoll C, Singh A, Weese JS. Economic impact of tibial plateau leveling osteotomy surgical site infection in dogs. *Vet Surg* 2014; 43(08):899–902
- 27 Bureau S. Owner assessment of the outcome of tibial plateau levelling osteotomy without meniscal evaluation for treatment of naturally occurring cranial cruciate ligament rupture: 130 cases (2009 to 2013). *J Small Anim Pract* 2017;58(08):468–475
- 28 Fitzpatrick N, Solano MA. Predictive variables for complications after TPLO with stifle inspection by arthrotomy in 1000 consecutive dogs. *Vet Surg* 2010;39(04):460–474
- 29 Kowaleski MP, Boudrieau RJ, Beale BS, Piras A, Hulse D, Johnson KA. Radiographic outcome and complications of tibial plateau leveling osteotomy stabilized with an anatomically contoured locking bone plate. *Vet Surg* 2013;42(07):847–852
- 30 National Healthcare Safety Network, Centers for Disease Control and Prevention. Surgical site infection (SSI) event. 2017. Accessed January 25, 2017 at: <http://www.cdc.gov/nhsn/pdfs/pscmanual/9pscscicurrent.pdf>
- 31 Windolf M, Leitner M, Schwieger K, et al. Accuracy of fragment positioning after TPLO and effect on biomechanical stability. *Vet Surg* 2008;37(04):366–373
- 32 Hagen CRM, Singh A, Weese JS, Marshall Q, Linden AZ, Gibson TWG. Contributing factors to surgical site infection after tibial plateau leveling osteotomy: a follow-up retrospective study. *Vet Surg* 2020;49(05):930–939
- 33 Carey K, Aiken SW, DiResta GR, Herr LG, Monette S. Radiographic and clinical changes of the patellar tendon after tibial plateau leveling osteotomy 94 cases (2000–2003). *Vet Comp Orthop Traumatol* 2005;18(04):235–242
- 34 Mattern KL, Berry CR, Peck JN, De Haan JJ. Radiographic and ultrasonographic evaluation of the patellar ligament following tibial plateau leveling osteotomy. *Vet Radiol Ultrasound* 2006;47(02):185–191
- 35 Brodell JD, Axon DL, Everts CM. The Robert Jones bandage. *J Bone Joint Surg Br* 1986;68(05):776–779
- 36 Iodence AE, Olsen AM, McGilvray KC, Duncan CG, Duerr FM. Use of pressure mapping for quantitative analysis of pressure points induced by external coaptation of the distal portion of the pelvic limb of dogs. *Am J Vet Res* 2018;79(03):317–323
- 37 Anderson DM, White RA. Ischemic bandage injuries: a case series and review of the literature. *Vet Surg* 2000;29(06):488–498
- 38 Campbell BG. Dressings, bandages, and splints for wound management in dogs and cats. *Vet Clin North Am Small Anim Pract* 2006;36(04):759–791
- 39 Harrison EJ, Scherrer WE, Fragola J, et al. Preliminary evaluation of a hydrogel liquid bandage in 30 dogs undergoing tibial plateau levelling osteotomy surgery. *N Z Vet J* 2017;65(01):30–33
- 40 Husi B, Overesch G, Forterre F, Rytz U. Surgical site infection after 769 Tibial Plateau Leveling Osteotomies. *Front Vet Sci* 2023;10:1133813