



# Superior Sagittal Sinus Thrombosis Secondary to Cerebral Aspergillosis with Ventriculitis in an Immunocompetent Patient: A Case Report

Chonrawee Chaisawasthomrong<sup>1</sup>

<sup>1</sup> Division of Neurosurgery, Department of Surgery, Ratchaburi Hospital, Ratchaburi, Thailand

Asian J Neurosurg

**Address for correspondence** Chonrawee Chaisawasthomrong, MD, Division of Neurosurgery, Department of Surgery, Ratchaburi Hospital, Ratchaburi 70000, Thailand (e-mail: chonraweethailand@gmail.com).

## Abstract

Cerebral aspergillosis is an opportunistic fungal infection that is exceedingly rare in immunocompetent patients. The primary etiological locations for these infections typically involve the nasal cavity and hematological dissemination. A 62-year-old male, focused on wellness, presented with intermittent, nonprogressive headaches in the occipital region, generalized clonic-tonic seizures, and altered consciousness. A computed tomography scan revealed multiple small rim-enhancing lesions in both occipital lobes, with vasogenic edema in both occipital lobes adjacent to the confluence of the sinuses and the posterior superior sagittal sinus. In this case, superior sagittal sinus thrombosis secondary to cerebral aspergillosis was discovered, a condition not previously diagnosed in this specific location but manageable through surgical intervention. A combination of surgical resection and antifungal therapy resulted in favorable outcomes. The prognosis for patients depends significantly on early diagnosis and prompt, aggressive treatment.

## Keywords

- ▶ superior sagittal sinus thrombosis
- ▶ venous sinus thrombosis
- ▶ cerebral aspergillosis
- ▶ brain abscess
- ▶ aspergillosis

## Introduction

Cerebral aspergillosis (CA) is an opportunistic fungal infection that is very rare in immunocompetent patients. However, there is an increasing number of reported cases of CA in immunocompetent patients. Clinical manifestations often include high fever, headache, neurological deficits, or focal/generalized seizures.<sup>1</sup> In some cases, it can even manifest as intracerebral hemorrhage, ultimately culminating in venous sinus thrombosis. There has been a growing number of reports of CA in immunocompetent patients, especially in the intensive care unit.<sup>2-4</sup>

*Aspergillus ventriculitis* is a devastating condition associated with significant morbidity and a high mortality rate.<sup>5</sup> The overall case fatality rate stands at 72.1%.<sup>6</sup> The treatment approach for central nervous system aspergillosis typically involves intravenous voriconazole. Additionally, some studies have suggested that intraventricular liposomal amphotericin B may be effective in cases of refractory *Aspergillus ventriculitis*.

Surgical excision of infected tissue, such as paranasal sinuses, bone, and brain abscesses, should be considered when feasible.<sup>7</sup> A small retrospective study has indicated that surgical resection of cerebral lesions, combined with

DOI <https://doi.org/10.1055/s-0044-1791714>.  
ISSN 2248-9614.

© 2024. Asian Congress of Neurological Surgeons. All rights reserved.

This is an open access article published by Thieme under the terms of the Creative Commons Attribution-NonDerivative-NonCommercial-License, permitting copying and reproduction so long as the original work is given appropriate credit. Contents may not be used for commercial purposes, or adapted, remixed, transformed or built upon. (<https://creativecommons.org/licenses/by-nc-nd/4.0/>)

Thieme Medical and Scientific Publishers Pvt. Ltd., A-12, 2nd Floor, Sector 2, Noida-201301 UP, India

antifungal therapy using voriconazole, may enhance the chances of survival.

We present a case of superior sagittal sinus thrombosis secondary to cerebral aspergillus abscess with concurrent ventriculitis in an immunocompetent patient. The diagnosis was confirmed through cerebral pus culture, which tested positive for fungus, and a cerebrospinal fluid (CSF) galactomannan antigen test.

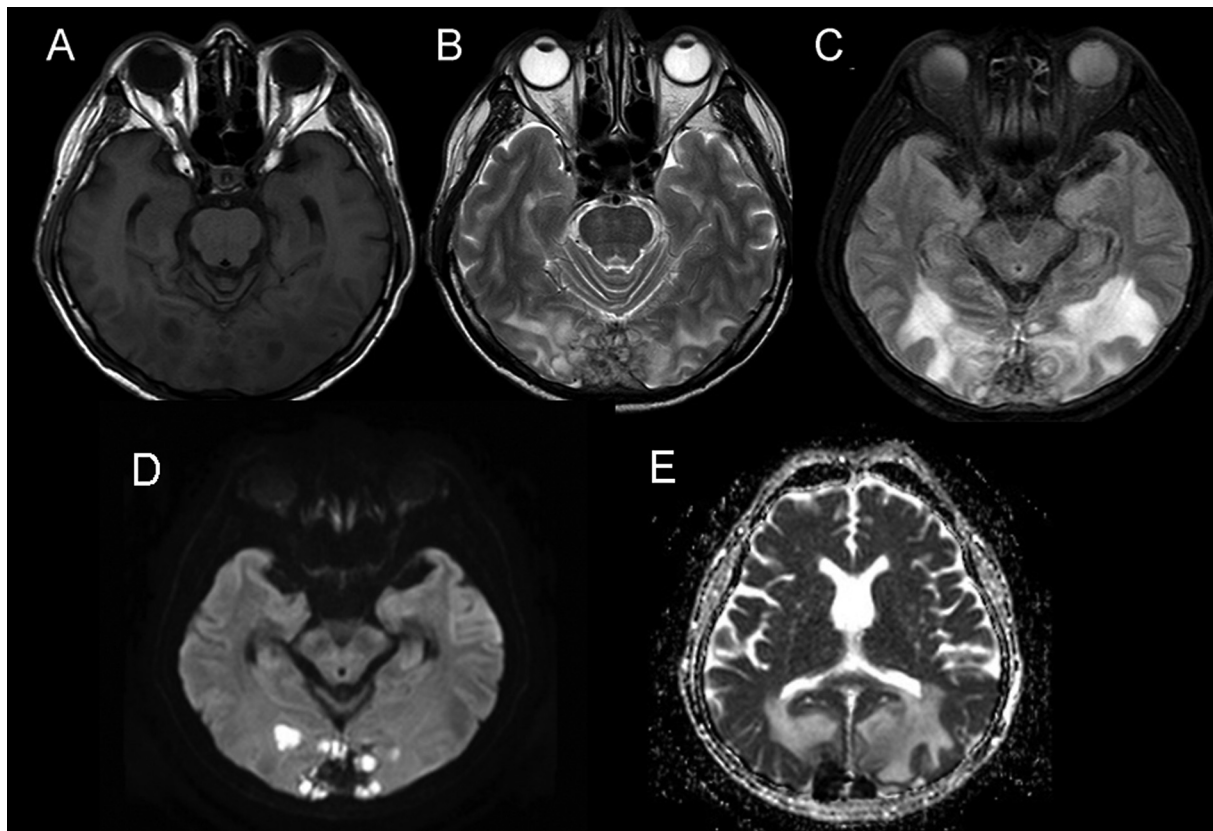
### Case History

A 62-year-old male presented with a medical history including herpes zoster, which was treated with antiviral medication for a year, and had no history of steroid use. He also had underlying medical conditions including hypertension. He presented with intermittent, nonprogressive headaches located in the occipital region. Initial treatment involved conservative measures using analgesic agents, but there was no improvement. Subsequently, a magnetic resonance imaging (MRI) examination was conducted, revealed multiple rim-enhancing lesions adjacent to the bilateral occipital lobe, invading the confluence of sinuses, and the posterior two-thirds of the superior sagittal sinus. These lesions showed hypointensity on T1-weighted imaging (T1WI) and mix hypo-hypersignal intensity on T2WI. Additionally, restricted diffusion was observed on diffusion-

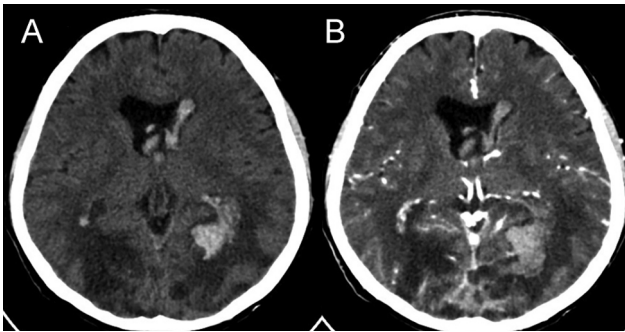
weighted imaging and apparent diffusion coefficient image. The radiologist confirmed that these findings indicate a brain abscess secondary to venous sinus thrombosis (►Fig. 1).

Following this, one day, he visited the emergency room as his condition worsened. He experienced a severe, progressively worsening headache, accompanied by a generalized clonic-tonic seizure, during which his eyes deviated upward for approximately 2 minutes. After the seizure, he regained consciousness but continued to experience a severe headache. Upon evaluation in the neurosurgery department, it was observed that he had a decreased level of consciousness and progressive right hemiparesis. The neurological examination revealed the patient to be drowsy and disoriented in terms of time, place, and person. His Glasgow Coma Scale score was E1V2M5, with pupils 2 mm slight reaction to light. Motor power in his right extremities was graded at 2. A computed tomography scan revealed stable enhancing lesions with vasogenic edema in both occipital lobes, as well as hyperdensity in the left occipital lobe. Additionally, it indicated involvement of both occipital horns of the lateral ventricle, raising suspicion of a hemorrhage at the foramen of Monro (►Fig. 2).

Patients undergo a series of tests, including hemoculture, urine culture, sputum gram stain, sputum culture, and human immunodeficiency virus testing, to pinpoint the cause of the brain abscess. However, no evidence of infection

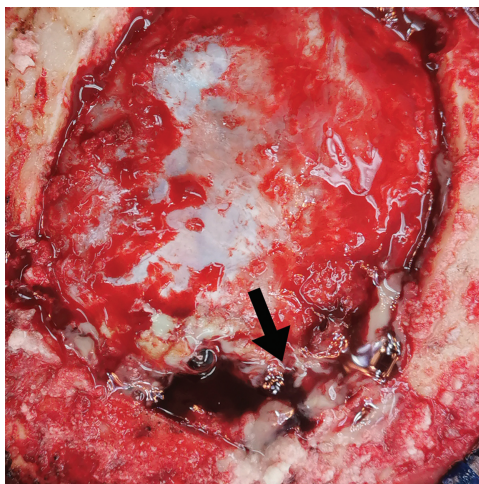


**Fig. 1** Radiological findings. Magnetic resonance imaging brain revealed multiple rim-enhancing lesions adjacent to the bilateral occipital lobe, invading the confluence of sinuses and the posterior two-thirds of the superior sagittal sinus. These lesions showed hypointensity on T1-weighted imaging and mix hypo-hypersignal intensity on T2-weighted imaging. Additionally, restricted diffusion was observed on diffusion-weighted imaging and apparent diffusion coefficient images: (A) T1-weighted imaging, (B) T2-weighted imaging, (C) fluid attenuated inversion recovery, (D) diffusion-weighted imaging, and (E) apparent diffusion coefficient image.



**Fig. 2** Radiological findings. Computed tomography (CT) brain revealed multiple rim-enhancing lesions with vasogenic edema in both occipital lobes, along with bilateral occipital horn intraventricular hemorrhage. (A and B) Contrast and noncontrast CT brain.

in other organs was detected, leading to the diagnosis of a brain abscess secondary to venous sinus thrombosis as the sole condition. Subsequently, the patient underwent operation involving a left occipital craniectomy for clot removal and drainage of the abscess. During the operation, significant brain swelling was observed, along with pus accumulation in the medial occipital lobe, leading to the destruction of the posterior two-thirds of the superior sagittal sinus. Additionally, there was a left occipital hematoma containing approximately 20 mL of pus (→**Fig. 3**). In a subsequent procedure, bilateral frontal ventriculostomies were performed to facilitate drainage of both blood and pus. During this operation, elevated pressure exceeding 30 cmH<sub>2</sub>O was noted in the CSF, which appeared reddish and turbid, and contained tissue debris within both frontal horns of the lateral ventricle. Pus tissue culture exhibited the presence of rare septate hyphae, and the culture results confirmed the presence of *Aspergillus* species. In the CSF analysis, the white blood cell (WBC) count was elevated at 1,157 cells/cu.mm, with 82% being neutrophils. The red blood cell (RBC) count in the CSF was 23,000 cells/cu.mm. Additionally, the CSF showed elevated protein levels at 147.2 mg/dL and glucose levels at 58.7 mg/dL. Furthermore, the CSF galactomannan antigen test yielded a



**Fig. 3** Intraoperative occipital craniectomy containing approximately 20 mL of pus. Arrow: Confluence of sinuses.

positive result. We diagnosed the patient with *Aspergillus* cerebral abscess accompanied by ventriculitis and venous sinus thrombosis. The patient was administered voriconazole at a dosage of 280 mg intravenously every 12 hours, a regimen maintained until the results of the pus culture were reported then performed ventricle irrigation with normal saline via ventriculostomy three times per week. Upon further examination of the CSF profile, a WBC count of 46 was observed, with no RBC detected. Additionally, no pathogens were detected in the following 2 weeks.

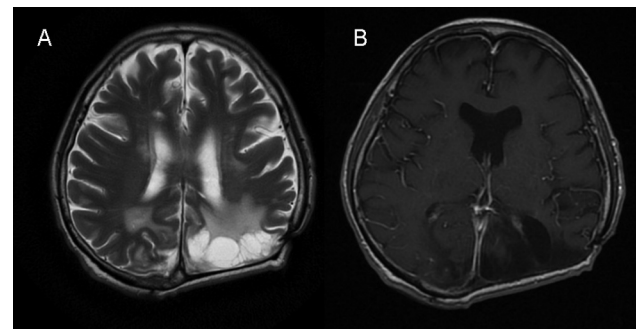
During the third surgery, the patient underwent a left occipital craniectomy with lobectomy due to severe brain edema, as well as aspiration and irrigation of the residual right cerebral abscess. Cultures were obtained, but no pathogens were identified. The patient continued to receive intravenous voriconazole treatment, with dosage adjustments based on serum voriconazole levels. Subsequent imaging follow-ups revealed the persistence of abscess cavities in both occipital lobes, although there was a slight improvement in the patient's level of consciousness following the medication and surgery. In total, the patient was admitted for 100 days, underwent three operations, and received voriconazole injections.

Upon 1 year of follow-up, the patient's consciousness had significantly improved, and they were alert and cooperative. Their neurological examination showed E4V5M6 with pupils measuring 3 mm and reacting to light. Additionally, the patient exhibited grade V motor power in all extremities.

In the most recent MRI brain review, there was evidence of encephalomalacia in the left occipital lobe, as well as a few small areas of encephalomalacia along the parasagittal aspect of the right occipital lobe and the right cerebellar hemisphere. Notably, there was no observed dilatation of the ventricular system. Additionally, hypersignal intensity in T2WI indicated minimal persistence of the superior sagittal sinus (→**Fig. 4**).

## Discussion

Immunocompetent CA is an exceedingly uncommon condition. *Aspergillus* can infiltrate the central nervous system



**Fig. 4** After 1 year of treatment, magnetic resonance imaging showed several small areas of encephalomalacia along the parasagittal aspect of the right occipital lobe. Additionally, hypersignal intensity in T2-weighted imaging indicated minimal persistence of the superior sagittal sinus.

(CNS) by three different routes: first, by hematogenous spread from a remote extracranial focus; second, by extension from a contiguous extracranial location; and the third pathway involves the direct introduction of *Aspergillus* into the central nervous system through a neurosurgical procedure, known as an iatrogenic route.<sup>8</sup> Numerous studies have documented an exceptionally high fatality rate in cases of CNS aspergillosis, with over 90% of individuals succumbing to the disease.<sup>9,10</sup> *Aspergillus* species thrive in well-oxygenated environments and are typically contracted by inhaling their spores. They are frequently found in soil, plant residue, and indoor environments.<sup>11</sup>

The brain exhibits remarkable resistance to fungal infections, owing to its abundant blood supply and the relatively impermeable blood–brain barrier. Nevertheless, despite the protective anatomical and functional barriers surrounding the brain and subarachnoid space, fungal pathogens can breach these defenses under specific conditions or in the presence of immune system abnormalities.<sup>12</sup> It is noteworthy that *Aspergillus* granulomas are predominantly reported in immunocompetent individuals in regions with temperate climates.<sup>13,14</sup>

Prior studies have reported cases of venous sinus thrombosis secondary to CA occurring in various locations, including the cavernous sinus,<sup>15–17</sup> sphenoid sinus, sella turcica, and the internal carotid artery.<sup>18</sup> The primary etiological location for these infections typically involves infections in the nasal cavity and hematological dissemination. However, our case presents an uncommon occurrence, with involvement in the superior sagittal sinus secondary to aspergillosis, which has not been previously diagnosed in this specific location.

The preferred treatment for sino-orbital aspergillosis or sphenoidal involvement is the surgical excision of the aspergilloma, along with the removal of granulation tissue from the affected sinus to facilitate proper ventilation and drainage. This intervention should be undertaken as early as possible in the course of the disease.<sup>19–21</sup> Notably, a small retrospective study has indicated that combining surgical resection of cerebral lesions with antifungal therapy using voriconazole may potentially enhance overall survival rates.<sup>22</sup>

The mainstay of treatment for a brain abscess secondary to cerebral venous thrombosis involves administering appropriate antibiotics based on culture results or the identified focus of infection. The use of anticoagulation therapy is a subject of debate and may or may not be recommended.<sup>23</sup>

In this case, our objective was to eradicate the pathogen through surgical management, involving maximal resection and drainage of the abscess located in the occipital hemisphere. Additionally, we attempted to initiate a bilateral intraventricular irrigation procedure to eliminate the pathogen from the ventricular system and to alleviate brain swelling through decompressive craniectomy. Following the surgical procedure, we collected pus for culture analysis. Once the pathogen was identified in the culture report, we promptly initiated voriconazole treatment. All of the proce-

dures, such as abscess aspiration, ventricular system irrigation, and systemic voriconazole injection, are aimed at aggressively eradicating pathogens. These steps are taken until the patient's clinical condition improves, and they can successfully recover.

## Conclusion

Superior sagittal sinus thrombosis secondary to CA was very rare especially in immunocompetent patient. Treatment of CA still be a combination of surgical resection and antifungal therapy resulted in good outcomes. The prognosis of the patients depends on early diagnosis and prompt aggressive treatment.

## Conflict of Interest

None declared.

## Acknowledgment

I extend my gratitude to Wutthiseth Dhitinanmuang, an infectious medicine doctor, for his dedicated care of patient and his adjustment of voriconazole, which contributed to the cure of the brain abscess.

## References

- 1 Verweij PE, Brinkman K, Kremer HP, Kullberg BJ, Meis JF. *Aspergillus* meningitis: diagnosis by non-culture-based microbiological methods and management. *J Clin Microbiol* 1999;37(04): 1186–1189
- 2 Bokhari R, Baeesa S, Al-Maghrabi J, Madani T. Isolated cerebral aspergillosis in immunocompetent patients. *World Neurosurg* 2014;82(1-2):e325–e333
- 3 Spapen H, Spapen J, Taccone FS, et al; AspICU Study Investigators. Cerebral aspergillosis in adult critically ill patients: a descriptive report of 10 patients from the AspICU cohort. *Int J Antimicrob Agents* 2014;43(02):165–169
- 4 Taccone FS, Van den Abeele AM, Bulpa P, et al; AspICU Study Investigators. Epidemiology of invasive aspergillosis in critically ill patients: clinical presentation, underlying conditions, and outcomes. *Crit Care* 2015;19(01):7
- 5 Taccone FS, Van den Abeele AM, Bulpa P, et al; AspICU Study Investigators. Epidemiology of invasive aspergillosis in critically ill patients: clinical presentation, underlying conditions, and outcomes. *Crit Care* 2015;19(01):7
- 6 Antinori S, Corbellino M, Meroni L, et al. *Aspergillus* meningitis: a rare clinical manifestation of central nervous system aspergillosis. Case report and review of 92 cases. *J Infect* 2013;66(03): 218–238
- 7 Miceli MH. Central nervous system infections due to *Aspergillus* and other hyaline molds. *J Fungi (Basel)* 2019;5(03):79
- 8 Endo T, Numagami Y, Jokura H, Ikeda H, Shirane R, Yoshimoto T. *Aspergillus* parasellar abscess mimicking radiation-induced neuropathy. Case report. *Surg Neurol* 2001;56(03):195–200
- 9 Bodey G, Bueltmann B, Duguid W, et al. Fungal infections in cancer patients: an international autopsy survey. *Eur J Clin Microbiol Infect Dis* 1992;11(02):99–109
- 10 Stevens DA, Kan VL, Judson MA, et al; Infectious Diseases Society of America. Practice guidelines for diseases caused by *Aspergillus*. *Clin Infect Dis* 2000;30(04):696–709
- 11 Zmeili OS, Soubani AO. Pulmonary aspergillosis: a clinical update. *QJM* 2007;100(06):317–334
- 12 Dotis J, Roilides E. Immunopathogenesis of central nervous system fungal infections. *Neurol India* 2007;55(03):216–220

- 13 Murthy JM, Sundaram C, Prasad VS, Purohit AK, Rammurti S, Laxmi V. Sinocranial aspergillosis: a form of central nervous system aspergillosis in south India. *Mycoses* 2001;44(05): 141–145
- 14 Shankar SK, Mahadevan A, Sundaram C, et al. Pathobiology of fungal infections of the central nervous system with special reference to the Indian scenario. *Neurol India* 2007;55(03): 198–215
- 15 Brenet E, Boulagnon-Rombi C, N'guyen Y, Litré CF. Cavernous sinus thrombosis secondary to aspergillus granuloma: a case report and review of the literature. *Auris Nasus Larynx* 2016;43 (05):566–569
- 16 Huang Y, Gui L. Cavernous sinus-orbital apex aspergillus infection in a diabetic patient: a case report. *Medicine (Baltimore)* 2019;98 (13):e15041
- 17 Rajagopala S, Chandrasekharan S, Kumar S, Rela M. Fulminant Aspergillus related cavernous sinus thrombosis in an immunocompetent intensive care unit patient. *Austin Crit Care J.* 2014;1 (01):1–3
- 18 Sekhar LN, Dujovny M, Rao GR. Carotid-cavernous sinus thrombosis caused by Aspergillus fumigatus. Case report. *J Neurosurg* 1980;52(01):120–125
- 19 Boutarbouch M, Arkha YA, El Ouahabi A, Derraz A, El khamlichi A. . Sphenoid aspergillosis simulating pituitary tumor in immunocompetent patient. *J Clin Neurosci* 2009;16(06):840–841
- 20 Panda NK, Saravanan K, Chakrabarti A. Combination antifungal therapy for invasive aspergillosis: can it replace high-risk surgery at the skull base? *Am J Otolaryngol* 2008;29(01):24–30
- 21 Siddiqui AA, Shah AA, Bashir SH. Craniocerebral aspergillosis of sinonasal origin in immunocompetent patients: clinical spectrum and outcome in 25 cases. *Neurosurgery* 2004;55(03):602–611, discussion 611–613
- 22 Schwartz S, Ruhnke M, Ribaud P, et al. Improved outcome in central nervous system aspergillosis, using voriconazole treatment. *Blood* 2005;106(08):2641–2645
- 23 Jacob MS, Gunasekaran K, Miraclin AT, et al. Clinical profile and outcome of patients with cerebral venous thrombosis secondary to bacterial infections. *Ann Indian Acad Neurol* 2020;23(04):477–481