



Practical Consensus Guidelines on the Use of Cetuximab in Head and Neck Squamous Cell Carcinoma (HNSCC)

Purvish M. Parikh¹ Ghanashyam Biswas² Nilesh Ashok Dhamne³ Chetan Dilip Deshmukh⁴
Sewanti Limaye⁵ Ashish Singh⁶ Hemant Malhotra⁷ Viashsta Pankaj Maniar⁸
Bhupendra Nath Kapur⁹ Prasad V.S.S. Sripada¹⁰ Vikas Tulsidas Talreja¹¹ Poonam Patil¹²
Suhas Vilasrao Agre¹³ Amit Dilip Bhat¹⁴ Priya Privadarshini Nayak¹⁵ Arun Seshachalam¹⁶
Boman Nariman Dhabhar¹⁷ Ajay Sharma¹⁸ Niraj N. Bhatt¹⁹ Pratap Kishore Das²⁰ Atul Sharma²¹
Govind Babu Kanakasetty²² Suresh Hariram Advani²³

- ¹ Department of Clinical Hematology, Mahatma Gandhi University of Medical Sciences and Technology, Jaipur, Rajasthan, India
- ² Department of Medical Oncology, Sparsh Hospitals and Critical Care Pvt Ltd, Bhubaneswar, Orissa, India
- ³ Department of Medical Oncology, Kolhapur Cancer Center, Kolhapur, Maharashtra, India
- ⁴ Department of Medical Oncology, Deenanath Mangeskar Hospital, Pune, Maharashtra, India
- ⁵ Department of Medical and Precision Oncology, Sir H.N. Reliance Foundation Hospital, Mumbai, Maharashtra, India
- ⁶ Department of Medical Oncology, Christian Medical College, Vellore, Tamil Nadu, India
- ⁷ Department of Medical Oncology, Sri Ram Cancer Center, Mahatma Gandhi University of Medical Sciences and Technology, Jaipur, Rajasthan, India
- ⁸ Department of Medical Oncology, MOC Cancer Care and Research Center, Mumbai, Maharashtra, India
- ⁹ Department of Medical Oncology, Yashoda Hospital, Ghaziabad, Uttar Pradesh, India
- ¹⁰ Department of Medical Oncology, Apollo Cancer Centers, Hyderabad, Telangana, India
- ¹¹ Department of Medical Oncology, Regency Hospital, Kanpur, Uttar Pradesh, India
- ¹² Department of Medical Oncology, Manipal Hospital, Bengaluru, Karnataka, India

Address for correspondence Purvish M. Parikh, MD, DNB, FICP, PHD, ECMO, CPI, Department of Clinical Hematology, Sri Ram Cancer Center, Mahatma Gandhi University of Medical Sciences and Technology, Jaipur 302022, Rajasthan, India (e-mail: purvish1@gmail.com).

- ¹³ Department of Medical Oncology, Hiranani Hospital, Mumbai, Maharashtra, India
- ¹⁴ Department of Medical Oncology, Avinash Cancer Clinic, Pune, Maharashtra, India
- ¹⁵ Department of Medical Oncology, Sum Ultimate Medicare, Bhubaneswar, Orissa, India
- ¹⁶ Department of Medical Oncology, Dr GVN Cancer Institute, Trichy, Kerala, India
- ¹⁷ Department of Medical Oncology, Fortis Mulund, Mumbai, Maharashtra, India
- ¹⁸ Department of Medical Oncology, AS lifeline Cancer Care Hospital, New Delhi, India
- ¹⁹ Department of Medical Oncology and Hematology, Hemato Oncology Clinic, Vadodara, Gujarat, India
- ²⁰ Department of Medical Oncology, Apollo Hospital, New Delhi, India
- ²¹ Department of Medical Oncology, Max Hospital Saket, New Delhi, India
- ²² Department of Medical Oncology, St. Johns Medical College Hospital, Bengaluru, Karnataka, India
- ²³ Department of Medical Oncology, Sushruth Hospital, Mumbai, Maharashtra, India

South Asian J Cancer

Abstract

Head and neck squamous cell carcinoma (HNSCC) is the most common malignancy group in India and several other low- and middle-income countries. Currently, majority of the patients present in advanced stage where systemic therapy is standard of care. Multiple relapses are also not uncommon. Almost all HNSCC tumors have epidermal growth factor receptor (EGFR) overexpression, making an attractive target. Cetuximab is the most successful method to target EGFR in HNSCC. After decades of its use, it still is a prominent part of the current management guidelines. Since other agents have

Keywords

- ▶ oral cancer
- ▶ monoclonal antibody
- ▶ EGFR
- ▶ targeted therapy

DOI <https://doi.org/10.1055/s-0044-1791783> ISSN 2278-330X

How to cite this article: Parikh PM, Biswas G, Dhamne NA, et al. Practical Consensus Guidelines on the Use of Cetuximab in Head and Neck Squamous Cell Carcinoma (HNSCC). *South Asian J Cancer* 2024;00(00):00–00.

© 2024. MedIntel Services Pvt Ltd. All rights reserved.

This is an open access article published by Thieme under the terms of the Creative Commons Attribution-NonDerivative-NonCommercial-License, permitting copying and reproduction so long as the original work is given appropriate credit. Contents may not be used for commercial purposes, or adapted, remixed, transformed or built upon. (<https://creativecommons.org/licenses/by-nc-nd/4.0/>)

Thieme Medical and Scientific Publishers Pvt. Ltd., A-12, 2nd Floor, Sector 2, Noida-201301 UP, India



Purvish M. Parikh

also been proven to be useful, we felt it was necessary to develop a real-world consensus guideline to help the decision-making process among the community oncologists. Our expert committee therefore put together currently available data, insights from their real-world clinical practice, and voted to arrive at a consensus. These consensus guidelines represent how cetuximab should be used today in the management of HNSCC.

Introduction

Carcinomas of head and neck (HN) region consist of a group of carcinomas of the lip, oral cavity, pharynx, larynx, paranasal sinuses, or salivary glands. The majority (90%) of HN cancers are squamous cell carcinomas (HNSCCs). Most of them occur in the lip/oral cavity (41%), larynx (20%), and pharynx (naso + oro + hypo; 34%).¹ HNSCC is a devastating disease that accounts for over 600,000 new cancer cases worldwide on a yearly basis with about half the patients having regional lymph node metastasis or locally advanced disease at the time of diagnosis. In India, we saw incidence of 225,419 new cases and 125,000 deaths per year. And we have more than 60% presenting in the locally advanced stages.¹ The majority (75%) have direct causative relationship with tobacco and alcohol.² Despite advances in diagnostics and treatment of HNSCC, overall 5-year survival remains stagnant at only 50% with significant rates of second primaries. In the Indian context, adverse prognostic factors include bulky tumors, primary in the oral cavity, younger age at diagnosis, and tobacco use starting in their teens.

Various options for their management include single-agent systemic therapy, combination systemic therapy, induction (neoadjuvant) therapy, metronomic therapy, immunotherapy, monoclonal antibodies, surgery, radiation therapy, and salvage therapy.³ Common agents used for systemic therapy include cisplatin/carboplatin/paclitaxel/docetaxel/5-fluorouracil/methotrexate/cetuximab (CTX)/gemcitabine/capecitabine/nivolumab/pembrolizumab and their derivatives.^{4–6}

Epidermal growth factor receptor (EGFR) overexpression or alterations are seen in almost all patients with HNSCC.⁷ Its adverse independent prognostic implication is established (reduced overall survival [OS]) in HNSCC.⁸ As far back as in 2006, value of treating HNSCC patients with CTX (anti-EGFR monoclonal antibody) was established with a highly significant improvement in 5-year OS.^{9–14} Subsequently, a multitude of clinical studies consolidated its role in various HNSCC scenarios—with chemoradiotherapy (CRT), radiotherapy (RT), organ preservation, and combination systemic therapy.^{15–25} This includes impressive data from India as well.^{26,27}

A score (two decades) later, CTX continues to play a vital role in the management of HNSCC.²⁸ This is because it has several modes of action. Besides EGFR inhibition, CTX also activates natural killer cells and induces antibody-dependent cellular cytotoxicity. It also has synergistic antitumor activity in combination with other targeted therapies.²⁹

In view of recent advances, availability of other novel targeted agents, data from CTX combinations, and finer points regarding the pros and cons in various clinical circumstances in the real world, we decided to put together these practical consensus guidelines on how to optimize use of CTX in HNSCC, with a focus on the real-world setting in the context of India and other low- and middle-income countries (LMICs).

Methods

For the development of a consensus recommendation we follow the method that we have followed and described earlier.^{30,31} The subject experts are medical oncologists with special academic interest and real-world experience in the management of HNSCC (all of which are coauthors). The group communicated in online mode (email, WhatsApp, webinar, videoconference) for structured discussions and voting. The well-established and previously used Delphi method was followed.³² Our method was aimed for a 75% consensus for these guidelines. When initial consensus was not present, further discussions were undertaken in the group with updated published literature of relevance being provided in advance. Tabulation of the final voting results formed the basis of the consensus recommendations. These took into consideration published international literature, data from Indian, and real-world experience/insights.³³ All the authors participated in the above steps by giving critical review, voting as many times as required, and ultimately contributed to the development of the final article “Practical consensus guidelines for the use of CTX in HNSCC.”

Results

When asked regarding their own real-world practice, there was a broad spectrum of patients seen by our expert committee. As far as the number of patients having high-risk features at initial presentation, the majority (14/23; 61%) found these in more than half of their patients (→ Fig. 1–2). Similarly, the number of geriatric patients (60 years and above) seen in their practice was primarily between 20 to 39% of their patients (16/23; 70%).

Consensus voting on the crucial recommendation statements is shown in → Table 1. More than 80% consensus was seen in 12 out of the 14 questions. For question no. 8 and 9 there was consensus in 65 and 70%, respectively.

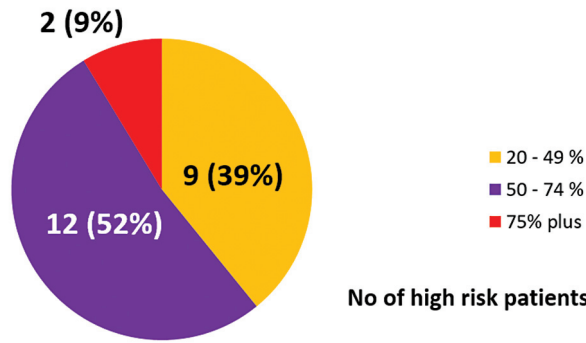


Fig. 1 Number of head and neck squamous cell carcinoma (HNSCC) patients at initial presentation, with high-risk features in real-world practice.

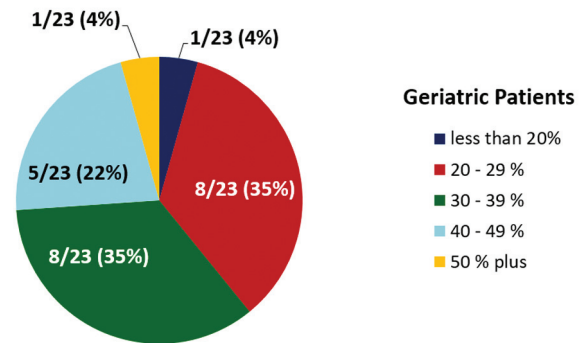


Fig. 2 Number of geriatric head and neck squamous cell carcinoma (HNSCC) patients in real-world practice (age 60 year and above).

Discussion

Patients of HNSCC from India (and other LMICs) are different from what is seen in the developed western world.^{31,33} Our

key challenges are younger age of patients, trismus, field cancerization (tobacco related), multiple primaries, and aggressive nature of the disease.³⁴ For instance, in India, oral cancer is more common primary and is predominantly

Table 1 Voting distribution on guideline recommendations by committee experts

Question no.	Question	Yes	No	Abstain
1	Of all the strategies/drugs available to inhibit EGFR in HNSCC patients, cetuximab continues to remain the best medication (to inhibit EGFR)	22 (95.7%)	00	01
2	Cetuximab has a role in both cisplatin-eligible and cisplatin-ineligible patients of HNSCC	19 (82.6%)	04	00
3	Cetuximab used once every 2 weeks (instead of weekly) is effective, safe, and convenient	20 (87%)	01	02
4	In case of hypersensitivity to cetuximab it has been still possible to use it by increasing premedication and reducing the infusion rate	20 (87%)	02	01
5	When EXTREME protocol is compared with TPEX protocol the latter is less toxic and easier to manage. So I do not use 1,000 mg 5-FU infusion × 4 days or cisplatin 100 mg on day 1 - in my real-world practice	21 (91.3%)	02	00
6	Cetuximab-based combinations have been especially effective in Asian and Indian patients as shown by Ankur Bahl publication and Change-2 studies	20 (87%)	00	03
7	Both EXTREME and Keynote 048 data show that their respective drugs can be used in the first line of advanced or metastatic HNSCC	23 (100%)	00	00
8	Immuno-oncology strategies are less effective in patients with oral cancer, which form the bulk of patients in India	15 (65%)	03	05
9	When using immune-oncology drugs, the risk of hyperprogression is underestimated. It is found to occur in 14.5% of patients and is associated with worse outcome	16 (70%)	03	04
10	Cetuximab combinations are safe and effective in geriatric patients who are fit to receive systemic therapy	23 (100%)	00	00
11	Right sequencing of cetuximab-based regimen and immune-oncology regimen have shown to result in median OS of 21.9 months	22 (95.7%)	00	01
12	The published retrospective data showing that in the first-line cetuximab combinations followed by immune-oncology drugs give RR (63%) as compared with immune-oncology drugs followed by cetuximab combinations (37%) with p = 0.028 is the only direct comparison	21 (91.3%)	00	02
13	The published retrospective data showing that in the second-line cetuximab combinations followed by immune-oncology drugs give RR (73%) as compared with immune-oncology drugs followed by cetuximab combinations (37%) with p = 0.002, is the only direct comparison	19 (82.6%)	00	04
14	ENZ-124 (biosimilar cetuximab) has received DCGI (Indian regulator) approval after providing data that meets international standards	19 (82.6%)	00	04

Abbreviations: DCGI, Drugs Controller General of India; EGFR, epidermal growth factor receptor; 5-FU, 5-fluorouracil; HNSCC, head and neck squamous cell carcinoma; OS, overall survival; RR, response rate; TPEX, TPEXtreme.

Table 2 Impact of progress in the management of recurrent and metastatic HNSCC on overall survival (OS)³⁴

Year	Rx strategy	Overall survival
1970s	Conventional CT	6 mo
1980s	CT combinations	10 mo
2008	Extreme regimen (platinum refractory or second line)	11 mo
2019	TPEX (and other combinations in first line)	14 mo
2020	TPEX >> ICI	21 mo

Abbreviations: CT, chemotherapy; HNSCC, head and neck squamous cell carcinoma; ICI, immune checkpoint inhibitors; Rx, radiotherapy; TPEX, TPEXtreme.

related to tobacco chewing. In the western countries, HNSCC is often caused by human papillomavirus (HPV) infection. Among oral cancers, tobacco users are also found to have poorer survival (43% vs. 72% in nontobacco users).³⁴

Today, HNSCC can be divided into two broad categories, based on the status of HPV infection^{35,36}:

1. HPV-positive (transcriptionally active) commonly in the oropharyngeal region, have wild-type TP53 and belong to the favorable group. They frequently also have loss of tumor necrosis factor receptor-associated factor 3 (*TRAF3*) and amplification of E2F transcription factor 1 (*E2F1*). Other molecular alterations of importance in this group are mutations in fibroblast growth factor receptor 3, KRAS proto-oncogene GTPase, DEAD-box helicase 3 X-linked, *FBXW7*, *NOTCH1*, and *PIK3CA*.
2. HPV-negative tumors, commonly expressing high chromosomal instability, with *TP53* mutated and belong to the unfavorable group. They also have alterations in cyclin-dependent kinase inhibitor 2A (*CDKN2A*)

Having said that, the HPV-positive group also contains a subset of patients with high chromosomal instability and varied HPV expression, whose prognosis may not be favorable. This group also has other mutations in discoidin domain receptor tyrosine kinase 2, lysine methyltransferase 2D/2C (*MLL2/3*), F-box and WD repeat domain containing 7 (*FBXW7*), notch receptor 1 (*NOTCH1*), nuclear receptor binding SET domain protein 1, phosphatidylinositol-4,5-bisphosphate 3-kinase catalytic subunit α (*PIK3CA*), loss of 3p, and amplification of 11q13 and 7p11. These have important implications for the targeting of cyclin D1 and EGFR.

Although HPV status provides prognostic information, it is not shown to predict therapy response, and so is not helpful for assigning first-line therapy in patients with HNSCC. On the other hand, EGFR has important prognostic and predictive value.^{37,38} In the TCGA NHSC study, 17/232 (7.33%) had somatic EGFR mutations.³⁹ In addition, the upregulation of *EGFR* and associated receptor/ligands was frequent. The G protein receptor signaling polymorphisms of EGFR intron 1 and *EGFR* amplification are mechanisms by which *EGFR* expression is increased. Downstream effectors also influence EGFR-dependent autophosphorylation.

The standard definitive primary treatment for patients with HNSCC is surgical excision or radical RT for early stages of the disease. If the disease is locally advanced, it is

chemotherapy (CT) or CRT. Adding targeted agents to any of the above improves both locoregional control as well as OS. When radical surgery can be avoided, patients benefit from organ preservation. If and when the disease recurs or becomes metastatic (seen in 10% of patients at initial presentation), treatment is primarily systemic (platinum compounds, taxane compounds, 5-fluorouracil [5-FU]), targeting EGFR and/or immune checkpoint inhibitors (ICIs). Progress in the management of recurrent and metastatic HNSCC is shown in **Table 2**.

Strategies to inhibit EGFR include monoclonal antibodies (CTX, zalutumumab, panitumumab, and nimotuzumab) or small molecular tyrosine kinase inhibitors (gefitinib, erlotinib, and lapatinib).^{26,27,35,36,38,40} CTX is of particular interest since it targets the extracellular domain of EGFR; blocks proliferative, antiapoptotic, and proangiogenic signals; as well as provides the best OS with less toxicity. The factors in favor of CTX include effective blockage, untethering of the receptor monomer, inhibition of dimerization, halting the activation of the tyrosine kinase domain, and therefore blocking the proliferative signaling through RAS and ERK. CTX also leads to internalization and degradation of EGFR, and has additional antibody-mediated cytotoxicity. The synergistic effects of CTX include radiation-induced apoptosis (blocking deoxyribonucleic acid repair via PI3K/AKT, JAK/STAT, and MAPK/ERK pathways).

Treatment for individual patients is personalized based on several factors. This includes tumor factors (stage, grade, molecular characteristics, biomarkers), patient factors (age, fitness, performance status, comorbidities, polypharmacy), and goals of therapy (cure, OS, quality of life [QoL], least out-of-pocket expenses, specific side effects to be avoided, and convenient hospital visit schedule). For instance, comorbidities are seen in as many as 57% of our patients with HNSCC.³⁴

The standard guidelines-directed conventional approach in HNSCC has several limitations. Surgery can lead to removal of vital organs and disfigurement. RT may cause mucositis, xerostomia, and osteoradionecrosis. Platinum-based CT also has significant toxicities—patients do not tolerate the standard 5-day infusion of 5-FU along with 100 mg of cisplatin on day 1 (highly emetogenic). The triplet regimen of docetaxel, cisplatin, and 5-FU (TPF) may offer the chance of an even better OS, but at the cost of higher toxicity and even significant risk of death.^{41,42} As mentioned earlier, Indian patients tend to have aggressive disease, higher tumor burden, compromised nutritional status, and often require a rapid

Table 3 Treatment options in advanced HNSCC based on cisplatin eligibility

No.	Cisplatin-eligible	Cisplatin-ineligible
1	Cisplatin single agent – 3 weekly cisplatin 100 mg/m ²	Cetuximab – weekly or 2 weekly
2	Cisplatin + infusional 5-FU	Nimotuzumab – weekly
3	Cisplatin + cetuximab	Carboplatin+ infusional 5-FU
4	Cisplatin + paclitaxel	Carboplatin + paclitaxel
5	Cisplatin + nimotuzumab	Extreme
6	Extreme	
7	TPEX	

Abbreviations: 5-FU, 5-fluorouracil; HNSCC, head and neck squamous cell carcinoma; TPEX, TPEXtreme.

response. Achieving symptomatic relief is as important as OS in our patients whose condition is complicated by significant pain and foul odor, especially in those with bulky disease. With most centers having long surgical waiting lists (often extending up to 6 weeks and beyond), the induction/neoadjuvant therapy approach is very attractive. Neoadjuvant systemic therapy (NAST; CT plus targeted therapy, e.g., CTX) offers better objective response rate (ORR) than RT with comparable OS.⁴³ Response to neoadjuvant CT predicted response to further treatment, and responders also have a better OS.^{44–46} Prospective randomized studies have confirmed that NAST plus RT offers better OS (70%) along with organ preservation—as compared with standard surgery plus RT.^{47,48} Patients with advanced HNSCC can be broadly divided into those who are eligible for cisplatin and those that are not (►Table 3).

Some patients are unable to receive platinum compounds (e.g., poor performance status, geriatric age group, significant comorbidities, polypharmacy, and prior use of platinum-based CT).⁴⁹ A systematic review of 24 studies included 4,450 locally advanced HNSCC (LAHNSCC) patients who were cisplatin-ineligible. The majority were treated with CTX plus RT (50.3%).⁴⁹

Cetuximab in HNSCC

CTX continues to have an important role in the management of HNSCC at various stages and circumstances, even after 18 years of its first approval for this indication.⁵⁰ A recent systematic review looked at all phase III clinical studies using anti-EGFR monoclonal antibodies (CTX, nimotuzumab, zalutumumab, and panitumumab).⁵¹ Maximum data was for CTX (only one trial looked at each of the other three targeted agents). When CTX was added to radical RT in patients with LAHNSCC, there was better OS, progression-free survival (PFS), and locoregional control, as compared with RT alone. As per the National Comprehensive Cancer Network guidelines Ver4.2024, the prominent role of CTX continues as part of preferred regimen, other recommended regimen, and regimen for specific circumstances as primary therapy, as neoadjuvant therapy, after neoadjuvant therapy, as postoperative systemic therapy, as well as therapy for metastatic/recurrent/persistent disease (►Table 4).⁵² No wonder, CTX plus combination CT is integral part of guidelines as one of the important standards of care in recurrent and metastatic HNSCC (European Head and Neck

Society–European Society for Medical Oncology – European Society for Radiotherapy and Oncology guidelines).⁵³

CTX was initially administered weekly. Now, we have data (prospective studies as well as in the real world) that confirms that CTX given every 2 weeks provides comparable efficacy and safety.⁵⁴ This has therefore become standard of care and also received regulatory approval. The advantages are obvious—patient convenience, more efficient use of human resources, and cost reduction.

CTX-based regimen provides faster symptom control as well better response, especially in patients with oral cancer. When used in the neoadjuvant setting, CTX plus CT followed by CRT shows 3-year OS of 74%.⁵⁵ CTX also has a pivotal role for tumors at “dangerous” sites (those that can cause bleeding or suffocation).³⁴ It is also rational that molecular alterations in *KRAS* are of predictive value for response to CTX. And the corollary is that resistance to CTX is caused by mutations in the RAS downstream signaling pathway.^{56,57} When treated with CTX, patients demonstrate significant changes in T cell receptor expression both in tumor tissue and the peripheral blood. Liquid biopsy can therefore be done to assess CTX response in a noninvasive manner. Using machine learning algorithms and artificial intelligence will help monitor clonal composition, three-dimensional alterations, and changes in organoids—features that can help ascertain resistance mechanisms and anticipate tumor progression.⁵⁸

However, multiple studies support the efficacy of CTX + CT irrespective of biomarker.^{38,59–61} In case patients develop hypersensitivity to CTX, data suggests that those with grade 2 toxicity can be rechallenged. This strategy requires increase in dose of the premedication (dexamethasone, famotidine, diphenhydramine, and acetaminophen) along with reduction of the infusion rate.⁶²

A prognostic scoring allows us to identify patients that are most likely to benefit from combination of CTX with polychemotherapy (performance status [PS] 0 or 1; normal C-reactive protein [CRP], normal leukocyte level, appropriate dose intensity, and relapse occurring more than 12 months after initial therapy).⁶³ Patients with 0 to 1 risk factors had a median OS of 13.6 months compared with a median OS of less than 1 month for patients 4 to 5 risk factors ($p < 0.001$). Scoring was assigned using the cutoff values of five laboratory values (CRP, leukocytes, hemoglobin, thrombocytes, and

Table 4 Place of cetuximab in systemic therapy of HNSCC – what does NCCN guidelines Ver4.2024 recommend?⁵²

1	Preferred regimen		Cetuximab – platinum (cisplatin/carboplatin + 5-FU)
2	Other recommended regimen		Single agent cetuximab
3	Useful in certain circumstances	As primary therapy	Cetuximab + nivolumab
			Cetuximab + pembrolizumab
			Cetuximab + paclitaxel
			Cetuximab + docetaxel as primary
			Cetuximab + RT as primary treatment
		As neo-adjuvant (induction) therapy	Cetuximab + carboplatin/paclitaxel
			Cetuximab + carboplatin + paclitaxel
		After neoadjuvant (induction) therapy	Cetuximab + RT
		For recurrent/persistent disease	Cetuximab + RT
		Postoperative systemic therapy + RT	Cetuximab + docetaxel (in cases of positive margin, extranodal extension or cisplatin ineligibility)

Abbreviations: 5-FU, 5-fluorouracil; HNSCC, head and neck squamous cell carcinoma; NCCN, National Comprehensive Cancer Network; RT, radiotherapy.

gamma-glutamyl transferase) plus three clinical factors (age less than 60.5 years; Eastern Cooperative Oncology Group Performance Status 0 or 1; and later recurrence).

The EXTREME Study

In the prospective phase III EXTREME trial, 442 patients with recurrent or metastatic HNSCC were randomized to CT plus CTX ($N=222$) versus CT alone ($N=220$). CT consisted of cisplatin 100 mg/m² or carboplatin area under the curve (AUC) 5 on day 1 along with 5-FU 1,000 mg/m² infusion on days 1 to 4.⁵⁹ The study arm received CTX as initial dose of 400 mg/m² intravenously and then weekly at 250 mg/m². CTX maintenance was continued till disease progression or unacceptable toxicity. The primary endpoint was OS. The study met its primary endpoint (median OS of 10.1 months with CTX + CT vs. 7.4 months with CT alone; $p=0.04$; hazard ratio [HR] 0.80; confidence interval [CI] 0.64–0.99). Subgroup analysis showed that maximum benefit was seen for patients with oral cancers (median OS of 11 vs. 4.4 months; HR 0.42; CI 0.26–0.67)⁵⁹

The TPEXtreme (TPEX) study was a prospective phase III trial that had CTX in both arms.⁶⁴ It randomized 539 patients with recurrent or metastatic HNSCC that were not suitable for locoregional treatment in a 1:1 fashion. The difference was in the CT schedule, the TPEX CT consisting of four cycles of cisplatin and docetaxel (both at 75 mg/m²; the 5-FU of EXTREME schedule being replaced with docetaxel) in the study arm. The median OS was 14.5 months in the TPEX arm and 13.4 months in the control arm (EXTREME protocol).^{59,64} The p -value was 0.15 with HR of 0.87 and CI of 0.71 to 1.05. Various parameters of the two studies are compared in **Table 5**. While there was no difference in OS, it is interesting to note that both arms had a median OS significantly better than in the original EXTREME study. The TPEX trial was able to provide the same efficacy outcome with significantly lower toxicity and better dose intensity. It is of particular importance for those with compromised cardiac condition as well as is a convenient scheduling not requiring hospitalization. **Table 5** summarizes the key differences between EXTREME and TPEX trials.

Table 5 Key differences between EXTREME and TPEX trials^{59,64}

Parameter	EXTREME trial	TPEX trial
CT schedule difference	4 days of 5-FU infusion	1 day docetaxel infusion
CT cycles difference	6	4
CTX schedule difference	Weekly	Once in 2 weeks
Patients maintaining dose intensity (planned cycles)	44%	72%
Adverse events (grade 3 or more)	81%	93%
Important contraindications	Cardiotoxicity/GI toxicity	GI toxicity
Quality of life		Better global health status, physical functioning

Abbreviations: CT, chemotherapy; CTX, cetuximab; 5-FU, 5-fluorouracil; GI, gastrointestinal; TPEX, TPEXtreme.

Table 6 Cetuximab trials of importance^{15,16,59,64}

Serial no.	Trial	Key learnings
1	EXTREME trial	Cetuximab + cisplatin/5-FU enhances outcome in recurrent/metastatic HNSCC
2	CHANGE-2 trial	Cetuximab + platinum-based CT shows better results in oral cavity subgroup in Asian patients
3	TP-EXTREME trial	Platinum + docetaxel + cetuximab provides OS comparable to EXTREME data
4	ENCORE trial	Cetuximab + platinum-based CT reproduces EXTREME benefit in the real-world setting

Abbreviations: CT, chemotherapy; 5-FU, 5-fluorouracil; HNSCC, head and neck squamous cell carcinoma.

These findings were reproduced in several trials, of which Change-2 and Encore stand out.^{15,16} How CTX was associated with immunogenicity leading to a better immune response was also documented.¹⁷ Key learnings from some of the important CTX-based trials are shown in **Table 6**.

Asian Patients

CTX + CT has demonstrated a consistent ORR and OS benefit in Asian populations; in clinical trials and the real world.^{15,18,19} The Change-2 trial showed that OS was better in Asian patients, especially those with oral HNSCC.¹⁵ Similar benefit was also seen in Indian patients, again in real world as well as trial setting as shown in **Fig. 3**.^{20,21} An Indian prospective study with CTX ± CT have shown response rate (RR) > 45% and better QoL (improvement in pain, speech, swallowing, and social eating), features that are extremely useful for palliation.

Immune Checkpoint Inhibitors in HNSCC

One first-line (KEYNOTE-048) and several second-line trials (CheckMate-141, KEYNOTE-012, KEYNOTE-055, and KEYNOTE-040) have proved the place of ICIs in HNSCC.^{22-24,65} Nivolumab and pembrolizumab are approved for use in second-line setting without checking for programmed death ligand-1 (PD-L1) expression.²⁵ If checked, the PD-L1 score requires appropriate reagents, hardware, and calculation (e.g., tumor proportion score, combined positive score [CPS]).^{66,67}

The first-line Keynote 048 study compared pembrolizumab alone versus pembrolizumab with CT versus CTX with CT (EXTREME protocol) in 1:1:1 randomization for recurrent and metastatic HNSCC in an open-labeled phase 3 fashion. It

demonstrated OS in intent to treat (ITT) and those with CPS > 20 to be better for patients that received pembrolizumab. While this is true for HNSCC as a heterogeneous group, the OS for patients is worse for patients with oral cavity tumors, a site that forms the bulk of patients in India. Whether these cases have unique immune-evasion mechanisms remain unknown at present.

There is also a risk of hyperprogression with ICI that is not well appreciated. Its incidence has been documented to be 15.4% and is associated with poorer OS and PFS.⁶⁶⁻⁶⁹ Only in a small fraction of heavily treated patients, do these agents result in long-lasting responses. This comes at the cost of lower overall RR, potentially life-threatening immune-related adverse events, chance of hyperprogression, and high costs. In a Korean study of 125 patients, there were 68 (54.4%) patients whose “best” response was progressive disease. Hyperprogressive disease (HPD) was seen in 18 of them (26.5% of 68 progressors; 14.4% of all 125 patients). HPD was associated with younger age, oral HNSCC, and prior irradiation ($p = 0.040, 0.027, \text{ and } 0.015$, respectively). Those that develop HPD also had shorter PFS (1.2 vs. 3.4 months, $p < 0.001$) as well as OS (3.4 vs. 10.7 months, $p = 0.047$).⁷⁰

Sequencing of Therapy

Both the first-line phase III trials (EXTREME and Keynote 048) demonstrated similar overall results. Indirect comparison of their OS and PFS showed consistent outcomes regardless of CPS. Hence, it is important to look at the right sequencing. We can either use CTX-based combination first followed by ICI, or vice versa.⁷¹

One study has shown that nivolumab improves response, regardless of prior CTX exposure.⁷² Having said that, improvement in the OS with nivolumab was greater in patients without prior CTX treatment.

There are also several studies using CTX monotherapy or combination therapy after HNSCC patients progress while on programmed cell death protein 1 inhibitors.⁷³⁻⁷⁵ Early results indicate that salvage therapy with CTX + CT combinations after PD-L1 inhibitors is associated with good RRs, manageable safety profile, and no treatment-related mortality.^{73,74} Another study used paclitaxel plus CTX (7/10, 70%) or S-1 (3/10, 30%) following nivolumab treatment and showed fairly good RR (60%), clinical benefit rate (90%), and median PFS (5.4 months).⁷⁶ Thus, CTX continued to show positive outcomes even when used after ICI.

The choice also depends on the individual patient's condition and preferences. For example, previous CTX

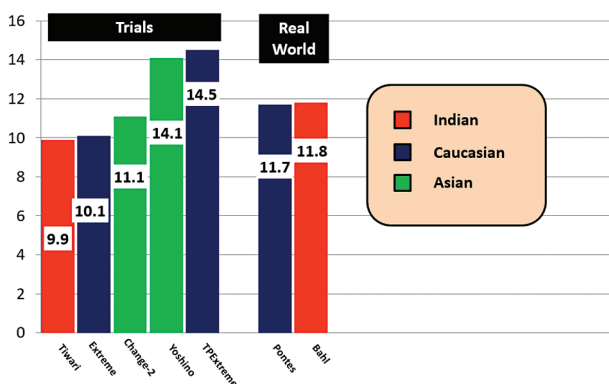
**Fig. 3** Median overall survival in cetuximab combination regimen.

Table 7 Which is better sequencing? CTX followed by IO or vice versa?⁷¹

	First-line Rx			Second-line Rx		
	IO followed by CTX	CTX followed by IO		IO followed by CTX	CTX followed by IO	
ORR	13 (37)	29 (73)	$p = 0.002$	13 (37)	25 (63)	$p = 0.028$
DCR	22 (65)	31 (78)	$p = 0.17$	18 (51)	31 (78)	$p = 0.018$
Median OS	22.8 mo	23.7 mo				

Abbreviations: CTX, cetuximab; DCR, disease control rate; IO, immunotherapy; ORR, objective response rate; OS, overall survival; Rx, radiotherapy.

maintenance given for more than 3 months was predictive of better OS. On the other hand, routine continuation of CTX after progressive disease following EXTREME regimen is not recommended.

So which drug should we use first to optimize sequencing? When prospective randomized head-to-head comparison is not available (nor is such a study likely to be done), we have to decide based on available real-world data. A retrospective study done in 75 patients with recurrent and/or metastatic patients conducted between 2017 and 2020 give us the answer (→Table 7). When OS is similar, the focus shifts to RR and symptom alleviation. When CTX is given first, and then ICI, ORR is significantly better. This provides better symptom control and palliation, key to patients at this stage in their disease.

After Definitive Surgery/RT/CRT

Adjuvant RT is used only in patients with adverse features. For patients with extranodal extension, positive margin, large primary tumors (pT3 or pT4), nodal extension (pN2 or pN3), disease in levels IV or V nodes, and perivascular/perineural/lymphatic invasion, adjuvant CTX containing systemic therapy is a recommended option.⁷⁷ Patients with recurrent or persistent disease are candidates for treatment with palliative intent. Besides CTX+CT, patient management should include symptomatic relief, pain control, and improvement in nutrition. Reirradiation can be considered provided there are no significant comorbidities, previous treatment did not cause unacceptable toxicity, and sufficient time has elapsed following the initial RT.⁴³

Special CTX Considerations

Biosimilar CTX and the Regulatory Requirements

HNSCC patients in India often face financial challenges, just as seen in other parts of the world. Any opportunity at maintaining efficacy while reducing cost is welcome. The best to do so is with the use of a biosimilar CTX.

For regulatory approvals, biosimilars must have a customized unique manufacturing process that is well documented right from the cell line creation; following specified step-by-step formulation, all the way to the final finished product through a patented continuous manufacturing process. The biosimilar medicine needs to be highly similar, but not exactly the same, as the reference “original” biological agent.⁷⁸ Biosimilars need to comply with the standards of pharmaceutical quality, safety, and efficacy that apply to all

biological medicines. While doing so, we cannot lose sight of why biosimilars are required. They play a vital role to increase therapeutic options and access to patients while simultaneously reducing cost. The global regulatory authorities (United States Food and Drug Administration, European Medicines Agency, Central Drugs Standard Control Organisation [CDSCO]) have therefore clearly specified that more is the preclinical data, less is the requirement for patient trials.^{79–81}

On January 18, 2019, Enzene Biosciences Limited (fully owned subsidiary of Alkem Laboratories Limited), received approval to do biosimilar trial for ENZ-124 (recommendations of Subject Expert Committee [Oncology and Hematology], made at its 79th meeting held on January 18, 2019 at CDSCO HQ, New Delhi, India).

This prospective phase III study (for regulatory approval), compared CTX biosimilar ENZ-124 to the original molecular in a 2:1 randomization.⁸² The patient characteristics and pharmacokinetic parameters (C_{max} , AUC_{0-t}) were comparable. The study met its efficacy endpoints. The safety analysis showed that ENZ-124 resulted in fewer acne skin rashes, 16/120 (13.3%) versus 11/60 (18.3%). The other safety features (treatment-emergent adverse events, serious adverse events) and immunogenicity (anti-CTX antibody levels) were similar.

The data proved to be in compliance with regulatory requirements, and the Drugs Controller General of India (DCGI) gave marketing approval to ENZ-124 (CDSCO Form 22; File No. BIO/MA/22/000101 dated January 23, 2023).⁸³ It is important to note that current DCGI’s biosimilar approval requirements are also in line with European and American standards. ENZ-124 was launched in May 2023 in India under the name of Cetuxa, providing substantial cost relief to our patients (INR 9,391 vs. 91,661 [Erbix] for each 100 mg vial).^{84,85} Other CTX biosimilars have also been able to prove equivalence and obtained regulatory approval.⁸⁶

Older Patients and Cetuximab

Can biologically fit geriatric patients be given EXTREME protocol safely? In a study of 85 patients with a median age of 75 years (72–79), 44 also received CTX as maintenance.⁸⁷ The study showed that treatment was well tolerated and beneficial in older patients who had recurrent or metastatic HNSCC and were found to be fit using geriatric evaluation tools.

Other Combinations with Cetuximab

CTX has been studied in combination with photodynamic therapy, alpelisib and ribociclib.^{88–91} There is also interest in

using fluorescence to guide the extent of surgical resection. A study using CTX-800CW systemically showed a sensitivity of 100% (4/4 tumor-positive margins) and specificity of 91% (10/11 tumor-negative margins).⁹² For patients recurring after CTX therapy, there is a possibility of HER2 and HER3 overexpression. This can be suppressed by the activation of the MET/MAPK pathway. This should be taken into consideration while deciding the next line of therapy for such patients.

Off-Label Use

There is a lot of interest in using expensive medications at lower doses. The primary reason is to save on costs, especially when it involves ICIs like nivolumab.^{93–95} Such use has not received regulatory approval and should be used with caution.

Conclusion

Since most of our HNSCC patients are diagnosed in advanced stages, aim of their management includes improving OS, preserving QoL, and delaying the development of progressive disease/recurrence. Cancer-directed systemic therapy is the main approach. CTX with CT (EXTREME protocol; TPEX regimen) are the standard of care that prolongs OS and maintains QoL. Personalized modifications help in further improving QoL, lowering toxicity, and providing a more patient-friendly scheduling.⁹⁶

Salient features to keep in mind are:

1. Each patient with HNSCC is unique
2. CTX + CT provides flexible options, allowing treatment to be tailored to the patient
3. Biosimilar CTX available in India meets regulatory approval as per international standards
4. In oral cavity tumors, CTX + CT has shown superior outcomes compared with other sites
5. Pembrolizumab + CT and pembrolizumab monotherapy outcomes are dependent on CPS
6. Hyperprogression with ICIs is underestimated—seen in 15.4% of HNSCC patients
7. Sequencing with CTX-based regimen in first line followed by immunotherapy in second line, gives longest OS—reaching 21.9 months

To provide the best possible outcome, such patients need the involvement of various stakeholders at relevant time points during their treatment. These include one or more of dentists, maxillofacial surgeon, medical oncologist, surgical oncologist, radiation oncologist, interventional radiologist, palliative care specialist, oncopathologist, speech therapist, counselor, geneticist/molecular oncologist, nurse, support groups, patients, and their caregiver and family members.

Our practical consensus guidelines on the use of CTX in HNSCC will strengthen the hands of the community oncologist in arriving at the right choice.

Conflict of Interest

None declared.

References

- 1 Noronha V, Prabhash K, Babu KG, et al. Indian clinical practice consensus guidelines for the management of very advanced head-and-neck squamous cell carcinoma: update 2022. *Cancer Res Stat Treat* 2024;7(01):S31–S35
- 2 Gupta R, Pednekar MS, Kumar R, Goel S. Tobacco cessation in India-current status, challenges, barriers and solutions. *Indian J Tuberc* 2021;68S:S80–S85
- 3 Patil VM, Noronha V, Menon N, et al. Results of phase III randomized trial for use of docetaxel as a radiosensitizer in patients with head and neck cancer, unsuitable for cisplatin-based chemoradiation. *J Clin Oncol* 2023;41(13):2350–2361
- 4 Khadela A, Shah Y, Mistry P, Mansuri M, Sureja D, Bodiwala K. A review of efficacy and safety of cetuximab and bevacizumab-based monoclonal antibodies in head and neck cancer. *Med Oncol* 2022;40(01):66
- 5 Urba S, van Herpen CML, Sahoo TP, et al. Pemetrexed in combination with cisplatin versus cisplatin monotherapy in patients with recurrent or metastatic head and neck cancer: final results of a randomized, double-blind, placebo-controlled, phase 3 study. *Cancer* 2012;118(19):4694–4705
- 6 Noronha V, Joshi A, Patil VM, et al. Once-a-week versus once-every-3-weeks cisplatin systemic therapy/RT for locally advanced head and neck cancer: a phase III randomized noninferiority trial. *J Clin Oncol* 2018;36(11):1064–1072
- 7 Patel B, Saba NF. Current aspects and future considerations of EGFR inhibition in locally advanced and recurrent metastatic squamous cell carcinoma of the head and neck. *Cancers (Basel)* 2021;13(14):3545
- 8 Agulnik M. New approaches to EGFR inhibition for locally advanced or metastatic squamous cell carcinoma of the head and neck (SCCHN). *Med Oncol* 2012;29(04):2481–2491
- 9 Bonner JA, Harari PM, Giralt J, et al. Radiotherapy plus cetuximab for squamous-cell carcinoma of the head and neck. *N Engl J Med* 2006;354(06):567–578
- 10 Kao J, Genden EM, Gupta V, et al. Phase 2 trial of concurrent 5-fluorouracil, hydroxyurea, cetuximab, and hyperfractionated intensity-modulated radiation therapy for locally advanced head and neck cancer. *Cancer* 2011;117(02):318–326
- 11 Suntharalingam M, Kwok Y, Goloubeva O, et al. Phase II study evaluating the addition of cetuximab to the concurrent delivery of weekly carboplatin, paclitaxel, and daily radiotherapy for patients with locally advanced squamous cell carcinomas of the head and neck. *Int J Radiat Oncol Biol Phys* 2012;82(05):1845–1850
- 12 Seiwert TY, Melotek JM, Blair EA, et al. Final results of a randomized phase 2 trial investigating the addition of cetuximab to induction chemotherapy and accelerated or hyperfractionated chemoradiotherapy for locoregionally advanced head and neck cancer. *Int J Radiat Oncol Biol Phys* 2016;96(01):21–29
- 13 Mesía R, Garcia-Saenz JA, Lozano A, et al; Spanish Head And Neck Cancer Cooperative Group. (Study TTCC-2007/02). Could the addition of cetuximab to conventional radiation therapy improve organ preservation in those patients with locally advanced larynx cancer who respond cooperative group phase 2 study. *Int J Radiat Oncol Biol Phys* 2017;97(03):473–480
- 14 Bonner J, Giralt J, Harari P, et al. Cetuximab and radiotherapy in laryngeal preservation for cancers of the larynx and hypopharynx: a secondary analysis of a randomized clinical trial. *JAMA Otolaryngol Head Neck Surg* 2016;142(09):842–849
- 15 Guo Y, Luo Y, Zhang Q, et al. First-line treatment with chemotherapy plus cetuximab in Chinese patients with recurrent and/or metastatic squamous cell carcinoma of the head and neck: efficacy and safety results of the randomised, phase III CHANGE-2 trial. *Eur J Cancer* 2021;156:35–45
- 16 Le Tourneau C, Ghiani M, Cau MC, et al. First-line cetuximab + platinum-based therapy for recurrent/metastatic head and neck squamous cell carcinoma: a real-world observational study-ENCORE. *Cancer Rep (Hoboken)* 2023;6(05):e1804

- 17 De Azevedo J, Mourtada J, Bour C, et al. The EXTREME regimen associating cetuximab and cisplatin favors head and neck cancer cell death and immunogenicity with the induction of an anti-cancer immune response. *Cells* 2022;11(18):2866
- 18 Yoshino T, Hasegawa Y, Takahashi S, et al. Platinum-based chemotherapy plus cetuximab for the first-line treatment of Japanese patients with recurrent and/or metastatic squamous cell carcinoma of the head and neck: results of a phase II trial. *Jpn J Clin Oncol* 2013;43(05):524–531
- 19 Pontes F, Garcia AR, Domingues I, et al. Survival predictors and outcomes of patients with recurrent and/or metastatic head and neck cancer treated with chemotherapy plus cetuximab as first-line therapy: a real-world retrospective study. *Cancer Treat Res Commun* 2021;27:100375
- 20 Bahl A, Bhatia K, Choudhary P, et al. Palliative chemotherapy with or without cetuximab in recurrent or metastatic squamous cell carcinoma of the head and neck: Indian tertiary care retrospective analysis. *Head Neck* 2020;42(05):955–962
- 21 Tiwari S, Goel V, John MC, Patnaik N, Doval DC. Efficacy and toxicity of cetuximab with chemotherapy in recurrent and metastatic head and neck cancer: a prospective observational study. *Indian J Cancer* 2016;53(04):487–492
- 22 Burtneess B, Harrington KJ, Greil R, et al; KEYNOTE-048 Investigators. Pembrolizumab alone or with chemotherapy versus cetuximab with chemotherapy for recurrent or metastatic squamous cell carcinoma of the head and neck (KEYNOTE-048): a randomised, open-label, phase 3 study. *Lancet* 2019;394(10212):1915–1928
- 23 Hobday SB, Brody RM, Kriegsman B, et al. Outcomes among patients with mucosal head and neck squamous cell carcinoma treated with checkpoint inhibitors. *JAMA Otolaryngol Head Neck Surg* 2022;148(10):918–926
- 24 Ferris RL, Blumenschein G Jr, Fayette J, et al. Nivolumab vs investigator's choice in recurrent or metastatic squamous cell carcinoma of the head and neck: 2-year long-term survival update of CheckMate 141 with analyses by tumor PD-L1 expression. *Oral Oncol* 2018;81:45–51
- 25 Fuereder T. Essential news of current guidelines: head and neck squamous cell carcinoma. *Memo* 2022;15:278–281
- 26 Dattatreya S, Goswami C. Cetuximab plus radiotherapy in patients with unresectable locally advanced squamous cell carcinoma of head and neck region—a open labelled single arm phase II study. *Indian J Cancer* 2011;48(02):154–157
- 27 Patil VM, Noronha V, Joshi A, et al. Comparison of paclitaxel-cetuximab chemotherapy versus metronomic chemotherapy consisting of methotrexate and celecoxib as palliative chemotherapy in head and neck cancers. *Indian J Cancer* 2017;54(01):20–24
- 28 Specenier P, Vermorken JB. Cetuximab: its unique place in head and neck cancer treatment. *Biologics* 2013;7:77–90
- 29 Baysal H, De Pauw I, Zaryouh H, et al. The right partner in crime: unlocking the potential of the anti-EGFR antibody cetuximab via combination with natural killer cell chartering immunotherapeutic strategies. *Front Immunol* 2021;12:737311
- 30 Aggarwal S, Vaid A, Ramesh A, et al. Practical consensus recommendations on management of HR + ve early breast cancer with specific reference to genomic profiling. *South Asian J Cancer* 2018;7(02):96–101
- 31 Parikh P, Babu G, Singh R, et al. Consensus guidelines for the management of HR-positive HER2/neu negative early breast cancer in India, SAARC region and other LMIC by DELPHI survey method. *BMC Cancer* 2023;23(01):714
- 32 Niederberger M, Spranger J. Delphi technique in health sciences: a map. *Front Public Health* 2020;8:457
- 33 Parikh PM, Aggarwal S, Biswas G, et al. Practical clinical consensus guidelines for the management of cancer associated anemia in low- and middle-income countries. *South Asian J Cancer* 2023;12(02):93–99
- 34 Prabhaskar K, Babu G, Chaturvedi P, et al. Indian clinical practice consensus guidelines for the management of squamous cell carcinoma of head and neck. *Indian J Cancer* 2020;57(Feb, Supplement):S1–S5
- 35 Bonner JA, Mesia R, Giralt J, et al. p16, HPV, and cetuximab: what is the evidence? *Oncologist* 2017;22(07):811–822
- 36 Johnson DE, Burtneess B, Leemans CR, Lui VWY, Bauman JE, Grandis JR. Head and neck squamous cell carcinoma. *Nat Rev Dis Primers* 2020;6(01):92
- 37 Echarri MJ, Lopez-Martin A, Hitt R. Targeted therapy in locally advanced and recurrent/metastatic head and neck squamous cell carcinoma (LA-R/M HNSCC). *Cancers (Basel)* 2016;8(03):E27
- 38 Bossi P, Platini F. Radiotherapy plus EGFR inhibitors: synergistic modalities. *Cancers Head Neck* 2017;2:2
- 39 Katase N, Nishimatsu SI, Yamauchi A, Okano S, Fujita S. DKK3 expression is correlated with poorer prognosis in head and neck squamous cell carcinoma: a bioinformatics study based on the TCGA database. *J Oral Biosci* 2023;65(04):334–346
- 40 Stewart JS, Cohen EE, Licitra L, et al. Phase III study of gefitinib compared with intravenous methotrexate for recurrent squamous cell carcinoma of the head and neck [corrected]. *J Clin Oncol* 2009;27(11):1864–1871
- 41 Vokes EE. Induction chemotherapy for head and neck cancer: recent data. *Oncologist* 2010;15(Suppl 3):3–7
- 42 Patil VM, Prabhaskar K, Noronha V, et al. Neoadjuvant chemotherapy followed by surgery in very locally advanced technically unresectable oral cavity cancers. *Oral Oncol* 2014;50(10):1000–1004
- 43 Comet B, Kramar A, Faivre-Pierret M, et al. Salvage stereotactic reirradiation with or without cetuximab for locally recurrent head-and-neck cancer: a feasibility study. *Int J Radiat Oncol Biol Phys* 2012;84(01):203–209
- 44 Rooney M, Kish J, Jacobs J, et al. Improved complete response rate and survival in advanced head and neck cancer after three-course induction therapy with 120-hour 5-FU infusion and cisplatin. *Cancer* 1985;55(05):1123–1128
- 45 Schuller DE, Wilson HE, Smith RE, Batley F, James AD. Preoperative reductive chemotherapy for locally advanced carcinoma of the oral cavity, oropharynx, and hypopharynx. *Cancer* 1983;51(01):15–19
- 46 Ensley J, Crissman J, Kish J, et al. The impact of conventional morphologic analysis on response rates and survival in patients with advanced head and neck cancers treated initially with cisplatin-containing combination chemotherapy. *Cancer* 1986;57(04):711–717
- 47 Lefebvre JL, Chevalier D, Luboinski B, Kirkpatrick A, Collette L, Sahnoud TEORTC Head and Neck Cancer Cooperative Group. Larynx preservation in pyriform sinus cancer: preliminary results of a European Organization for Research and Treatment of Cancer phase III trial. *J Natl Cancer Inst* 1996;88(13):890–899
- 48 Wolf GT, Fisher SG, Hong WK, et al; Department of Veterans Affairs Laryngeal Cancer Study Group. Induction chemotherapy plus radiation compared with surgery plus radiation in patients with advanced laryngeal cancer. *N Engl J Med* 1991;324(24):1685–1690
- 49 Michelson I, Nachtigal GC, Dacoregio MI, et al. Treatment options for cisplatin-ineligible patients with locally advanced head and neck squamous cell carcinoma: a systematic review. *J Cancer Res Clin Oncol* 2024;150(08):379
- 50 Chen TH, Pan YY, Lee TL, et al. Treatment outcomes of cetuximab-containing regimen in locoregional recurrent and distant metastatic head and neck squamous cell carcinoma. *BMC Cancer* 2022;22(01):1336
- 51 Nair LM, Ravikumar R, Rafi M, et al. Anti-epidermal growth factor receptor monoclonal antibody therapy in locally advanced head and neck cancer: a systematic review of phase III clinical trials. *Med Int (Lond)* 2024;4(04):41

- 52 NCCN reference Ver4.2024. Accessed August 21, 2024 at: https://www.nccn.org/professionals/physician_gls/pdf/head-and-neck.pdf
- 53 D'cruz A, Lin T, Anand AK, et al. Consensus recommendations for management of head and neck cancer in Asian countries: a review of international guidelines. *Oral Oncol* 2013;49(09):872–877
- 54 Bokemeyer C, Ciardiello F, Dubreuil O, et al. Cetuximab every 2 weeks versus standard weekly dosing administration schedule. *Future Oncol* 2024;20(07):393–407
- 55 Argiris A, Heron DE, Smith RP, et al. Induction docetaxel, cisplatin, and cetuximab followed by concurrent radiotherapy, cisplatin, and cetuximab and maintenance cetuximab in patients with locally advanced head and neck cancer. *J Clin Oncol* 2010;28(36):5294–5300
- 56 Diniz CHP, Henrique T, Stefanini ACB, De Castro TB, Tajara EH. Cetuximab chemotherapy resistance: insight into the homeostatic evolution of head and neck cancer (Review). *Oncol Rep* 2024;51(06):80
- 57 Weidhaas JB, Harris J, Schae D, et al. The KRAS-variant and cetuximab response in head and neck squamous cell cancer: a secondary analysis of a randomized clinical trial. *JAMA Oncol* 2017;3(04):483–491
- 58 Mahmood H, Shaban M, Rajpoot N, Khurram SA. Artificial intelligence-based methods in head and neck cancer diagnosis: an overview. *Br J Cancer* 2021;124(12):1934–1940
- 59 Vermorken JB, Mesia R, Rivera F, et al. Platinum-based chemotherapy plus cetuximab in head and neck cancer. *N Engl J Med* 2008;359(11):1116–1127
- 60 Vermorken JB, Trigo J, Hitt R, et al. Open-label, uncontrolled, multicenter phase II study to evaluate the efficacy and toxicity of cetuximab as a single agent in patients with recurrent and/or metastatic squamous cell carcinoma of the head and neck who failed to respond to platinum-based therapy. *J Clin Oncol* 2007;25(16):2171–2177
- 61 Bossi P, Miceli R, Locati LD, et al. A randomized, phase 2 study of cetuximab plus cisplatin with or without paclitaxel for the first-line treatment of patients with recurrent and/or metastatic squamous cell carcinoma of the head and neck. *Ann Oncol* 2017;28(11):2820–2826
- 62 Lofy M, Jung L, Dow-Hillgartner E. Premedication strategy in cetuximab rechallenge after Grade 2 hypersensitivity reactions. *J Oncol Pharm Pract* 2024;30(02):412–416
- 63 Magnes T, Melchardt T, Weiss L, et al. Prognostic score in patients with recurrent or metastatic carcinoma of the head and neck treated with cetuximab and chemotherapy. *PLoS One* 2017;12(07):e0180995
- 64 Guigay J, Aupérin A, Fayette J, et al; GORTEC AIO TTCC, and UniCancer Head and Neck groups. Cetuximab, docetaxel, and cisplatin versus platinum, fluorouracil, and cetuximab as first-line treatment in patients with recurrent or metastatic head and neck squamous-cell carcinoma (GORTEC 2014-01 TPEXtreme): a multicentre, open-label, randomised, phase 2 trial. *Lancet Oncol* 2021;22(04):463–475
- 65 Pfister DG, Haddad RI, Worden FP, et al. Biomarkers predictive of response to pembrolizumab in head and neck cancer. *Cancer Med* 2023;12(06):6603–6614
- 66 Paver EC, Cooper WA, Colebatch AJ, et al. Programmed death ligand-1 (PD-L1) as a predictive marker for immunotherapy in solid tumours: a guide to immunohistochemistry implementation and interpretation. *Pathology* 2021;53(02):141–156
- 67 Szturz P, Vermorken JB. Management of recurrent and metastatic oral cavity cancer: raising the bar a step higher. *Oral Oncol* 2020;101:104492
- 68 Li Y, Wang P, Xu J, Shi X, Yin T, Teng F. Noninvasive radiomic biomarkers for predicting pseudoprogression and hyperprogression in patients with non-small cell lung cancer treated with immune checkpoint inhibition. *Oncol Immunology* 2024;13(01):2312628
- 69 Ding P, Wen L, Tong F, Zhang R, Huang Y, Dong X. Mechanism underlying the immune checkpoint inhibitor-induced hyper-progressive state of cancer. *Cancer Drug Resist* 2022;5(01):147–164
- 70 Park JH, Chun SH, Lee YG, et al. Hyperprogressive disease and its clinical impact in patients with recurrent and/or metastatic head and neck squamous cell carcinoma treated with immune-checkpoint inhibitors: Korean cancer study group HN 18-12. *J Cancer Res Clin Oncol* 2020;146(12):3359–3369 Erratum in: *J Cancer Res Clin Oncol*. 2020 Dec;146(12):3371. doi: 10.1007/s00432-020-03342-3. PMID: 32671504
- 71 Yang CC, Lien CF, Hwang TZ, et al. Treatment sequences in patients with recurrent or metastatic head and neck squamous cell carcinoma: cetuximab followed by immunotherapy or vice versa. *Cancers (Basel)* 2022;14(10):2351
- 72 Ferris RL, Licitra L, Fayette J, et al. Nivolumab in patients with recurrent or metastatic squamous cell carcinoma of the head and neck: efficacy and safety in CheckMate 141 by prior cetuximab use. *Clin Cancer Res* 2019;25(17):5221–5230
- 73 Burcher KM, Bloomer CH, Gavrila E, et al. Study protocol: phase II study to evaluate the effect of cetuximab monotherapy after immunotherapy with PD-1 inhibitors in patients with head and neck squamous cell cancer. *Ther Adv Med Oncol* 2024;16:17588359231217959
- 74 Cabezas-Camarero S, Cabrera-Martín MN, Merino-Menéndez S, et al. Safety and efficacy of cetuximab-based salvage chemotherapy after checkpoint inhibitors in head and neck cancer. *Oncologist* 2021;26(06):e1018–e1035
- 75 Wakasaki T, Yasumatsu R, Uchi R, et al. Outcome of chemotherapy following nivolumab treatment for recurrent and/or metastatic head and neck squamous cell carcinoma. *Auris Nasus Larynx* 2020;47(01):116–122
- 76 Chevalier T, Daste A, Saada-Bouzd E, et al. Cetuximab combined with paclitaxel or paclitaxel alone for patients with recurrent or metastatic head and neck squamous cell carcinoma progressing after EXTREME. *Cancer Med* 2021;10(12):3952–3963
- 77 Kreinbrink PJ, Mierzwa ML, Huth B, et al. Adjuvant radiation and cetuximab improves local control in head and neck cutaneous squamous cell carcinoma: phase II study. *Head Neck* 2021;43(11):3408–3416
- 78 Bui LA, Hurst S, Finch GL, et al. Key considerations in the preclinical development of biosimilars. *Drug Discov Today* 2015;20(Suppl 1):3–15
- 79 Accessed August 17, 2024 at: <https://www.ema.europa.eu/en/human-regulatory-overview/biosimilar-medicines-overview#:~:text=A%20biosimilar%20is%20a%20biological,apply%20to%20all%20biological%20medicineslast>
- 80 Accessed August 17, 2024 at: <https://www.fda.gov/files/drugs/published/Biosimilar-Product-Regulatory-Review-and-Approval.pdf>
- 81 Accessed August 17, 2024 at: <https://cdsco.gov.in/opencms/resources/UploadCDSCOWeb/2018/UploadAlertsFiles/BiosimilarGuideline2016.pdf>
- 82 Dhamne N, Jain M, Nagarkar R, et al. Efficacy and safety of ENZ-124 versus innovator cetuximab in combination with platinum-based chemotherapy in patients with recurrent locoregional or metastatic squamous cell carcinoma of the head and neck (SCCHN). *Ann Oncol* 2023;34(Suppl 4):S1607–S1619
- 83 Accessed September 30, 2024 at: <https://cdsco.gov.in/opencms/resources/UploadCDSCOWeb/2018/UploadCTApprovals/2.%20Enzene%20Cetuximab.pdf>
- 84 Accessed September 30, 2024 at: <https://timesofindia.indiatimes.com/business/india-business/alkem-launches-worlds-1st-biosimilar-for-cetuximab/articleshow/100659457.cms>
- 85 Accessed September 30, 2024 at: <https://www.1mg.com/search/all?name=Cetuximab&st=cetuximab&sl=Cetuximab&s=Cetuximab>
- 86 Soulières D, Aguilar JL, Chen E, et al. Cetuximab plus platinum-based chemotherapy in head and neck squamous cell carcinoma:

- a randomized, double-blind safety study comparing cetuximab produced from two manufacturing processes using the EXTREME study regimen. *BMC Cancer* 2016;16:19
- 87 Guigay J, Le Caer H, Ferrand FR, et al; ELAN Group including Gustave Roussy, Unicancer GERICO and H&N groups, and GORTEC. Adapted EXTREME regimen in the first-line treatment of fit, older patients with recurrent or metastatic head and neck squamous cell carcinoma (ELAN-FIT): a multicentre, single-arm, phase 2 trial. *Lancet Healthy Longev* 2024;5(06):e392–e405
 - 88 van Caloen G, Schmitz S, van Marcke C, et al. Preclinical evaluation of the association of the cyclin-dependent kinase 4/6 inhibitor, ribociclib, and cetuximab in squamous cell carcinoma of the head and neck. *Cancers (Basel)* 2021;13(06):1251
 - 89 Peng W, de Bruijn HS, Ten Hagen TLM, et al. Targeted photodynamic therapy of human head and neck squamous cell carcinoma with anti-epidermal growth factor receptor antibody cetuximab and photosensitizer IR700DX in the mouse skin-fold window chamber model. *Photochem Photobiol* 2020;96(03):708–717
 - 90 Razak ARA, Wang HM, Chang JY, et al. A Phase 1b/2 study of alpelisib in combination with cetuximab in patients with recurrent or metastatic head and neck squamous cell carcinoma. *Target Oncol* 2023;18(06):853–868
 - 91 Voskuil FJ, de Jongh SJ, Hooghiemstra WTR, et al. Fluorescence-guided imaging for resection margin evaluation in head and neck cancer patients using cetuximab-800CW: a quantitative dose-escalation study. *Theranostics* 2020;10(09):3994–4005
 - 92 Novoplansky O, Fury M, Prasad M, et al. MET activation confers resistance to cetuximab, and prevents HER2 and HER3 upregulation in head and neck cancer. *Int J Cancer* 2019;145(03):748–762
 - 93 Patil VM, Noronha V, Menon N, et al. Low-dose immunotherapy in head and neck cancer: a randomized study. *J Clin Oncol* 2023;41(02):222–232
 - 94 Joris S, Fontaine C, Decoster L, et al. Efficacy of a flat low dose of nivolumab in advanced cancer: a retrospective case series. *Anti-cancer Res* 2022;42(03):1433–1437
 - 95 Patel A, Akhade A, Parikh P, et al. Pembrolizumab weight based dosing – a call for policy change. *Indian J Med Paediatr Oncol* 2022;43(03):306–310
 - 96 Guigay J, Tahara M, Licitra L, et al. The evolving role of taxanes in combination with cetuximab for the treatment of recurrent and/or metastatic squamous cell carcinoma of the head and neck: evidence, advantages, and future directions. *Front Oncol* 2019;9:668