





# Pseudocyst-Portal Vein Fistula with Hepatic Pseudocysts as Life-Threatening Complication of Pancreatitis: A Case Series with Review of Literature

Pritam Das<sup>1</sup> Dhruv Thakur<sup>2</sup> Gourav Jyoti Borah<sup>3</sup>  Naganath Kashinath Wodeyar<sup>3</sup> Kartik Balankhe<sup>3</sup>  
S. Rakesh Kumar<sup>3</sup> Samir Mohindra<sup>3</sup> 

<sup>1</sup> Department of Gastroenterology, King George's Medical University, Lucknow, Uttar Pradesh, India

<sup>2</sup> Department of Gastroenterology, G.S.V.M., Kanpur, Uttar Pradesh, India

<sup>3</sup> Department of Gastroenterology, Sanjay Gandhi Postgraduate Institute of Medical Sciences, Lucknow, Uttar Pradesh, India

Address for correspondence Samir Mohindra, Department of Gastroenterology Sanjay Gandhi Postgraduate Institute of Medical Sciences, Lucknow 226014, Uttar Pradesh, India (e-mail: mohindrasamir@yahoo.com).

J Digest Endosc 2024;15:228–234.

## Abstract

Pseudocyst-portal vein fistula (PPVF) manifesting as hepatic pseudocyst is a very rare vascular complication of pancreatitis. We present three cases of pancreatitis manifesting as PPVF with hepatic pseudocyst. One of them had a symptomatic pseudocyst with nonpatent portal vein with sepsis, which was managed with endoscopic drainage. The second case had a symptomatic pseudocyst with nonpatent portal vein without any manifestation of sepsis or gastrointestinal (GI) bleed, which was managed conservatively with gradual improvement. The third case manifested with sepsis with organ failure and GI bleed; portal vein reconstruction was planned, but the patient succumbed to sepsis. During a follow-up of 12 months, the first two patients had an uncomplicated course. Patency of the portal vein played a key role in determining the further course of treatment. In case of a nonpatent portal vein, endoscopic drainage may be preferred in case of symptomatic patients, whereas asymptomatic patients may be managed conservatively.

## Keywords

- ▶ pseudocyst-portal vein fistula
- ▶ hepatic pseudocysts
- ▶ pancreatitis

## Introduction

Pancreatitis often leads to pancreatic pseudocysts (PPCs). Vascular complications such as portal vein thrombosis (PVT), pseudoaneurysms, and gastric varices are detected in 12 to 20% of patients.<sup>1</sup> There is a rare but life-threatening complication caused by PPC fistulizing to the portal vein (pseudocyst-portal vein fistula [PPVF]). Although there are no clear guidelines for managing PPVF, clinical and radiological data are vital in determining appropriate management strategies to prevent life-threatening complications.<sup>2</sup> Importantly, a precise etiopathogenesis is yet to be established. There are several postulated theories, one postulating the presence of

pancreatic rests in liver parenchyma, resulting in pancreatic inflammation and PPCs.<sup>3</sup> It is also possible that high-pressure theory can explain how pancreatitis along with its associated inflammation leads to PVT and further extension into the liver parenchyma via low-pressure pathways.<sup>4</sup> Alternatively, PPC can form along the hepatoduodenal ligament, resulting in liver pseudocysts and subsequent PVT. These cases have the potential to pose a life-threatening management issue when pseudocysts fistulizing into portal veins are misidentified as pseudocysts, and are managed by either endoscopic or percutaneous drainage, with the risk of massive hemorrhage along the path. Furthermore, patients with extrahepatic biliary obstruction due to peripancreatic

DOI <https://doi.org/10.1055/s-0044-1792132>.  
ISSN 0976-5042.

© 2024. The Author(s).

This is an open access article published by Thieme under the terms of the Creative Commons Attribution License, permitting unrestricted use, distribution, and reproduction so long as the original work is properly cited. (<https://creativecommons.org/licenses/by/4.0/>)  
Thieme Medical and Scientific Publishers Pvt. Ltd., A-12, 2nd Floor, Sector 2, Noida-201301 UP, India

collection have difficulty identifying PPF. An attempt at biliary drainage in these cases can result in dislodgement of the thrombosis in the portal vein, leading to gastrointestinal bleeding.<sup>5</sup>

Against this background, in the present study, we aim to describe two cases of acute pancreatitis with PPF and one case of acute exacerbation of chronic calcific pancreatitis. We also aimed at conducting a systematic literature review of relevant case reports or series published on PPF manifesting with hepatic pseudocysts in patients with pancreatitis.

## Methods

In this case series, we present a total of three cases from our departmental database. For the review of literature, a non-exhaustive, systematic search was conducted on PubMed via Medline, Embase, and Scopus using the keywords that included but not limited to “pseudocyst-portal vein fistula,” “hepatic pseudocyst,” and “pancreatitis”—from the inception of each database to February 2024. The search was restricted to English-language articles. Two authors independently screened the titles, abstracts, and full texts, and extracted data using standard methods. Any disagreements were resolved by discussion or referring to a third author.

## Results

### Patient 1

A 41-year-old man with a history of alcohol use and diabetes mellitus presented with epigastric pain persisting for 1 year. Imaging revealed a head stricture with parenchymal and intraductal calcification in the pancreas, along with a pancreatic head collection (walled-off necrosis [WON]) communicating with the lumen of the main portal vein (MPV) and its branches. Management involved multiple endoscopic retrograde cholangiopancreatography (ERCP) procedures. Selective cannulation of the main pancreatic duct (MPD) revealed dye leaking into a large collection, with a distal duct disruption. A single pigtail stent was placed at the entry of the collection. Subsequent ERCPs showed the short ventral duct opening directly into the collection, with graded dilatation and insertion of a distal pancreatic duct stent. An endoscopic nasocystic drain was placed in the cyst cavity, from which dirty fluid drained. Further dilatation and placement of a transpapillary biliary stent from the minor papilla into the collection were performed. Follow-up with ultrasound imaging every 2 weeks showed gradual reduction in the size of the collection and resolution of the pseudocysts. However, at week 6, ill-defined hypoechoic lesions were noted in segments IV, V, and VII, with the largest measuring 5.1 × 3.2 cm in segment VII. By week 9, a lesion involving the right lobe of the liver measuring 2.7 × 2.2 cm was observed. By week 13, resolution of the collection was noted, with the portal vein replaced by multiple cystic channels suggestive of collaterals.

### Patient 2

A 52-year-old man with a history of alcohol use presented with epigastric pain persisting for 6 months and low-grade

fever for 10 days. Imaging revealed a PPC with fistulous communication with the MPV and intrahepatic collections, along with arteriovenous shunting. Magnetic resonance cholangiopancreatography (MRCP) showed a heterogeneous fluid collection in the pancreatic head region communicating with the MPD and extending to the porta, suggestive of a WON with sequelae of pancreatic-portal vein fistula, along with portal cavernoma and portal biliopathy. Management involved conservative measures, including enzyme replacement and oral analgesia, leading to resolution of pain without evidence of sepsis, gastrointestinal bleed, or other symptoms. The patient was followed up with ultrasound imaging every 4 weeks, showing no increase in the size of the pseudocyst over the last 12 months. There was no history of gastrointestinal bleed, jaundice, or cholangitis. Contrast-enhanced computed tomography of the abdomen after 1 year revealed partial resolution of the size of the collection. The patient remained well controlled on analgesia, antioxidants, and enzyme replacement therapy.

### Patient 3

A 36-year-old man with a history of alcohol use presented with epigastric pain persisting for 3 months, accompanied by melena for 1 week, jaundice for 3 months, and fever for 3 months. Imaging revealed pancreatic head and body collections (WON) with the collection in the pancreatic head communicating with the lumen of the MPV and extending into its right and left branches, suggestive of fistulous communication. Additionally, there was extension into the inferior mesenteric vein and a loculated retroperitoneal collection in the right pararenal space containing a hyperdense hematoma. Management involved the insertion of a Malecot catheter into the pelvic ascites and retroperitoneal collection. Drainage resulted in the removal of around 5.5 L of ascites and 400 mL of serosanguineous fluid from the retroperitoneal space. Follow-up ultrasound on week 11 revealed heterogeneously hypoechoic collections in the lesser sac and retroperitoneal region, along with free ascitic fluid with septations. Magnetic resonance imaging (MRI) was performed to further evaluate the collections. Unfortunately, the patient developed sepsis, persistent acidosis, and altered sensorium. Despite medical intervention, the patient succumbed to the condition after 4 weeks of admission. The baseline presentations and the clinical outcome are summarized in ►Tables 1 and 2 and ►Fig. 1.

## Discussion

PPVF is a rare complication of PPC. It results from erosion of a PPC into the portal venous system, leading to the formation of a fistulous communication. The exact pathogenesis is not fully understood, but it is thought to involve a combination of inflammation, necrosis, and vascular erosion. Clinical presentation of PPF can vary widely and may include abdominal pain, jaundice, gastrointestinal bleeding, fever, and signs of hepatic decompensation. Imaging modalities such as ultrasound, computed tomography (CT) scan, MRI, and MRCP are essential for diagnosis, allowing visualization of the PPC, portal vein involvement, and associated

**Table 1** Demographic and clinical presentation

	Case 1	Case 2	Case 3
Age/sex	41 y/male	52 y/male	36 y/male
Etiology	Alcohol	Alcohol	Alcohol
Comorbidities	Diabetes mellitus	None	None
<b>Clinical presentation</b>			
Epigastric pain/duration	Epigastric pain/1 y	Epigastric pain/6 mo	Epigastric pain/3 mo
Gastrointestinal bleed	–	–	Melena for 1 wk
Jaundice	–	–	Jaundice/3 mo
Ascites	–	–	–
Infection	–	Low-grade fever/10 d	Fever/3 mo
Pancreatic stone/stricture	Head stricture with parenchymal and intraductal calcification	No calcification	No calcification
Pancreatic duct communication (PPC)	Present	Present	Present
Portal vein patency	Nonpatent	Nonpatent	Nonpatent
Hemorrhage from PPC	No	Intracystic bleed	Melena likely
Imaging (CECT)	Pancreatic head collection measuring 32 × 28 mm was observed (WON) Collection communicating with the lumen of the MPV, extending to involve its branches with no postcontrast enhancement suggesting fistulous communication Multiple collaterals were seen Multiple collections, hepatic pseudocyst in segments VII and VIII collectively measuring 7.6 × 4.3 cm, were observed	Pancreatic PPC with fistulous communication with the MPV and intrahepatic collections, with arteriovenous shunting Abdomen MRCP revealed a heterogeneous fluid collection in the pancreatic head region, communicating with the MPD and extending to the porta, consistent with WON with sequelae of the pancreatic-portal vein fistula; associated multiple intrahepatic collections, portal cavernoma, and portal biliopathy were observed	Pancreatic collection in the pancreatic head communicating with the lumen of the MPV and extending to involve its branches with no contrast opacification, suggesting fistulous communication. The collection is further seen extending into the IMV. There was loculated retroperitoneal collection in the right pararenal space and presence of hyperdense hematoma within the collection

Abbreviations: CECT, contrast-enhanced computed tomography; IMV, inferior mesenteric vein; MPD, main pancreatic duct; MPV, main portal vein; MRCP, magnetic resonance cholangiopancreatography; WON, walled-off necrosis.

complications.<sup>7,10</sup> The treatment of PPVF usually involves a multidisciplinary approach, including a combination of analgesics, antibiotics, and interventions, such as drainage of the pseudocyst or portal vein embolization, or even surgery. The complications of PPVF include sepsis, acidosis, altered sensorium, and, eventually, death. Due to its rarity and potentially life-threatening nature, prompt recognition and appropriate management are crucial in improving outcomes for patients with PPVF. The summary of the approach to the patients is illustrated in ► **Fig. 2**.

Management of PPVF depends on the clinical presentation, severity of symptoms, and presence of complications. Conservative measures, including pain management, enzyme replacement therapy, and supportive care, may be sufficient in asymptomatic or stable patients.<sup>16</sup> However, in cases of symptomatic PPVF or complications such as gastrointestinal bleeding or sepsis, more invasive interventions may be required. Endoscopic interventions, such as ERCP with stent placement and pseudocyst drainage, are often the first-line treatment for PPVF.<sup>16</sup> This approach allows for

direct visualization of the pancreatic duct and pseudocyst, as well as the placement of stents to promote drainage and closure of the fistulous communication. Surgical interventions, including pseudocyst drainage, pancreatic resection, and vascular interventions, may be necessary in refractory cases or in the presence of severe complications.<sup>17</sup>

The prognosis of PPVF varies depending on the severity of the disease, presence of complications, and response to treatment. While some patients may have a favorable outcome with conservative or minimally invasive interventions, others may experience persistent symptoms, recurrent complications, or even mortality. A high mortality rate is associated with PPVF.<sup>3</sup> In our case series, patient 1 responded to step-up decompression therapy. At first, the patient was drained through the major pancreatic duct, then through the minor papillae. The hepatic pseudocyst gradually resolved after ductal drainage, resulting in PVT and collaterals. During follow-up, the patient remained symptom free after therapy. Patient 2 was subjected to conservative management during initial admission. Patient 3 had poor Eastern Cooperative

**Table 2** Management and follow-up

	Case 1	Case 2	Case 3
Management	<p>ERCP 1: Selective MPD cannulation was done, which revealed dye leaking into a large collection. Beyond this collection, disrupted distal duct was seen at an angle. The wire failed to bridge over and was going into the collection with difficulty (stricture at the distal end of the MPD up to the genu). After multiple attempts, a 7 Fr × 7 cm single pig tail stent crossing the entry of the collection was inserted</p> <p>ERCP 2: Pancreatogram showed the short ventral duct opening directly into the collection. Graded Soendra biliary dilation catheter (SBDC) dilatation was done up to 10 Fr. Dye was seen to accumulate in the large cavity in the head region. A 10 Fr × 7 cm DPT was inserted just at the opening of the cavity</p> <p>ERCP 3: An 8 Fr ENCD was placed in the cavity. Dirty fluid came out of the cyst cavity</p> <p>ERCP 4: Graded SBDC was dilatation done up to 10 Fr. A 10 Fr × 5 cm TB (with side holes) was placed from the minor papilla into the collection</p>	<p>The patient was managed conservatively. Pain resolved with enzyme replacement and oral analgesia and there was no evidence of sepsis, GI bleed, or any other symptoms</p> <p>The patient was followed up with USG of the abdomen every 4 wk</p>	<p>The patient was managed with a Malecot catheter into the pelvic ascites and retroperitoneal collection. The pelvic catheter drained around 5.5 L of ascites and the retroperitoneal drain collected around 400 mL of serosanguineous fluid</p> <p>Ultrasound review done on week 11 showed a 300-mL heterogeneously hypoechoic collection in the lesser sac with dense echogenic content seen. A 370-mL collection was noted in the right side of the retroperitoneal region and free ascitic fluid was seen in the pelvis with few septations. MRI of the abdomen was done to look at the collections. The patient developed sepsis, persistent acidosis, and altered sensorium</p>
Outcome	<p>The patient was followed up with repeat abdomen USG on every 2 wk, which showed a gradual decrease in size of the collection of the pseudocysts</p> <p>Abdomen USG at week 6: ill-defined hypoechoic lesion was seen in segments IV, V, and VII, with the largest measuring 5.1 × 3.2 cm in segment VII</p> <p>Abdomen USG at week 9: a lesion measuring 2.7 × 2.2 cm involving the right lobe of the liver was observed</p> <p>Abdomen USG at week 13: there was resolution of the collection; the portal vein was replaced by multiple cystic channels suggesting the presence of collaterals</p>	<p>Follow-up for the past 12 mo: Well controlled on analgesia, antioxidants and enzyme replacement</p> <p>Repeat abdomen USG every 2 mo was not suggestive of increased size of the pseudocyst. There was no history of GI bleed, jaundice, or cholangitis</p>	<p>The patient succumbed to the disease after 4 wk of admission</p>

Abbreviations: ENCD, endoscopic nasocystic drain; ERCP, endoscopic retrograde cholangiopancreatography; GI, gastrointestinal; MPD, main pancreatic duct; MRI, magnetic resonance imaging; TB, transpapillary biliary stent; USG, ultrasonography.

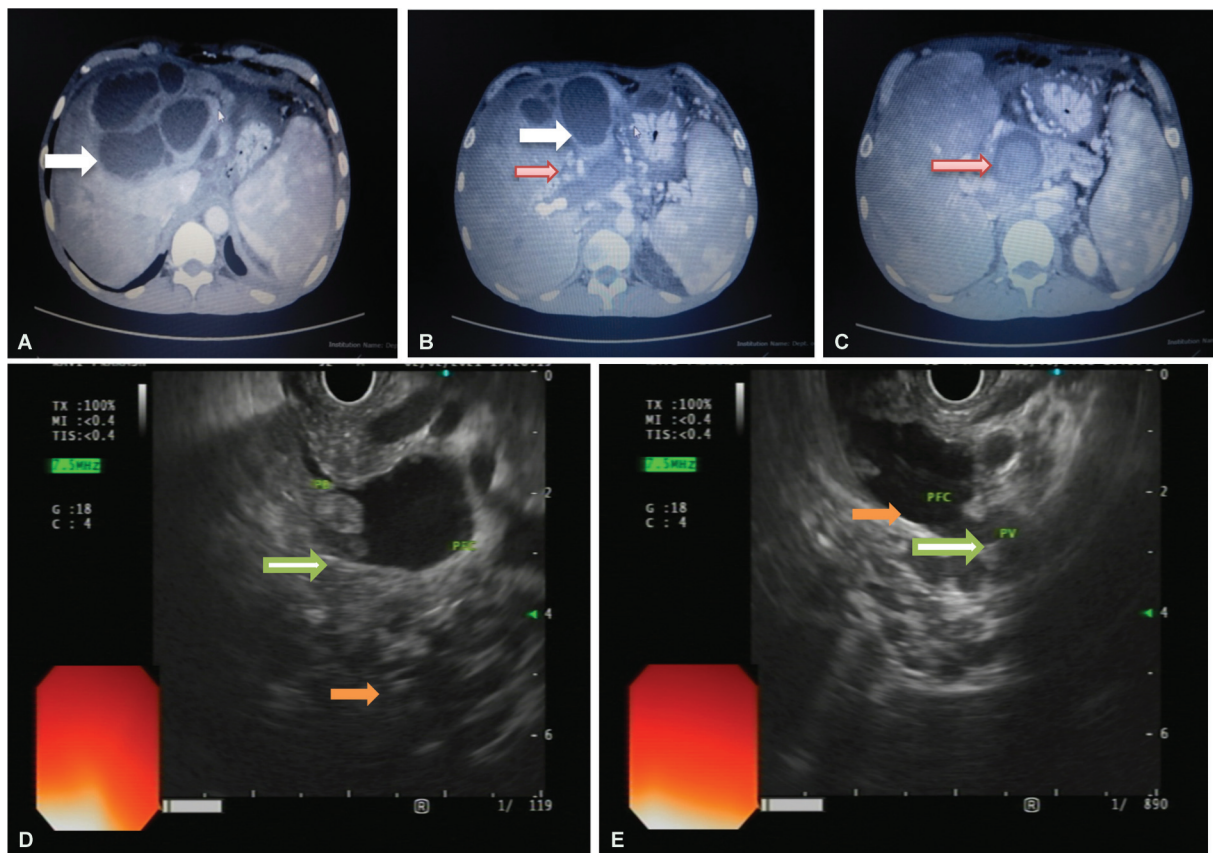
Oncology Group (ECOG) status. A broad spectrum of antibiotics was administered, and percutaneous drainage was performed on this patient. Despite drainage, he showed persistent signs of sepsis. The patient was scheduled to undergo surgical intervention or transhepatic portal vein stenting as a next step. Unfortunately, he succumbed to his illness as a result of poor health and severe sepsis. Septicemia, septic shock, disseminated intravascular coagulation (DIC) may result from infected pseudocysts communicating with portal veins, alongside major gastrointestinal bleeding risks. It is possible to prevent these complications by managing PPF in a timely manner. Infection of pseudocysts, pancreatic enzymes, and portal hypertension can result in recanalization of thrombus.<sup>18</sup>

One study details multiple instances of PPVF occurrences, with the authors suggesting that PVT arises as a result of fistula, rather than promoting its development. They discussed a significant association between excessive alcohol consumption and the emergence of PPVF, particularly when coupled with chronic pancreatitis. CT scans might not adequately diagnose PPVF, initially indicating only PVT;

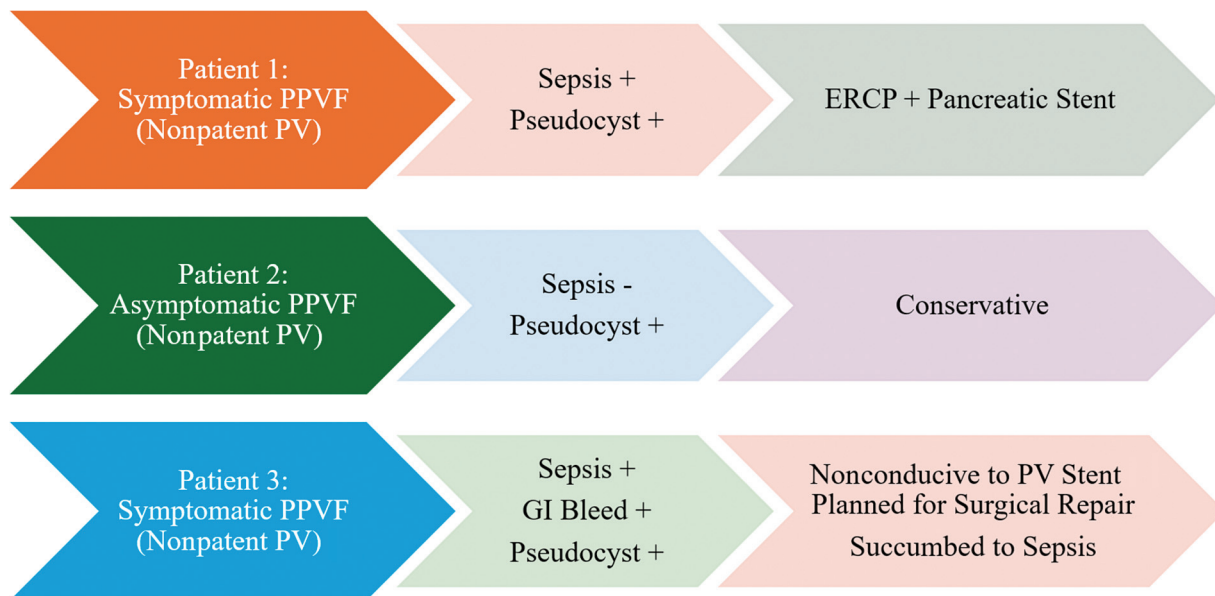
however, in our cases, expert radiological review identified PPVF alongside PVT.<sup>14</sup>

In another case presentation, a patient exhibited a sizable PPC adjacent to an enlarged, low-density fluid-filled portal vein and a liver abscess. Confirmation of PPVF came through percutaneous transhepatic portography. During endoscopic retrograde pancreatography, the patient showed signs of pancreatic duct stricture and communication with the pseudocyst. Successful pancreatic duct stenting led to the resolution of both pancreatic and hepatic fluid collections.<sup>12</sup>

Based on previous literature, the patency of the portal vein played a key role in determining the further course of treatment. Surgical repair or transhepatic portal vein stenting would be therapeutic options if the fistulous portal vein was patent. It is possible to decompress the high-pressure system by sphincterotomy and pancreatic stenting in the presence of thrombosis of the portal vein, as well as perform cystoenterostomy if the pseudocyst persists despite ductal decompression. In cases of persistent systemic inflammation and refractory cases, surgical decompression may be



**Fig. 1** (A) Contrast-enhanced computed tomography of the abdomen showing hepatic pseudocyst (white arrow). (B, C) Hepatic pseudocysts (white arrow) and portal vein pseudocyst fistula (red arrow). (D, E) Endoscopic ultrasound images showing portal vein (green arrow) and pseudocyst with communication (orange arrow).

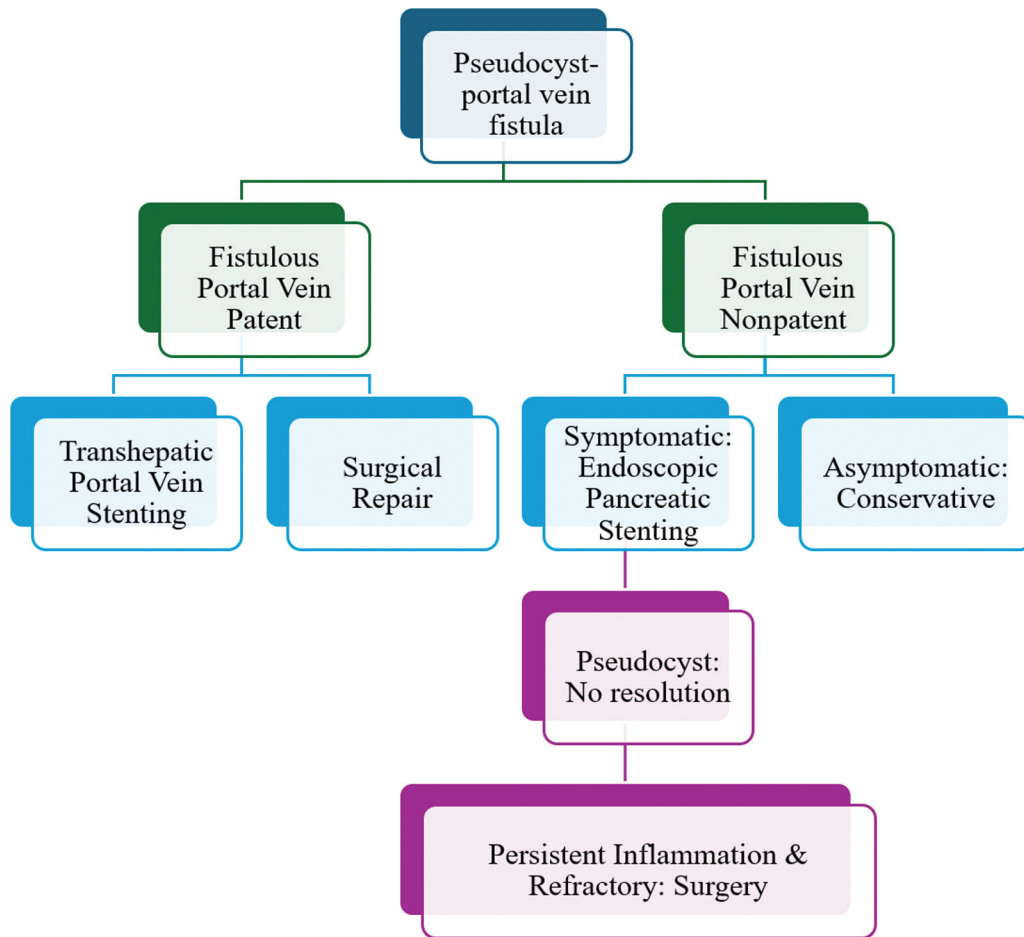


**Fig. 2** Summary of patient characteristics and management. ERCP, endoscopic retrograde cholangiopancreatography; GI, gastrointestinal; PPVF, pseudocyst-portal vein fistula; PV, portal vein.

considered. If delayed, the thrombus may dislodge or recanalize or persistent inflammation may result.

Literature on PPVF is limited due to its rarity, and most information comes from case reports and small case series.

However, several studies have highlighted the clinical features, diagnostic modalities, management strategies, and outcomes of PPVF. Overall, the literature underscores the importance of a multidisciplinary approach involving



**Fig. 3** Algorithm for management of pseudocyst-portal vein fistula.

gastroenterologists, hepatologists, interventional radiologists, and surgeons in the management of PPVF. Further research is needed to better understand the pathogenesis, optimal diagnostic strategies, and treatment algorithms for this rare but potentially life-threatening condition. Based on our experience, we propose an algorithmic approach to such patients, as illustrated in ►**Fig. 3**.

## Conclusion

In conclusion, PPVF is a rare complication of pancreatitis that can lead to significant morbidity and mortality. Clinical presentation varies, and diagnosis relies on imaging modalities such as ultrasound, CT scan, MRI, and MRCP. Management depends on the severity of symptoms and complications, with endoscopic and surgical interventions playing key roles. Further research is needed to improve our understanding of PPVF and optimize treatment strategies for this challenging condition.

### Funding

None.

### Conflict of Interest

None declared.

## References

- Kalas MA, Leon M, Chavez LO, Canalizo E, Surani S. Vascular complications of pancreatitis. *World J Clin Cases* 2022;10(22): 7665–7673
- Makary MS, Gayou EL, Kyrouac D, Shah ZK. Pancreaticportal fistula formation as a consequence of recurrent acute pancreatitis: clinical and imaging considerations. *J Clin Imaging Sci* 2018;8:4
- Raza SS, Hakeem A, Sheridan M, Ahmad N. Spontaneous pancreatic pseudocyst-portal vein fistula: a rare and potentially life-threatening complication of pancreatitis. *Ann R Coll Surg Engl* 2013;95(01):e7–e9
- Liu W, Du J-J, Li Z-H, Zhang X-Y, Zuo H-D. Liver injury associated with acute pancreatitis: The current status of clinical evaluation and involved mechanisms. *World J Clin Cases* 2021;9(34): 10418–10429
- Molina H, Chan MM, Lewandowski RJ, Gabr A, Riaz A. Complications of percutaneous biliary procedures. *Semin Intervent Radiol* 2021;38(03):364–372
- Yamamoto T, Hayakawa K, Kawakami S, et al. Rupture of a pancreatic pseudocyst into the portal venous system. *Abdom Imaging* 1999;24(05):494–496
- Chang L-H, Francoeur L, Schweiger F. Pancreaticportal fistula in association with antiphospholipid syndrome presenting as ascites and portal system thrombosis. *Can J Gastroenterol* 2002;16(09):601–605
- Hammar A-M, Sand J, Lumio J, et al. Pancreatic pseudocystportal vein fistula manifests as residivating oligoarthritis, subcutaneous, bursal and osseal necrosis: a case report and review of literature. *Hepatogastroenterology* 2002;49(43):273–278

- 9 Riddell A, Jhaveri K, Haider M. Pseudocyst rupture into the portal vein diagnosed with MRI. *Br J Radiol* 2005;78(927):265–268
- 10 Yoon SE, Lee Y-H, Yoon K-H, Choi CS, Kim H-C, Chae KM. Spontaneous pancreatic pseudocyst-portal vein fistula presenting with pancreatic ascites: strength of MR cholangiopancreatography. *Br J Radiol* 2008;81(961):e13–e16
- 11 Dawson BC, Kasa D, Mazer MA. Pancreatic pseudocyst rupture into the portal vein. *South Med J* 2009;102(07):728–732
- 12 Noh R, Kim HJ. A pancreatic pseudocyst-portal vein fistula closed by endoscopic pancreatic stent insertion. *Gastrointest Endosc* 2010;72(05):1103–1105
- 13 Horino K, Takamori H, Ikuta Y, et al. Pancreatic pseudocyst-portal vein fistula. *Open J Gastroenterol* 2012;02(03):143–144
- 14 Alessandrino F, Strickland C, Mojtahed A, Eberhardt SC, Mortele KJ. Clinical and cross-sectional imaging features of spontaneous pancreatic pseudocyst-portal vein fistula. *Clin Imaging* 2017;44:22–26
- 15 Eccles J, Wiebe E, D'Souza P, Sandha G. Pancreatic pseudocyst-portal vein fistula with refractory hepatic pseudocyst: Two cases treated with EUS cyst-gastrostomy and review of the literature. *Endosc Int Open* 2019;7(01):E83–E86
- 16 Jee KN. Pancreatic pseudocyst-portal vein fistula: serial imaging and clinical follow-up from pseudocyst to fistula. *J Korean Soc Radiol* 2015;72(03):180
- 17 Masuda S, Koizumi K, Uojima H, et al. Pancreatic pseudocyst-portal vein fistula: a case treated with EUS-guided cyst-drainage and a review of the literature. *Clin J Gastroenterol* 2020;13(04):597–606
- 18 Ng TSC, Rochefort H, Czaplicki C, et al. Massive pancreatic pseudocyst with portal vein fistula: case report and proposed treatment algorithm. *Pancreatol* 2015;15(01):88–93