

Pearls in the Pool: A Rare Case of Primary Mucinous Carcinoma of Eyelid

Sharjubala Khumanthem¹ Shilpa Manigatta Doddagowda¹ Sneha Kulkarni¹

¹Department of Pathology, Sri Devaraj Urs Medical College affiliated to Sri Devaraj Urs Academy of Higher Education and Research, Tamaka, Kolar, Karnataka, India

Address for correspondence Shilpa Manigatta Doddagowda, MD, Sri Devaraj Urs Medical College, Tamaka. Kolar, Karnataka 563101, India (e-mail: mdshilpa@sduaher.ac.in).

J Health Allied Sci^{NU}

Abstract

Primary mucinous carcinoma of the eyelid is a low-grade neoplasm and a rare pathologic entity arising from the eccrine glands. We present here the case of 64-year-old man with a swelling in the eyelid, which was clinically diagnosed as a sebaceous cyst. However, histopathological examination later confirmed it as primary mucinous carcinoma.

Keywords

- ▶ sebaceous cyst
- ▶ mucinous adenocarcinoma
- ▶ eccrine glands

Introduction

Primary mucinous carcinoma (PMC) of the eyelid is a rare uncommon neoplasm arising from sweat glands, with an incidence of 1 per 150,000 population.¹ Due to lack of typical characteristics, it is often misdiagnosed as pilomatricoma, chalazion, or epidermoid cyst before resection.² Clinically PMCs are indolent in nature; hence, these lesions are often unremarkable. They are described grossly as pedunculated, fungating, or papillomatous.³

They commonly arise in the head and neck region, with the eyelid being the most common site of origin.⁴ It is more commonly seen in males and appears most frequently between the ages of 50 and 70 years.⁵ Here, we report a case of PMC of the left upper eyelid in a 64-year-old man. They are characterized by slow growth and local invasion with a high rate of recurrence.⁶ On hematoxylin and eosin stain, PMC usually mimics metastatic carcinoma of the breast, gastrointestinal (GI) tract, ovary, or lung origin, and create a diagnostic dilemma.

Case Report

A 64-year-old male patient presented in the outpatient department of ophthalmology with a swelling over the

middle part of the left upper eyelid. Initially swelling was small and gradually increased to the present size over the course of 10 years (▶ **Fig. 1**). He is a known diabetic for the past 15 years. On local examination, a mass measuring 2 × 2 cm was found over the left upper eyelid, which was nontender and had cystic consistency without localized/generalized lymphadenopathy. The transillumination test was positive. There was no history of weight loss. All routine hematological and biochemical tests were within

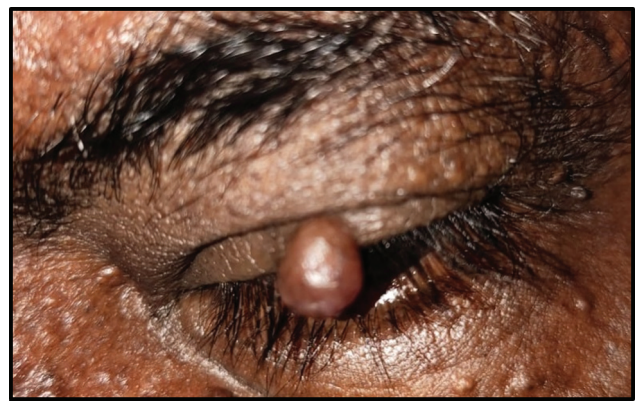


Fig. 1 Clinical image showing polypoidal lesion on the left upper eyelid.

DOI <https://doi.org/10.1055/s-0044-1792144>.
ISSN 2582-4287.

© 2024. The Author(s).

This is an open access article published by Thieme under the terms of the Creative Commons Attribution License, permitting unrestricted use, distribution, and reproduction so long as the original work is properly cited. (<https://creativecommons.org/licenses/by/4.0/>)
Thieme Medical and Scientific Publishers Pvt. Ltd., A-12, 2nd Floor, Sector 2, Noida-201301 UP, India

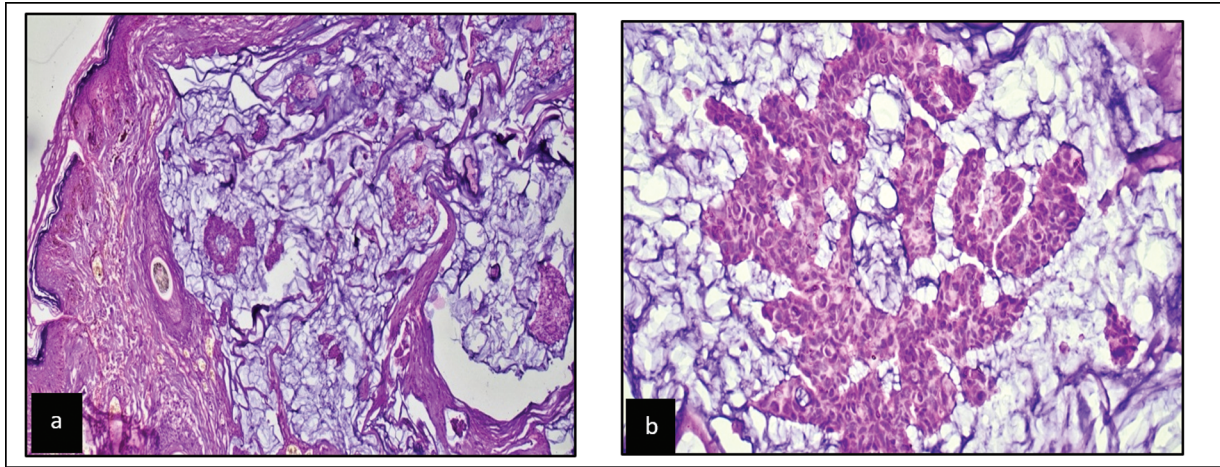


Fig. 2 (a) Microscopy showing a well-circumscribed tumor consisting of cells in pools of mucin: hematoxylin and eosin (H&E), $\times 100$. (b) Individual tumor cells had scant cytoplasm with hyperchromatic round nuclei and mild atypia: H&E, $\times 400$.

normal limits. Gastrointestinal endoscopy was done, which was normal. Computed tomography of the head and neck, chest, abdomen, and pelvis revealed no lymph node or distant metastases.

Excision biopsy with lid reconstruction was performed and sent for histopathological examination. Gross examination revealed a partially skin-covered irregular soft tissue mass measuring $1 \times 1 \times 0.5$ cm in size. On microscopic examination, sections showed epidermis with dermis having a poorly circumscribed tumor consisting of predominantly large pools of basophilic mucin compartmentalized by delicate fibrous septa with floating islands of neoplastic epithelial cells within the pools of mucin. These tumor cells were arranged in tubular and cribriform patterns. Individual tumor cells had scant cytoplasm with hyperchromatic round nuclei and mild atypia (\rightarrow Fig. 2). There was no tumor necrosis, and lymphovascular and perineural invasion. Resected margins were negative for tumor involvement. Periodic acid–Schiff (PAS) stain was positive for mucin pools (\rightarrow Fig. 3). Immunohistochemically the tumor was positive for estrogen receptor (ER), progesterone receptor (PR), and pancytokeratin AE1/AE3 immunohistochemical markers (\rightarrow Fig. 4). Based on all the findings, a final diagnosis of primary mucinous tumor of eyelid with stage IA was

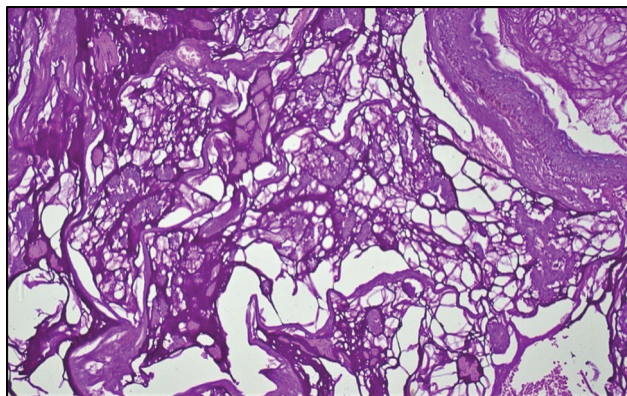


Fig. 3 Periodic acid–Schiff (PAS) stain showing mucin positivity ($\times 400$).

made. No recurrence was discerned at follow-up examination 6 months later.

Discussion

PMC is a very rare slow-growing tumor that was first described in 1952 by Lennox et al with an incidence of 1 per 150,000 population. They primarily affect middle-aged or older individuals, with 54.7 to 70% of cases occurring in men and periorbital involvement observed in 40 to 49.7% of cases. It is a slow-growing, small, flesh-colored or pale blue, smooth nodule. Because of the lack of typical characteristics, it is often misdiagnosed as an epidermoid cyst, pilomatrixoma, or chalazion before resection with subsequent enucleation performed unintentionally.^{1,2,5} It is a malignant tumor of sweat gland origin, with 40% of the cases originating periorbitally. It is a locally destructive tumor infiltrating into the muscle, orbital fat, and bone with frequent recurrence but rare metastasis.⁷ In the present case, the patient is 64-year-old.

Although it was controversial and debate exists whether it arises from eccrine or apocrine differentiation, most authors favor the eccrine differentiation based on the evidence from the immunohistochemical studies and structural analysis by electron microscopy.⁸

Mucinous carcinoma rarely originates in the skin and the majority are actually metastatic to it.⁹ Common sites of origin of mucinous carcinomas are the breast, gastrointestinal tract, salivary glands, lacrimal glands, nose, paranasal sinuses, bronchi, renal pelvis, and ovary.¹⁰ The criterion to distinguish a primary from a secondary mucinous carcinoma is the presence of an in situ component, which indicates a tumor with skin as its origin because a metastatic carcinoma from a distant place cannot have an in situ component. Moreover, since mammary neoplasms have a strong preference for the chest, breast, and axilla, the location of the tumor may be useful in the differential diagnosis. The PMC diagnosis in our case is supported by the tumor's location on the upper eyelid and the presence of low-grade atypical cells.¹¹ Primary lesions can be differentiated from metastatic

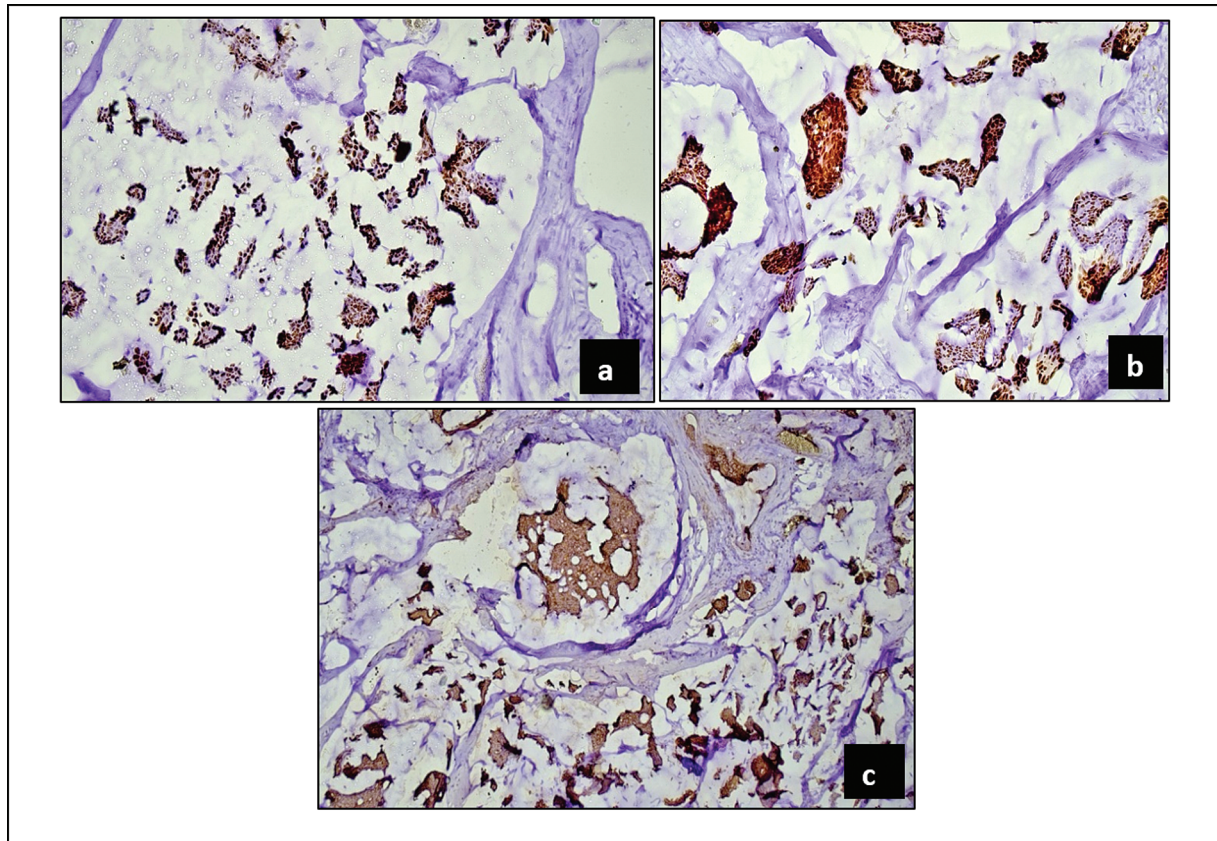


Fig. 4 Immunohistochemical staining of tumor cells showing (a) estrogen receptor positivity ($\times 200$), (b) progesterone receptor positive ($\times 400$), and (c) PanCK AE1/AE3. Positive ($\times 200$).

lesions by their more organized epithelial cells and less hyperchromatic and fewer mitoses in individual cells. In addition, in the case of metastatic carcinoma, tumor cells invade between the collagen bundles at the margin of the nodule, which was not seen in our case.

PMCs are sharply circumscribed tumor in the dermis with no connection to the epidermis. It should always be differentiated from sweat gland and sebaceous gland carcinomas.

On histopathology, PMC is composed of small clusters of tumor cells in ducts and trabeculae floating in pools of basophilic extracellular mucin. The mucin is PAS positive.¹¹ This case also showed the same microscopic features.

It is important to distinguish from metastatic adenocarcinoma and it is mainly by immunohistochemical profile. This case showed a strong expression for ER, PR, and pancytokeratin. Since endoscopy and CT findings were normal, other markers like MUC1 and MUC5AC were not done.

Treatment of PMC is primarily surgical. The majority of morbidities in patients with PMC are due to incomplete lesion resection.^{10,11} The prognosis following local excision confirmed with tumor-free margins is good. Several reports of successful treatment using Mohs micrographic surgery have been described. The treatment of choice was excision in our case as well. Other treatments, such as chemotherapy and radiation, are generally not employed in the management of these tumors. Patients should be counseled about the importance of frequent follow-ups for evaluation of local tumor recurrence or development of regional lymphadenopathy.

Conclusion

PMCs are rare challenging neoplasms and often resemble common lesions. The ophthalmologists should be aware of this tumor due to its high recurrence rate and should consider these carcinomas in the differential diagnosis of any cystic/solid lesion of the eyelid in the periorbital region.

Funding

None.

Conflict of Interest

None declared.

References

- Mehregan AH, Hashimoto K, Rahbari H. Eccrine adenocarcinoma. A clinicopathologic study of 35 cases. *Arch Dermatol* 1983;119 (02):104–114
- Saito Y, Ota K, Sumita Y. Primary mucinous carcinoma of the skin arising from the upper eyelid: a case report and literature review. *JPRAS Open* 2020;25:18–23
- Sanft D-M, Zoroquiain P, Arthurs B, Burnier MN Jr. Primary mucinous adenocarcinoma of the eyelid: a case-series. *Hum Pathol* 2017;9:19–23
- Wright JD, Font RL. Mucinous sweat gland adenocarcinoma of eyelid: a clinicopathologic study of 21 cases with histochemical and electron microscopic observations. *Cancer* 1979;44(05):1757–1768
- Ashok Kumar P, Paulraj S, Hahn SS, Sivapiragasam A. Primary mucinous adenocarcinoma of the upper eyelid in an African

- American female: a rare clinical entity. a case report and literature review. *Cureus* 2019;11(11):e6254
- 6 Smith K, Laun J, Triggs W, Payne WG. Primary cutaneous mucinous carcinoma of the eyelid. *Eplasty* 2017;17:ic26
 - 7 Lennox B, Pearse AG, Richards HG. Mucin-secreting tumours of the skin with special reference to the so-called mixed-salivary tumour of the skin and its relation to hidradenoma. *J Pathol Bacteriol* 1952;64(04):865-880
 - 8 Kavitha A, Kavya C, Sneha K, Teja C. Primary mucinous carcinoma of skin with a trichoadenomatous component: a rare case report. *Indian J Dermatol Venereol Leprol* 2019;85(02):171-174
 - 9 Snow SN, Reizner GT. Mucinous eccrine carcinoma of the eyelid. *Cancer* 1992;70(08):2099-2104
 - 10 Carson HJ, Gattuso P, Raslan WF, Reddy V. Mucinous carcinoma of the eyelid. An immunohistochemical study. *Am J Dermatopathol* 1995;17(05):494-498
 - 11 Chauhan A, Ganguly M, Takkar P, Dutta V. Primary mucinous carcinoma of eyelid: a rare clinical entity. *Indian J Ophthalmol* 2009;57(02):150-152